

World Journal of *Radiology*

World J Radiol 2019 March 28; 11(3): 27-54





MINIREVIEWS

- 27 Role of advanced magnetic resonance imaging in the assessment of malignancies of the mediastinum
Broncano J, Alvarado-Benavides AM, Bhalla S, Álvarez-Kindelan A, Raptis CA, Luna A
- 46 Progress in image-guided radiotherapy for the treatment of non-small cell lung cancer
Ren XC, Liu YE, Li J, Lin Q

ABOUT COVER

Editorial Board Member of *World Journal of Radiology*, SeyedReza Najafizadeh, MD, Associate Professor, Department of Rheumatology, Imam Khomeini Hospital, Tehran University of Medical Sciences, Tehran 1586814116, Iran

AIMS AND SCOPE

World Journal of Radiology (*World J Radiol*, *WJR*, online ISSN 1949-8470, DOI: 10.4329) is a peer-reviewed open access academic journal that aims to guide clinical practice and improve diagnostic and therapeutic skills of clinicians.

The *WJR* covers topics concerning diagnostic radiology, radiation oncology, radiologic physics, neuroradiology, nuclear radiology, pediatric radiology, vascular/interventional radiology, medical imaging achieved by various modalities and related methods analysis. The current columns of *WJR* include editorial, frontier, mini-reviews, review, medical ethics, original articles, case report, etc.

We encourage authors to submit their manuscripts to *WJR*. We will give priority to manuscripts that are supported by major national and international foundations and those that are of great basic and clinical significance.

INDEXING/ABSTRACTING

The *WJR* is now abstracted and indexed in Emerging Sources Citation Index (Web of Science), PubMed, PubMed Central, China National Knowledge Infrastructure (CNKI), China Science and Technology Journal Database (CSTJ), and Superstar Journals Database.

RESPONSIBLE EDITORS FOR THIS ISSUE

Responsible Electronic Editor: Yun-Xiaojuan Wu Proofing Editorial Office Director: Jin-Lei Wang

NAME OF JOURNAL

World Journal of Radiology

ISSN

ISSN 1949-8470 (online)

LAUNCH DATE

January 31, 2009

FREQUENCY

Monthly

EDITORS-IN-CHIEF

Venkatesh Mani

EDITORIAL BOARD MEMBERS

<https://www.wjgnet.com/1949-8470/editorialboard.htm>

EDITORIAL OFFICE

Jin-Lei Wang, Director

PUBLICATION DATE

March 28, 2019

COPYRIGHT

© 2019 Baishideng Publishing Group Inc

INSTRUCTIONS TO AUTHORS

<https://www.wjgnet.com/bpg/gerinfo/204>

GUIDELINES FOR ETHICS DOCUMENTS

<https://www.wjgnet.com/bpg/GerInfo/287>

GUIDELINES FOR NON-NATIVE SPEAKERS OF ENGLISH

<https://www.wjgnet.com/bpg/gerinfo/240>

PUBLICATION MISCONDUCT

<https://www.wjgnet.com/bpg/gerinfo/208>

ARTICLE PROCESSING CHARGE

<https://www.wjgnet.com/bpg/gerinfo/242>

STEPS FOR SUBMITTING MANUSCRIPTS

<https://www.wjgnet.com/bpg/GerInfo/239>

ONLINE SUBMISSION

<https://www.f6publishing.com>

Progress in image-guided radiotherapy for the treatment of non-small cell lung cancer

Xiao-Cang Ren, Yue-E Liu, Jing Li, Qiang Lin

ORCID number: Xiao-Cang Ren (0000-0001-5632-1434); Yue-E Liu (0000-0002-4222-2061); Jing Li (0000-0003-1724-3490); Qiang Lin (0000-0001-9599-4121).

Author contributions: Ren XC wrote the manuscript; Liu YE and Li J contributed to the writing of the manuscript; Lin Q designed the editorial and wrote the manuscript.

Conflict-of-interest statement:

There is no conflict of interest associated with any of the senior author or other coauthors contributed their efforts in this manuscript.

Open-Access: This article is an open-access article which was selected by an in-house editor and fully peer-reviewed by external reviewers. It is distributed in accordance with the Creative Commons Attribution Non Commercial (CC BY-NC 4.0) license, which permits others to distribute, remix, adapt, build upon this work non-commercially, and license their derivative works on different terms, provided the original work is properly cited and the use is non-commercial. See: <http://creativecommons.org/licenses/by-nc/4.0/>

Manuscript source: Invited manuscript

Received: October 29, 2018

Peer-review started: October 29, 2018

First decision: November 29, 2018

Revised: January 27, 2019

Accepted: February 27, 2019

Article in press: March 28, 2019

Xiao-Cang Ren, Yue-E Liu, Jing Li, Qiang Lin, Department of Oncology, North China Petroleum Bureau General Hospital, Hebei Medical University, Renqiu 062552, Hebei Province, China

Corresponding author: Qiang Lin, MD, PhD, Professor, Department of Oncology, North China Petroleum Bureau General Hospital, Hebei Medical University, 8 Huizhan Avenue, Renqiu 062552, Hebei Province, China. zyy_lq@petrochina.com.cn

Telephone: +86-317-2721951

Fax: +86-317-2722381

Abstract

Lung cancer is one of the most common malignant tumors. It has the highest incidence and mortality rate of all cancers worldwide. Late diagnosis of non-small cell lung cancer (NSCLC) is very common in clinical practice, and most patients miss the chance for radical surgery. Thus, radiotherapy plays an indispensable role in the treatment of NSCLC. Radiotherapy technology has evolved from the classic two-dimensional approach to three-dimensional conformal and intensity-modulated radiotherapy. However, how to ensure delivery of an accurate dose to the tumor while minimizing the irradiation of normal tissues remains a huge challenge for radiation oncologists, especially due to the positioning error between fractions and the autonomous movement of organs. In recent years, image-guided radiotherapy (IGRT) has greatly increased the accuracy of tumor irradiation while reducing the irradiation dose delivered to healthy tissues and organs. This paper presents a brief review of the definition of IGRT and the various technologies and applications of IGRT. IGRT can help ensure accurate dosing of the target area and reduce radiation damage to the surrounding normal tissue. IGRT may increase the local control rate of tumors and reduce the incidence of radio-therapeutic complications.

Key words: Non-small cell lung cancer; Radiotherapy; Image-guided radiotherapy; Intensity-modulated radiotherapy; Positioning error

©The Author(s) 2019. Published by Baishideng Publishing Group Inc. All rights reserved.

Core tip: Lung cancer is one of the most common malignant tumors. Radiotherapy plays an indispensable role in the treatment of non-small cell lung cancer. How to ensure delivery of an accurate dose to the tumor while minimizing the irradiation of normal tissues remains a huge challenge. In this brief review, we summarize the methods of radiotherapy technology, especially for the image-guided radiotherapy (IGRT). We believe that IGRT can help ensure accurate dosing of the target area and reduce radiation

Published online: March 28, 2019

P-Reviewer: Bazeed MF, Engin G, Liang Y, Neninger E, Peitsidis P

S-Editor: Ji FF

L-Editor: A

E-Editor: Wu YXJ



damage to the surrounding normal tissue.

Citation: Ren XC, Liu YE, Li J, Lin Q. Progress in image-guided radiotherapy for the treatment of non-small cell lung cancer. *World J Radiology* 2019; 11(3): 46-54URL: <https://www.wjgnet.com/1949-8470/full/v11/i3/46.htm>DOI: <https://dx.doi.org/10.4329/wjr.v11.i3.46>

INTRODUCTION

Lung cancer is one of the most common malignant tumors, and it ranks first in both incidence and mortality worldwide. Non-small cell lung cancer (NSCLC) accounts for 80%-85% of all lung cancers^[1]. Late diagnosis of NSCLC is very common in clinical practice, and most patients miss the chance for radical surgery. Thus, radiotherapy is one of major treatment modalities for NSCLC^[1]. In recent years, continuous advancements in image-guided radiotherapy (IGRT) technology have enabled more accurate positioning and precise radiotherapy. IGRT can decrease errors during treatment, increase the local radiation dose, and reduce the dose of radiation delivered to the normal surrounding tissue to optimize the local tumor control rate and significantly improve patient quality of life^[2,3]. This paper presents a brief review of the technical developments and application of IGRT in recent years.

STATUS OF RADIOTHERAPY

Lung cancer has increased globally in both incidence and mortality. It ranks first among malignant tumors in both incidence and mortality worldwide and is a threat to human health. NSCLC account for 80%-85% of all lung cancers, and early diagnosis is limited. Approximately 85% of patients are in advanced stages at the time of diagnosis. The efficacy of surgical treatment is not ideal, and the 5-year survival rate is only about 16%^[4]. According to statistics radiotherapy was widely utilized as high as 55% in all new cancer cases^[5]. In traditional two-dimensional radiotherapy, an oncologist must control the treatment based on his experience because the imaging diagnosis and positioning system operate on a two-dimensional plane. Irradiating a large area can easily destroy normal cells around the tumor but not the tumor itself. Therefore, the treatment efficacy is poor, with obvious side effects and many complications^[6]. The ideal radiotherapy technique is to deliver a lethal dose to the target area according to the shape of the tumor without irradiating the normal tissue around the target area. In 1959, Dr. Takahashi from Japan first proposed and outlined the concept of conformal radiation therapy. The development and application of technologies such as computed tomography (CT), magnetic resonance imaging, three-dimensional treatment planning systems and multi-leaf collimators have made three-dimensional conformal radiotherapy possible and facilitated the transition from the 2-dimensional era to the 3-dimensional era. In recent years, many new technologies and new methods for improving the accuracy of treatment have been developed. Technologies such as three-dimensional conformal radiation therapy (3DCRT) and intensity-modulated radiation therapy (IMRT) have solved the problem of dose conformation in stationary target areas. However, the position and shape of the tumor and the positional relationship between the tumor and its surrounding organs can change over the course of treatment. The proactive treatment method uses a certain technique to detect the positioning error and/or movement of the target area and to improve the delivery of radiation to the tumor while correcting the error to better protect the surrounding normal tissues. Methods to ensure and control the quality of radiation therapy are still under active investigation.

DEFINITION OF IGRT

Compared to traditional radiotherapy, IGRT enhances the biological effects of radiotherapy and is considered an extension of 3DCRT and IMRT. It integrates respiratory movement over time during treatment and positioning error between fractions. It is the most advanced four-dimensional radiotherapy technology in the field of tumor treatment, featuring accurate positioning, plan design and control of

the accelerators. IGRT can correct the patient's positioning error, aid in planning subsequent radiotherapy, guide real-time beam irradiation, and collect images and/or other signals during treatment in order to ensure the accuracy of radiation delivery. The collected images and/or signals are used to guide and deliver the dose of radiation to the target area and ultimately improve the rate of local control rate and long-term survival in patients with advanced NSCLC^[7-9]. IGRT technology can correct the error between the lesions and the markers and modify the changes in the radiation dose between the tumor and normal tissues. It can reasonably adjust the dose to protect normal tissue while reducing the safe marginal region and increasing dose delivery to the tumor area^[10]. IGRT can be achieved using the following technologies: online correction, adaptive radiotherapy, breath-holding and respiratory gating control, four-dimensional radiotherapy and real-time tracking technology^[11].

IMPLEMENTATION OF IGRT IN NSCLC RADIOTHERAPY

Online correction technology

During the course of fractional treatments, two-dimensional or three-dimensional images of the patient are acquired and compared to the planned image (preplaced markers) after positioning to determine the positioning error or the error of the radiation field, which are corrected immediately to obtain the appropriate position of the target area. The optimal radiation dose can then be delivered. In recent years, online correction has evolved from earlier film to current electro phoretic image display technology, which increases the degree of automation and shortens the additional treatment time. Moreover, the X-ray source for imaging has evolved from MV imaging to KV-MV combination imaging or KV imaging alone, and the technology for the calibration image has also evolved from two-dimensional to three-dimensional imaging such as spiral CT or cone beam CT (CBCT)^[10,11].

Adaptive radiotherapy

Due to individual differences, the actual appropriate width of the marginal region around the target areas different for each patient. Therefore, it is necessary to set an individualized width of the marginal region according to the individual's positioning error and organ movement data and then to adjust the margins of the planned target volume (PTV) and the clinical target volume. The plan and mode of adaptive radiation therapy can be modified using a systematic feedback of measurements during treatment^[12,13].

CBCT-guided adaptive radiotherapy: Conventional radiotherapy plans are designed based on CT images obtained before radiotherapy. However, changes in the patient's body mass index, tumor deformation, and movement of the surrounding organs can cause displacement of the target and consequent deformation^[14]. CBCT-guided adaptive radiotherapy is a new extension of IGRT technology that allows for feedback of the target tumor volume and position changes during treatment to analyze the difference between the original plan and the treatment and to obtain real-time anatomical images in order to re-design the treatment plan. This technique can ensure appropriate dose delivery to the target area and reduce unnecessary irradiation of normal tissue, thus minimizing the side effects of radiotherapy^[15,16]. A study by Zhao *et al*^[17] described how to delineate the target area using the anatomical images collected by CBCT and how to form an outline of the new target area using deformation registration software. Under the guidance of CBCT, the treatment plan can be re-optimized. CBCT also allows for updated calculations of the actual dose accumulation in the target area and surrounding organs and an accurate final determination of the radiation dose for further treatments in order to reduce damage to normal tissues and increase dose delivery to the target area. Buckley *et al*^[18] proposed CBCT-guided helical tomotherapy (HT) as a replacement for IMRT to achieve adaptive contour delineation, planning, and fractional dose accumulation. Currently, studies of CBCT-guided radiotherapy for NSCLC mainly focus on respiratory movement and shrinkage of the target area. Interference of respiratory movement can be improved by techniques such as respiratory gating, real-time tracking and 4D-CT, while the effect of target shrinkage can be effectively addressed by the timely modification of radiotherapy plans^[19]. Adaptive radiotherapy technology based on CBCT image guidance could be comparable to adaptive HT with further optimization of the time required for adaptive radiotherapy planning. De *et al*^[20] reported that HT and IGRT are effective and safe treatment modalities for anal cancer and are considered standard of care for these conditions in our department. A study by Elsayad *et al*^[17] demonstrated 83% tumor regression and 13% progression in patients with small cell lung cancer (13 patients) or NSCLC (59 patients) undergoing

fractional CBCT-guided radiation. Moreover, the decrease in gross tumor volume was associated with the number of CBCT scans ($r = 0.313$, $P = 0.046$) and the time of chemotherapy administration ($r = 0.385$, $P = 0.013$). Weekly CBCT to monitor changes in the tumor offers the advantage of adaptive treatment for patients with lung cancer.

Breath-holding and respiratory gating technology

If the target area is affected by respiratory movement, breath-holding can temporarily eliminate such movement, allowing for a small marginal region. Before treatment, the patient should perform appropriate breathing exercises to increase the duration of breath-holding during treatment and to reduce the volume of lung radiation exposure^[21,22]. Active respiratory gating technology and deep inspiration breath hold techniques are the two options available to minimize the influence of respiratory movement. Respiratory gating is a technique that collects images from different respiratory phases in NSCLC patients and reconstructs images by using four-dimensional computed tomography (4D-CT). It can be used to calculate and reconstruct doses at different respiratory phases to better eliminate movement artifacts, adjust the radiation plan, and monitor the effects of the patient's respiratory movement on the organ and target tumor area during treatment. Ultimately, this technique allows for control of the intensity of the radiation beam to the linear accelerator and matches the specific phase of the respiratory cycle of NSCLC patients with the controlled radiation beam^[23-25]. Respiratory gating technology can reduce the influence of respiratory movement on radiotherapy. For instance, patients with stage I to II lung cancer who are affected by respiratory movements and patients with subphrenic tumors are better suited to respiratory gating technology with hypofractionated radiation therapy.

During radiotherapy, respiratory and organ movement in NSCLC patients causes movement of the tumor target area and displacement of the tumor's position in the lung, resulting in differences in anatomical position between the planned design and actual treatment. Moreover, changes in the volume and density of the lung tissue result in beam penumbra changes in the field and a lower dose of radiation delivery to the tumor target in lung tissue. Therefore, during IGLFRT, in addition to expansion of the radiation target area, assisted respiratory gating technology can help reduce the scope of treatment while increasing dose delivery to the tumor target area. This can effectively avert the possibility of mistargeted dose delivery and the consequent excessive exposure of normal tissue to radiation due to individual differences in respiratory movement^[26].

Radiotherapy techniques accounting for time

Three-dimensional radiotherapy technology can be further enhanced by accounting for time using a technique that accounts for changes in anatomical structure during imaging positioning, planning, and therapeutic implementation. Three key factors must be taken into consideration: four-dimensional image localization (collecting the time sequence of four-dimensional images throughout all phases in one respiratory cycle), four-dimensional plan design (determination of time-marked field parameters from four-dimensional image data), and four-dimensional treatment implementation (monitoring of the patient's breathing using the same respiratory monitoring device used in the four-dimensional imaging system)^[27,28].

Personalized delineation of the target range based on 4D-CT: During the course of routine spiral CT scanning, movement artifacts can cause up to 90% volumetric deviation in the 3D reconstruction of the target area. Therefore, it is very important to individualize the target range of movement in NSCLC patients^[29]. The development of 4D-CT technology not only effectively eliminates movement artifacts to accurately and reliably reproduce the target area receiving radiotherapy but also can reflect the dynamic characteristics of radiotherapy in the target area with respect to respiratory movements and perform precise, individualized delineation of the target area^[30]. 4D-CT takes advantage of three-dimensional reconstruction technology and integrates a time factor during image positioning, planning and treatment implementation stages. It also incorporates changes in anatomical structure over time, individualized target volume (ITV) changes and respiratory cycle. A study by Tan *et al.*^[31] has shown that 4D-CBCT is superior to 3D-CBCT in image guidance in small lung tumors because 4D-CBCT can reduce the uncertainty of the tumor location caused by internal respiratory movement, thereby increasing the accuracy of image guidance. Ehrbar *et al.*^[32] used 4D-CT to delineate ITV and design a radiotherapy plan for patients with lung cancer. Their results show that ITV ensured tumor coverage but that the lung tissue was exposed to higher doses of radiation. Significantly reduced ITV can improve tumor control while protecting normal tissues. In addition, Jurkovic *et al.*^[33] used the average intensity projection and maximum intensity projection techniques to

quickly and accurately delineate ITV. These techniques can significantly reduce the physical effort involved in target delineation. ITV delineation based on 4D-CT can increase the target dose and reduce the marginal region, thus reducing the radiation dose delivered to normal lung tissue.

Real-time tracking with stereotactic body radiotherapy

Because human respiratory movement is not strictly identical between two consecutive cycles, and treatment time is often longer than the image positioning time, especially when using hypofractional techniques (such as stereotactic radiotherapy), involuntary movements cannot be predicted. Real-time X-ray tracking treatment techniques have been developed to address this problem.

Image-guided hypofractionated stereotactic radiotherapy after accurate positioning in NSCLC patients can deliver large doses to the tumor target area, whereas the dose of radiation delivered to surrounding normal lung tissue is decreased^[7,34]. The tumor control rate of conventional radiotherapy is low in some patients with early NSCLC who are not candidates for surgical treatment. IGRT treatment can reduce the uncertainty of the positioning error and the movement of the target area, thereby reducing the irradiation volume, which can allow for increased daily treatment doses, shortened treatment time, and improved local control^[35]. For patients undergoing hypofractionated stereotactic radiotherapy, during the course of treatment, image guidance techniques are used to correct positioning errors and to monitor changes in tumor volume and location, thus ensuring coverage of the target area and reducing the dose absorbed by surrounding tissues^[36,37]. A study by Ehrbar *et al*^[32] showed that the control rate and overall survival of patients undergoing hypofractionated stereotactic treatment are superior to those of patients receiving conventional radiotherapy. Moreover, side effects were less common with hypofractionated radiotherapy. Verma *et al*^[38] evaluated 92 patients from 12 institutions and found from their multi-institutional study that the toxicity of stereotactic body radiotherapy (SBRT) in patients with NSCLC tumors ≥ 5 cm was acceptable. Daily treatment are associated with a high toxicity rate. Vivek *et al*^[39] reported that the 1- and 2-year actuarial local control rates in patients with NSCLC tumors ≥ 5 cm were 95.7% and 73.2%, respectively, and the 1-year and 2-year disease-free survival rates were 72.1% and 53.5%, respectively; the 1- and 2-year disease-specific survival rates were 95.5% and 78.6%, respectively. Their study indicates that SBRT is a safe and effective treatment when combined with IGRT technology (Figure 1 and Table 1).

CONCLUSION

In summary, image-guided hypofractionated radiotherapy has several advantages in the treatment of NSCLC. Functional imaging allows for the differentiation of normal tissue from tumor tissue. By ensuring radiotherapy accuracy and appropriate dosing, these technologies can lower the radiation dose delivered to normal surrounding tissue while improving the local tumor control rate of the tumor and reducing the chance of radiation complications. This results in improved the quality of life of patients after treatment. Treatment that is based on advanced image guidance technology and computer-assisted adaptive radiotherapy is likely to become the most common approach for NSCLC radiotherapy in the future.

Table 1 Summary of important data of advantage of image-guided radiotherapy in radiotherapy

Ref.	Published date	Authors	Highlights of detailed data
[21]	2003	Remouchamps <i>et al</i>	The use of mDIBH reduced the mean percentage of both lungs receiving more than 20 Gy from 20.4% to 15.2% ($P < 0.00007$)
[22]	2015	Muralidhar <i>et al</i>	The mean difference of right lung volume receiving more than 20 Gy of the dose was from 1% to -98 % (IGRT < 0.24556)
[26]	2003	Hof <i>et al</i>	In the craniocaudal direction the mean tumor movement was 5.1 mm , in the ventrodorsal direction 3.1 mm, and in the lateraldirection 2.6 mm
[31]	2017	Tan <i>et al</i>	The errors of image-guided registration using 4D-CBCT and 3D-CBCT on the X, Y, Z axes, and 3D space were 0.80 ± 0.21 mm and 1.08 ± 0.25 mm, 2.02 ± 0.46 mm and 3.30 ± 0.53 mm, 0.52 ± 0.16 mm and 0.85 ± 0.24 mm, and 2.25 ± 0.44 mm and 3.59 ± 0.48 mm (all $P < 0.001$), respectively
[32]	2017	Ehrbar <i>et al</i>	Compared with the 4D dose calculations, the mid-ventilation and single-phase tracking overestimated the target mean dose (2.3% and 1.3%), respectively
[34]	2016	Garibaldi	The PTV margins used to compensate for residual tumor localization errors were 3.1, 3.5 and 3.3 mm in the LR, SI and AP directions, respectively
[7]	2016	Wang <i>et al</i>	Position errors after correction in Left-right, Anterior-posterior and Cranial-caudal were 0.22 cm, 0.16 cm and 0.19 cm, respectively
[36]	2016	Ariyaratne <i>et al</i>	Under the use of IGRT, the population mean setup error was 0.01 cm (left-right), 0.05 cm (supero-inferior) and 0.13 cm (antero-posterior)

mDIBH: Moderate deep inspiration breath hold; IGRT: Image-guided radiotherapy; PTV: Planned target volume.

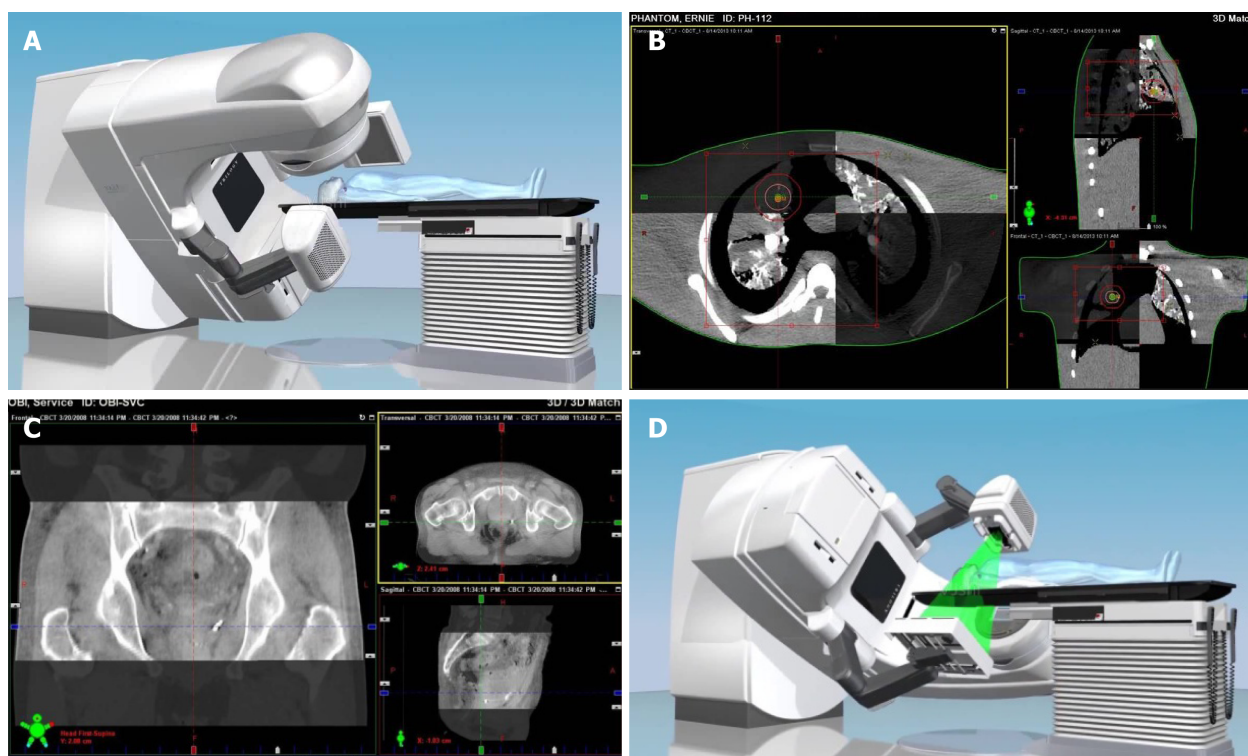


Figure 1 Images of computed tomography. A: The placement of cone beam computed tomography; B: Chest image fusion; C: Pelvic image fusion; D: Radiotherapy after correction with image-guided radiotherapy.

REFERENCES

- 1 **Glatzer M**, Elicin O, Ramella S, Nestle U, Putora PM. Radio(chemo)therapy in locally advanced nonsmall cell lung cancer. *Eur Respir Rev* 2016; **25**: 65-70 [PMID: 26929423 DOI: 10.1183/16000617.0053-2015]
- 2 **Holmes T**. *Image-Guided Radiotherapy (IGRT)*. In: Speer TW, Knowlton CA, Mackay MK. Encyclopedia of Radiation Oncology. Springer Berlin Heidelberg 2013; 364-364
- 3 **Vilote F**, Antoine M, Bobin M, Latorzeff I, Supiot S, Richaud P, Thomas L, Leduc N, Guérif S, Iriondo-Alberdi J, de Crevoisier R, Sargos P. Post-Prostatectomy Image-Guided Radiotherapy: The Invisible Target Concept. *Front Oncol* 2017; **7**: 34 [PMID: 28337425 DOI: 10.3389/fonc.2017.00034]
- 4 **Siegel R**, Naishadham D, Jemal A. Cancer statistics, 2012. *CA Cancer J Clin* 2012; **62**: 10-29 [PMID: 22237781 DOI: 10.3322/caac.20138]
- 5 **Delaney G**, Jacob S, Featherstone C, Barton M. The role of radiotherapy in cancer treatment: estimating optimal utilization from a review of evidence-based clinical guidelines. *Cancer* 2005; **104**: 1129-1137 [PMID: 16080176 DOI: 10.1002/cncr.21324]
- 6 **Moon SH**, Cho KH, Lee CG, Keum KC, Kim YS, Wu HG, Kim JH, Ahn YC, Oh D, Lee JH. IMRT vs. 2D-radiotherapy or 3D-conformal radiotherapy of nasopharyngeal carcinoma: Survival outcome in a Korean multi-institutional retrospective study (KROG 11-06). *Strahlenther Onkol* 2016; **192**: 377-385 [PMID: 26972085 DOI: 10.1007/s00066-016-0959-y]
- 7 **Wang SW**, Ren J, Yan YL, Xue CF, Tan L, Ma XW. Effect of image-guided hypofractionated stereotactic radiotherapy on peripheral non-small-cell lung cancer. *Onco Targets Ther* 2016; **9**: 4993-5003 [PMID: 27574441 DOI: 10.2147/OTT.S101125]
- 8 **De Los Santos J**, Popple R, Agazaryan N, Bayouth JE, Bissonnette JP, Bucci MK, Dieterich S, Dong L, Forster KM, Indelicato D, Langen K, Lehmann J, Mayr N, Parsai I, Salter W, Tomblin M, Yuh WT, Chetty IJ. Image guided radiation therapy (IGRT) technologies for radiation therapy localization and delivery. *Int J Radiat Oncol Biol Phys* 2013; **87**: 33-45 [PMID: 23664076 DOI: 10.1016/j.ijrobp.2013.02.021]
- 9 **Arcangeli S**, Falcinelli L, Bracci S, Greco A, Monaco A, Dognini J, Chiostri C, Bellavita R, Aristei C, Donato V. Treatment outcomes and patterns of radiologic appearance after hypofractionated image-guided radiotherapy delivered with helical tomotherapy (HHT) for lung tumours. *Br J Radiol* 2017; **90**: 20160853 [PMID: 28256158 DOI: 10.1259/bjr.20160853]
- 10 **Mao W**, Speiser M, Medin P, Papiez L, Solberg T, Xing L. Initial application of a geometric QA tool for integrated MV and kV imaging systems on three image guided radiotherapy systems. *Med Phys* 2011; **38**: 2335-2341 [PMID: 21776767 DOI: 10.1118/1.3570768]
- 11 **Arns A**, Blessing M, Fleckenstein J, Stsepankou D, Boda-Heggemann J, Simeonova-Chergou A, Hesser J, Lohr F, Wenz F, Wertz H. Towards clinical implementation of ultrafast combined kV-MV CBCT for IGRT of lung cancer : Evaluation of registration accuracy based on phantom study. *Strahlenther Onkol* 2016; **192**: 312-321 [PMID: 26864049 DOI: 10.1007/s00066-016-0947-2]
- 12 **Wang ZQ**, Li RQ, Zhang Y. Progress in Research of Adaptive Radiation Therapy for Head and Neck Cancer. *Zhongguo Aizheng Zazhi*. 2016; 131-134 [DOI: 10.3969/j.issn.1007-3969.2014.12.012]
- 13 **Wang D**, Sha XY, Lin HL. Evaluations of set-up errors and target margins for super and middle part of esophageal carcinoma in image guided radiotherapy. *Zhongguo Fangshe Yixue Yu Fanghu Zazhi* 2014; **34**: 610-612 [DOI: 10.3760/cma.j.issn.0254-5098.2014.08.012]

- 14 **Li Q**, Kim J, Balagurunathan Y, Liu Y, Latifi K, Stringfield O, Garcia A, Moros EG, Dilling TJ, Schabath MB, Ye Z, Gillies RJ. Imaging features from pretreatment CT scans are associated with clinical outcomes in nonsmall-cell lung cancer patients treated with stereotactic body radiotherapy. *Med Phys* 2017; **44**: 4341-4349 [PMID: [28464316](#) DOI: [10.1002/mp.12309](#)]
- 15 **Buckley JG**, Wilkinson D, Malaroda A, Metcalfe P. Investigation of the radiation dose from cone-beam CT for image-guided radiotherapy: A comparison of methodologies. *J Appl Clin Med Phys* 2018; **19**: 174-183 [PMID: [29265684](#) DOI: [10.1002/acm2.12239](#)]
- 16 **Rotolo N**, Floridi C, Imperatori A, Fontana F, Ierardi AM, Mangini M, Arlanti V, De Marchi G, Novario R, Dominioni L, Fugazzola C, Carrafiello G. Comparison of cone-beam CT-guided and CT fluoroscopy-guided transthoracic needle biopsy of lung nodules. *Eur Radiol* 2016; **26**: 381-389 [PMID: [26045345](#) DOI: [10.1007/s00330-015-3861-6](#)]
- 17 **Elsayad K**, Kriz J, Reinartz G, Scobioala S, Ernst I, Haverkamp U, Eich HT. Cone-beam CT-guided radiotherapy in the management of lung cancer: Diagnostic and therapeutic value. *Strahlenther Onkol* 2016; **192**: 83-91 [PMID: [26630946](#) DOI: [10.1007/s00066-015-0927-y](#)]
- 18 **Cui QL**, Sun Y, Zhong W, Chen YZ, Zhao YX. Meta-analysis of dosimetric comparison between helical tomotherapy and intensity-modulated radiotherapy for early-stage postoperative breast cancer. *Cancer Res Clin* 2016; **28**: 828-832 [DOI: [10.3760/cma.j.issn.1006-9801.2016.12.009](#)]
- 19 **Zhang SX**, Lin SQ. New progress in radiotherapy of NSCLC guided by multimodality medical imaging. *Oncology Progress* 2013; **11**: 520-524
- 20 **De Bari B**, Jumeau R, Bouchaab H, Vallet V, Matzinger O, Troussier I, Mirimanoff RO, Wagner AD, Hanhloser D, Bourhis J, Ozsahin EM. Efficacy and safety of helical tomotherapy with daily image guidance in anal canal cancer patients. *Acta Oncol* 2016; **55**: 767-773 [PMID: [27034083](#) DOI: [10.3109/0284186X.2015.1120886](#)]
- 21 **Remouchamps VM**, Vicini FA, Sharpe MB, Kestin LL, Martinez AA, Wong JW. Significant reductions in heart and lung doses using deep inspiration breath hold with active breathing control and intensity-modulated radiation therapy for patients treated with locoregional breast irradiation. *Int J Radiat Oncol Biol Phys* 2003; **55**: 392-406 [PMID: [12527053](#) DOI: [10.1016/S0360-3016\(02\)04143-3](#)]
- 22 **Muralidhar KR**, Sha RL, Rout BK, Murthy PN. Advantage of using deep inspiration breath hold with active breathing control and image-guided radiation therapy for patients treated with lung cancers. *Int J Cancer Ther Oncol* 2015; **3**: 1-7 [DOI: [10.14319/ijcto.0302.1](#)]
- 23 **Chang Q**, Lin MZ, Wang XH. Advances in radiotherapy for non-small cell lung cancer guided by image. *Zhongliu Jichu Yu Linchuang* 2014; **27**: 183-184
- 24 **Jiang SB**, Wolfgang J, Mageras GS. Quality assurance challenges for motion-adaptive radiation therapy: gating, breath holding, and four-dimensional computed tomography. *Int J Radiat Oncol Biol Phys* 2008; **71**: S103-S107 [PMID: [18406905](#) DOI: [10.1016/j.ijrobp.2007.07.2386](#)]
- 25 **Bernatowicz K**, Keall P, Mishra P, Knopf A, Lomax A, Kipritidis J. Quantifying the impact of respiratory-gated 4D CT acquisition on thoracic image quality: a digital phantom study. *Med Phys* 2015; **42**: 324-334 [PMID: [25563272](#) DOI: [10.1118/1.4903936](#)]
- 26 **Hof H**, Herfarth KK, Munter M, Essig M, Wannenmacher M, Debus J. The use of the multislice CT for the determination of respiratory lung tumor movement in stereotactic single-dose irradiation. *Strahlenther Onkol* 2003; **179**: 542-547 [PMID: [14509953](#) DOI: [10.1007/s00066-003-1070-8](#)]
- 27 **Moorees J**, Bezak E. Four dimensional CT imaging: a review of current technologies and modalities. *Australas Phys Eng Sci Med* 2012; **35**: 9-23 [PMID: [22302463](#) DOI: [10.1007/s13246-012-0124-6](#)]
- 28 **Liu Q**, Li N, Sun B. Effect of 4D-CT reconstruction technique in accurate radiotherapy for hepatocellular carcinoma. *Weichang Bingxue He Ganbingxue Zazhi* 2016; **25**: 885-888
- 29 **Zhang SX**, Chen GJ, Zhou LH, Yang KC, Lin SQ. Influences of Motion Artifacts on Three-Dimensional Reconstruction Volume and Conformal Radiotherapy Planning. *Zhongguo Shengwu Yixue Gongcheng Xuebao* 2007; **16**: 123-130
- 30 **Lu XG**, Ohtani H. The research of respiratory movement induced hepatic tumor motion in radiotherapy by use of a cone-beam CT under the fluoroscopic mode. *Riben Weisheng Kexueyuan Yuanbao* 2017; **16**: 133-139 [DOI: [10.24531/jhsaiih.16.3_133](#)]
- 31 **Tan Z**, Liu C, Zhou Y, Shen W. Preliminary comparison of the registration effect of 4D-CBCT and 3D-CBCT in image-guided radiotherapy of Stage IA non-small-cell lung cancer. *J Radiat Res* 2017; **58**: 854-861 [PMID: [28992047](#) DOI: [10.1093/jrr/rrx040](#)]
- 32 **Ehrbar S**, Johl A, Tartas A, Stark LS, Riesterer O, Klock S, Guckenberger M, Tanadini-Lang S. ITV, mid-ventilation, gating or couch tracking - A comparison of respiratory motion-management techniques based on 4D dose calculations. *Radiother Oncol* 2017; **124**: 80-88 [PMID: [28587761](#) DOI: [10.1016/j.radonc.2017.05.016](#)]
- 33 **Jurkovic I**, Stathakis S, Li Y, Patel A, Vincent J, Papanikolaou N, Mavroidis P. SU-E-J-79: Internal Tumor Volume Motion and Volume Size Assessment Using 4D CT Lung Data. *Med Phys* 2014; **41** (6 Part 7): 173-173 [DOI: [10.1118/1.4888131](#)]
- 34 **Garibaldi C**, Piperno G, Ferrari A, Surgo A, Muto M, Ronchi S, Bazani A, Pansini F, Cremonesi M, Jereczek-Fossa BA, Orecchia R. Translational and rotational localization errors in cone-beam CT based image-guided lung stereotactic radiotherapy. *Phys Med* 2016; **32**: 859-865 [PMID: [27289354](#) DOI: [10.1016/j.ejmp.2016.05.055](#)]
- 35 **Nguyen NP**, Kratz S, Chi A, Vock J, Vos P, Shen W, Vincent VH, Ewell L, Jang S, Altdorfer G, Karlsson U, Godinez J, Woods W, Dutta S, Ampil F; International Geriatric Radiotherapy Group. Feasibility of image-guided radiotherapy and concurrent chemotherapy for locally advanced nonsmall cell lung cancer. *Cancer Invest* 2015; **33**: 53-60 [PMID: [25634242](#) DOI: [10.3109/07357907.2014.1001896](#)]
- 36 **Ariyaratne H**, Chesham H, Pettingell J, Alonzi R. Image-guided radiotherapy for prostate cancer with cone beam CT: dosimetric effects of imaging frequency and PTV margin. *Radiother Oncol* 2016; **121**: 103-108 [PMID: [27576431](#) DOI: [10.1016/j.radonc.2016.07.018](#)]
- 37 **Rudat V**, Nour A, Hammoud M, Alaradi A, Mohammed A. Image-guided intensity-modulated radiotherapy of prostate cancer: Analysis of interfractional errors and acute toxicity. *Strahlenther Onkol* 2016; **192**: 109-117 [PMID: [26545764](#) DOI: [10.1007/s00066-015-0919-y](#)]
- 38 **Verma V**, Shostrom VK, Zhen W, Zhang M, Braunstein SE, Holland J, Hallemeier CL, Harkenrider MM, Iskhani A, Jabbour SK, Attia A, Lee P, Wang K, Decker RH, McGarry RC, Simone CB 2nd. Influence of Fractionation Scheme and Tumor Location on Toxicities After Stereotactic Body Radiation Therapy for Large (≥ 5 cm) Non-Small Cell Lung Cancer: A Multi-institutional Analysis. *Int J Radiat Oncol Biol Phys* 2017; **97**: 778-785 [PMID: [28244414](#) DOI: [10.1016/j.ijrobp.2016.11.049](#)]
- 39 **Verma V**, Shostrom VK, Kumar SS, Zhen W, Hallemeier CL, Braunstein SE, Holland J, Harkenrider

MM, S Iskhanian A, Neboori HJ, Jabbour SK, Attia A, Lee P, Alite F, Walker JM, Stahl JM, Wang K, Bingham BS, Hadzitheodorou C, Decker RH, McGarry RC, Simone CB 2nd. Multi-institutional experience of stereotactic body radiotherapy for large (≥ 5 centimeters) non-small cell lung tumors. *Cancer* 2017; **123**: 688-696 [PMID: [27741355](#) DOI: [10.1002/cncr.30375](#)]



Published By Baishideng Publishing Group Inc
7041 Koll Center Parkway, Suite 160, Pleasanton, CA 94566, USA
Telephone: +1-925-2238242
Fax: +1-925-2238243
E-mail: bpgoffice@wjgnet.com
Help Desk: <https://www.f6publishing.com/helpdesk>
<https://www.wjgnet.com>

