

# World Journal of *Clinical Cases*

*World J Clin Cases* 2019 February 6; 7(3): 260-404



**ORIGINAL ARTICLE****Retrospective Cohort Study**

- 260** Overexpression of HSP27 and HSP70 is associated with decreased survival among patients with esophageal adenocarcinoma

*Söderström HK, Kauppi JT, Oksala N, Paavonen T, Krogerus L, Räsänen J, Rantanen T*

**Observational Study**

- 270** Incidence, risk factors, and outcome of BK polyomavirus infection after kidney transplantation

*Favi E, Puliatti C, Sivaprakasam R, Ferrareso M, Ambrogi F, Delbue S, Gervasi F, Salzillo I, Raison N, Cacciola R*

- 291** Influencing factors of postoperative early delayed gastric emptying after minimally invasive Ivor-Lewis esophagectomy

*Huang L, Wu JQ, Han B, Wen Z, Chen PR, Sun XK, Guo XD, Zhao CM*

**Prospective Study**

- 300** Split-dose or hybrid nonsteroidal anti-inflammatory drugs and N-acetylcysteine therapy for prevention of post-retrograde cholangiopancreatography pancreatitis

*Pavel L, Bălan GG, Nicorescu A, Gîlcă-Blanariu GE, Sfarti C, Chiriac Ș, Diaconescu S, Drug VL, Bălan G, Ștefănescu G*

**SYSTEMATIC REVIEWS**

- 311** Celiac crisis, a rare occurrence in adult celiac disease: A systematic review

*Balaban DV, Dima A, Jurcut C, Popp A, Jinga M*

**META-ANALYSIS**

- 320** Hand-assisted laparoscopic splenectomy is a useful surgical treatment method for patients with excessive splenomegaly: A meta-analysis

*Huang Y, Wang XY, Wang K*

**CASE REPORT**

- 335** Successful treatment of obstructing colonic cancer by combining self-expandable stent and neoadjuvant chemotherapy: A case report

*Li ZL, Wang ZJ, Han JG, Yang Y*

- 340** Long-term survival of a patient with a large adrenal primitive neuroectodermal tumor: A case report

*Dai J, He HC, Huang X, Sun FK, Zhu Y, Xu DF*

- 347** Intravenous leiomyomatosis with different surgical approaches: Three case reports

*He J, Chen ZB, Wang SM, Liu MB, Li ZG, Li HY, Zhao G*

- 357** Ghost cell odontogenic carcinoma of the jaws: Report of two cases and a literature review  
*Jia MQ, Jia J, Wang L, Zou HX*
- 366** Papillary cystadenoma of the parotid gland: A case report  
*Wang L, Zhang SK, Ma Y, Ha PK, Wang ZM*
- 373** Castleman disease presenting with jaundice: A case report and review of literature  
*Zhai B, Ren HY, Li WD, Reddy S, Zhang SJ, Sun XY*
- 382** Considerations for routine coagulation monitoring with rivaroxaban: A case report and review of the literature  
*Wu HD, Cao HY, Song ZK, Yang S, Tang ML, Liu Y, Qin L*
- 389** Gerstmann-Sträussler-Scheinker disease: A case report  
*Zhao MM, Feng LS, Hou S, Shen PP, Cui L, Feng JC*
- 396** Biventricular pacing for treating heart failure in children: A case report and review of the literature  
*Yu S, Wu Q, Chen BL, An YP, Bu J, Zhou S, Wang YM*

**ABOUT COVER**

Editorial Board Member of *World Journal of Clinical Cases*, Shui-Bo Zhu, MD, PhD, Professor, Department of Thoracic Cardiovascular Surgery, Wuhan Military Command Wuhan General Hospital, Wuhan 430070, Hubei Province, China

**AIMS AND SCOPE**

*World Journal of Clinical Cases* (*World J Clin Cases*, *WJCC*, online ISSN 2307-8960, DOI: 10.12998) is a peer-reviewed open access academic journal that aims to guide clinical practice and improve diagnostic and therapeutic skills of clinicians.

The primary task of *WJCC* is to rapidly publish high-quality Case Report, Clinical Management, Editorial, Field of Vision, Frontier, Medical Ethics, Original Articles, Meta-Analysis, Minireviews, and Review, in the fields of allergy, anesthesiology, cardiac medicine, clinical genetics, clinical neurology, critical care, dentistry, dermatology, emergency medicine, endocrinology, family medicine, gastroenterology and hepatology, *etc.*

**INDEXING/ABSTRACTING**

*World Journal of Clinical Cases* (*WJCC*) is now indexed in PubMed, PubMed Central, Science Citation Index Expanded (also known as SciSearch®), and Journal Citation Reports/Science Edition. The 2018 Edition of Journal Citation Reports cites the 2017 impact factor for *WJCC* as 1.931 (5-year impact factor: N/A), ranking *WJCC* as 60 among 154 journals in Medicine, General and Internal (quartile in category Q2).

**RESPONSIBLE EDITORS FOR THIS ISSUE**

Responsible Electronic Editor: *Han Song*

Proofing Editorial Office Director: *Jin-Lei Wang*

**NAME OF JOURNAL**

*World Journal of Clinical Cases*

**ISSN**

ISSN 2307-8960 (online)

**LAUNCH DATE**

April 16, 2013

**FREQUENCY**

Semimonthly

**EDITORS-IN-CHIEF**

Dennis A Bloomfield, Sandro Vento

**EDITORIAL BOARD MEMBERS**

<https://www.wjgnet.com/2307-8960/editorialboard.htm>

**EDITORIAL OFFICE**

Jin-Lei Wang, Director

**PUBLICATION DATE**

February 6, 2019

**COPYRIGHT**

© 2019 Baishideng Publishing Group Inc

**INSTRUCTIONS TO AUTHORS**

<https://www.wjgnet.com/bpg/gerinfo/204>

**GUIDELINES FOR ETHICS DOCUMENTS**

<https://www.wjgnet.com/bpg/GerInfo/287>

**GUIDELINES FOR NON-NATIVE SPEAKERS OF ENGLISH**

<https://www.wjgnet.com/bpg/gerinfo/240>

**PUBLICATION MISCONDUCT**

<https://www.wjgnet.com/bpg/gerinfo/208>

**ARTICLE PROCESSING CHARGE**

<https://www.wjgnet.com/bpg/gerinfo/242>

**STEPS FOR SUBMITTING MANUSCRIPTS**

<https://www.wjgnet.com/bpg/GerInfo/239>

**ONLINE SUBMISSION**

<https://www.f6publishing.com>





# Hand-assisted laparoscopic splenectomy is a useful surgical treatment method for patients with excessive splenomegaly: A meta-analysis

Yong Huang, Xiao-Yun Wang, Kai Wang

**ORCID number:** Yong Huang (0000-0002-9154-8711); Xiao-Yun Wang (0000-0003-1549-1490); Kai Wang (0000-0002-2172-5233).

**Author contributions:** All the authors equally contributed to this work.

**Supported by** the National Natural Science Foundation of China, No. 81760514; and Youth Science Fund of Jiangxi Provincial Science and Technology Department, No. 20161BAB215252.

**Conflict-of-interest statement:** The authors declare that they have no competing interests.

**PRISMA 2009 Checklist statement:** The authors have read the PRISMA 2009 Checklist, and the manuscript was prepared and revised according to the PRISMA 2009 Checklist.

**Open-Access:** This article is an open-access article which was selected by an in-house editor and fully peer-reviewed by external reviewers. It is distributed in accordance with the Creative Commons Attribution Non Commercial (CC BY-NC 4.0) license, which permits others to distribute, remix, adapt, build upon this work non-commercially, and license their derivative works on different terms, provided the original work is properly cited and the use is non-commercial. See: <http://creativecommons.org/licenses/by-nc/4.0/>

**Manuscript source:** Unsolicited

**Yong Huang, Kai Wang,** Department of General Surgery, Hepato-Biliary-Pancreatic Surgery Division, The Second Affiliated Hospital of Nanchang University, Nanchang 330006, Jiangxi Province, China

**Xiao-Yun Wang,** Department of Operating Room, The Second Affiliated Hospital of Nanchang University, Nanchang 330006, Jiangxi Province, China

**Corresponding author:** Kai Wang, MD, PhD, Professor, Department of General Surgery, Hepato-Biliary-Pancreatic Surgery Division, The Second Affiliated Hospital of Nanchang University, No. 1, Mingde Road, Nanchang 330006, Jiangxi Province, China.

[neswk@163.com](mailto:neswk@163.com)

**Telephone:** +86-791-86259319

**Fax:** +86-791-86259319

## Abstract

### BACKGROUND

Hand-assisted laparoscopic splenectomy (HALS) can help overcome the drawbacks of laparoscopic splenectomy (LS) while maintaining its advantages.

### AIM

To evaluate the efficacy and advantages of HALS for splenomegaly.

### METHODS

The relevant literature was reviewed using the PubMed, EMBASE, Cochrane, Ovid Medline, and Wanfang databases to compare the clinical outcomes of HALS and LS. Odds ratios or mean differences were calculated with 95% confidence intervals for fixed-effects and random-effects models. Overall, 754 patients from 16 trials who met the inclusion criteria were selected.

### RESULTS

In pure splenectomy, blood loss volume ( $P < 0.001$ ) and conversion rate ( $P = 0.008$ ) were significantly lower in the HALS group than in the LS group. Conversely, for splenomegaly, the operative time ( $P = 0.04$ ) was shorter and blood loss volume ( $P < 0.001$ ) and conversion rate ( $P = 0.001$ ) were significantly lower in the HALS group than in the LS group. However, no significant difference was observed in hospital stay length, blood transfusion, time to food intake, complications, or mortality rate between the two groups. Moreover, in splenectomy and devascularization of the upper stomach (DUS), the operative time ( $P = 0.04$ ) was significantly shorter and blood loss volume ( $P < 0.001$ ) and

manuscript

**Received:** November 6, 2018**Peer-review started:** November 8, 2018**First decision:** December 10, 2018**Revised:** December 26, 2018**Accepted:** January 3, 2019**Article in press:** January 3, 2019**Published online:** February 6, 2019

conversion rate ( $P = 0.05$ ) were significantly lower in the HALS + DUS group than in the LS + DUS group. However, no significant difference was observed in hospital stay length, timing of diet, and complications between the two groups.

### CONCLUSION

HALS is an ideal surgical treatment method for splenomegaly because it can maximize the benefits for patients while maintaining the advantages of LS.

**Key words:** Hand-assisted; Laparoscopic; Splenectomy; Splenomegaly; Devascularization

©The Author(s) 2019. Published by Baishideng Publishing Group Inc. All rights reserved.

**Core tip:** Hand-assisted laparoscopic splenectomy (HALS) can help overcome the drawbacks of laparoscopic splenectomy (LS) while maintaining its advantages, but it is not widely accepted. Our study demonstrated that HALS can significantly benefit patients with splenomegaly while maintaining the advantages of LS and the tactile sense of open splenectomy. Moreover, as it improves the safety of surgery, it is a good alternative.

**Citation:** Huang Y, Wang XY, Wang K. Hand-assisted laparoscopic splenectomy is a useful surgical treatment method for patients with excessive splenomegaly: A meta-analysis. *World J Clin Cases* 2019; 7(3): 320-334

**URL:** <https://www.wjgnet.com/2307-8960/full/v7/i3/320.htm>

**DOI:** <https://dx.doi.org/10.12998/wjcc.v7.i3.320>

## INTRODUCTION

With the high incidence of chronic hepatitis B and C infections worldwide, portal hypertension secondary to liver cirrhosis is common<sup>[1-3]</sup>. Hypersplenism and splenomegaly, which are common major complications of liver cirrhosis, occur in approximately 24%-80% of cases<sup>[4,5]</sup>. Splenomegaly is associated with a great challenge in spleen retrieval during splenectomy due to dense adhesions and increased tissue vascularity, which often suggests a need for longer incision to retrieve the specimen. With rapid technological advancement in laparoscopic surgery, laparoscopic splenectomy (LS) has been proven safe and effective<sup>[6-8]</sup>. The advantages of LS over open splenectomy (OS) include less trauma, quicker recovery, and less postoperative pain<sup>[9-11]</sup>. However, patients with splenomegaly often exhibit a combination of signs and symptoms, such as hypersplenism, frequent coexistence of varices and thickening, perisplenic collateral vessel distortions, splenomegaly due to limited space of abdominal cavity, and thrombocytopenia, all of which can increase the risk of intraoperative hemorrhage and lead to conversion to open splenectomy<sup>[12,13]</sup>. Not all patients who need splenectomy benefit from LS owing to the disadvantages of laparotomy, including limited operating field, tactile feedback, and hand-eye coordination<sup>[14]</sup>. Moreover, with the increasing demand for safe and effective surgical treatment, hand-assisted LS (HALS) is preferred by most people because it has the advantages of both laparotomy and laparoscopy.

Because of these various contradictions, selecting an ideal surgical approach and maximizing its benefits for patients with splenomegaly are essential. However, previous studies have presented inconsistent results<sup>[11,14-16]</sup> due to the lack of data and group discussions during meta-analysis<sup>[16]</sup>. Additionally, some surgeons do not prefer HALS because they believe that it is a regressive surgical technique. Therefore, the present study was conducted to further divide pure splenectomy, splenomegaly, and splenectomy plus devascularization of the upper stomach (DUS) into three subgroups and evaluate the safety and feasibility of HALS compared to LS.

## MATERIALS AND METHODS

### Literature search

A systematic search of the literature was conducted in the PubMed, EMBASE, Cochrane, Ovid Medline, and Wanfang databases using the following keywords:

hand assisted, hand port, laparoscopic, and splenectomy. The search included articles published between the dates of the creation of the electronic resources and January 20, 2018. In addition, the reference lists of selected papers and systematic reviews were searched for potentially relevant studies missed out during the original search. Eligible studies were independently selected by two reviewers and any disagreements on article inclusion between the two were resolved by discussion with a third reviewer. This study protocol followed the Preferred Reporting Items for Systematic Reviews and Meta-Analyses statement and the Cochrane Handbook for Diagnostic Test Accuracy Reviews. Institutional review board approval and patient consent were waived because of the nature of this study. The Newcastle-Ottawa Scale was used to assess the quality of studies<sup>[17]</sup>, and a star system (range, 0-9 stars) was developed for the evaluation (Table 1). The study was approved by the Ethics Committee.

### **Inclusion and exclusion criteria**

All case-control studies that compared HALS and LS were selected. The inclusion criteria were patients with no requirement of additional procedures, no history of upper laparotomy, and a history of splenectomy (including malignant, benign, and normal results). In addition, the included studies must have reported data on sex, spleen weight (in kg), body mass index (BMI), maximum diameter (in cm), malignancy, blood transfusion, conversion rate, mortality rate, total morbidity, operative time (in min), hospital stay length (in days), blood loss volume (in ml), or the time to food intake (in days).

We excluded the following articles: articles that did not report outcomes, editorials, review studies, and animal studies. Neither authorship nor publisher information influenced the inclusion of articles.

### **Statistical analysis**

Statistical analyses were performed using Review Manager version 5.1 (RevMan, Cochrane Collaboration, Oxford, United Kingdom). The results of this meta-analysis are expressed as the odds ratios (ORs) for dichotomous data and mean differences (MDs) for continuous data, with 95% confidence intervals (CIs) for both. The inverse variance method was used for continuous variables, whereas the Mantel-Haenszel method was used for dichotomous variables. Statistical heterogeneity was evaluated using the  $\chi^2$  test.  $P < 0.05$  was considered statistically significant. If heterogeneity was significant, we used the random-effects model; otherwise, we used the fixed-effects model. If data were reported as median and range rather than mean and SD, the mean and SD were estimated as previously described<sup>[18,19]</sup>.

## **RESULTS**

### **Study selection and characteristics**

The search process and the selection of relevant studies are presented in Figure 1. In total, 16 trials were analyzed<sup>[11,14,20-33]</sup> (Table 1) involving 754 patients who met the criteria. There were 11 trials for pure splenectomy<sup>[11,14,20-28]</sup> involving 573 patients that compared HALS and LS, 9 trials for splenomegaly<sup>[11,14,20-22,24-26,28]</sup> involving 486 patients that compared HALS and LS, and 5 trials<sup>[29-33]</sup> involving 181 patients that compared HALS + DUS and LS + DUS.

### **HALS vs LS for pure splenectomy**

There were 11 trials for splenectomy involving 573 patients that compared HALS and LS. The splenic weight in the HALS group was significantly greater than that in the LS group (MD: 0.82, 95%CI: 0.18-1.47;  $P = 0.01$ ; Figure 2D). In addition, the maximum diameter of the spleen (MD: 2.68, 95%CI: 0.94-4.42;  $P = 0.002$ ; Figure 2F) in the HALS group was significantly greater than that in the LS group. However, no significant difference was observed in the BMI (MD: 0.45, 95%CI: -0.32 to 1.22;  $P = 0.25$ ; Figure 2A) between the two groups.

Blood loss volume (MD: -63.07, 95%CI: -86.23 to -39.90;  $P < 0.001$ ; Figure 2B) and conversion rate (OR: 0.34, 95%CI: 0.15-0.75;  $P = 0.008$ ; Figure 3D) were significantly lower in the HALS group than in the LS group. However, no significant difference was observed in the operative time (MD: -22.12, 95%CI: -52.33 to 8.09;  $P = 0.15$ ; Figure 2E), hospital stay length (MD: 0.04, 95%CI: -1.28 to 1.35;  $P = 0.96$ ; Figure 2G), blood transfusion (OR: 0.82, 95%CI: 0.44-1.54;  $P = 0.54$ ; Figure 3B), time to food intake (MD: -0.09, 95%CI: -0.21 to 0.04;  $P = 0.18$ ; Figure 2C), complications (OR: 0.95, 95%CI: 0.45-1.99;  $P = 0.88$ ; Figure 3A), or mortality rate (OR: 0.65, 95%CI: 0.21-1.542.07;  $P = 0.47$ ; Figure 3C) between the two groups.

### **HALS vs LS for splenomegaly**

Table 1 Description of included studies

| Author                                   | HALS/LS | Splenic weight                      | M/F   | MBI                   | Maximum diameter (cm) | Malignant | Blood loss (mL)                   | Transfusion | Operative time (min)           | Conversion | Complication | Total score | Hospital stay length (d)         | Diet (d)                         | Mortality | Splenomegaly |
|--|---------|-------------------------------------|-------|-----------------------|-----------------------|-----------|-----------------------------------|-------------|--------------------------------|------------|--------------|-------------|----------------------------------|----------------------------------|-----------|--------------|
| Ailawadi <i>et al</i> <sup>[20]</sup>    | 22/19   | 1.3 ± 1013/0.87 ± 0.57 <sup>1</sup> | 27/14 | -                     | -                     | 16/11     | 492 ± 630/846 ± 1084 <sup>1</sup> | -           | 161 ± 45/212 ± 61 <sup>1</sup> | 3/7        | 74/6         | 6           | 3.6 ± 1.7/4.5 ± 3.7 <sup>1</sup> | 2.3 ± 0.7/2.3 ± 0.7 <sup>1</sup> | 0/3       | Y            |
| Kercher <i>et al</i> <sup>[21]</sup>     | 7/49    | -                                   | -     | -                     | -                     | -         | -                                 | 0/2         | 283 ± 107/210 ± 207            | 0/0        | 0/3          | 6           | -                                | -                                | 0/0       | Y            |
| Rosen <i>et al</i> <sup>[22]</sup>       | 14/31   | 1.516/1.031                         | 29/16 | 25/28                 | -                     | 9/16      | 602/376                           | -           | 177/186                        | 1/7        | 5/6          | 6           | 5.4/4.2                          | -                                | 0/0       | Y            |
| Targarona <i>et al</i> <sup>[11]</sup>   | 20/36   | 1.753 ± 1.124/1.425 ± 0.844         | 34/22 | -                     | 26 ± 8/25 ± 5         | -         | -                                 | 7/14        | 135 ± 52/177 ± 52              | 1/7        | 2/13         | 8           | 4 ± 1.2/6.3 ± 3.3                | -                                | 0/0       | Y            |
| Smith <i>et al</i> <sup>[23]</sup>       | 4/3     | 1.425/0.638                         | -     | -                     | -                     | -         | 220/75                            | 3/0         | 88.4/82                        | -          | 2/0          | 6           | 5/3                              | -                                | -         | N            |
| Wang <i>et al</i> <sup>[24]</sup>        | 20/16   | 1.346 ± 0.735/1.185 ± 0.546         | 19/17 | -                     | 27 ± 7/24 ± 5         | -         | 86 ± 45/138 ± 80                  | -           | 141 ± 64/195 ± 71              | 0/4        | 0/2          | 8           | 7.4 ± 1.6/5.3 ± 3.8              | -                                | -         | Y            |
| Reso <i>et al</i> <sup>[25]</sup>        | 10/9    | -                                   | -     | -                     | -                     | -         | -                                 | -           | -                              | 0/0        | -            | 7           | -                                | -                                | 2/3       | Y            |
| Pietrabissa <i>et al</i> <sup>[26]</sup> | 43/42   | 2.46 ± 1.5/1.15 ± 0.69              | 55/29 | 24.1 ± 6.6/24 ± 4.6   | -                     | -         | -                                 | -           | 184 ± 22/176 ± 18              | 1/1        | 29/13        | 7           | 5 ± 2/4 ± 3                      | -                                | 1/0       | Y            |
| Altaf <i>et al</i> <sup>[27]</sup>       | 23/80   | 2.166 ± 1.446/0.209 ± 0.166         | 49/54 | 26.9 ± 4.8/28.7 ± 6.8 | -                     | 20/16     | 351 ± 716/84 ± 151                | 4/8         | 172 ± 54/125 ± 49              | 1/0        | 8/21         | 7           | 6.9 ± 7/3.5 ± 5                  | 3.5 ± 2.7/1.8 ± 3                | -         | N            |
| Wang <i>et al</i> <sup>[14]</sup>        | 19/20   | -                                   | 16/23 | -                     | 28 ± 7/24 ± 5         | -         | 92 ± 65/169 ± 136                 | 1/4         | 124 ± 42/195 ± 43              | 0/0        | 4/9          | 8           | 7.2 ± 2.8/8.5 ± 2.3              | 1 ± 0.1/1.1 ± 0.3                | -         | Y            |
| Wang <i>et al</i> <sup>[28]</sup>        | 41/45   | -                                   | 45/41 | 21.9 ± 2.3/21.1 ± 2.1 | 27.4 ± 7.6/24.7 ± 5.1 | -         | 81 ± 57/149 ± 84                  | 3/9         | 136 ± 41/179 ± 54              | 0/2        | 17/22        | 8           | 8.5 ± 2.9/8.8 ± 3.5              | 2.1 ± 0.9/2.3 ± 0.9              | 1/0       | Y            |
| Ando <i>et al</i> <sup>[29]</sup>        | 6/10    | 0.583 ± 0.253/0.457 ± 0.225         | -     | -                     | -                     | 0         | 531 ± 390/342 ± 513               | -           | 341 ± 94/224 ± 56              | -          | 4/1          | 7           | 19.8 ± 8.7/14.6 ± 3.5            | -                                | -         | -            |
| Li <i>et al</i> <sup>[30]</sup>          | 31/27   | -                                   | 42/16 | -                     | -                     | 0         | 238 ± 89/287 ± 115                | -           | 201 ± 41/241 ± 35              | 0/1        | -            | 7           | 10.2 ± 3.1/9.8 ± 2.9             | 2.4 ± 1.3/2.2 ± 1.2              | 0/0       | -            |
| Yu <i>et al</i> <sup>[31]</sup>          | 16/14   | -                                   | 17/13 | -                     | -                     | 0         | 250 ± 53/370 ± 45                 | -           | 270 ± 21/350 ± 19              | 0/0        | 0/1          | 7           | 12.2 ± 1/11.8 ± 1.1              | 5.7 ± 0.6/5.4 ± 0.8              | 0/0       | -            |
| Akahoishi <i>et al</i> <sup>[32]</sup>   | 10/9    | 0.680 ± 0.233/0.526 ± 0.321         | 11/8  | -                     | -                     | 0         | 250 ± 210/981 ± 821               | -           | 245 ± 51/336 ± 67              | 0/4        | 3/4          | 8           | 6.5 ± 4.2/10.2 ± 5.5             | -                                | 0/0       | -            |
| Li <i>et al</i> <sup>[33]</sup>          | 29/29   | -                                   | 29/29 | -                     | -                     | 0         | 335 ± 12/413 ± 12                 | -           | 183 ± 8/205 ± 8                | -          | 3/8          | 8           | -                                | 2.7 ± 0.4/3.1 ± 0.5              | 0/0       | -            |

<sup>1</sup>The mean and SD were estimated by median and a range; total score was calculated by adding up the points awarded in each item using the Newcastle-Ottawa Scale.

There were 9 trials for splenectomy involving 486 patients that compared HALS and LS. There was no significant difference in the splenic weight (MD: 0.60, 95%CI: -0.12 to 1.32;  $P = 0.1$ ; Figure 4C) or BMI (MD: 0.71, 95%CI: -0.16 to 1.58;  $P = 0.11$ ; Figure 4A) between the two groups.

The operative time (MD: -32.74, 95%CI: -63.32 to -2.17;  $P = 0.04$ ; Figure 4E) was significantly shorter and blood loss volume (MD: -65.13, 95%CI: -88.36 to -41.89;  $P <$

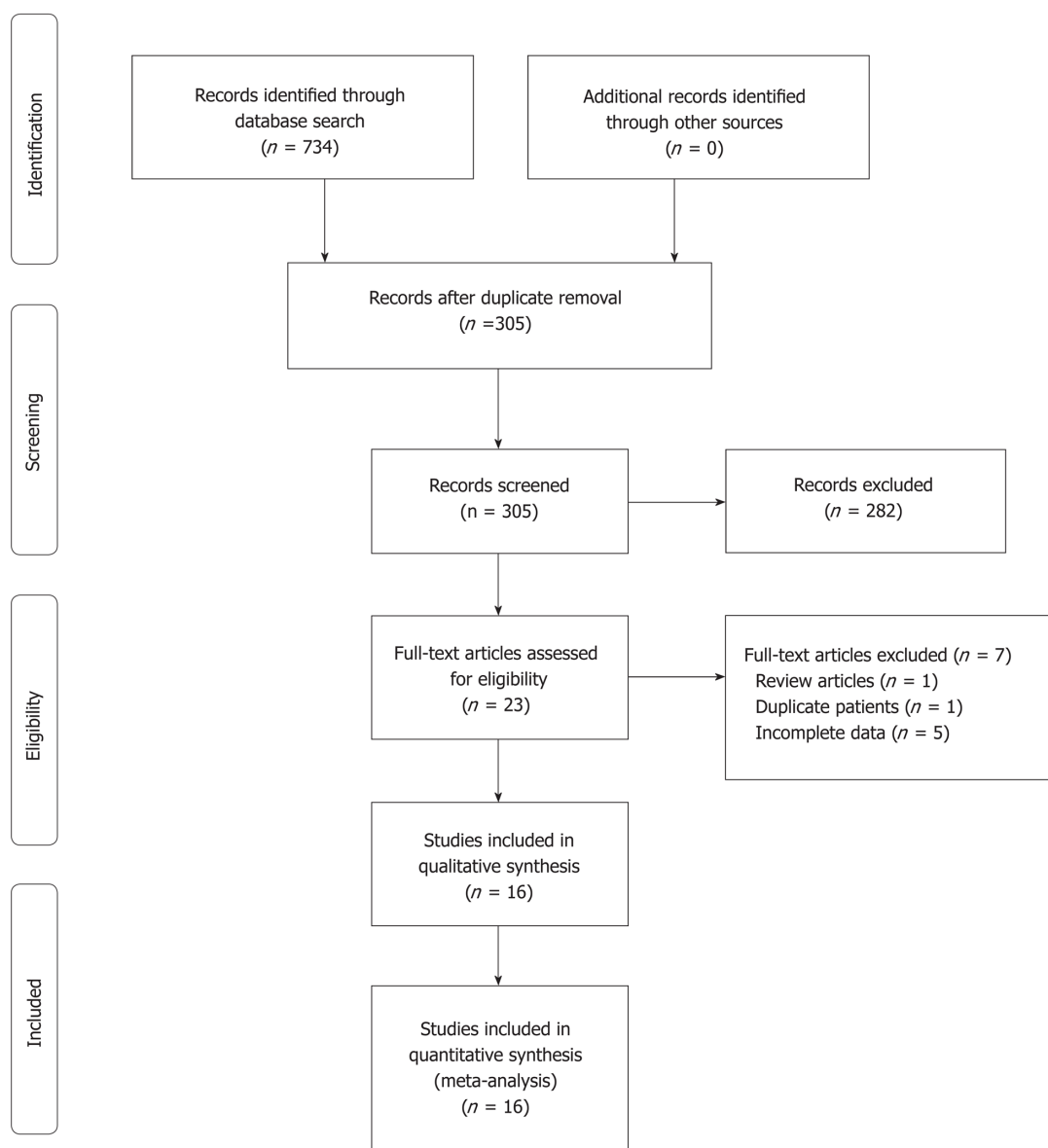


Figure 1 Flow diagram of study selection.

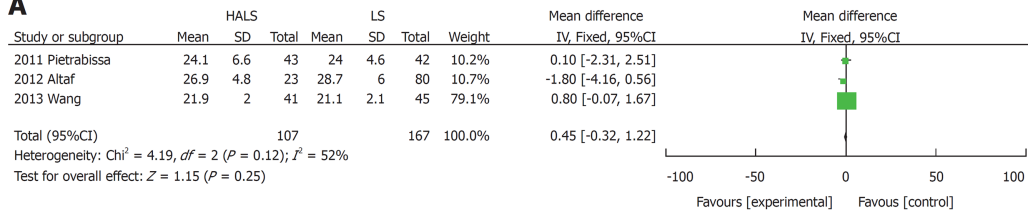
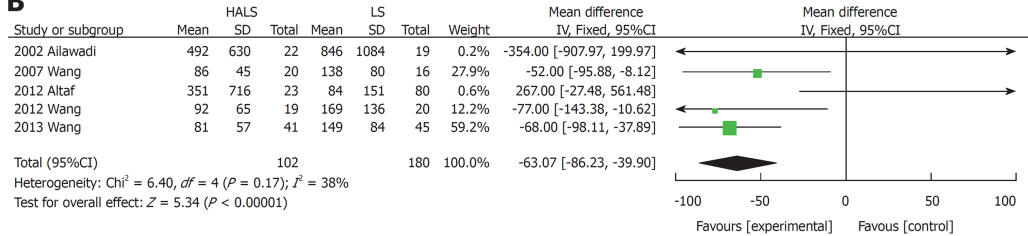
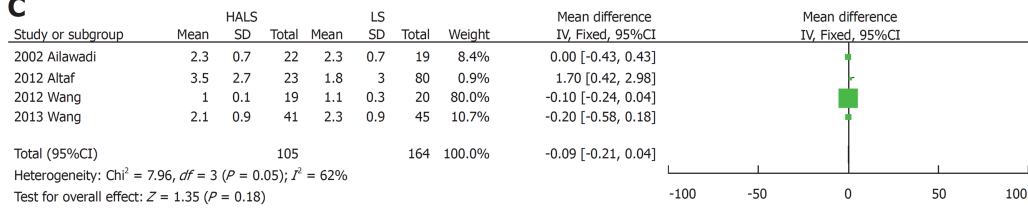
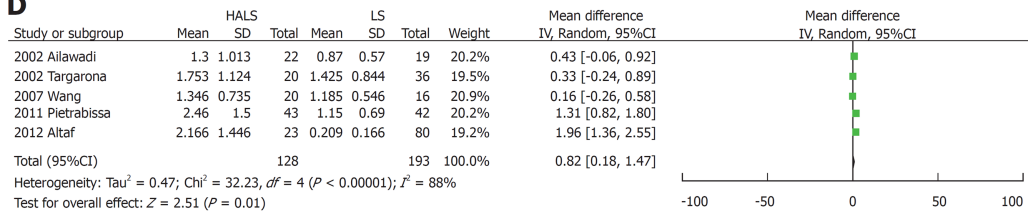
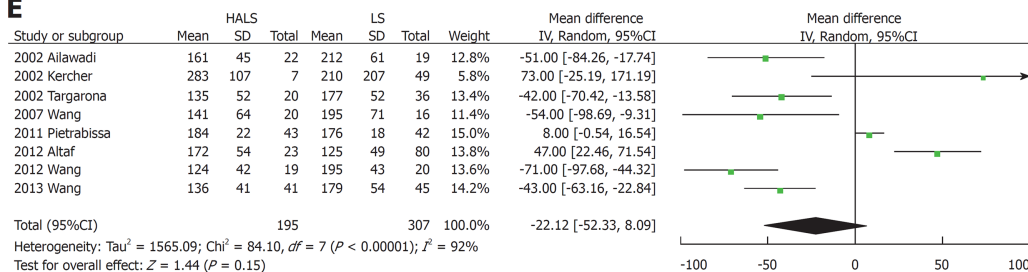
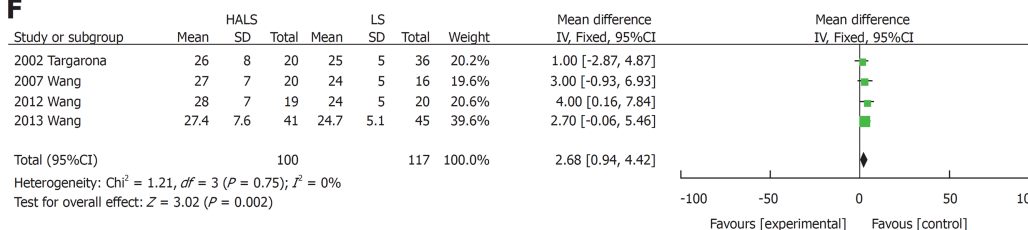
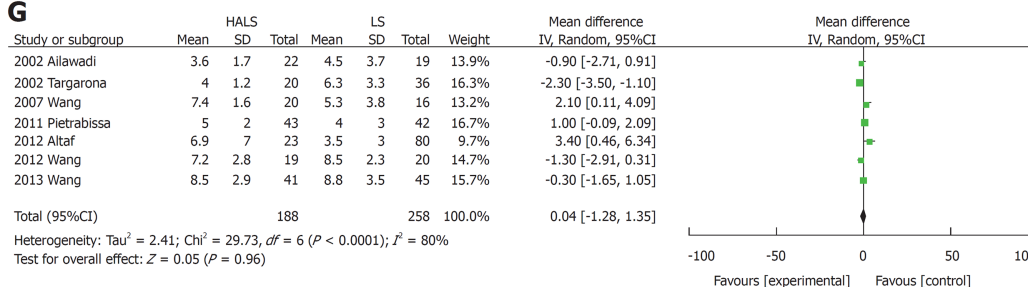
0.001; **Figure 4D**) and conversion rate (OR: 0.23, 95%CI: 0.09-0.56;  $P = 0.001$ ; **Figure 5D**) were significantly lower in the HALS group than in the LS group. However, no significant difference was observed in hospital stay length (MD: -0.39, 95%CI: -1.69 to 0.9;  $P = 0.55$ ; **Figure 4G**), blood transfusion (OR: 0.51, 95%CI: 0.24-1.12;  $P = 0.09$ ; **Figure 5B**), time to food intake (MD: -0.1, 95%CI: -0.23 to 0.02;  $P = 0.11$ ; **Figure 4B**), complications (OR: 0.76, 95%CI: 0.31-1.88;  $P = 0.55$ ; **Figure 5A**), or mortality rate (OR: 0.54, 95%CI: 0.20-2.02;  $P = 0.45$ ; **Figure 5C**) between the two groups.

### HALS + DUS vs LS + DUS

There were 5 trials for splenectomy involving 181 patients that compared HALS + DUS and LS + DUS. No significant difference was observed in the splenic weight (MD: 139.51, 95%CI: -37.35 to 316.36;  $P = 0.12$ ; **Figure 6F**) between the two groups.

The operative time (MD: -36.56, 95%CI: -72.24 to -0.88;  $P = 0.04$ ; **Figure 6D**) was significantly shorter and blood loss volume (MD: -85.77, 95%CI: -127.31 to -44.22;  $P < 0.001$ ; **Figure 6B**) and conversion rate (OR: 0.12, 95%CI: 0.01-1.02;  $P = 0.05$ ; **Figure 6E**) were significantly lower in the HALS + DUS group than in the LS + DUS group. However, no significant difference was observed in hospital stay length (MD: 0.35, 95%CI: -0.32 to 1.02;  $P = 0.31$ ; **Figure 6G**), time to food intake (MD: -0.02, 95%CI: -0.54 to 0.5;  $P = 0.94$ ; **Figure 6C**), or complications (OR: 0.73, 95%CI: 0.30-1.75;  $P = 0.48$ ; **Figure 6A**) between the two groups.

### Publication bias

**A****B****C****D****E****F****G**



**Figure 2 Forest plots of meta-analysis for pure splenectomy.** The BMI (A), blood loss volume (B), time to food intake (C), splenic weight (D), operative time (E), maximum diameter (F), and hospital stay length (G). HALS: Hand-assisted laparoscopic splenectomy; LS: Laparoscopic splenectomy.

Significant heterogeneity was found with regard to splenic weight and blood loss volume. However, no significant heterogeneity was found with regard to operative time and conversion rate. There was no significant publication bias. The combined results are highly reliable.

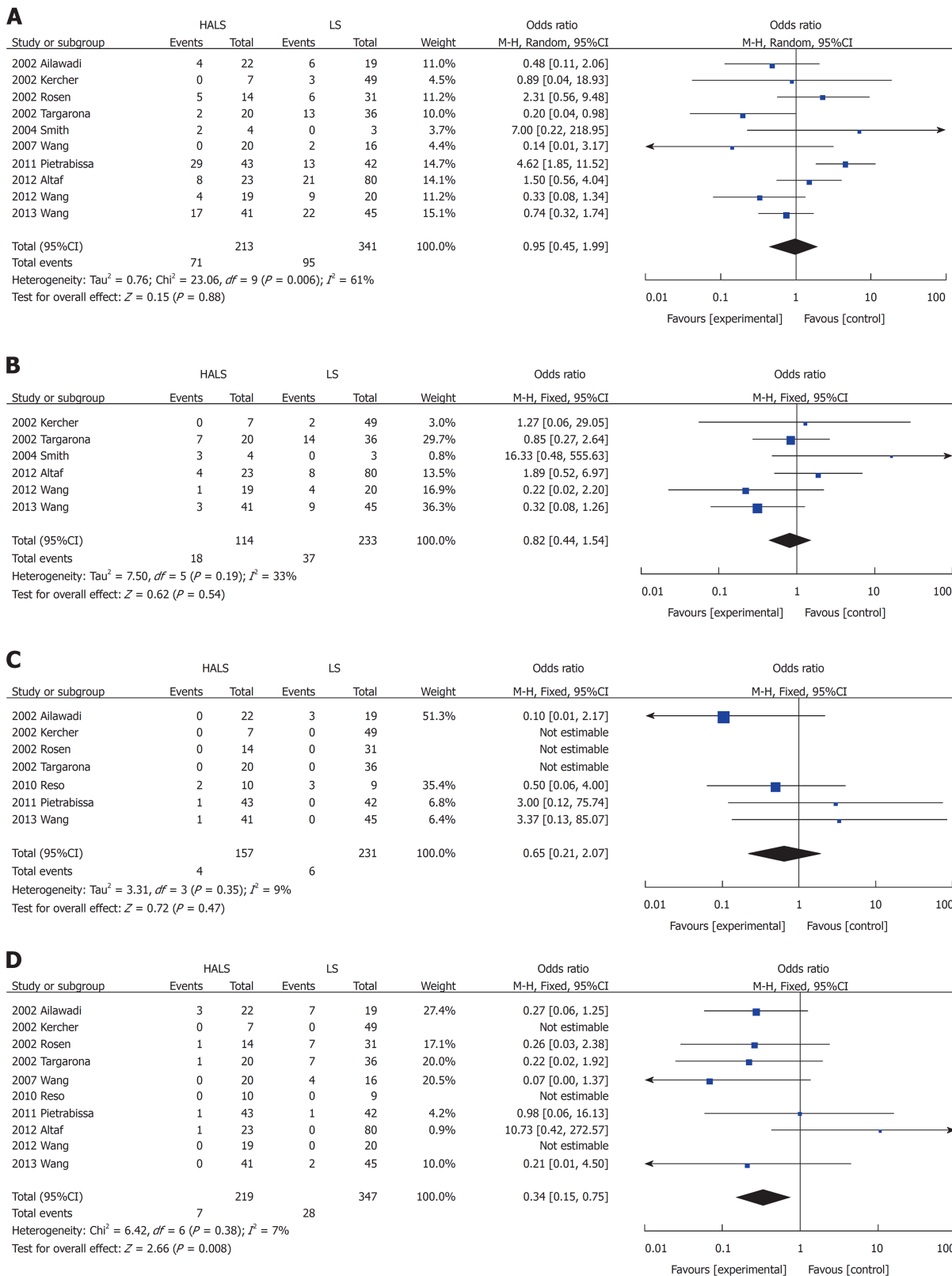
## DISCUSSION

With the high incidence of chronic hepatitis B and C infections worldwide, a large number of patients develop portal hypertension secondary to liver cirrhosis, which indicates a need for splenectomy treatment<sup>[1-3]</sup>. There is an increasing concern about the safety of the operation while ensuring minimally invasive surgery. LS is considered a standard treatment and has numerous advantages<sup>[6-8]</sup>; however, it presents greater risks, such as longer operative time, more blood loss, and higher conversion rate owing to the lack of haptic feedback and impaired hand-eye coordination, particularly for splenomegaly<sup>[16,20,24]</sup>. Fortunately, HALS, first described in 1995<sup>[34]</sup>, can overcome these drawbacks and has become an alternative to LS while maintaining the advantages of LS and OS<sup>[16,35]</sup>. Because HALS has not been widely recognized and accepted, this study was conducted. The results revealed that HALS should be the preferred choice of treatment for splenectomy or splenectomy + DUS despite the presence of splenomegaly.

This study demonstrated that either with pure splenectomy or splenomegaly, HALS exhibited better advantages than LS. Moreover, for splenectomy + DUS, the operative time was significantly shorter and blood loss volume and conversion rate were significantly lower in the HALS + DUS group than in the LS + DUS group. No significant difference was observed in hospital stay length, time to food intake, or complications between the two groups. HALS requires the chief surgeon to place one hand in the abdominal cavity while maintaining the pneumoperitoneum to improve the accuracy of manipulation by direct tactile sense. By maintaining tactile feedback and hand-eye coordination, the surgeon can bluntly dissect adhesion around the spleen and encircle the splenic pedicle and the space beneath the tail of the pancreas with the hand in the abdominal cavity<sup>[36]</sup>. This step, together with the preventive ligation of the splenic artery, will limit the result of any possible injury that might occur during the operation because the surgeon would be able to control the splenic pedicle with his or her fingers at any time<sup>[36]</sup>. Bagging these enlarged spleens is easy with hand, thus reducing operative time. After all, the surgeon's hand is more reliable than any laparoscopic instrument. The results from this study demonstrated that for pure splenectomy, blood loss volume and conversion rate were significantly lower in the HALS group than in the LS group even though the splenic weight and maximum diameter were significantly greater in the HALS group than in the LS group. For patients with splenomegaly, the operative time was significantly shorter and blood loss and conversion rate were significantly lower in the HALS group than in the LS group, whereas no significant difference was observed in the splenic weight between the two groups. As the splenic weight or size increases, the laparoscopic approach gets more difficult. With the aid of the hand in the abdominal cavity, HALS is facilitated and can be accomplished faster and more safely. Therefore, it was not surprising for patients undergoing HALS to have shorter operative time and lower blood loss volume than patients undergoing LS, as shown in the present study. For open conversion patients, massive intraoperative hemorrhage was the main concern based on the first-hand experience. When uncontrolled bleeding occurred, all operations focused more on the rapid control of bleeding, disregarding other problems, which causes a potential threat to patients. However, in HALS, this surgical uncertainty is reduced. Bleeding is easily controlled through the compression of the splenic vascular pedicle by the left hand, thereby reducing blood loss and conversion rate. In addition, HALS has a shorter learning curve<sup>[37]</sup> and was performed with fewer trocars and less assistance compared with LS. These advantages have greatly reduced the patient's financial burden.

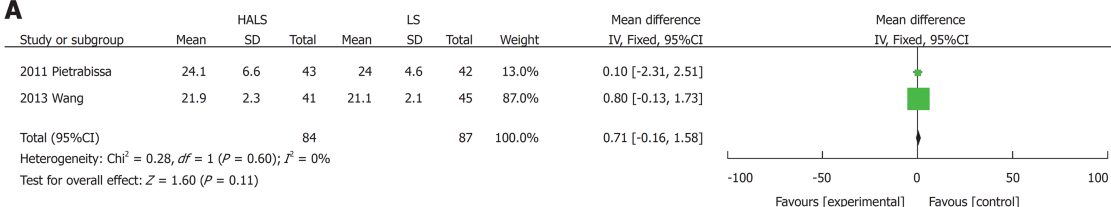
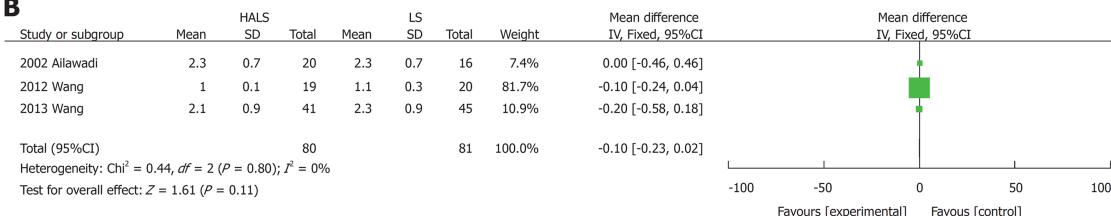
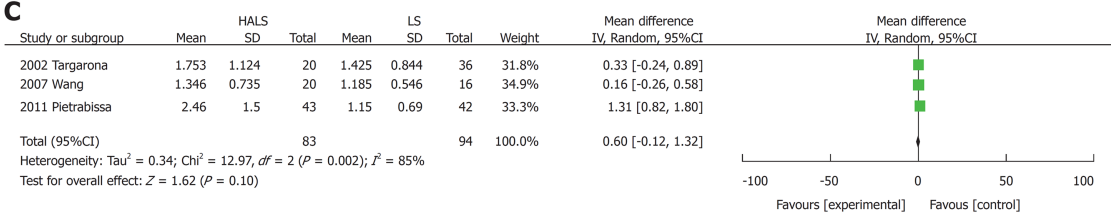
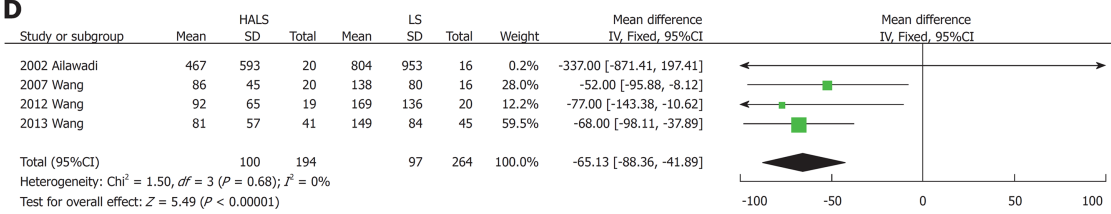
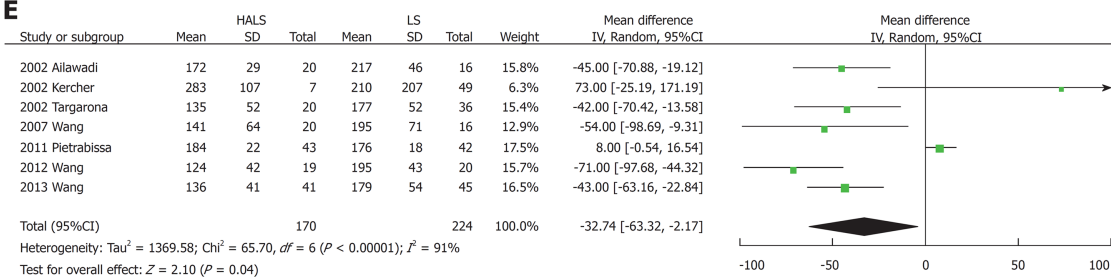
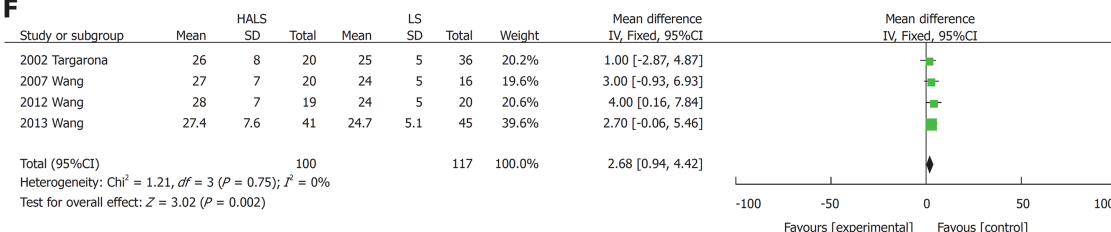
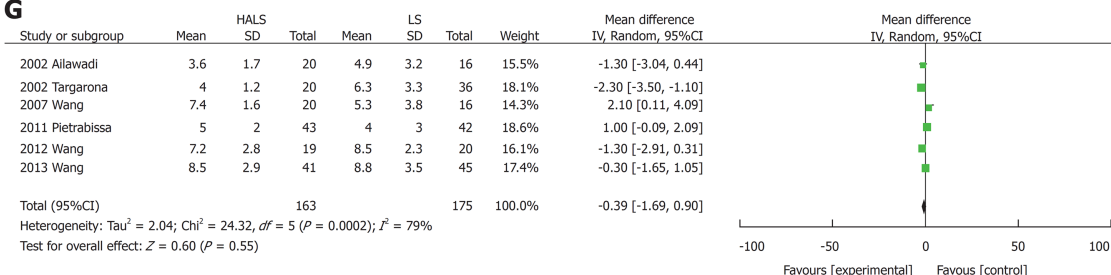
Despite these advantages, the results from this study also show that no significant difference was observed in hospital stay length, blood transfusion, timing of diet, complications, or mortality rate between the two groups. These indicated that there was no difference in the recovery speed between the two groups. Both the HALS and LS groups have a 5-cm length accessory incision; however, the incidence of surgical





**Figure 3 Forest plots of meta-analysis for pure splenectomy.** Complications (A), blood transfusion (B), mortality rate (C), and conversion rate (D). HALS: Hand-assisted laparoscopic splenectomy; LS: Laparoscopic splenectomy.

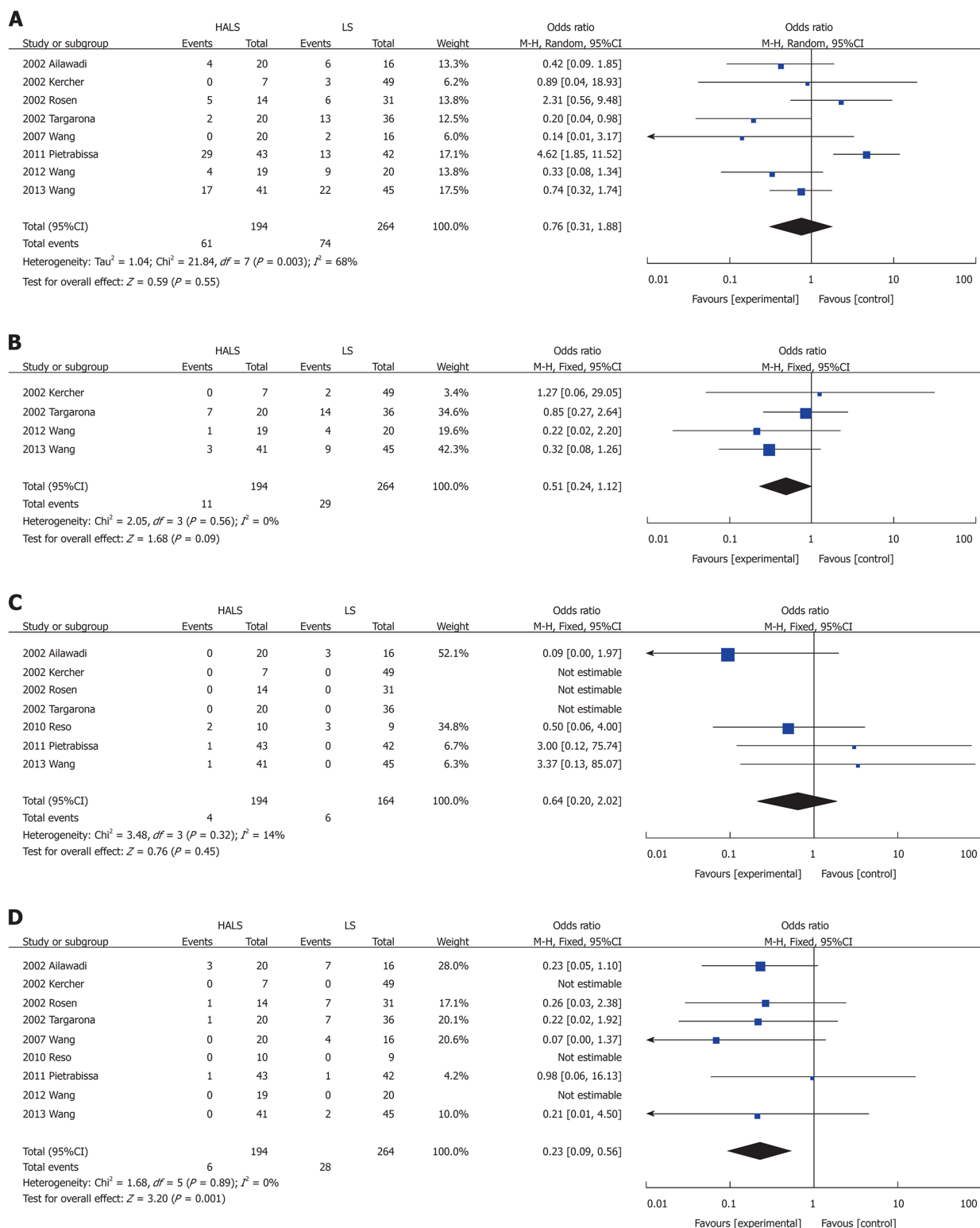
trauma is lower in the HALS group than in the LS group. In the LS group, the incision was made at the end of the operation for spleen retrieval. However, in the HALS group, the incision was made at the beginning of the operation for hand-assisted port placement. Based on the above results, HALS not only maintained the advantages of LS and OS but also overcame the disadvantages of LS and OS, resulting in the perfect combination of minimally invasive surgery and surgical safety.

**A****B****C****D****E****F****G**

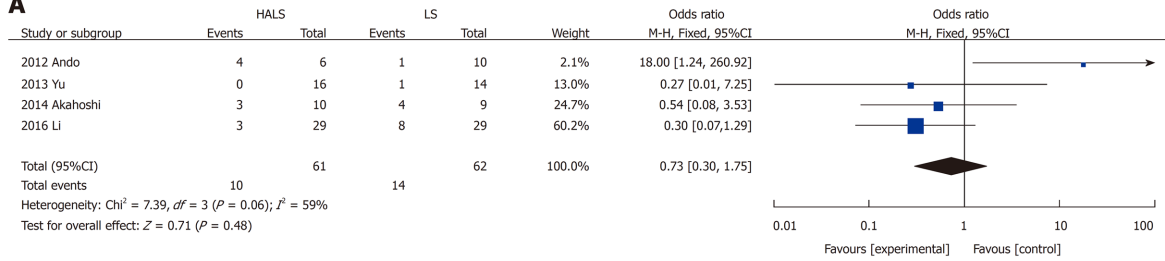
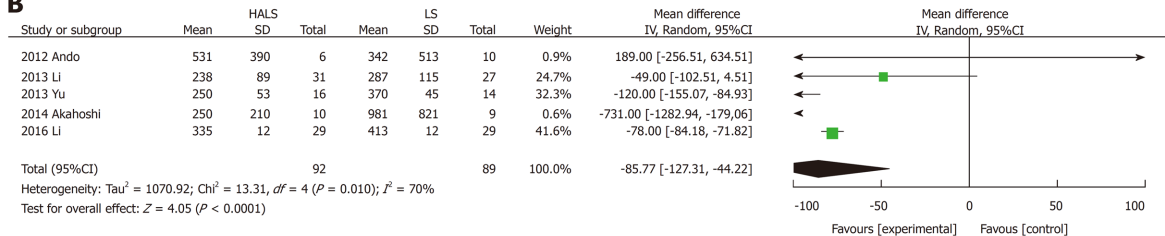
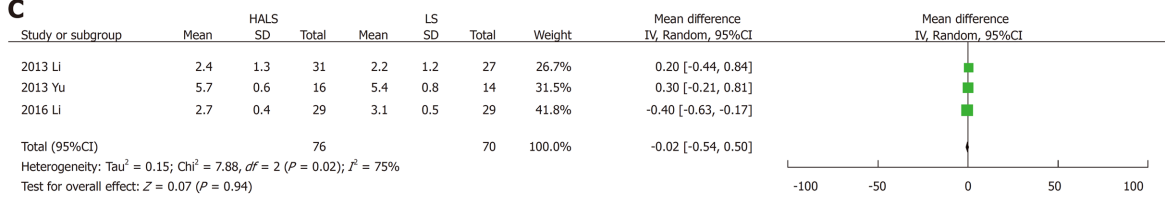
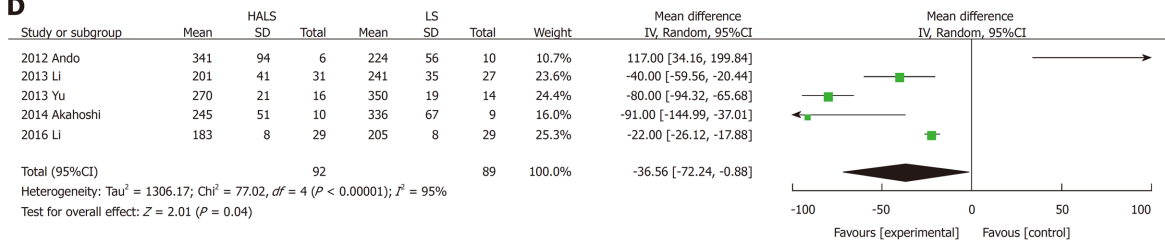
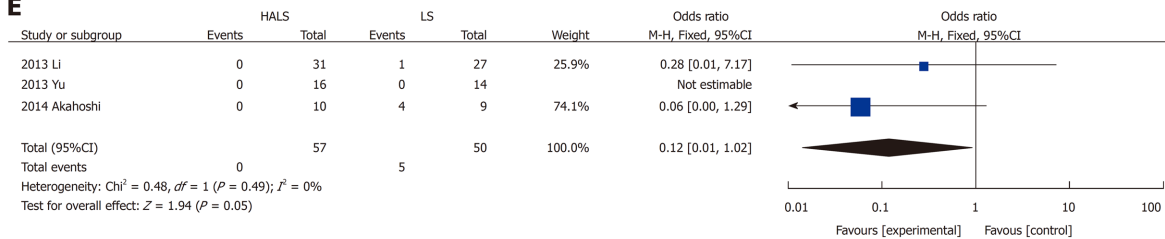
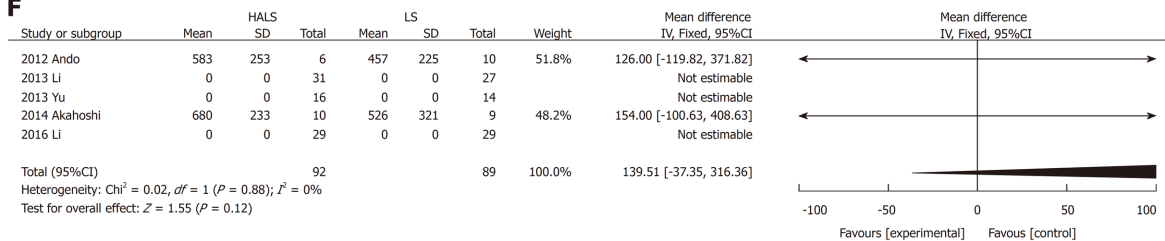
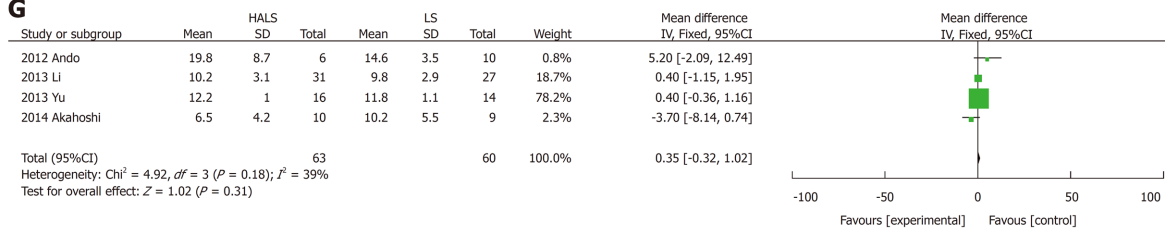
**Figure 4 Forest plots of meta-analysis for splenomegaly.** The BMI (A), time to food intake (B), splenic weight (C), blood loss volume (D), operative time (E), maximum diameter (F), and hospital stay length (G). HALS: Hand-assisted laparoscopic splenectomy; LS: Laparoscopic splenectomy.

From a technical point of view, the main challenges of HALS are as follows: (1) the hand-assisted incision should be chosen based on the criteria, such as well-exposed tissue, easy operation, minimal tissue trauma, and easy-to-convey laparotomy; (2) hand-assisted device incision and position of puncture design must be considered. It is necessary to avoid piercing using a hand-puncturing device and also to provide a space for the left hand; (3) the nondominant hand of the surgeon is easily fatigued during long-term surgical operation. The spleen and stomach ligament should be separated from top to bottom. This method easily prevents hand fatigue and provides a good field of vision at the same time; (4) in regard to splenic blood vessel treatment, prevention of bleeding is the focus of splenectomy. The main vessels, including splenic vessels of the lower pole and short gastric vessels of the upper edge of the spleen, and splenic pedicles need to be treated. If the splenic pedicle is close to the hand-assisted incision, it is blocked and double-tied with Sadin's forceps after removing the hand-assisted device; and (5) LigaSure, ultrasonic scalpel, Endo GIA, and other equipment are used to simplify the operation, reduce intraoperative bleeding, reduce the difficulty of surgery, shorten the operative time, and improve the safety of the surgery. Hand-assisted laparoscopic technique can be implemented for a difficult laparoscopic procedure and has been verified in various complicated laparoscopic operations<sup>[38]</sup>, including gastrointestinal cancer surgeries<sup>[39,40]</sup>, pancreatectomies<sup>[41,42]</sup>, nephrectomies<sup>[43,44]</sup>, and hepatectomies<sup>[45]</sup>. In the case of splenomegaly, the spleen was difficult and sometimes impossible to dissociate using complete laparoscopy due to limited visualization of this area owing to the large spleen size. For HALS, these attachments can usually be severed by blunt finger dissection even in areas that are hidden from the endoscopic view because of the retained tactile feedback<sup>[28]</sup>.

In conclusion, this study demonstrates that HALS can significantly benefit patients with splenomegaly while maintaining the advantages of LS and tactile sense of OS. Moreover, it improves the safety of surgery and is thus considered as a good alternative.



**Figure 5 Forest plots of meta-analysis for splenomegaly.** Complications (A), blood transfusion (B), mortality (C), and conversion rate (D). HALS: Hand-assisted laparoscopic splenectomy; LS: Laparoscopic splenectomy.

**A**

**B**

**C**

**D**

**E**

**F**

**G**


**Figure 6 Forest plots of meta-analysis for splenectomy and devascularization of the upper stomach.** Complications (A), blood loss volume (B), time to food intake (C), operative time (D), conversion rate (E), splenic weight (F), and hospital stay length (G). HALS: Hand-assisted laparoscopic splenectomy; LS: Laparoscopic splenectomy.

## ARTICLE HIGHLIGHTS

### Research background

Hand-assisted laparoscopic splenectomy (HALS) can help overcome the drawbacks of laparoscopic splenectomy (LS) while maintaining its advantages, but it has not been widely accepted.

### Research motivation

To compare the advantages and disadvantages of HALS and LS.

### Research objectives

This study evaluated the efficacy and advantages of HALS for splenomegaly.

### Research methods

The relevant literature was reviewed using the PubMed, EMBASE, Cochrane, Ovid Medline, and Wanfang databases to compare the clinical outcomes of HALS and LS. Odds ratios or mean differences were calculated with 95% confidence intervals for fixed-effects and random-effects models.

### Research results

In pure splenectomy, blood loss volume and conversion rate were significantly lower in the HALS group than in the LS group. Conversely, for splenomegaly, the operative time was significantly shorter and blood loss volume and conversion rate were significantly lower in the HALS group than in the LS group. However, no significant difference was observed in hospital stay length, blood transfusion, time to food intake, complications, or mortality rate between the two groups. In addition, in splenectomy and devascularization of the upper stomach (DUS), the operative time was significantly shorter and blood loss volume and conversion rate were significantly lower in the HALS + DUS group than in the LS + DUS group. However, no significant difference was observed in hospital stay length, time to food intake, or complications between the two groups.

### Research conclusions

HALS is an ideal surgical treatment for splenomegaly because it can maximize the benefits for patients while maintaining the advantages of LS.

### Research perspectives

Definite protocol or guidelines should be established using reliable studies with good design. In the future, a well-designed prospective randomized study or multicenter cohort study is mandatory to elucidate the safety and feasibility of HALS.

## REFERENCES

- 1 Xu W, Liu P, Mu YP. Research progress on signaling pathways in cirrhotic portal hypertension. *World J Clin Cases* 2018; **6**: 335-343 [PMID: 30283796 DOI: 10.12998/wjcc.v6.i10.335]
- 2 Su MH, Lu AL, Li SH, Zhong SH, Wang BJ, Wu XL, Mo YY, Liang P, Liu ZH, Xie R, He LX, Fu WD, Jiang JN. Long-term lamivudine for chronic hepatitis B and cirrhosis: A real-life cohort study. *World J Gastroenterol* 2015; **21**: 13087-13094 [PMID: 26673249 DOI: 10.3748/wjg.v21.i46.13087]
- 3 Ioannou GN. Chronic hepatitis B infection: a global disease requiring global strategies. *Hepatology* 2013; **58**: 839-843 [PMID: 23703788 DOI: 10.1002/hep.26516]
- 4 Jiang X, Gao F, Ma Y, Feng S, Liu X, Zhou H. Percutaneous Microwave Ablation in the Spleen for Treatment of Hypersplenism in Cirrhosis Patients. *Dig Dis Sci* 2016; **61**: 287-292 [PMID: 26031423 DOI: 10.1007/s10620-015-3732-7]
- 5 Jensen DM. Endoscopic screening for varices in cirrhosis: findings, implications, and outcomes. *Gastroenterology* 2002; **122**: 1620-1630 [PMID: 12016427 DOI: 10.1053/gast.2002.33419]
- 6 Zhan XL, Ji Y, Wang YD. Laparoscopic splenectomy for hypersplenism secondary to liver cirrhosis and portal hypertension. *World J Gastroenterol* 2014; **20**: 5794-5800 [PMID: 24914339 DOI: 10.3748/wjg.v20.i19.5794]
- 7 Habermalz B, Sauerland S, Decker G, Delaitre B, Gigot JF, Leandros E, Lechner K, Rhodes M, Silecchia G, Szold A, Targarona E, Torelli P, Neugebauer E. Laparoscopic splenectomy: the clinical practice guidelines of the European Association for Endoscopic Surgery (EAES). *Surg Endosc* 2008; **22**: 821-848 [PMID: 18293036 DOI: 10.1007/s00464-007-9735-5]
- 8 Knauer EM, Ailawadi G, Yahanda A, Obermeyer RJ, Millie MP, Ojeda H, Mulholland MW, Colletti L, Sweeney JF. 101 laparoscopic splenectomies for the treatment of benign and malignant hematologic disorders. *Am J Surg* 2003; **186**: 500-504 [PMID: 14599614 DOI: 10.1016/j.amjsurg.2003.07.026]
- 9 Owers A, Hamade AM, Bani Hani OI, Ammori BJ. Laparoscopic versus open splenectomy for massive splenomegaly: a comparative study. *J Laparoendosc Adv Surg Tech A* 2006; **16**: 241-246 [PMID: 16544444 DOI: 10.1007/s10063-006-9044-4]



- 16796432 DOI: [10.1089/lap.2006.16.241](https://doi.org/10.1089/lap.2006.16.241)]
- 10 **Meijer DW**, Gossot D, Jakimowicz JJ, De Wit LT, Bannenberg JJ, Gouma DJ. Splenectomy revised: manually assisted splenectomy with the dexterity device--a feasibility study in 22 patients. *J Laparoendosc Adv Surg Tech A* 1999; **9**: 507-510 [PMID: [10632513](https://pubmed.ncbi.nlm.nih.gov/10632513/) DOI: [10.1089/lap.1999.9.507](https://doi.org/10.1089/lap.1999.9.507)]
  - 11 **Targarona EM**, Balague C, Cerdán G, Espert JJ, Lacy AM, Visa J, Trias M. Hand-assisted laparoscopic splenectomy (HALS) in cases of splenomegaly: a comparison analysis with conventional laparoscopic splenectomy. *Surg Endosc* 2002; **16**: 426-430 [PMID: [11928021](https://pubmed.ncbi.nlm.nih.gov/11928021/) DOI: [10.1007/s00464-001-8104-z](https://doi.org/10.1007/s00464-001-8104-z)]
  - 12 **Terroso G**, Donini A, Baccarani U, Vianello V, Anania G, Zala F, Pasqualucci A, Bresadola F. Laparoscopic versus open splenectomy in the management of splenomegaly: our preliminary experience. *Surgery* 1998; **124**: 839-843 [PMID: [9823396](https://pubmed.ncbi.nlm.nih.gov/9823396/) DOI: [10.1016/S0039-6060\(98\)70006-6](https://doi.org/10.1016/S0039-6060(98)70006-6)]
  - 13 **Targarona EM**, Espert JJ, Balagué C, Piulachs J, Artigas V, Trias M. Splenomegaly should not be considered a contraindication for laparoscopic splenectomy. *Ann Surg* 1998; **228**: 35-39 [PMID: [9671064](https://pubmed.ncbi.nlm.nih.gov/9671064/) DOI: [10.1097/0000658-199807000-00006](https://doi.org/10.1097/0000658-199807000-00006)]
  - 14 **Wang X**, Li Y, Zhou J, Wu Z, Peng B. Hand-assisted laparoscopic splenectomy is a better choice for patients with supramassive splenomegaly due to liver cirrhosis. *J Laparoendosc Adv Surg Tech A* 2012; **22**: 962-967 [PMID: [23067068](https://pubmed.ncbi.nlm.nih.gov/23067068/) DOI: [10.1089/lap.2012.0237](https://doi.org/10.1089/lap.2012.0237)]
  - 15 **Grahn SW**, Alvarez J, Kirkwood K. Trends in laparoscopic splenectomy for massive splenomegaly. *Arch Surg* 2006; **141**: 755-761; discussion 761-762 [PMID: [16924082](https://pubmed.ncbi.nlm.nih.gov/16924082/) DOI: [10.1001/archsurg.141.8.755](https://doi.org/10.1001/archsurg.141.8.755)]
  - 16 **Qian D**, He Z, Hua J, Gong J, Lin S, Song Z. Hand-assisted versus conventional laparoscopic splenectomy: a systematic review and meta-analysis. *ANZ J Surg* 2014; **84**: 915-920 [PMID: [24712437](https://pubmed.ncbi.nlm.nih.gov/24712437/) DOI: [10.1111/ans.12597](https://doi.org/10.1111/ans.12597)]
  - 17 **Cota GF**, de Sousa MR, Fereguetti TO, Rabello A. Efficacy of anti-leishmania therapy in visceral leishmaniasis among HIV infected patients: a systematic review with indirect comparison. *PLoS Negl Trop Dis* 2013; **7**: e2195 [PMID: [23658850](https://pubmed.ncbi.nlm.nih.gov/23658850/) DOI: [10.1371/journal.pntd.0002195](https://doi.org/10.1371/journal.pntd.0002195)]
  - 18 **Hozo SP**, Djulbegovic B, Hozo I. Estimating the mean and variance from the median, range, and the size of a sample. *BMC Med Res Methodol* 2005; **5**: 13 [PMID: [15840177](https://pubmed.ncbi.nlm.nih.gov/15840177/) DOI: [10.1186/1471-2288-5-13](https://doi.org/10.1186/1471-2288-5-13)]
  - 19 **Feng Q**, Huang Y, Wang K, Yuan R, Xiong X, Wu L. Laparoscopic Transeystic Common Bile Duct Exploration: Advantages over Laparoscopic Choledochotomy. *PLoS One* 2016; **11**: e0162885 [PMID: [27668730](https://pubmed.ncbi.nlm.nih.gov/27668730/) DOI: [10.1371/journal.pone.0162885](https://doi.org/10.1371/journal.pone.0162885)]
  - 20 **Ailawadi G**, Yahanda A, Dimick JB, Bedi A, Mulholland MW, Colletti L, Sweeney JF. Hand-assisted laparoscopic splenectomy in patients with splenomegaly or prior upper abdominal operation. *Surgery* 2002; **132**: 689-94; discussion 694-6 [PMID: [12407354](https://pubmed.ncbi.nlm.nih.gov/12407354/) DOI: [10.1067/msy.2002.127686](https://doi.org/10.1067/msy.2002.127686)]
  - 21 **Kercher KW**, Matthews BD, Walsh RM, Sing RF, Backus CL, Heniford BT. Laparoscopic splenectomy for massive splenomegaly. *Am J Surg* 2002; **183**: 192-196 [PMID: [11918887](https://pubmed.ncbi.nlm.nih.gov/11918887/) DOI: [10.1016/S0002-9610\(01\)00874-1](https://doi.org/10.1016/S0002-9610(01)00874-1)]
  - 22 **Rosen M**, Brody F, Walsh RM, Ponsky J. Hand-assisted laparoscopic splenectomy vs conventional laparoscopic splenectomy in cases of splenomegaly. *Arch Surg* 2002; **137**: 1348-1352 [PMID: [12470097](https://pubmed.ncbi.nlm.nih.gov/12470097/) DOI: [10.1001/archsurg.137.12.1348](https://doi.org/10.1001/archsurg.137.12.1348)]
  - 23 **Smith L**, Luna G, Merg AR, McNevin MS, Moore MR, Bax TW. Laparoscopic splenectomy for treatment of splenomegaly. *Am J Surg* 2004; **187**: 618-620 [PMID: [15135677](https://pubmed.ncbi.nlm.nih.gov/15135677/) DOI: [10.1016/j.amjsurg.2004.01.016](https://doi.org/10.1016/j.amjsurg.2004.01.016)]
  - 24 **Wang KX**, Hu SY, Zhang GY, Chen B, Zhang HF. Hand-assisted laparoscopic splenectomy for splenomegaly: a comparative study with conventional laparoscopic splenectomy. *Chin Med J (Engl)* 2007; **120**: 41-45 [PMID: [17254486](https://pubmed.ncbi.nlm.nih.gov/17254486/)]
  - 25 **Reso A**, Brar MS, Church N, Mitchell P, Dixon E, Debru E. Outcome of laparoscopic splenectomy with preoperative splenic artery embolization for massive splenomegaly. *Surg Endosc* 2010; **24**: 2008-2012 [PMID: [20419317](https://pubmed.ncbi.nlm.nih.gov/20419317/) DOI: [10.1007/s00464-010-0896-2](https://doi.org/10.1007/s00464-010-0896-2)]
  - 26 **Pietrabissa A**, Morelli L, Peri A, Pugliese L, Zonta S, Dionigi P, Mosca F. Laparoscopic treatment of splenomegaly: a case for hand-assisted laparoscopic surgery. *Arch Surg* 2011; **146**: 818-823 [PMID: [21768428](https://pubmed.ncbi.nlm.nih.gov/21768428/) DOI: [10.1001/archsurg.2011.149](https://doi.org/10.1001/archsurg.2011.149)]
  - 27 **Altamirano AM**, Ellsmere J, Jaap Bonjer H, El-Ghazaly TH, Klassen DR. Morbidity of hand-assisted laparoscopic splenectomy compared to conventional laparoscopic splenectomy: a 6-year review. *Can J Surg* 2012; **55**: 227-232 [PMID: [22617537](https://pubmed.ncbi.nlm.nih.gov/22617537/) DOI: [10.1503/cjs.028910](https://doi.org/10.1503/cjs.028910)]
  - 28 **Wang X**, Li Y, Peng B. Hand-assisted laparoscopic technique in the setting of complicated splenectomy: a 9-year experience. *World J Surg* 2013; **37**: 2046-2052 [PMID: [23756773](https://pubmed.ncbi.nlm.nih.gov/23756773/) DOI: [10.1007/s00268-013-2114-6](https://doi.org/10.1007/s00268-013-2114-6)]
  - 29 **Ando K**, Kurokawa T, Nagata H, Arikawa T, Yasuda A, Ito N, Kotake K, Nonami T. Laparoscopic surgery in the management of hypersplenism and esophagogastric varices: our initial experiences. *Surg Innov* 2012; **19**: 421-427 [PMID: [22298753](https://pubmed.ncbi.nlm.nih.gov/22298753/) DOI: [10.1177/1553350611432724](https://doi.org/10.1177/1553350611432724)]
  - 30 **Li E**, Wu Z, Liu H, Li Z, Chen K, Zhang Z, Zhang R, Zeng H. A comparative study of hand-assisted laparoscopic versus total laparoscopic splenectomy plus portal-azygous disconnection for portal hypertension in liver cirrhosis. *Lingnan Xiandai Linchuang Waik* 2013; **13**: 489-492 [DOI: [10.3969/j.issn.1009-976X.2013.06.005](https://doi.org/10.3969/j.issn.1009-976X.2013.06.005)]
  - 31 **Yu H**, Chen H, Chen L, Jin X. A comparative study on the clinical efficacy of splenectomy plus porta-azygous devascularization in the treatment of portal hypertension using either the hand-assisted or the laparoscopic approaches. *Zhonghua Gandan Waik* 2013; **19**: 370-372 [DOI: [10.3760/cma.j.issn.1007-8118.2013.05.015](https://doi.org/10.3760/cma.j.issn.1007-8118.2013.05.015)]
  - 32 **Akahoshi T**, Uehara H, Tomikawa M, Kawanaka H, Hashizume M, Maehara Y. Comparison of open, laparoscopic, and hand-assisted laparoscopic devascularization of the upper stomach and splenectomy for treatment of esophageal and gastric varices: a single-center experience. *Asian J Endosc Surg* 2014; **7**: 138-144 [PMID: [24571442](https://pubmed.ncbi.nlm.nih.gov/24571442/) DOI: [10.1111/ases.12096](https://doi.org/10.1111/ases.12096)]
  - 33 **Li Q**, Wang C, Gong W, Li G. Clinical Comparative Effect of Laparoscopic Splenectomy Plus Hand-assisted Laparoscopic Splenectomy Plus Pericardial Devascularization. *Zhongguo Yiyao Daobao* 2016; **18**: 1006-1010
  - 34 **Kusminsky RE**, Boland JP, Tiley EH, Deluca JA. Hand-assisted laparoscopic splenectomy. *Surg Laparosc Endosc* 1995; **5**: 463-467 [PMID: [8611994](https://pubmed.ncbi.nlm.nih.gov/8611994/)]
  - 35 **Winslow ER**, Brunt LM. Perioperative outcomes of laparoscopic versus open splenectomy: a meta-analysis with an emphasis on complications. *Surgery* 2003; **134**: 647-653; discussion 654-655 [PMID: [14605626](https://pubmed.ncbi.nlm.nih.gov/14605626/) DOI: [10.1016/S0039-6060\(03\)00312-X](https://doi.org/10.1016/S0039-6060(03)00312-X)]
  - 36 **Kaban GK**, Czerniach DR, Litwin DE, Litwin DE. Hand-assisted laparoscopic surgery. *Surg Technol Int* 2003; **11**: 63-70 [PMID: [12931285](https://pubmed.ncbi.nlm.nih.gov/12931285/)]
  - 37 **Litwin DE**, Darzi A, Jakimowicz J, Kelly JJ, Arvidsson D, Hansen P, Callery MP, Denis R, Fowler DL,



- Medich DS, O'Reilly MJ, Atlas H, Himpens JM, Swanstrom LL, Arous EJ, Pattyn P, Yood SM, Ricciardi R, Sandor A, Meyers WC. Hand-assisted laparoscopic surgery (HALS) with the HandPort system: initial experience with 68 patients. *Ann Surg* 2000; **231**: 715-723 [PMID: [10767793](#) DOI: [10.1097/0000658-200005000-00012](#)]
- 38 **Gong J**, Cao Y, Li Y, Zhang G, Wang P, Luo G. Hand-assisted laparoscopic versus laparoscopy-assisted D2 radical gastrectomy: a prospective study. *Surg Endosc* 2014; **28**: 2998-3006 [PMID: [24879135](#) DOI: [10.1007/s00464-014-3566-y](#)]
- 39 **Wang ZQ**. Application and indication choice of hand-assisted laparoscopic operation in gastrointestinal surgery. *Zhonghua Weichang Waikao Zazhi* 2012; **15**: 796-798 [PMID: [23072019](#)]
- 40 **Klingler PJ**, Hinder RA, Menke DM, Smith SL. Hand-assisted laparoscopic distal pancreatectomy for pancreatic cystadenoma. *Surg Laparosc Endosc* 1998; **8**: 180-184 [PMID: [9649039](#) DOI: [10.1097/00019509-199806000-00003](#)]
- 41 **Shinchi H**, Takao S, Noma H, Mataka Y, Iino S, Aikou T. Hand-assisted laparoscopic distal pancreatectomy with minilaparotomy for distal pancreatic cystadenoma. *Surg Laparosc Endosc Percutan Tech* 2001; **11**: 139-143 [PMID: [11330382](#) DOI: [10.1097/00129689-200104000-00016](#)]
- 42 **Kercher KW**, Joels CS, Matthews BD, Lincourt AE, Smith TI, Heniford BT. Hand-assisted surgery improves outcomes for laparoscopic nephrectomy. *Am Surg* 2003; **69**: 1061-1066 [PMID: [14700291](#)]
- 43 **Tanaka M**, Tokuda N, Koga H, Yokomizo A, Sakamoto N, Naito S. Hand assisted laparoscopic radical nephrectomy for renal carcinoma using a new abdominal wall sealing device. *J Urol* 2000; **164**: 314-318 [PMID: [10893573](#) DOI: [10.1016/S0022-5347\(05\)67348-X](#)]
- 44 **Fong Y**, Jarnagin W, Conlon KC, DeMatteo R, Dougherty E, Blumgart LH. Hand-assisted laparoscopic liver resection: lessons from an initial experience. *Arch Surg* 2000; **135**: 854-859 [PMID: [10896382](#) DOI: [10.1001/archsurg.135.7.854](#)]
- 45 **Salit Y**, Bitterman A, Lefel O, Eisenberg D, Eden A, Barzelai M, Steiner M, Zuckerman E, Haddad R. Hand-assisted laparoscopic surgery for liver tumors. *Isr Med Assoc J* 2010; **12**: 424-427 [PMID: [20862824](#)]

**P- Reviewer:** Misiakos EP, Solaini L

**S- Editor:** Cui LJ **L- Editor:** Wang TQ **E- Editor:** Song H





Published By Baishideng Publishing Group Inc  
7901 Stoneridge Drive, Suite 501, Pleasanton, CA 94588, USA  
Telephone: +1-925-2238242  
Fax: +1-925-2238243  
E-mail: [bpgoffice@wjgnet.com](mailto:bpgoffice@wjgnet.com)  
Help Desk: <https://www.f6publishing.com/helpdesk>  
<https://www.wjgnet.com>

