

## Keratoconus therapeutics advances

Martha Jaimes, Arturo Ramirez-Miranda, Enrique O Graue-Hernández, Alejandro Navas

Martha Jaimes, Arturo Ramirez-Miranda, Enrique O Graue-Hernández, Alejandro Navas, Department of Cornea and Refractive Surgery, Institute of Ophthalmology "Conde de Valenciana", 06800 Mexico City, Mexico

**Author contributions:** All the authors fulfill the Vancouver definition of authorship; Jaimes M and Navas A contributed to conception and design, drafting the article and final approved of the version to be published; Ramirez-Miranda A and Graue-Hernández EO contributed to acquisition of data, revising the article for important intellectual content and final approved of the version to be published.

**Correspondence to:** Alejandro Navas, MD, MSc, Department of Cornea and Refractive Surgery, Institute of Ophthalmology "Conde de Valenciana", Chimalpopoca 14, Col Obrera, 06800 Mexico City, Mexico. [dr.alejandro.navas@gmail.com](mailto:dr.alejandro.navas@gmail.com)

Telephone: +52-55-54421700 Fax: +52-55- 55789748

Received: June 29, 2013 Revised: August 10, 2013

Accepted: August 11, 2013

Published online: August 12, 2013

intraocular lens implant, phakic intraocular lenses and the combination of these alternatives. Some authors have been using excimer laser in patients with keratoconus but the safety of the procedure is controversial. Currently, the techniques for the management of keratoconus can be classified in 3 types: corneal strengthening techniques, optical optimization techniques and combined techniques.

© 2013 Baishideng. All rights reserved.

**Key words:** Keratoconus; Treatment; Management; Corneal ectasia; Therapeutics

**Core tip:** There are several treatment options for the current management of keratoconus patients. These alternatives are increasing and better outcomes could be obtained. The purpose of this review is to summarize the therapeutics advances in keratoconus.

### Abstract

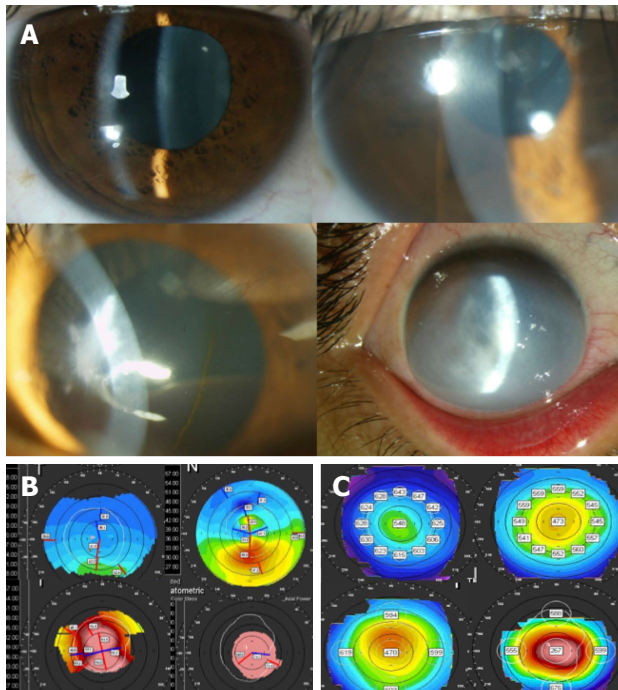
Keratoconus is a progressive, usually bilateral disease of the cornea that significantly diminishes visual acuity, secondary to a progressive corneal deformity which is characterized by corneal thinning, variable degrees of irregular astigmatism and specific abnormal topographic patterns. Normally it initiates during puberty and is progressive until the third or fourth decade of life, when normally the progression rate is diminished or waned. There are multiple scales to clinically classify keratoconus. One of the most commonly used is Amsler-Krumeich and recently with the development of morphometric and aberrometric techniques, additional scales have been created that allow keratoconus to be classified according to its severity. Despite certain etiology of keratoconus remains unknown, current treatment options are available in patients with ectatic corneas and they vary depending on the severity of the disease and they include spectacles, contact lenses, intrastromal rings, keratoplasty both penetrant or lamellar, cross-linking, refractive lens exchange with

Jaimes M, Ramirez-Miranda A, Graue-Hernández EO, Navas A. Keratoconus therapeutics advances. *World J Ophthalmol* 2013; 3(3): 20-31 Available from: URL: <http://www.wjgnet.com/2218-6239/full/v3/i3/20.htm> DOI: <http://dx.doi.org/10.5318/wjo.v3.i3.20>

### INTRODUCTION

Keratoconus is a corneal ectasia that significantly diminishes visual acuity, secondary to a progressive corneal deformity which is characterized by corneal thinning, variable degrees of irregular astigmatism and specific abnormal patterns (Figure 1) of corneal elevation<sup>[1]</sup>.

It has an approximate incidence, which varies between 50 to 230 cases in 100000 inhabitants in general population (1:2000). The estimated prevalence is of 54.5:100000 inhabitants. Normally it initiates during puberty and is progressive until the third or fourth decade of life, when normally the progression rate is diminished or waned<sup>[2]</sup>.



**Figure 1 Keratoconus clinical and topographic variation examples.** A: Several clinical presentations and severity of keratoconus cases; B: Different keratometric stages of keratoconus; C: Pachymetric maps showing different grades of KC cases.

There are multiple scales to clinically classify keratoconus. One of the most commonly used is Amsler-Krumeich<sup>[3]</sup> (Table 1) and recently with the development of morphometric and aberrometric techniques, additional scales have been created that allow keratoconus to be classified according to its severity<sup>[4]</sup> (Table 2).

Currently, the techniques for the management of keratoconus can be classified in 3 types: corneal strengthening techniques, optical optimization techniques and combined techniques<sup>[5]</sup>.

Among the strengthening techniques are: corneal collagen cross-linking and placement of intrastromal rings segments (which also have a refractive effect). The optical optimization techniques include the use of spectacles, rigid, soft or optimized contact lenses; excimer laser, lamellar or penetrating keratoplasty (which also have a strengthening effect), phakic lenses and pseudophakic lenses.

The combined procedures are those that are utilized in a sequential manner to obtain optical and refractive results and they include a wide array of possible combinations of the procedures previously described to obtain these objectives (Figure 2).

One of the main criteria to consider the more suitable technique or treatment for our patient is refraction, age, the thinning degree and the irregular astigmatism. If it is possible to obtain a correct subjective and objective refraction and the patient shows an improvement in their visual acuity with optical correction, then the options of treatment will have as an objective to correct the refrac-

**Table 1 Clinical classification of keratoconus<sup>[3]</sup>**

Stage	Characteristics
Stage I	Eccentric bulging Induced myopia and/or astigmatism of 5 D Average central keratometry of 48 D
Stage II	Induced myopia and/or astigmatism of 5 to 8 D Average central keratometry > 48 D but < 53 D Absent scarring Minimum corneal thickness of 400 microns
Stage III	Induced myopia and/or astigmatism of 8 to 10 D Average central keratometry > 53 D Absent scarring Central corneal thickness of 300 to 400 microns
Stage IV	Invaluable refraction Average central keratometry > 55 D Central corneal scar Corneal thickness < 200 microns

tive error more so than to stabilize the keratoconus. According to this, we present an algorithm suggested for decision making in respect to surgical criteria in patients with keratoconus (Figure 3). Evidently, every patient needs to be individualized.

## SPECTACLES

These represent the best option for treatment of fruste keratoconus and keratoconus with small irregular astigmatism that are refractable and have a visual capacity > 20/40 or do not wish surgery to treat the ectasia or the slight ametropia. The recommendation in these cases is to have topographic follow ups every 6 mo to evaluate progression.


## CONTACT LENSES

Contact lenses are treatment of choice for 90% of the patients with keratoconus. The degree of keratoconus influences the selection of the type of contact lens and also many of the patients that have been treated with penetrating keratoplasty use contact lenses<sup>[6]</sup>.

The most commonly used contact lens design in patients with keratoconus is the unique base curve in rigid gas permeable material. Lenses with multiple base curves can also be used. In patients with highly advanced keratoconus, hybrid or scleral lenses have been used<sup>[6]</sup>.

In recent studies, it's been identified that 79% of patients with keratoconus use contact lenses; of which, 21.3% have already had at least one penetrating keratoplasty. Sixty-seven point seven percent of the patients use the hybrid gas permeable lens, 13% soft contact lens, 4.2% scleral gas permeable lens and 15.1% use other types of contact lenses<sup>[7]</sup>.

Presently, new personalized lens models have been designed for the treatment of keratoconus for those with intolerance of the conventional contact lens. Examples of these include the PROSE lens (Prosthetic replacement



**Figure 2 Combined procedures.** A: Combination of intrastromal ring segments and pseudophakic toric intraocular lens; B: Pseudophakic plate toric intraocular lens following penetrating keratoplasty.

**Table 2 Paraclinic criteria for diagnosis of keratoconus<sup>[4]</sup>**

Criteria	Values in keratoconus
Curvature	> 46 to 47 D
Asymmetry I-S	> 1.4 D
Irregularity	> 20 or 30 degrees with respect to the vertical meridian
Keratometric difference between the 2 eyes	> 1 D
Anterior elevation	< 15 m in Placido rings images and < 12 m in Scheimpflug images
Posterior elevation	< 35 m in Placido rings images and < 18 m in Scheimpflug images
Pachymetry	Thinnest, decentered point, difference of 100 m between center and periphery
Aphericity (Q)	Between -0.5 and < -1
Eccentricity	Approaching 1
Form factor	Approaching 0
Corneal irregularity	> 1.1-5
Medium toric keratometry	47.3-60 D
Surface irregularity index	> 1.55
Predicted corneal acuity (Holladay Report)	> 0
Keratoconus index (Maeda)	> 0
Keratoconus % index	> 100
Keratoconus prediction index	> 0.38
Surface variation index	> 41
Vertical asymmetry index	0.32
Keratoconus index	> 1.07
Central keratoconus index	> 1.03
Smallest curvature radius	> 6.71
Largest asymmetry index	> 21
Height decentration index	> 0.016
Aberration coefficient	> 1
Aberration	Vertical Coma and Coma-like RMS (> 1.5 m)
Corneal volume analysis	> 57.98 ± 2.65 mm <sup>3</sup>
Corneal hysteresis	> 9.64 mmHg
Corneal resistance factor	> 9.6 mmHg

of the ocular surface ecosystem; BFS, Needham, MA); a device manufactured from a gas permeable polymer of fluorosilicone-acrylate with a Dk index of  $85 \times 10^{-12}$  mL O<sub>2</sub>/s mL mmHg, which currently has reported 88% use success with 93% of the patients with AV > 20/40<sup>[8]</sup>.

The SynergEyes lens (SynergEyes, Inc, Carsbd, CA) is a third generation hybrid lens with a rigid gas permeable center and a “skirt” of hydrophilic material; it has the highest coefficient of oxygen diffusion of previous generations.

The use of these lenses is associated with a corrected distance visual acuity (CDVA) improvement of 85.2% of the keratoconus cases treated and a usage success rate of 86.9% of the keratoconus cases in which it was fitted<sup>[9]</sup>.

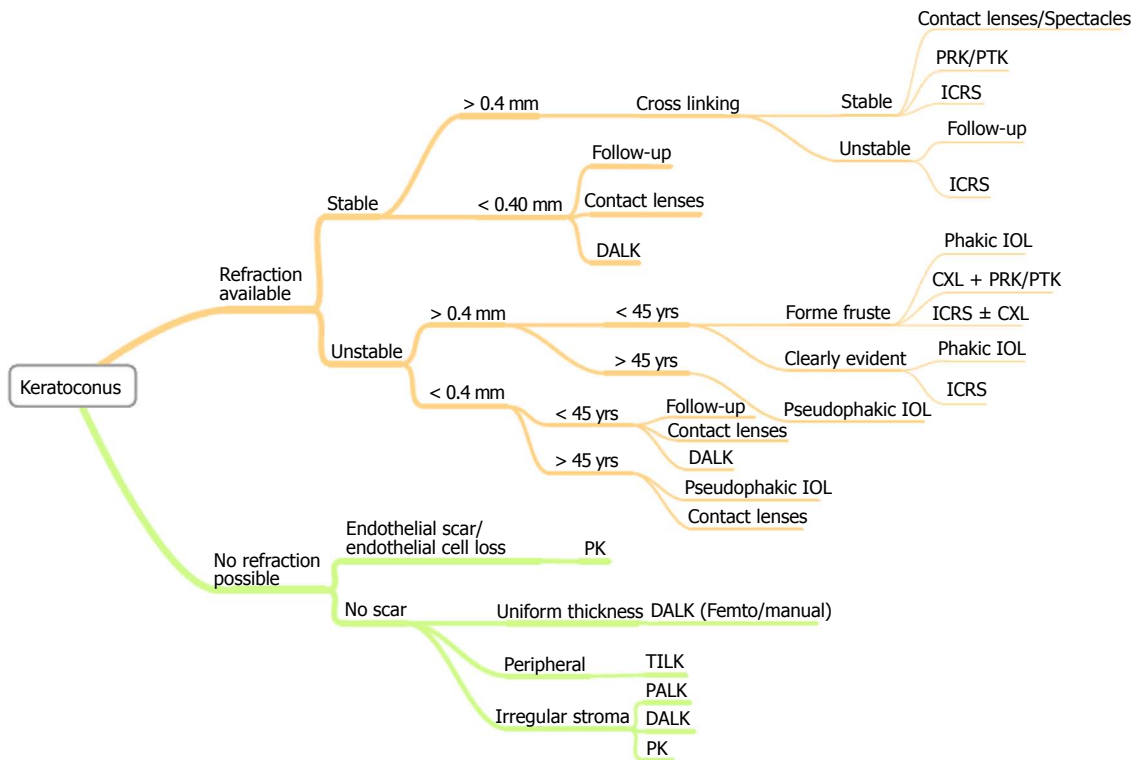
Another lens design is the personalized rigid gas permeable lens (Rose K Lens, Con-Cise Contact Lens Company, San Leandro, CA), with a 76% success rate in lens fitting<sup>[10]</sup> and aberrometry guided scleral lens fitting, which recently have been tested for the treatment of high order aberrations in keratoconus. These lenses have proven to be effective in the correction of corneal aberrations such as vertical coma and secondary astigmatism, achieving an CDVA of 20/30 in average and corneal aberrations compatible with a corneal pattern of healthy population and low reduction of contrast sensitivity compared to conventional rigid gas permeable contact lenses<sup>[11]</sup>.

## PHAKIC INTRAOCULAR LENSES

From 2003 to date, there have been increasing reports published of the use of phakic lenses as a sole or sequential procedure for the treatment of stable keratoconus. One of the firsts reports in literature was made by Lec-cisotti *et al.*<sup>[12]</sup>, when he reports for the first time the use of an anterior chamber phakic lens with angular support for the treatment of keratoconus. Following this, multiple studies with different types of phakic lenses (anterior and posterior chamber, toric and spherical) have been employed for the treatment of keratoconus and even for the management of residual ametropia following penetrating keratoplasty<sup>[13]</sup>.

The safety, efficacy and predictability indexes of all of the studies have demonstrated to be very suitable in cases in which the patient has been selected appropriately, in particular, adequately identifying progression and refractability; and given the case where the keratoconus is not stable, it is useful to utilize strengthening techniques such as cross-linking and placement of intrastromal rings in a simultaneous or sequential manner (Table 3).

The current criteria for the placement of a phakic lens in keratoconus takes into account a stable keratoconus, correctable refractive error due to the types of phakic lenses available, endothelial count greater than 2500 cel/mm<sup>2</sup>, anterior chamber depth > 2.8 mm in cases of



**Figure 3 Proposed algorithm for keratoconus treatment.** PRK: Photorefractive keratectomy; PTK: Phototherapeutic keratectomy; ICRS: Intrastromal corneal ring segments; DALK: Deep anterior lamellar keratoplasty; CXL: Corneal collagen cross-linking; IOL: Intraocular lenses; PK: Penetrating keratoplasty; TILK: "Tuck-In" lamellar keratoplasty; PALK: DALK assisted by pachymetry.

posterior chamber lenses (Figure 4), absence of uveal pathology or glaucoma.

## PSEUDOPHAKIC INTRAOCULAR LENSES

The current trend for management of large ametropias in patients over 45 years old with keratoconus is the use of replacement of the crystalline lens with pseudophakic<sup>[26]</sup> intraocular lenses (Figure 5). These options are considered specifically in this age group given the tendency for arrested progression of the keratoconus starting the fourth decade of life<sup>[27]</sup>.

Previous reports have been published by our group in 2011<sup>[28]</sup> about this treatment option. Our experience consists of the treatment of 19 eyes of patients with keratoconus which underwent refractive lens exchange for the correction of ametropia of the compound myopic astigmatism type in stable keratoconus. The preoperative and postoperative sphere was of  $-5.25 \pm 6.4$  D and  $0.22 \pm 1.01$  D respectively. The preoperative and postoperative cylinder was of  $-3.95 \pm 1.3$  and  $1.36 \pm 1.17$ , with preoperative spherical equivalent of  $-7.10 \pm 6.41$  D and postoperatively of  $-0.46 \pm 1.12$  D. The preoperative UDVA was  $1.35 \pm 0.36$  (logMAR) and postoperative of  $0.29 \pm 0.23$  (logMAR). The procedure was safe, predictable, effective and subjectively gratifying for all of the patients<sup>[28]</sup>.

Recently, Nanavaty *et al*<sup>[29]</sup> reported a series of 12 cases of keratoconus patients treated with a plate toric pseu-

dophakic lens implant for the management of ametropia. Their results report a UDVA of 20/40 or better in 75% of the patients and CDVA of 20/40 or better in 83.3% of the treated cases. The preoperative sphere of  $-4.8 \pm 5.6$  D was reduced to  $0.3 \pm 0.5$  D and the cylinder decreased from  $3 \pm 1$  D to  $0.7 \pm 0.8$  D. None of the cases reported in both series had keratoconus progression<sup>[29]</sup>.

There are also a few reports of combined intraocular lens treatment (piggyback) for the management of residual ametropia in keratoconus patients who underwent cataract surgery either at the same time or considering sequential implant<sup>[30]</sup>.

The great advantage of this technique over the others is that it allows for the appropriate ametropia correction, caused by the keratoconus, to be made in just one procedure without the need of additional treatments and, with current techniques such as biometry through interferometry and corneal topography/tomography, the lens calculation tends to be more accurate every time<sup>[28]</sup>.

## CORNEAL COLLAGEN CROSS-LINKING

The collagen crosslinking technique was first described in the 70's; however, it wasn't until 2003 that ultraviolet light A (370 nm) combined with riboflavin for the strengthening of the corneal collagen fibers in human eyes was used to stop keratoconus progression<sup>[31]</sup>.

Since then, numerous studies have been published

**Table 3** Phakic intraocular lenses for keratoconus studies

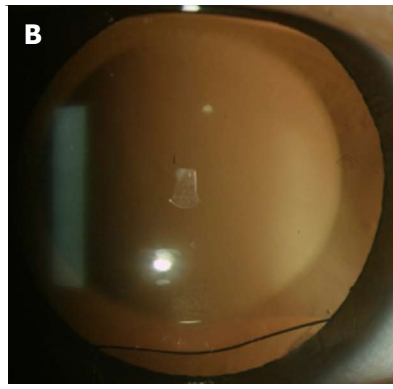
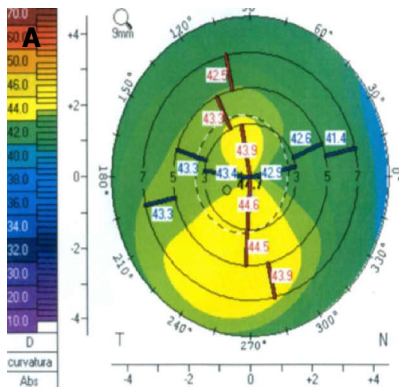
Ref.	Criteria	Lens	Preoperative	Postoperative	P-value
Leccisotti <i>et al</i> <sup>[12]</sup>	12 eyes. KC I y II	Angular supported, spherical	Sphere -10.23 ± 2.85 D Cyl -2.79 ± 1.11 D CDVA 0.13 ± 0.17	Sph 0.46 ± 0.45 D Cyl -2.35 ± 1 D UCVA 0.44 ± 0.8 CDVA 0.03 ± 0.05	0.002
Alfonso <i>et al</i> <sup>[14]</sup>	25 eyes	Posterior chamber, spherical	Sph -8.54 ± 4.15 D Cyl -1.24 ± 1.19 D CDVA 0.13 ± 0.15	Sph 0.0 ± 0.25 D Cyl -0.45 ± 0.73 D SE -0.32 ± 0.55 D UCVA 0.17 ± 0.19 CDVA 0.12±0.12	< 0.05
Venter <i>et al</i> <sup>[15]</sup>	18 eyes	Iris supported, toric/ spherical	Sph -4.64 ± 2.74 D Cyl -3.07 ± 2.04 D CDVA ≥0.5	SE -0.46 ± 0.6 D UDVA ≥ 0.2 en 94%	< 0.05
Alfonso <i>et al</i> <sup>[16]</sup>	30 eyes	Posterior chamber, toric	SE -5.38 ± 3.26 D Cyl -3.48 ± 1.24 D UDVA 0.8 logMar CDVA 0.10	SE -0.08 ± 0.37 D Cyl 0.41 ± 0.61 D UDVA 0.10 logMar CDVA 0.10	
Kamiya <i>et al</i> <sup>[17]</sup>	27 eyes, mild KC	Posterior chamber, toric	SE -10.11 ± 2.46 D Cyl -3.03 ± 1.58 D UCVA 1.51 ± 0.2 CDVA -0.11 ± 0.08	SE 0.00 ± 0.35 D UCVA -0.09 ± 0.16 CDVA -0.15 ± 0.09	
Sedaghat <i>et al</i> <sup>[18]</sup>	16 eyes,	Anterior chamber, iris supported	Sph -12.5 ± 4.61 D Cyl 2.95 ± 4.06 D SE -13.9 ± 4.61 D UDVA CF CDVA 0.21 ± 0.14	Sph -0.03±1.81 D Cyl 2.08 ± 1.04 D UDVA 0.15 ± 0.13 CDVA 0.11 ± 0.1	< 0.0001
Kato <i>et al</i> <sup>[19]</sup>	36 eyes	Iris supported, toric, spherical	SE -8.38 ± 3.42 D  Cyl 2.44 ± 2.25 D UDVA 1.39 ± 0.42	SE -0.42 ± 0.89 D  Cyl 0.62 ± 0.69 D UDVA 0.02 ± 0.21	
Hashemian <i>et al</i> <sup>[20]</sup>	22 eyes	ICL toric	SE -4.98 ± 2.63 D Cyl -2.77 ± 0.99 D UDVA 0.63 ± 0.2 dec.	SE -0.33 ± 0.51 D Cyl -1.23 ± 0.65 D UDVA 0.85 ± 0.21 dec.	
Combined procedures Moshirfar <i>et al</i> <sup>[21]</sup>	19 eyes	Intacs/verisyse, sequential vs simultaneous	SE -12.38 ± 4.2 D Cyl 3.3 ± 1.8 D UCVA 2.025 ± 0.32 CDVA 0.34 ± 0.22	SE -1.2 ± 1.15 D Cyl 2.06 ± 1.1 D UCVA 0.465 ± 0.18 CDVA 0.15 ± 0.09	No difference regarding sequential vs simultaneous
Izquierdo <i>et al</i> <sup>[22]</sup>	11 eyes Progressive KC I and II	Crosslinking/verisyse	Sph -5.7 D Cyl -1.45 D SE -6.42 D UDVA 1.4 ± 0.4 CDVA 0.14 ± 0.06	Sph -0.27 D Cyl -0.9 D SE -0.72 D UDVA 0.16 ± 0.06 CDVA 0.04 ± 0.05	< 0.05
Alfonso <i>et al</i> <sup>[23]</sup>	40 eyes	Keraring/ICL	SE -9.65 ± 6.9 D UDVA 1.0 CDVA 0.3	SE -1.2 ± 1.3 D UDVA 0.3 CDVA 0.18	
Güell <i>et al</i> <sup>[24]</sup>	17 eyes Progressive KC I and II	Crosslinking and toric artiflex/artisan	SE -6.99 ± 3.2 D Cyl -3.54 ± 1.38 D UDVA < 1 CDVA 0.1 ± 0.09	SE -0.22 ± 0.33 D Cyl -0.62 ± 0.39 D 0.17 ± 0.13 CDVA 0.10 ± 0.09	
Navas <i>et al</i> <sup>[25]</sup>	11 eyes KC I -IV	ICRS and toric and spherical ICL	Sph -9.04 ± 6.03 D Cyl -2.95 ± 1.35 D SE -10.52 ± 5.88 D UDVA 1.31 ± 0.37 CDVA 0.289 ± 0.14	Sph -0.06 ± 0.46 D Cyl -1.22 ± 0.65 D SE -0.68 ± 0.45 D UDVA 0.14 ± 0.04 CDVA 0.16 ± 0.08	< 0.01

CDVA: Corrected distance visual acuity; UDVA: Uncorrected distance visual acuity; ICRS: Intrastromal corneal ring segments.

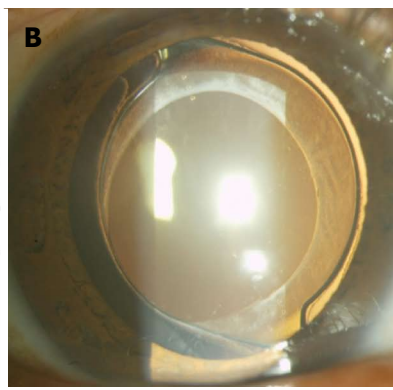
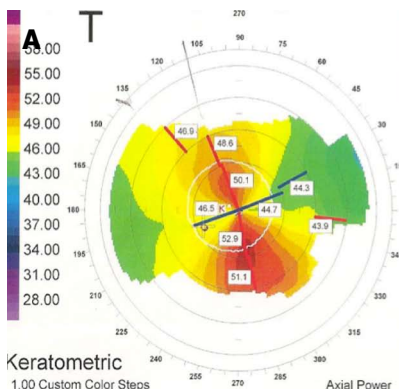
about the effect of UVA light on keratoconus. It is known that the more meaningful effects are the progression halt of the keratoconus and in some reports there's also mention of its regression on an average of 2 D (from 1 to 4)<sup>[32,33]</sup>.

At this moment, the long term effects of the imple-

mentation of this procedure are still unknown, with minimal or inexistent adverse effects being described in many of the cases with longer follow ups<sup>[32,33]</sup>. Some publications report a central haze, which tends to resolve itself with time, as the main complication and that it is more evident when performing a corneal<sup>[34]</sup> densitometry,



**Figure 4** Phakic toric intraocular lens implantation in (A) forme fruste keratoconus case, (B) notice the rhomboidal marks of the lens toricity axis.



**Figure 5** Pseudophakic toric intraocular lens in (A) frank keratoconus, (B) notice the three dot marks for toric intraocular lenses alignment.

remaining in up to 8.6%<sup>[35]</sup>. Up to now, in the majority of the studies done, no significant endothelial cell loss has been reported<sup>[36]</sup>, but recently it has been identified that the pre-operative corneal thickness > 400 microns is an important factor which determines the absence of CXL effects on the endothelium<sup>[37]</sup>. Through confocal microscopy it has been identified that during early phases of the scarring process some changes occurs such as a hyper-reflective phenomenon in the collagen fibers of the medial to posterior stroma<sup>[36]</sup>, as well as epithelial thinning, stromal edema and keratocytes apoptosis in the first 4 to 6 wk. Subsequently, an epithelial thickness and collagen compaction occurs<sup>[38]</sup>.

Today, the more widely accepted criteria to perform a corneal crosslinking include patients with topographic evidence of keratoconus progression, corneal thickness > 400 microns and keratoconus without deep stromal scarring or history of corneal hydrops. Numerous modifications have been developed to the technique, amongst which we have the transepithelial crosslinking and accelerated cross-linking (Figure 6) for the optimized effect on experimental models<sup>[39-41]</sup>.

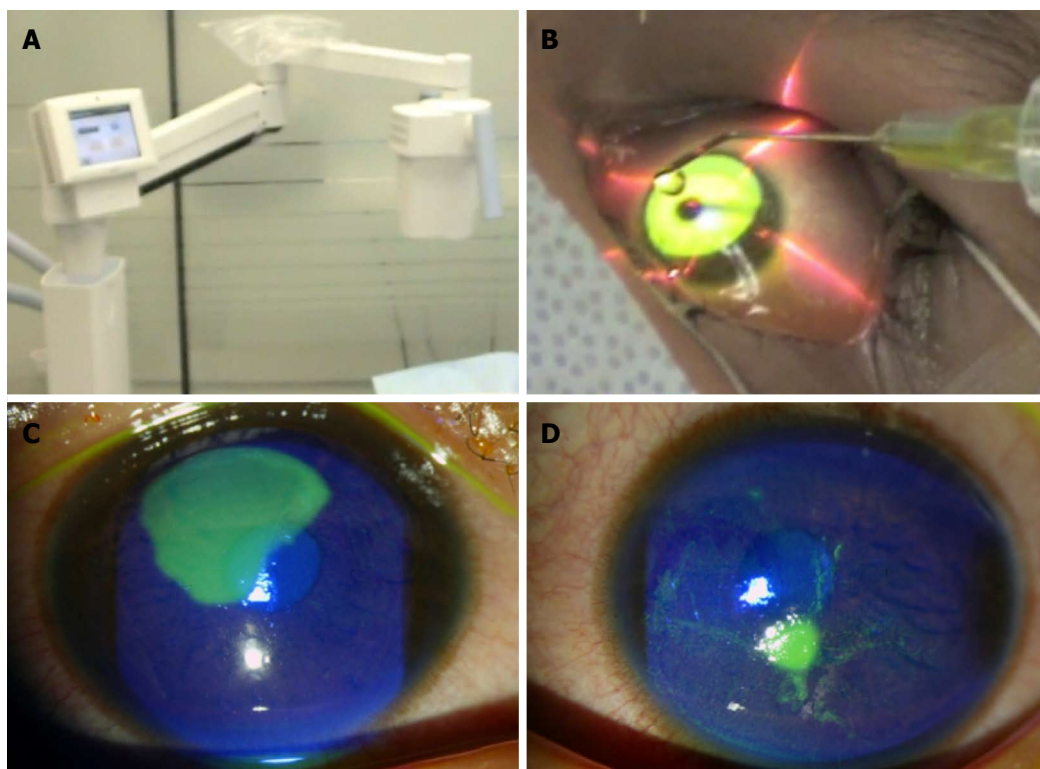
## EXCIMER LASER

Until a few years ago, the keratoconus or its fruste form was considered a total contraindication to keratorefractive surgery with excimer laser. Recently, these techniques have been utilized in the treatment of patients with fruste keratoconus or its mild forms with satisfactory visual results. Currently, there have been results of photorefrac-

tive keratectomy with and without being combined with crosslinking as an adjunctive treatment in the management of ametropia secondary to keratoconus.

The advantage of this technique is that it does not need the creation of an epithelial/stromal flap; this way, performing the ablation immediate to the ocular surface, the structural loss associated to LASIK is prevented, which has proven to be a factor related to ectasia progression in keratoconus. This technique is ideal for the treatment of small ametropias, such that it is not recommended for large ablations (ideally, less than 50 microns) given the possibility of postoperative haze. It is important to be cautious considering that there are reports of ectasia even when employing this technique<sup>[42]</sup>. In regards to this technique, Bilgihan *et al*<sup>[43]</sup> and Bahar *et al*<sup>[44]</sup> have reported an improvement UDVA in fruste keratoconus patients treated with PRK. During the follow up period they don't report keratoconus progression. Based on these results, the authors conclude that photorefractive keratectomy seems to be a safe strategy on eyes suspected of having frank keratoconus. Recently, Guedj *et al*<sup>[45]</sup> have reported follow up of keratoconus suspects treated with PRK, where they demonstrate lack of ectasia progression in any of their 62 eyes at 5 year follow up, considering an average refractive sphere error of  $-3.48 \pm 3.14$  D and cylinder  $-0.97 \pm 0.92$  D.

The combination of PRK with crosslinking has been a most utilized strategy and, in these cases, the criteria for its application has to do with the residual stromal bed posterior to ablation, which ideally should be greater than 400 microns. The techniques that combine these proce-



**Figure 6 Collagen cross-linking.** A, B: Accelerated corneal collagen cross-linking (A) equipment (B) and riboflavin instillation, collagen cross-linking (CXL) treatment could be decreased to 3 min with Ultraviolet-light intensity of  $30 \text{ mW/cm}^2$  achieving the same energy on cornea of conventional CXL of  $5 \text{ J/cm}^2$ ; C: Right eye three days after accelerated cross-linking showing corneal epithelium recovery; D: Left eye also after three days following accelerated CXL.

dures can be sequential or be applied in the same surgical time and, in the majority of the reports, the combination of these techniques are associated with a significant improvement in respect to UDVA, improvement in keratometries and ceasement of keratoconus progression<sup>[46-48]</sup>.

However, laser treatment experiences in keratoconus must be taken with caution because of the few reports and short term follow-up reported until now in the literature. Our knowledge about the progression in this kind of cases is still poor and the risk-benefit ratio in low ametropia treatment must be taken in consideration.

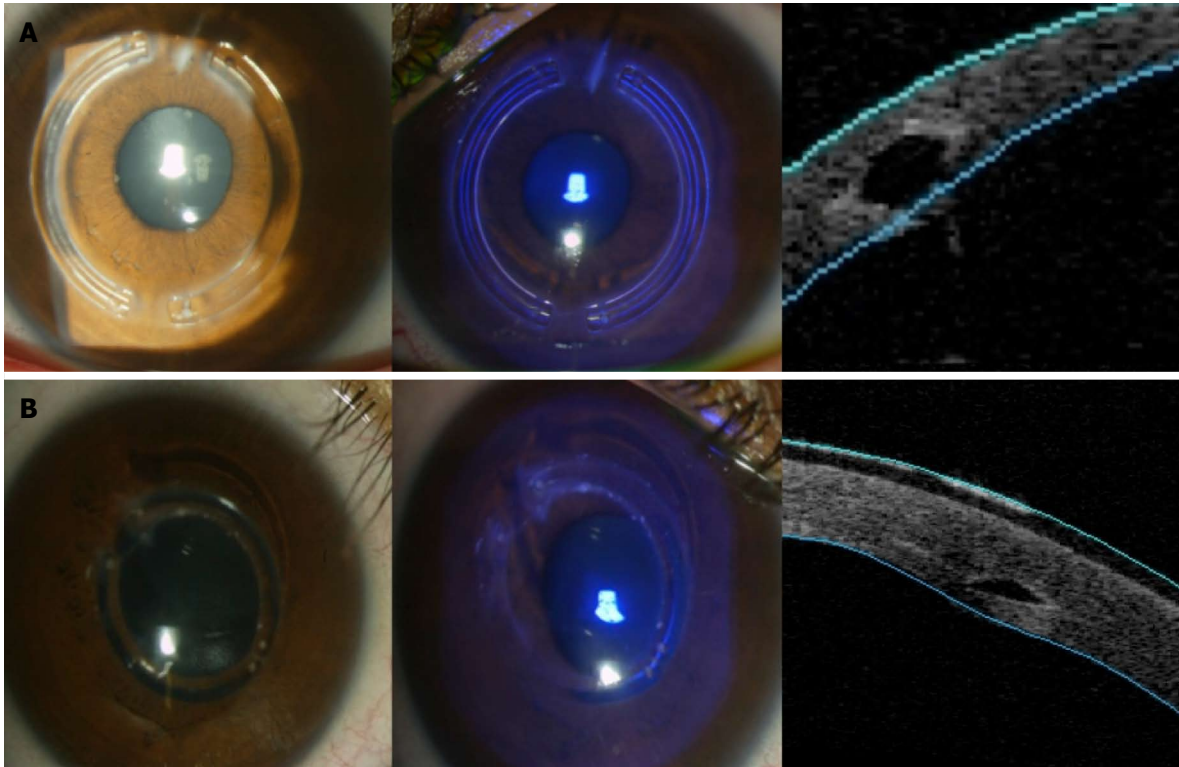
## INTRASTROMAL RING SEGMENTS

Intrastromal segments are manufactured of polymethyl methacrylate (PMMA) and were initially utilized for the treatment of myopia and astigmatism<sup>[5]</sup> (Figure 7). Recent studies have reported the effective use in the treatment of keratoconus and currently its stabilizing effect on ectasia is still controversial<sup>[49-51]</sup>. There are 5 models available, each with variations in their curvature radius, thickness and arc longitude, according to the effect to be achieved: (1) Ferrara rings (Mediphacos Inc, Belo Horizonte, Brazil); (2) Bisantis segments (Opticon 2000 SpA and Soleko SpA, Rome, Italy); (3) Intrastromal rings, Intacs (Addition Technology, Fremont, California, United States); (4) Myoring (Dioptex, GmbH, Austria); and (5) Cornealring (Visiontech Medical Optics, Belo Horizonte, Brazil). This technology is ideal for use in patients with central

corneal thickness over 400 microns and clear central cornea<sup>[49]</sup>. For their placement it is important to consider the algorithm designed for each one of the manufacturing companies to obtain the optimum effect given that such effect tends to be somewhat unpredictable<sup>[52]</sup>. In 1991, the first intrastromal segment implant on human eyes was done<sup>[53]</sup> and, through time, numerous studies have been published about the refractive results of this technology<sup>[49-56]</sup>. The majority of the authors concur that the refractive result that is obtained with the rings is better in patients with keratoconus of I and II Amsler Krumeich degree and refraction with a low spherical equivalent in which myopia is less than the astigmatism; additionally, the refractive effect tends to remain in time but not the case of the corneal curvature effect, which tends to present regression<sup>[50]</sup>.

Alió *et al*<sup>[56]</sup> has described that in keratometries  $> 53 \text{ D}$  an optimal visual effect was not observed. In the treatment of fruste keratoconus, with spherical equivalent of  $-4.5 \text{ D}$ , Güell *et al*<sup>[57]</sup> report at 4 year follow up, UDVA and CDVA improvement with 82.05% of eyes within a  $\pm 1 \text{ D}$  refraction in range of emmetropia without showing progression of keratoconus during the follow up period.

The channels for the insertion of the segments can be created mechanically or with a femtosecond laser. The most common complications associated with the mechanical dissection are: epithelial defects on the insertion site, anterior and posterior perforations, inadequate depth placement of the ring, extrusion, infectious keratitis, stro-



**Figure 7** Different intrastromal ring segments models (A) clinical and optical coherence tomography showing hexagonal shape and (B) another design with triangular shape.

mal thinning, stromal edema, intraepithelial growth in the tunnel, corneal melting and tunnel vascularization<sup>[58-61]</sup>. The use of the femtosecond laser reduces the risk of complications in the creation of the tunnels, however it has been reported that the main complication with this technique is the incomplete formation of the tunnel (up to 2.7% of the cases), among those cited previously for the manual technique<sup>[62]</sup>. Recently, the combined technique of intrastromal segments and crosslinking has been used sequentially with the purpose of attaining stability in cases of progressive keratoconus, nevertheless, no long term favorable results have been reported for this trend<sup>[63,64]</sup>.

## KERATOPLASTY

The first keratoplasty reports in history were in 1840 by Franz Mùhlbauer, who described a technique of triangular grafts to perform the first anterior lamellar keratoplasty. However, these early efforts to perform corneal grafts were not successful. The penetrating transplant was considered the treatment of choice for keratoconus for many decades; nevertheless, one of the principal disadvantages has to do with the risk of immunological rejection which can occur in up to 20% of the patients with good prognosis, such as the case of keratoconus<sup>[65]</sup>. This technique continues to be the treatment of choice when there are endothelial scars (secondary scars to hydrops) or low receptor endothelial cell count.

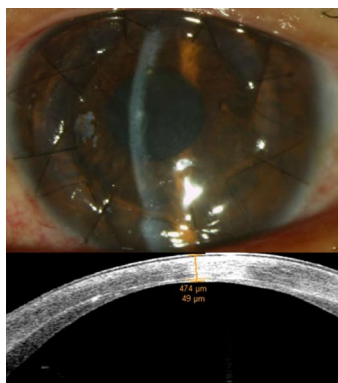The current tendency in keratoplasty is to preserve the receptor's endothelium with the objective of avoid-

ing the risk of endothelial rejection, which is normally a conditional for graft failure<sup>[66]</sup>. The advantages of the lamellar techniques over the penetrating keratoplasty are that these techniques have lower recuperative time periods, earlier management of astigmatism and sutures and lower incidence of post-operative glaucoma and graft rejection<sup>[67]</sup>.

In recent years, multiple more advanced and reproducible surgical techniques have been developed to achieve this objective. Currently there are techniques based on manual and automated dissection of the donor and receptor graft (microkeratome, femtosecond laser and excimer laser) to obtain lamellar transplants at different depths depending on the treatment expected outcome<sup>[68-70]</sup>.

The most frequently used techniques are the techniques of manual dissection, due to the little additional material required in terms of that used in a penetrating keratoplasty<sup>[66]</sup>; within this category we have Melles'<sup>[71]</sup> water and air dissection technique, the big-bubble dissection technique<sup>[72]</sup>, divide and conquer technique and Anwar's<sup>[73]</sup> visco-dissection technique. Unfortunately, the great majority of these techniques require specially advanced surgical skills, given that the conversion rate to penetrating keratoplasty can be up to 40% in inexperienced hands and 2% to 6% in experienced surgeons<sup>[74]</sup>.

Perhaps the most important limitations of the lamellar techniques continue to be the irregular borders of the corneal surface dissection that are obtained through manual technique, also the endothelial folds that are con-



**Figure 8** Femtosecond anterior lamellar keratoplasty, upper image showing the clinical photograph and lower image optical coherence tomography showing the residual stromal and endothelial tissue of around 50 microns.

ditioned by structural alterations of the receptor cornea in its posterior or more internal section (determined by the anterior and posterior curvature of the treated patient). Another of the limitations is the CDVA that patients reach that, although it's true that have lower post-surgical astigmatism than the PKP patients, CDVA, high order aberrations and contrast sensibility are similar to the penetrating technique<sup>[75]</sup>.

One of the new trends is to use the femtosecond laser (Figure 8) to perform a tissular disruption at predetermined depths by the surgeon and this way can be more precise in the graft dissection to be placed as well as the receptor with the aim of achieving better visual results. However, the reported short term results have not been able to overcome the penetrating technique<sup>[76]</sup>.

The deep anterior lamellar transplant assisted by pachymetry (PALK) was described by Carriazo *et al.*<sup>[77]</sup> in 2007. The purpose of this technique is to perform a photoblation with an excimer laser guided by topography and pachymetry of 95% of the stromal surface in a way that more regular cuts can be made at specific diameters without observing adverse perforation effects of the Descemet membrane. The initial visual results are similar to the reported by other techniques of lamellar keratoplasty and not superior in visual quantity or quality to the penetrating keratoplasty; nevertheless, showing improvement in terms of recuperation periods, post-surgical astigmatism and the use of pharmaceuticals and the suture management in the post-operative period. This same technique has recently been reported by Spadea *et al.*<sup>[78]</sup>, obtaining 20/40 CDVA at 2 years in 89% of the patients in that series.

## CONCLUSION

Keratoconus continues to be one of the most frequent corneal pathologies worldwide, being one of the primary causes of corneal blindness. Its early detection is essential and each day there are more complex and improved resources/equipment for its detection. The historic

evolution, in terms of treatments, has currently supplied us with many resources for its management, which can provide gratifying visual results for the patient and are ideal in terms of surgical techniques and lower complication rates. In order to be able to choose one of the treatments previously set out, it's important to consider the main outcome objectives for the desired treatment and the patient expectations regarding their visual rehabilitation. In the future, surely new treatment techniques will have scientific foundations in molecular mechanisms which can halt the initial onset of ectasia.

## ACKNOWLEDGMENTS

The authors would like to thank Yvonne Machain for her skillful help with the translation and edition of this manuscript.

## REFERENCES

- 1 **Krachmer JH**, Feder RS, Belin MW. Keratoconus and related noninflammatory corneal thinning disorders. *Surv Ophthalmol* 1984; **28**: 293-322 [PMID: 6230745]
- 2 **Rabinowitz YS**. Keratoconus. *Surv Ophthalmol* 1998; **42**: 297-319 [PMID: 9493273]
- 3 **Alió JL**, Shabayek MH. Corneal higher order aberrations: a method to grade keratoconus. *J Refract Surg* 2006; **22**: 539-545 [PMID: 16805116]
- 4 **Piñero DP**, Nieto JC, Lopez-Miguel A. Characterization of corneal structure in keratoconus. *J Cataract Refract Surg* 2012; **38**: 2167-2183 [PMID: 23195256]
- 5 **Jhanji V**, Sharma N, Vajpayee RB. Management of keratoconus: current scenario. *Br J Ophthalmol* 2011; **95**: 1044-1050 [PMID: 20693553 DOI: 10.1136/bjo.2010.185868]
- 6 **Garcia-Lledo M**, Feinbaum C, Alio JL. Contact lens fitting in keratoconus. *Compr Ophthalmol Update* 2006; **7**: 47-52 [PMID: 16709339]
- 7 **Shneor E**, Millodot M, Blumberg S, Ortenberg I, Behrman S, Gordon-Shaag A. Characteristics of 244 patients with keratoconus seen in an optometric contact lens practice. *Clin Exp Optom* 2013; **96**: 219-224 [PMID: 23278637 DOI: 10.1111/cxo.12005]
- 8 **Baran I**, Bradley JA, Alipour F, Rosenthal P, Le HG, Jacobs DS. PROSE treatment of corneal ectasia. *Cont Lens Anterior Eye* 2012; **35**: 222-227 [PMID: 22633003 DOI: 10.1016/j.clae.2012.04.003]
- 9 **Abdalla YF**, Elsahn AF, Hammersmith KM, Cohen EJ. SynergEyes lenses for keratoconus. *Cornea* 2010; **29**: 5-8 [PMID: 19907301 DOI: 10.1097/ICO.0b013e3181a9d090]
- 10 **Betts AM**, Mitchell GL, Zadnik K. Visual performance and comfort with the Rose K lens for keratoconus. *Optom Vis Sci* 2002; **79**: 493-501 [PMID: 12199541]
- 11 **Sabesan R**, Johns L, Tomashevskaya O, Jacobs DS, Rosenthal P, Yoon G. Wavefront-guided scleral lens prosthetic device for keratoconus. *Optom Vis Sci* 2013; **90**: 314-323 [PMID: 23478630 DOI: 10.1097/OPX.0b013e318288d19c]
- 12 **Leccisotti A**, Fields SV. Angle-supported phakic intraocular lenses in eyes with keratoconus and myopia. *J Cataract Refract Surg* 2003; **29**: 1530-1536 [PMID: 12954300]
- 13 **Iovieno A**, Guglielmetti S, Capuano V, Allan BD, Maurino V. Correction of postkeratoplasty ametropia in keratoconus patients using a toric implantable Collamer lens. *Eur J Ophthalmol* 2013; **23**: 361-367 [PMID: 23335306 DOI: 10.5301/ejo.5000232]
- 14 **Alfonso JF**, Palacios A, Montés-Micó R. Myopic phakic

- STAAR collamer posterior chamber intraocular lenses for keratoconus. *J Refract Surg* 2008; **24**: 867-874 [PMID: 19044225]
- 15 **Venter J**. Artisan phakic intraocular lens in patients with keratoconus. *J Refract Surg* 2009; **25**: 759-764 [PMID: 19772260]
  - 16 **Alfonso JF**, Fernández-Vega L, Lisa C, Fernandes P, González-Méjome JM, Montés-Micó R. Collagen copolymer toric posterior chamber phakic intraocular lens in eyes with keratoconus. *J Cataract Refract Surg* 2010; **36**: 906-916 [PMID: 20494760 DOI: 10.3928/1081597X-20090813-01]
  - 17 **Kamiya K**, Shimizu K, Kobashi H, Komatsu M, Nakamura A, Nakamura T, Ichikawa K. Clinical outcomes of posterior chamber toric phakic intraocular lens implantation for the correction of high myopic astigmatism in eyes with keratoconus: 6-month follow-up. *Graefes Arch Clin Exp Ophthalmol* 2011; **249**: 1073-1080 [PMID: 20953620 DOI: 10.1007/s00417-010-1540-5]
  - 18 **Sedaghat M**, Ansari-Astaneh MR, Zarei-Ghanavati M, Davis SW, Sikder S. Artisan iris-supported phakic IOL implantation in patients with keratoconus: a review of 16 eyes. *J Refract Surg* 2011; **27**: 489-493 [PMID: 21323301 DOI: 10.3928/1081597X-20110203-01]
  - 19 **Kato N**, Toda I, Hori-Komai Y, Sakai C, Arai H, Tsubota K. Phakic intraocular lens for keratoconus. *Ophthalmology* 2011; **118**: 605-605.e2 [PMID: 21376252 DOI: 10.1016/j.ophttha.2010.08.043]
  - 20 **Hashemian SJ**, Soleimani M, Foroutan A, Joshaghani M, Ghaempanah J, Jafari ME. Toric implantable collamer lens for high myopic astigmatism in keratoconic patients after six months. *Clin Exp Optom* 2013; **96**: 225-232 [PMID: 22963113 DOI: 10.1111/j.1444-0938.2012.00800.x]
  - 21 **Moshirfar M**, Fenzl CR, Meyer JJ, Neuffer MC, Espandar L, Mifflin MD. Simultaneous and sequential implantation of intacs and verisyse phakic intraocular lens for refractive improvement in keratectasia. *Cornea* 2011; **30**: 158-163 [PMID: 21045659 DOI: 10.1097/ICO.0b013e3181eeb0dd]
  - 22 **Izquierdo L**, Henriquez MA, McCarthy M. Artiflex phakic intraocular lens implantation after corneal collagen cross-linking in keratoconic eyes. *J Refract Surg* 2011; **27**: 482-487 [PMID: 21210571 DOI: 10.3928/1081597X-20101223-02]
  - 23 **Alfonso JF**, Lisa C, Fernández-Vega L, Madrid-Costa D, Poo-López A, Montés-Micó R. Intrastromal corneal ring segments and posterior chamber phakic intraocular lens implantation for keratoconus correction. *J Cataract Refract Surg* 2011; **37**: 706-713 [PMID: 21420596 DOI: 10.1016/j.jcrs.2010.10.060]
  - 24 **Güell JL**, Morral M, Malecaze F, Gris O, Elies D, Manero F. Collagen crosslinking and toric iris-claw phakic intraocular lens for myopic astigmatism in progressive mild to moderate keratoconus. *J Cataract Refract Surg* 2012; **38**: 475-484 [PMID: 22261324 DOI: 10.1016/j.jcrs.2011.10.031]
  - 25 **Navas A**, Tapia-Herrera G, Jaimes M, Graue-Hernández EO, Gomez-Bastar A, Ramirez-Luquín T, Ramirez-Miranda A. Implantable collamer lenses after intracorneal ring segments for keratoconus. *Int Ophthalmol* 2012; **32**: 423-429 [PMID: 22581308]
  - 26 **Thebpatiphat N**, Hammersmith KM, Rapuano CJ, Ayres BD, Cohen EJ. Cataract surgery in keratoconus. *Eye Contact Lens* 2007; **33**: 244-246 [PMID: 17873627]
  - 27 **McMahon TT**, Edrington TB, Szczotka-Flynn L, Olafsson HE, Davis LJ, Schechtman KB. Longitudinal changes in corneal curvature in keratoconus. *Cornea* 2006; **25**: 296-305 [PMID: 16633030]
  - 28 **Jaimes M**, Xacur-García F, Alvarez-Melloni D, Graue-Hernández EO, Ramirez-Luquín T, Navas A. Refractive lens exchange with toric intraocular lenses in keratoconus. *J Refract Surg* 2011; **27**: 658-664 [PMID: 21667880 DOI: 10.3928/1081597X-20110531-01]
  - 29 **Nanavaty MA**, Lake DB, Daya SM. Outcomes of pseudo-phakic toric intraocular lens implantation in Keratoconic eyes with cataract. *J Refract Surg* 2012; **28**: 884-889 [PMID: 23310966]
  - 30 **Goh YW**, Misra S, Patel DV, McGhee CN. Combining primary and piggyback intraocular lenses to treat extreme myopic astigmatism in stable keratoconus following cataract surgery. *Clin Exp Optom* 2013; **96**: 242-244 [PMID: 23448261 DOI: 10.1111/cxo.12050]
  - 31 **Wollensak G**, Spoerl E, Seiler T. Riboflavin/ultraviolet-a-induced collagen crosslinking for the treatment of keratoconus. *Am J Ophthalmol* 2003; **135**: 620-627 [PMID: 12719068]
  - 32 **Asri D**, Touboul D, Fournié P, Malet F, Garra C, Gallois A, Malecaze F, Colin J. Corneal collagen crosslinking in progressive keratoconus: multicenter results from the French National Reference Center for Keratoconus. *J Cataract Refract Surg* 2011; **37**: 2137-2143 [PMID: 22108109 DOI: 10.1016/j.jcrs.2011.08.026]
  - 33 **Raiskup-Wolf F**, Hoyer A, Spoerl E, Pillunat LE. Collagen crosslinking with riboflavin and ultraviolet-A light in keratoconus: long-term results. *J Cataract Refract Surg* 2008; **34**: 796-801 [PMID: 18471635 DOI: 10.1016/j.jcrs.2007.12.039]
  - 34 **Greenstein SA**, Fry KL, Bhatt J, Hersh PS. Natural history of corneal haze after collagen crosslinking for keratoconus and corneal ectasia: Scheimpflug and biomicroscopic analysis. *J Cataract Refract Surg* 2010; **36**: 2105-2114 [PMID: 21111314 DOI: 10.1016/j.jcrs.2010.06.067]
  - 35 **Raiskup F**, Hoyer A, Spoerl E. Permanent corneal haze after riboflavin-UVA-induced cross-linking in keratoconus. *J Refract Surg* 2009; **25**: S824-S828 [PMID: 19772259 DOI: 10.3928/1081597X-20090813-12]
  - 36 **Wittig-Silva C**, Whiting M, Lamoureux E, Lindsay RG, Sullivan LJ, Snibson GR. A randomized controlled trial of corneal collagen cross-linking in progressive keratoconus: preliminary results. *J Refract Surg* 2008; **24**: S720-S725 [PMID: 18811118]
  - 37 **Kymionis GD**, Portaliou DM, Diakonis VF, Kounis GA, Panagopoulou SI, Grentzelos MA. Corneal collagen cross-linking with riboflavin and ultraviolet-A irradiation in patients with thin corneas. *Am J Ophthalmol* 2012; **153**: 24-28 [PMID: 21861976 DOI: 10.1016/j.ajo.2011.05.036]
  - 38 **Mazzotta C**, Caporossi T, Denaro R, Bovone C, Sparano C, Paradiso A, Baiocchi S, Caporossi A. Morphological and functional correlations in riboflavin UV A corneal collagen cross-linking for keratoconus. *Acta Ophthalmol* 2012; **90**: 259-265 [PMID: 20456255 DOI: 10.1111/j.1755-3768.2010.01890.x]
  - 39 **Zhang ZY**, Zhang XR. Efficacy and safety of transepithelial corneal collagen crosslinking. *J Cataract Refract Surg* 2012; **38**: 1304; author reply 1304-1305 [PMID: 22727312 DOI: 10.1016/j.jcrs.2012.05.012]
  - 40 **Cherfan D**, Verter EE, Melki S, Gisel TE, Doyle FJ, Scarcelli G, Yun SH, Redmond RW, Kochevar IE. Collagen cross-linking using rose bengal and green light to increase corneal stiffness. *Invest Ophthalmol Vis Sci* 2013; **54**: 3426-3433 [PMID: 23599326 DOI: 10.1167/iovs.12-11509]
  - 41 **Celik HU**, Alagöz N, Yildirim Y, Agca A, Marshall J, Demirok A, Yilmaz OF. Accelerated corneal crosslinking concurrent with laser in situ keratomileusis. *J Cataract Refract Surg* 2012; **38**: 1424-31 [DOI: 10.1016/j.jcrs.2012.03.034]
  - 42 **Navas A**, Ariza E, Haber A, Fermon S, Velazquez R, Suarez R. Bilateral keratectasia after photorefractive keratectomy. *J Refract Surg* 2007; **23**: 941-943 [PMID: 18041251]
  - 43 **Bilgihan K**, Ozdek SC, Konuk O, Akata F, Hasanreisoglu B. Results of photorefractive keratectomy in keratoconus suspects at 4 years. *J Refract Surg* 2000; **16**: 438-443 [PMID: 10939723]
  - 44 **Bahar I**, Levinger S, Kremer I. Wavefront-supported photorefractive keratectomy with the Bausch & Lomb Zyoptix in patients with myopic astigmatism and suspected keratoconus. *J Refract Surg* 2006; **22**: 533-538 [PMID: 16633030]

- 16805115]
- 45 **Guedj M**, Saad A, Audureau E, Gatineau D. Photorefractive keratectomy in patients with suspected keratoconus: five-year follow-up. *J Cataract Refract Surg* 2013; **39**: 66-73 [PMID: 23102727 DOI: 10.1016/j.jcrs.2012.08.058]
- 46 **Kanellopoulos AJ**. Comparison of sequential vs same-day simultaneous collagen cross-linking and topography-guided PRK for treatment of keratoconus. *J Refract Surg* 2009; **25**: S812-S818 [PMID: 19772257 DOI: 10.3928/1081597X-20090813-10]
- 47 **Tuwairqi WS**, Sinjab MM. Safety and efficacy of simultaneous corneal collagen cross-linking with topography-guided PRK in managing low-grade keratoconus: 1-year follow-up. *J Refract Surg* 2012; **28**: 341-345 [PMID: 22443804 DOI: 10.3928/1081597X-20120316-01]
- 48 **Stojanovic A**, Zhang J, Chen X, Nitter TA, Chen S, Wang Q. Topography-guided transepithelial surface ablation followed by corneal collagen cross-linking performed in a single combined procedure for the treatment of keratoconus and pellucid marginal degeneration. *J Refract Surg* 2010; **26**: 145-152 [PMID: 20163079 DOI: 10.3928/1081597X-20100121-10]
- 49 **Ruckhofer J**, Twa MD, Schanzlin DJ. Clinical characteristics of lamellar channel deposits after implantation of intacs. *J Cataract Refract Surg* 2000; **26**: 1473-1479 [PMID: 11033393]
- 50 **Alió JL**, Shabayek MH, Artola A. Intracorneal ring segments for keratoconus correction: long-term follow-up. *J Cataract Refract Surg* 2006; **32**: 978-985 [PMID: 16814056]
- 51 **Torquetti L**, Berbel RF, Ferrara P. Long-term follow-up of intrastromal corneal ring segments in keratoconus. *J Cataract Refract Surg* 2009; **35**: 1768-1773 [PMID: 19781474 DOI: 10.1016/j.jcrs.2009.05.036]
- 52 **Piñero DP**, Alió JL, El Kady B, Coskunseven E, Morbelli H, Uceda-Montanes A, Maldonado MJ, Cuevas D, Pascual I. Refractive and aberrometric outcomes of intracorneal ring segments for keratoconus: mechanical versus femtosecond-assisted procedures. *Ophthalmology* 2009; **116**: 1675-1687 [PMID: 19643498 DOI: 10.1016/j.ophtha.2009.05.016]
- 53 **Rapuan CJ**, Sugar A, Koch DD, Agapitos PJ, Culbertson WW, de Luise VP, Huang D, Varley GA. Intrastromal corneal ring segments for low myopia: a report by the American Academy of Ophthalmology. *Ophthalmology* 2001; **108**: 1922-1928 [PMID: 11581075]
- 54 **Ertan A**, Kamburoğlu G. Intacs implantation using a femtosecond laser for management of keratoconus: Comparison of 306 cases in different stages. *J Cataract Refract Surg* 2008; **34**: 1521-1526 [PMID: 18721713 DOI: 10.1016/j.jcrs.2008.05.028]
- 55 **Vega-Estrada A**, Alió JL, Brenner LF, Javaloy J, Plaza Puche AB, Barraquer RI, Teus MA, Murta J, Henriques J, Uceda-Montanes A. Outcome analysis of intracorneal ring segments for the treatment of keratoconus based on visual, refractive, and aberrometric impairment. *Am J Ophthalmol* 2013; **155**: 575-584.e1 [PMID: 23218702 DOI: 10.1016/j.ajo.2012.08.020]
- 56 **Alió JL**, Shabayek MH, Belda JL, Correas P, Feijoo ED. Analysis of results related to good and bad outcomes of Intacs implantation for keratoconus correction. *J Cataract Refract Surg* 2006; **32**: 756-761 [PMID: 16765791]
- 57 **Güell JL**, Morral M, Salinas C, Elies D, Gris O, Manero F. Intrastromal corneal ring segments to correct low myopia in eyes with irregular or abnormal topography including forme fruste keratoconus: 4-year follow-up. *J Cataract Refract Surg* 2010; **36**: 1149-1155 [PMID: 20610093 DOI: 10.1016/j.jcrs.2010.01.019]
- 58 **Colin J**, Buestel C, Touboul D. Unusual secondary displacement of Intacs segments--superimposition of distal ends. *J Refract Surg* 2010; **26**: 924-925 [PMID: 21162490 DOI: 10.3928/1081597X-20101001-02]
- 59 **Hashemi H**, Ghaffari R, Mohammadi M, Moghimi S, Miraftab M. Microbial keratitis after INTACS implantation with loose suture. *J Refract Surg* 2008; **24**: 551-552 [PMID: 18494352]
- 60 **Hofling-Lima AL**, Branco BC, Romano AC, Campos MQ, Moreira H, Miranda D, Kwitko S, de Freitas D, Casanova FH, Sartori M, Schor P, Souza LB. Corneal infections after implantation of intracorneal ring segments. *Cornea* 2004; **23**: 547-549 [PMID: 15256990]
- 61 **Kymionis GD**, Kontadakis GA. Severe corneal vascularization after intacs implantation and rigid contact lens use for the treatment of keratoconus. *Semin Ophthalmol* 2012; **27**: 19-21 [PMID: 22352820 DOI: 10.3109/08820538.2011.588646]
- 62 **Coskunseven E**, Kymionis GD, Tsiklis NS, Atun S, Arslan E, Siganos CS, Jankov M, Pallikaris IG. Complications of intrastromal corneal ring segment implantation using a femtosecond laser for channel creation: a survey of 850 eyes with keratoconus. *Acta Ophthalmol* 2011; **89**: 54-57 [PMID: 19681760 DOI: 10.1111/j.1755-3768.2009.01605.x]
- 63 **El Awady H**, Shawky M, Ghanem AA. Evaluation of collagen crosslinking in keratoconus eyes with Kera intracorneal ring implantation. *Eur J Ophthalmol* 2012; **22** Suppl 7: S62-S68 [PMID: 21786268 DOI: 10.5301/ejo.5000020]
- 64 **Kılıç A**, Kamburoğlu G, Akıncı A. Riboflavin injection into the corneal channel for combined collagen crosslinking and intrastromal corneal ring segment implantation. *J Cataract Refract Surg* 2012; **38**: 878-883 [PMID: 22425362 DOI: 10.1016/j.jcrs.2011.11.041]
- 65 **Brierly SC**, Izquierdo L, Mannis MJ. Penetrating keratoplasty for keratoconus. *Cornea* 2000; **19**: 329-332 [PMID: 10832693]
- 66 **Reinhart WJ**, Musch DC, Jacobs DS, Lee WB, Kaufman SC, Shtein RM. Deep anterior lamellar keratoplasty as an alternative to penetrating keratoplasty: a report by the american academy of ophthalmology. *Ophthalmology* 2011; **118**: 209-218 [PMID: 21199711 DOI: 10.1016/j.ophtha.2010.11.002]
- 67 **Han DC**, Mehta JS, Por YM, Htoon HM, Tan DT. Comparison of outcomes of lamellar keratoplasty and penetrating keratoplasty in keratoconus. *Am J Ophthalmol* 2009; **148**: 744-751.e1 [PMID: 19589495 DOI: 10.1016/j.ajo.2009.05.028]
- 68 **Buzzonetti L**, Laborante A, Petrocilli G. Refractive outcome of keratoconus treated by combined femtosecond laser and big-bubble deep anterior lamellar keratoplasty. *J Refract Surg* 2011; **27**: 189-194 [PMID: 20540471 DOI: 10.3928/1081597X-20100520-01]
- 69 **Busin M**, Scordia V, Zambianchi L, Ponzin D. Outcomes from a modified microkeratome-assisted lamellar keratoplasty for keratoconus. *Arch Ophthalmol* 2012; **130**: 776-782 [PMID: 22801840 DOI: 10.1001/archophthol.2011.1546]
- 70 **Tan DT**, Ang LP. Modified automated lamellar therapeutic keratoplasty for keratoconus: a new technique. *Cornea* 2006; **25**: 1217-1219 [PMID: 17172901]
- 71 **Melles GR**, Lander F, Rietveld FJ, Remeijer L, Beekhuis WH, Binder PS. A new surgical technique for deep stromal, anterior lamellar keratoplasty. *Br J Ophthalmol* 1999; **83**: 327-333 [PMID: 10365042]
- 72 **Anwar M**, Teichmann KD. Big-bubble technique to bare Descemet's membrane in anterior lamellar keratoplasty. *J Cataract Refract Surg* 2002; **28**: 398-403 [PMID: 11973083]
- 73 **Anwar M**, Teichmann KD. Deep lamellar keratoplasty: surgical techniques for anterior lamellar keratoplasty with and without baring of Descemet's membrane. *Cornea* 2002; **21**: 374-383 [PMID: 11973386]
- 74 **Feizi S**, Javadi MA, Jamali H, Mirbabaee F. Deep anterior lamellar keratoplasty in patients with keratoconus: big-bubble technique. *Cornea* 2010; **29**: 177-182 [PMID: 20023579 DOI: 10.1097/ICO.0b013e3181af25b7]
- 75 **Söğütli Sari E**, Kubaloğlu A, Ünal M, Piñero Llorens D, Koytak A, Ofluoglu AN, Öztürk Y. Penetrating keratoplasty versus deep anterior lamellar keratoplasty: comparison of optical and visual quality outcomes. *Br*

- J Ophthalmol* 2012; **96**: 1063-1067 [PMID: 22718792 DOI: 10.1136/bjophthalmol-2011-301349]
- 76 **Almoussa R**, Samaras KE, Khan S, Lake DB, Daya SM. Femtosecond laser-assisted lamellar keratoplasty (FSLK) for anterior corneal stromal diseases. *Int Ophthalmol* 2013 May 24; [Epub ahead of print] [PMID: 23703704 DOI: 10.1007/s10792-013-9794-7]
- 77 **Carriazo C**. Pachymetry-assisted laser keratoplasty: a new approach to an old technique. In: Azar D. *Refractive Surgery* 2007. 2nd ed. St. Louis, MO: Elsevier-Mosby, 2007: 291-297
- 78 **Spadea L**, Gizzi R, Evangelista Conocchia N, Urbano S. Optical pachymetry-guided custom excimer laser-assisted lamellar keratoplasty for the surgical treatment of keratoconus. *J Cataract Refract Surg* 2012; **38**: 1559-1567 [PMID: 22906442 DOI: 10.1016/j.jcrs.2012.05.029]

**P- Reviewers** Jhanji V, Leccisotti A **S- Editor** Song XX  
**L- Editor** A **E- Editor** Lu YJ





Published by **Baishideng Publishing Group Co., Limited**

Flat C, 23/F., Lucky Plaza, 315-321 Lockhart Road,

Wan Chai, Hong Kong, China

Fax: +852-65557188

Telephone: +852-31779906

E-mail: [bpgoffice@wjgnet.com](mailto:bpgoffice@wjgnet.com)

<http://www.wjgnet.com>

