

World Journal of *Gastrointestinal Surgery*

World J Gastrointest Surg 2019 February 27; 11(2): 34-116





EDITORIAL

- 34 Pushing the limits of liver surgery for colorectal liver metastases: Current state and future directions
Araujo RL, Linhares MM
- 41 Enhanced recovery after surgery in emergency colorectal surgery: Review of literature and current practices
Lohsiriwat V, Jitmongkarn R

REVIEW

- 53 Success and safety of endoscopic treatments for concomitant biliary and duodenal malignant stenosis: A review of the literature
Mangiavillano B, Khashab MA, Tarantino I, Carrara S, Semeraro R, Auriemma F, Bianchetti M, Eusebi LH, Yen-I C, De Luca L, Traina M, Repici A

MINIREVIEWS

- 62 Safe laparoscopic cholecystectomy: Adoption of universal culture of safety in cholecystectomy
Gupta V, Jain G

ORIGINAL ARTICLE

Basic Study

- 85 *In vivo* expression of thrombospondin-1 suppresses the formation of peritoneal adhesion in rats
Tai YS, Jou IM, Jung YC, Wu CL, Shiau AL, Chen CY

Case Control Study

- 93 Dual loop (Roux en Y) reconstruction with isolated gastric limb reduces delayed gastric emptying after pancreatoduodenectomy
Ben-Ishay O, Zhaya RA, Kluger Y

CASE REPORT

- 101 Acquired segmental colonic hypoganglionosis in an adult Caucasian male: A case report
Kwok AM, Still AB, Hart K
- 112 Esophagogastric junction outflow obstruction successfully treated with laparoscopic Heller myotomy and Dor fundoplication: First case report in the literature
Pereira PF, Rosa AR, Mesquita LA, Anzolph MJ, Branchi RN, Giongo AL, Paixão FC, Chedid MF, Kruel CD

ABOUT COVER

Associate Editor of *World Journal of Gastrointestinal Surgery*, Marcio F Chedid, MD, PhD, Professor, Surgeon, Division of Gastrointestinal Surgery and Liver Transplantation, Hospital de Clínicas de Porto Alegre, Medical School of UFRGS, Porto Alegre 90035-903, Brazil

AIMS AND SCOPE

World Journal of Gastrointestinal Surgery (*World J Gastrointest Surg*, *WJGS*, online ISSN 1948-9366, DOI: 10.4240) is a peer-reviewed open access academic journal that aims to guide clinical practice and improve diagnostic and therapeutic skills of clinicians.

WJGS covers topics concerning micro-invasive surgery; laparoscopy; hepatic, biliary, pancreatic and splenic surgery; surgical nutrition; portal hypertension, as well as associated subjects. The current columns of *WJGS* include editorial, frontier, diagnostic advances, therapeutics advances, field of vision, mini-reviews, review, original articles, case report, etc.

We encourage authors to submit their manuscripts to *WJGS*. We will give priority to manuscripts that are supported by major national and international foundations and those that are of great basic and clinical significance.

INDEXING/ABSTRACTING

The *WJGS* is now abstracted and indexed in PubMed, PubMed Central, Emerging Sources Citation Index (Web of Science), China National Knowledge Infrastructure (CNKI), China Science and Technology Journal Database (CSTJ), and Superstar Journals Database.

**RESPONSIBLE EDITORS
FOR THIS ISSUE**

Responsible Electronic Editor: Yun-Xiaojuan Wu Proofing Editorial Office Director: Jin-Lei Wang

NAME OF JOURNAL

World Journal of Gastrointestinal Surgery

ISSN

ISSN 1948-9366 (online)

LAUNCH DATE

November 30, 2009

FREQUENCY

Monthly

EDITORS-IN-CHIEF

Varut Lohsirirawat, Shu-You Peng

EDITORIAL BOARD MEMBERS

<https://www.wjgnet.com/1948-9366/editorialboard.htm>

EDITORIAL OFFICE

Jin-Lei Wang, Director

PUBLICATION DATE

February 27, 2019

COPYRIGHT

© 2019 Baishideng Publishing Group Inc

INSTRUCTIONS TO AUTHORS

<https://www.wjgnet.com/bpg/gerinfo/204>

GUIDELINES FOR ETHICS DOCUMENTS

<https://www.wjgnet.com/bpg/GerInfo/287>

GUIDELINES FOR NON-NATIVE SPEAKERS OF ENGLISH

<https://www.wjgnet.com/bpg/gerinfo/240>

PUBLICATION MISCONDUCT

<https://www.wjgnet.com/bpg/gerinfo/208>

ARTICLE PROCESSING CHARGE

<https://www.wjgnet.com/bpg/gerinfo/242>

STEPS FOR SUBMITTING MANUSCRIPTS

<https://www.wjgnet.com/bpg/GerInfo/239>

ONLINE SUBMISSION

<https://www.f6publishing.com>



Esophagogastric junction outflow obstruction successfully treated with laparoscopic Heller myotomy and Dor fundoplication: First case report in the literature

Pedro F Pereira, Andre RP Rosa, Leonardo A Mesquita, Marcelle J Anzolch, Rafael N Branchi, Augusto L Giongo, Francisco C Paixão, Marcio F Chedid, Cleber DP Kruel

ORCID number: Pedro F Pereira (0000-0002-8106-0819); Andre RP Rosa (0000-0002-9761-576X); Leonardo A Mesquita (0000-0002-6373-0057); Marcelle J Anzolch (0000-0003-0425-772X); Rafael N Branchi (0000-0002-8360-6723); Augusto L Giongo (0000-0002-8106-0818); Francisco C Paixao (0000-0002-5036-2128); Marcio F Chedid (0000-0001-6182-6963); Cleber DP Kruel (0000-0003-3840-4791).

Author contributions: Pereira PF, Rosa AR, Mesquita LA, Anzolch MJ, Branchi RN, Giongo AL, Paixão FC, Chedid MF, Kruel CD, contributed with methodology, data acquisition, data presentation and writing of an original draft of the manuscript; Kruel C, Rosa AR and Chedid MF contributed with methodology; conceptualization, and supervision; all authors conducted critical revisions and approved the final version of the manuscript.

Supported by Research and Events Support Fund at Hospital de Clínicas de Porto Alegre.

Informed consent statement: Informed written consent was obtained from the patient for publication of this report and any accompanying images.

Conflict-of-interest statement: The authors declare that they have no conflict of interest.

Pedro F Pereira, Andre RP Rosa, Leonardo A Mesquita, Marcelle J Anzolch, Rafael N Branchi, Augusto L Giongo, Francisco C Paixão, Marcio F Chedid, Cleber DP Kruel, Division of Gastrointestinal Surgery and Liver Transplantation, Hospital de Clínicas de Porto Alegre, Federal University of Rio Grande do Sul, Porto Alegre 90035-903, Brazil

Corresponding author: Marcio F Chedid, MD, PhD, Professor, Surgeon, Division of Gastrointestinal Surgery and Liver Transplantation, Hospital de Clínicas de Porto Alegre, Medical School of Federal University of Rio Grande do Sul, Rua Ramiro Barcelos 2350, 6th Floor, Room 600, Porto Alegre 90035-903, Brazil. marciochedid@hotmail.com
Telephone: +55-51-997721980

Abstract

BACKGROUND

Esophagogastric junction outflow obstruction (EGJO) is a rare syndrome, characterized by an elevation of the integrated relaxation pressure of the lower esophageal sphincter, not accompanied by alterations in esophageal motility that may lead to the criteria for achalasia. We were unable to find any prior report of the combination of Heller myotomy with anterior partial fundoplication (Dor) as the treatment for EGJO. We herein report a case of EGJO treated with laparoscopic Heller myotomy combined with Dor fundoplication.

CASE SUMMARY

A 26-year-old man presented with a 3-year history of solid dysphagia and a 30-kg weight loss. He was treated with oral nifedipine, isosorbide, and omeprazole, without resolution of symptoms. An upper gastrointestinal series (barium swallow) revealed a "bird's beak" sign. Esophagogastroduodenoscopy was positive for Los Angeles grade A peptic esophagitis. High-resolution esophageal manometry was compatible with EGJO. Esophageal pH monitoring showed pathological acid reflux both in orthostatic and decubitus position. An 8-cm laparoscopic Heller myotomy combined with an anterior 220° Dor fundoplication was performed. Solid diet was introduced on postoperative day 2, and the patient was discharged home the same day. At 17-mo follow-up, he reported no symptoms. Barium swallow was compatible with complete radiologic resolution. Both esophageal manometry and upper endoscopy showed normal findings 9 mo after the operation.

CARE Checklist (2016) statement:

The authors have read the CARE Checklist (2013), and the manuscript was prepared and revised according to the CARE Checklist (2016).

Open-Access: This article is an open-access article which was selected by an in-house editor and fully peer-reviewed by external reviewers. It is distributed in accordance with the Creative Commons Attribution Non Commercial (CC BY-NC 4.0) license, which permits others to distribute, remix, adapt, build upon this work non-commercially, and license their derivative works on different terms, provided the original work is properly cited and the use is non-commercial. See:

<http://creativecommons.org/licenses/by-nc/4.0/>

Manuscript source: Invited manuscript

Received: January 26, 2019

Peer-review started: January 27, 2019

First decision: February 19, 2019

Revised: February 21, 2019

Accepted: February 21, 2019

Article in press: February 22, 2019

Published online: February 27, 2019

CONCLUSION

Surgical treatment with Heller myotomy and Dor fundoplication is a potential treatment option for EGJOO refractory to medical treatment.

Key words: Esophagogastric junction outflow obstruction; Heller myotomy; Partial fundoplication; Dor fundoplication; Case report

©The Author(s) 2019. Published by Baishideng Publishing Group Inc. All rights reserved.

Core tip: Esophagogastric junction outflow obstruction (EGJOO) is a rare syndrome, characterized by an elevation of the integrated relaxation pressure of the lower esophageal sphincter, not accompanied by alterations in esophageal motility that may lead to the criteria for achalasia. Surgical treatment of EGJOO is very rarely considered and very few cases have been reported in the medical literature. We herein report the first case of EGJOO successfully treated with laparoscopic Heller myotomy combined with Dor fundoplication.

Citation: Pereira PF, Rosa AR, Mesquita LA, Anzolch MJ, Branchi RN, Giongo AL, Paixão FC, Chedid MF, Krueel CD. Esophagogastric junction outflow obstruction successfully treated with laparoscopic Heller myotomy and Dor fundoplication: First case report in the literature. *World J Gastrointest Surg* 2019; 11(2): 112-116

URL: <https://www.wjgnet.com/1948-9366/full/v11/i2/112.htm>

DOI: <https://dx.doi.org/10.4240/wjgs.v11.i2.112>

INTRODUCTION

Esophagogastric junction outflow obstruction (EGJOO) is a rare syndrome, characterized by an elevation of the integrated relaxation pressure of the lower esophageal sphincter, not accompanied by alterations in esophageal motility that may lead to the criteria for achalasia^[1]. In a recent study, of the 1000 patients meeting the criteria for evaluation by esophageal pressure topography, only 8 were diagnosed with EGJOO^[2].

The main clinical manifestations of EGJOO are dysphagia, chest pain, or both. Because the symptoms may resolve without intervention in up to 40% of cases, a waiting period between diagnosis and initiation of treatment is recommended^[3]. Oral calcium-channel blockers are the treatment of choice, but botulinum toxin injections may also be employed. Further therapeutic options include endoscopic treatment, such as dilation and endoscopic myotomy^[1,3]. In only a minority of patients EGJOO may progress to achalasia^[1].

According to a recent expert consensus document on the management of esophageal motility disorders, surgical treatment of EGJOO is not an option.³ Therefore, surgical treatment of EGJOO is very rarely considered and very few cases have been reported in the medical literature^[2,4]. Although a few cases using laparoscopic Heller myotomy for the treatment of EGJOO have been reported^[1], we did not find any prior report of the combination of Heller myotomy with anterior partial fundoplication (Dor fundoplication) for the treatment of EGJOO^[3]. We herein report a case of EGJOO treated with laparoscopic Heller myotomy combined with Dor fundoplication.

CASE PRESENTATION**Chief complaints**

A 26-year-old man presented with a 3-year history of solid dysphagia and a 30-kg weight loss. He also complained of heartburn and regurgitation, especially at night.

History of present illness

The patient was referred to the outpatient clinic and treated with oral nifedipine, isosorbide, and omeprazole, without resolution of symptoms.

History of past illness

The history of past illness was unremarkable.

Personal and family history

The personal and family history was negative for gastrointestinal and endocrine disease.

Physical examination upon admission

The Physical examination upon admission revealed a thin patient. No lumps or abdominal tumors were detected.

Laboratory examination

Routine blood tests, routine urine tests and urinary sediment examination, routine fecal tests and occult blood test, blood biochemistry, immune indexes, and infection indexes – all were within normal limits.

Imaging examinations

An upper gastrointestinal series (barium swallow) revealed a “bird’s beak” sign (Figure 1A).

FINAL DIAGNOSIS

Esophagogastroduodenoscopy was positive for Los Angeles grade A peptic esophagitis. High-resolution esophageal manometry revealed an integrated relaxation pressure of 28 mm Hg, with incomplete relaxation and normal esophageal peristalsis (100% peristaltic waves), compatible with EGJOO (Table 1). Esophageal pH monitoring showed pathological acid reflux both in orthostatic and decubitus position.

TREATMENT

An 8-cm laparoscopic Heller myotomy combined with an anterior 220° Dor fundoplication was performed. Liquid diet was introduced on postoperative day 1. The patient was started on a solid diet on postoperative day 2 and discharged home the same day.

OUTCOME AND FOLLOW-UP

At the 17-mo follow-up visit, the patient reported no regurgitation and complete resolution of symptoms. A repeat barium swallow revealed no gastroesophageal obstruction and no esophageal dilation, compatible with complete radiologic resolution (Figure 1B).

Nine months after the operation, both a repeat endoscopy and an esophageal manometry showed normal findings (Table 2).

DISCUSSION

Surgical treatment of EGJOO is controversial^[5]. Three cases of successful Heller myotomy were reported by Scherer *et al*^[2]. Recently, Lin *et al*^[4] reported a successful robotic-assisted thoracoscopic esophageal myotomy and Belsey-Mark IV fundoplication. However, to the best of our knowledge, there is no prior published report of the combination of Heller myotomy with anterior partial fundoplication as the treatment for EGJOO.

Heller myotomy alone appears to be associated with symptomatic acid reflux in patients with achalasia. Conversely, the combination of complete (Nissen) fundoplication with Heller myotomy may predispose patients to post-fundoplication lower dysphagia. Furthermore, post-fundoplication dysphagia has been shown to resolve in parallel with the reduction of intrabolus pressure following conversion to partial fundoplication^[5]. In view of these observations, our Division has used Heller myotomy associated with anterior partial fundoplication as the standard treatment for achalasia refractory to endoscopic treatment. Therefore, the same treatment was employed in this case for the treatment of EGJOO refractory to medical and endoscopic treatment.

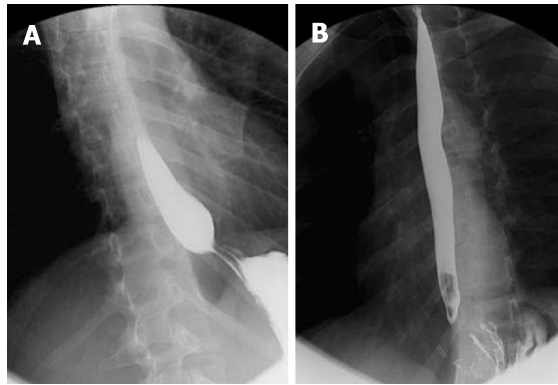


Figure 1 Barium swallow. A: Barium swallow revealing a bird's beak sign; B: Postoperative normal barium swallow.

CONCLUSION

Surgical treatment with Heller myotomy and Dor fundoplication provides a potential option for the treatment of EGJOO refractory to medical treatment.

Table 1 High resolution manometry

	Normal values	Patient values
Lower esophageal sphincter		
Localization		47.1 - 44.1
Resting pressure (mmHg)	10-45	46.7
Residual pressure (mmHg)	< 8	15.4
Integrated relaxation pressure(mmHg)	< 15	28
Relaxation	Complete	Incomplete
EGJ length (cm)	3-5	3
Esophageal body		
Peristaltic waves (%)	80 - 100	100
Distal latency (s)	> 4.5	10.0
Distal contractile Integral (mmHg/s/cm)	450 - 5000	5948

EGJ: Esophagogastric junction.

Table 2 Postoperative high resolution manometry

	Normal values	Patient values
Lower esophageal sphincter		
Localization		48-44
Resting pressure (mmHg)	10-45	7.1
Residual pressure (mmHg)	< 8	- 4
Relaxation	Completo	Complete
EGJ length (cm)	3-5	4
Esophageal body		
Peristaltic waves (%)	80-100	100

EGJ: Esophagogastric junction.

REFERENCES

- 1 **Kahrilas PJ**, Bredenoord AJ, Fox M, Gyawali CP, Roman S, Smout AJ, Pandolfino JE; International High Resolution Manometry Working Group. The Chicago Classification of esophageal motility disorders, v3.0. *Neurogastroenterol Motil* 2015; **27**: 160-174 [PMID: [25469569](#) DOI: [10.1111/nmo.12477](#)]
- 2 **Scherer JR**, Kwiatek MA, Soper NJ, Pandolfino JE, Kahrilas PJ. Functional esophagogastric junction obstruction with intact peristalsis: a heterogeneous syndrome sometimes akin to achalasia. *J Gastrointest Surg* 2009; **13**: 2219-2225 [PMID: [19672666](#) DOI: [10.1007/s11605-009-0975-7](#)]
- 3 **Kahrilas PJ**, Bredenoord AJ, Fox M, Gyawali CP, Roman S, Smout AJPM, Pandolfino JE; International Working Group for Disorders of Gastrointestinal Motility and Function. Expert consensus document: Advances in the management of oesophageal motility disorders in the era of high-resolution manometry: a focus on achalasia syndromes. *Nat Rev Gastroenterol Hepatol* 2017; **14**: 677-688 [PMID: [28951579](#) DOI: [10.1038/nrgastro.2017.132](#)]
- 4 **Lin KH**, Lee SC, Huang TW, Huang HK. Esophagogastric junction outflow obstruction-related functional chest pain treated using robotic-assisted thoracoscopic esophageal myotomy. *J Thorac Dis* 2017; **9**: E432-E436 [PMID: [28616302](#) DOI: [10.21037/jtd.2017.03.176](#)]
- 5 **Teitelbaum EN**, Dunst CM, Reavis KM, Sharata AM, Ward MA, DeMeester SR, Swanström LL. Clinical outcomes five years after POEM for treatment of primary esophageal motility disorders. *Surg Endosc* 2018; **32**: 421-427 [PMID: [28664434](#) DOI: [10.1007/s00464-017-5699-2](#)]

P- Reviewer: Arda I, Rubbini M

S- Editor: Wang JL L- Editor: A E- Editor: Wu YXJ





Published By Baishideng Publishing Group Inc
7901 Stoneridge Drive, Suite 501, Pleasanton, CA 94588, USA
Telephone: +1-925-2238242
Fax: +1-925-2238243
E-mail: bpgoffice@wjgnet.com
Help Desk: <https://www.f6publishing.com/helpdesk>
<https://www.wjgnet.com>

