

World Journal of *Clinical Cases*

World J Clin Cases 2019 May 26; 7(10): 1093-1241



**ORIGINAL ARTICLE****Retrospective Cohort Study**

- 1093** Impact of perioperative transfusion in patients undergoing resection of colorectal cancer liver metastases: A population-based study
Long B, Xiao ZN, Shang LH, Pan BY, Chai J

Retrospective Study

- 1103** Analysis of 24 patients with Achenbach's syndrome
Ada F, Kasimzade F
- 1111** Risk factors and clinical responses of pneumonia patients with colistin-resistant *Acinetobacter baumannii-calcoaceticus*
Aydemir H, Tuz HI, Piskin N, Celebi G, Kulah C, Kakturk F

Observational Study

- 1122** Diagnostic value of two dimensional shear wave elastography combined with texture analysis in early liver fibrosis
Jian ZC, Long JF, Liu YJ, Hu XD, Liu JB, Shi XQ, Li WS, Qian LX

CASE REPORT

- 1133** Selective dorsal rhizotomy in cerebral palsy spasticity - a newly established operative technique in Slovenia: A case report and review of literature
Velmar T, Spazzapan P, Rodi Z, Kos N, Bosnjak R
- 1142** Invasive myxopapillary ependymoma of the lumbar spine: A case report
Strojnink T, Bujas T, Velmar T
- 1149** Electrohydraulic lithotripsy and rendezvous nasal endoscopic cholangiography for common bile duct stone: A case report
Kimura K, Kudo K, Yoshizumi T, Kurihara T, Yoshiya S, Mano Y, Takeishi K, Itoh S, Harada N, Ikegami T, Ikeda T
- 1155** F-18 fluorodeoxyglucose positron emission tomography/computed tomography image of gastric mucormycosis mimicking advanced gastric cancer: A case report
Song BI
- 1161** Ultrasound guidance for transforaminal percutaneous endoscopic lumbar discectomy may prevent radiation exposure: A case report
Zhang MB, Yan LT, Li SP, Li YY, Huang P

- 1169** Retroperitoneoscopic approach for partial nephrectomy in children with duplex kidney: A case report
Chen DX, Wang ZH, Wang SJ, Zhu YY, Li N, Wang XQ
- 1177** Small cell lung cancer with panhypopituitarism due to ectopic adrenocorticotrophic hormone syndrome: A case report
Jin T, Wu F, Sun SY, Zheng FP, Zhou JQ, Zhu YP, Wang Z
- 1184** Therapeutic plasma exchange and a double plasma molecular absorption system in the treatment of thyroid storm with severe liver injury: A case report
Tan YW, Sun L, Zhang K, Zhu L
- 1191** Multiple rare causes of post-traumatic elbow stiffness in an adolescent patient: A case report and review of literature
Pan BQ, Huang J, Ni JD, Yan MM, Xia Q
- 1200** Liquorice-induced severe hypokalemic rhabdomyolysis with Gitelman syndrome and diabetes: A case report
Yang LY, Yin JH, Yang J, Ren Y, Xiang CY, Wang CY
- 1206** Hepatitis B virus-related liver cirrhosis complicated with dermatomyositis: A case report
Zhang J, Wen XY, Gao RP
- 1213** Small cell lung cancer starting with diabetes mellitus: Two case reports and literature review
Zhou T, Wang Y, Zhao X, Liu Y, Wang YX, Gang XK, Wang GX
- 1221** Significant benefits of osimertinib in treating acquired resistance to first-generation EGFR-TKIs in lung squamous cell cancer: A case report
Zhang Y, Chen HM, Liu YM, Peng F, Yu M, Wang WY, Xu H, Wang YS, Lu Y
- 1230** Successful endoscopic extraction of a proximal esophageal foreign body following accurate localization using endoscopic ultrasound: A case report
Wang XM, Yu S, Chen X
- 1234** Minimally invasive endoscopic maxillary sinus lifting and immediate implant placement: A case report
Mudalal M, Sun XL, Li X, Fang J, Qi ML, Wang J, Du LY, Zhou YM

ABOUT COVER

Editorial Board Member of *World Journal of Clinical Cases*, Abdullah Ozkok, MD, Associate Professor, Department of Internal Medicine and Nephrology, University of Health Sciences, Umraniye Training and Research Hospital, Istanbul, Turkey

AIMS AND SCOPE

World Journal of Clinical Cases (*World J Clin Cases*, *WJCC*, online ISSN 2307-8960, DOI: 10.12998) is a peer-reviewed open access academic journal that aims to guide clinical practice and improve diagnostic and therapeutic skills of clinicians.

The primary task of *WJCC* is to rapidly publish high-quality Case Report, Clinical Management, Editorial, Field of Vision, Frontier, Medical Ethics, Original Articles, Meta-Analysis, Minireviews, and Review, in the fields of allergy, anesthesiology, cardiac medicine, clinical genetics, clinical neurology, critical care, dentistry, dermatology, emergency medicine, endocrinology, family medicine, gastroenterology and hepatology, etc.

INDEXING/ABSTRACTING

The *WJCC* is now indexed in PubMed, PubMed Central, Science Citation Index Expanded (also known as SciSearch®), and Journal Citation Reports/Science Edition. The 2018 Edition of Journal Citation Reports cites the 2017 impact factor for *WJCC* as 1.931 (5-year impact factor: N/A), ranking *WJCC* as 60 among 154 journals in Medicine, General and Internal (quartile in category Q2).

RESPONSIBLE EDITORS FOR THIS ISSUE

Responsible Electronic Editor: Yun-Xiaojuan Wu Proofing Editorial Office Director: Jin-Lei Wang

NAME OF JOURNAL

World Journal of Clinical Cases

ISSN

ISSN 2307-8960 (online)

LAUNCH DATE

April 16, 2013

FREQUENCY

Semimonthly

EDITORS-IN-CHIEF

Dennis A Bloomfield, Sandro Vento

EDITORIAL BOARD MEMBERS

<https://www.wjgnet.com/2307-8960/editorialboard.htm>

EDITORIAL OFFICE

Jin-Lei Wang, Director

PUBLICATION DATE

May 26, 2019

COPYRIGHT

© 2019 Baishideng Publishing Group Inc

INSTRUCTIONS TO AUTHORS

<https://www.wjgnet.com/bpg/gerinfo/204>

GUIDELINES FOR ETHICS DOCUMENTS

<https://www.wjgnet.com/bpg/GerInfo/287>

GUIDELINES FOR NON-NATIVE SPEAKERS OF ENGLISH

<https://www.wjgnet.com/bpg/gerinfo/240>

PUBLICATION MISCONDUCT

<https://www.wjgnet.com/bpg/gerinfo/208>

ARTICLE PROCESSING CHARGE

<https://www.wjgnet.com/bpg/gerinfo/242>

STEPS FOR SUBMITTING MANUSCRIPTS

<https://www.wjgnet.com/bpg/GerInfo/239>

ONLINE SUBMISSION

<https://www.f6publishing.com>



F-18 fluorodeoxyglucose positron emission tomography/computed tomography image of gastric mucormycosis mimicking advanced gastric cancer: A case report

Bong-Il Song

ORCID number: Bong-Il Song (0000-0002-3106-6112).

Author contributions: Song BI edited the all manuscript.

Supported by National Research Foundation of Korea (NRF) grant funded by the Korea government (MSIP), No. 2017R1C1B5076640.

Institutional review board statement: This case report was reviewed and approved by the Institutional Review Board of Dongsan Medical Center Keimyung University (IRB No. 2018-04-021).

Informed consent statement: Informed consent was obtained from the patient.

Conflict-of-interest statement: Song BI declare no conflicts of interests.

CARE Checklist (2016) statement: The authors have read the CARE Checklist (2016), and the manuscript was prepared and revised according to the CARE Checklist (2016).

Open-Access: This article is an open-access article which was selected by an in-house editor and fully peer-reviewed by external reviewers. It is distributed in accordance with the Creative Commons Attribution Non Commercial (CC BY-NC 4.0) license, which permits others to distribute, remix, adapt, build upon this work non-commercially, and license their derivative works on different terms, provided the

Bong-Il Song, Department of Nuclear Medicine, Dongsan Medical Center, Keimyung University School of Medicine, Daegu 41932, South Korea

Corresponding author: Bong-Il Song, MD, Assistant Professor, Department of Nuclear Medicine, Dongsan Medical Center, Keimyung University School of Medicine, 56 Dalseong-ro, Jung-gu, Daegu 41931, South Korea. song@dsmc.or.kr
Telephone: +82-53-250-7023
Fax: +82-53-250-8695

Abstract

BACKGROUND

Mucormycosis is a very rare fungal infection, and its prognosis is poor. Most common sites of infection are the sinuses, lung, or skin, and gastric involvement is uncommon. The standard antifungal therapy is the treatment of choice for gastric mucormycosis. However, the symptoms of gastric mucormycosis are varied and the early diagnosis is not easy.

CASE SUMMARY

I report a 53-year-old alcoholic man, who was admitted due to epigastric pain. The upper gastrointestinal endoscopy revealed a huge ulcer lesion in the stomach, which was suspected to be gastric cancer. F-18 fluorodeoxyglucose positron emission tomography/computed tomography (F-18 FDG PET/CT) showed diffusely intense FDG uptake at the ulcer lesion of the stomach, and several enlarged hypermetabolic lymph nodes were noted at the left gastric chain. Although, endoscopy and F-18 FDG PET/CT findings suggested advanced gastric cancer with regional lymph node metastases, there was no cancer cells in the biopsy results and multiple fungal hyphae were noted in the periodic acid-Schiff stained image.

CONCLUSION

He was diagnosed with gastric mucormycosis and successfully underwent amphotericin B and posaconazole treatment.

Key words: F-18 fluorodeoxyglucose; Positron emission tomography; Mucormycosis; Amphotericin B; Gastric cancer; Case report

©The Author(s) 2019. Published by Baishideng Publishing Group Inc. All rights reserved.

original work is properly cited and the use is non-commercial. See: <http://creativecommons.org/licenses/by-nc/4.0/>

Manuscript source: Unsolicited manuscript

Received: December 29, 2018

Peer-review started: December 29, 2018

First decision: March 10, 2019

Revised: March 21, 2019

Accepted: March 26, 2019

Article in press: March 26, 2019

Published online: May 26, 2019

P-Reviewer: Eleftheriadis NP, Tsolakis AV

S-Editor: Dou Y

L-Editor: A

E-Editor: Wu YXJ



Core tip: Gastric mucormycosis is very rare, and there have been no reports on the F-18 fluorodeoxyglucose positron emission tomography/computed tomography (F-18 FDG PET/CT) finding of gastric mucormycosis. Since, endoscopic findings of gastric mucormycosis reveal ulcer margin with inflammatory/necrotic debris and hemorrhagic clots, F-18 FDG PET/CT of gastric mucormycosis reveal increased FDG uptake in the infected site. Additionally, reactive enlarged hypermetabolic lymph nodes in the perigastric chain could be observed. In this regard, it was difficult to differentiate gastric mucormycosis and gastric cancer by endoscopic findings and radiologic examinations. Therefore, careful consideration of clinical manifestations and precise diagnosis are necessary for optimal treatment of gastric mucormycosis.

Citation: Song BI. F-18 fluorodeoxyglucose positron emission tomography/computed tomography image of gastric mucormycosis mimicking advanced gastric cancer: A case report. *World J Clin Cases* 2019; 7(10): 1155-1160

URL: <https://www.wjnet.com/2307-8960/full/v7/i10/1155.htm>

DOI: <https://dx.doi.org/10.12998/wjcc.v7.i10.1155>

INTRODUCTION

Mucormycosis is a life-threatening angioinvasive infection caused by fungi in the order Mucorales. It has the characteristic of invading the blood vessels; thus, the prognosis is known to be very poor. Like other fungal infections, patients with mucormycosis may have several predisposing factors associated with immunosuppressive conditions such as diabetes or long-term corticosteroid use. Additionally, several studies reported that chronic alcoholism can be one of the important predisposing conditions^[1].

The three common sites of mucormycosis are the sinuses (39%), lung (24%), and skin (19%). Mucormycosis less commonly occurs in the gastrointestinal (GI) tract (about 7%)^[2]. In the GI tract, mucormycosis most commonly affects the stomach followed by the colon and ileum^[2]. Pathogens are known to be acquired by ingestion of contaminated foods.

The treatment for gastric mucormycosis is amphotericin B, posaconazole, and adjuvant surgical removal of the "fungal ball". The mortality rate is known to be extremely high, which is about 85%^[3]. One of the major causes of gastric mucormycosis mortality is extremely delayed diagnoses; only 25% of patients with GI mucormycosis are diagnosed before death. Recently, several studies emphasized the importance of early diagnosis, which can affect the treatment direction and improve prognosis^[4].

It is difficult to diagnose gastric mucormycosis because confirmation is possible only through histologic examination. In addition, some cases have been misdiagnosed as cancer during the initial screening due to their radiologic and endoscopic similarities. Several studies have reported the detection of mucormycosis in other organs using F-18 fluorodeoxyglucose positron emission tomography/computed tomography (F-18 FDG PET/CT); however, there have been no reports on the F-18 FDG PET/CT finding of gastric mucormycosis. We present an interesting case of a 53-year-old man who underwent F-18 FDG PET/CT and were initially suspected with advanced gastric cancer but finally confirmed as gastric mucormycosis.

CASE PRESENTATION

Chief complaints

A 53-year-old man presented with a 1-wk history of epigastric pain. He also had complaints of bloody vomitus and melena.

History of present illness

Three weeks prior to this hospital admission, abdominal discomfort and nausea had developed. He had visited the local hospital and received conservative treatment. However, the symptoms were not relieved after medication. A week ago, epigastric pain had developed, and he had vomited reddish blood on the day before admission. For further evaluation, the patient was transferred to this hospital.

History of past illness

He had no history of surgery and past medical history.

Personal and family history

The patient had a history of severe alcohol abuse and a 20 pack-year history of smoking. Otherwise, there were no special circumstances in family history.

Physical examination upon admission

The physical examination revealed no palpable abdominal mass or signs of peritoneal irritation. His blood pressure was 153/120 mmHg, and pulse rate was 115/min. He appeared chronically ill.

Laboratory examinations

The laboratory testing showed a normal white blood cell count, blood glucose, creatinine, coagulation profile, and serum electrolytes except low hemoglobin was present with a level of 10.5 g/dL (normal range: 13.5-17.5 g/dL).

Imaging examinations

The patient's upper GI endoscopy revealed diffuse erythema and edema of the gastric wall. Furthermore, a huge ulcer was detected in the posterior wall of the lower body (Figure 1), which was suspicious for Borrmann type II gastric cancer; therefore, patient underwent biopsy and additional studies for evaluation. Moreover, the contrast-enhanced abdominal CT showed a huge ulcer within the same lesion with diffuse wall thickening (Figure 2A). The margin of the pancreas was unclear, and multiple enlarged lymph nodes were observed in the left gastric and gastroepiploic chain (Figure 2B).

Because these findings strongly suggested gastric cancer at advanced stage, F-18 FDG PET/CT was performed for further evaluation. In the maximum intensity projection image, there was uneven FDG uptake on the stomach, but no other distant metastasis was seen (Figure 3A). Trans-axial F-18 FDG PET/CT image showed diffusely intense FDG uptake at the ulcer lesion (Figure 3B). In addition, several enlarged hypermetabolic lymph nodes were noted at the left gastric chain (Figure 3C). The clinical impression was gastric cancer with regional lymph node metastases.

However, there were no malignant cells and only severe inflammation was seen in the first biopsy result. The patient underwent secondary endoscopic biopsy for a pathologic confirmation. However, no cancer cells were found, and multiple fungal hyphae were noted in the periodic acid-Schiff (PAS)-stained image. The results indicated mucormycosis based on the characteristics of the hyphae, which showed a 90-degree angle branching with no visible septa (Figure 4).

FINAL DIAGNOSIS

The final diagnosis of the presented case is gastric mucormycosis. Unfortunately, the type of mucormycosis remained undetermined.

TREATMENT

The patient was treated with amphotericin B, given by injection, for 20 d and adjuvant posaconazole for 2 mo.

OUTCOME AND FOLLOW-UP

The follow-up endoscopy finding showed marked improvement of previous infected lesions and only mild redness of the gastric wall was observed (Figure 5). In addition, the follow-up CT showed much-improved state of previous gastric mucormycosis lesion and decreased size and number of previous enlarged lymph nodes (Figure 6). Thereafter, the therapy was terminated without further treatment.

DISCUSSION

With regard to the diagnosis, gastric mucormycosis has no specific finding on radiologic examination. In contrast-enhanced CT image, irregular thickening of the gastric folds can be seen with ulcer forming process^[3]. In endoscopic examination,

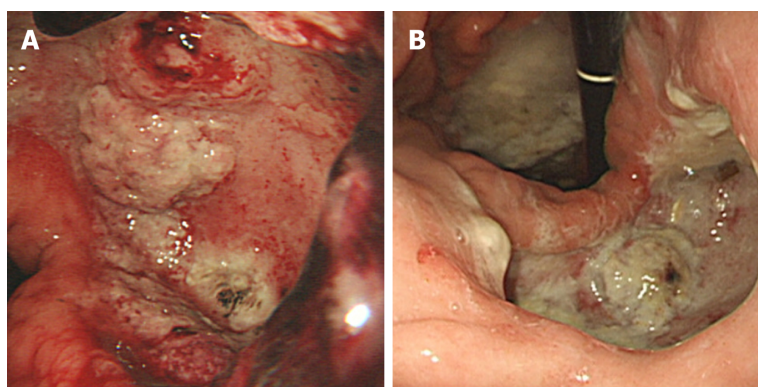


Figure 1 Upper gastrointestinal endoscopy images. This reveals a huge ulcer in the posterior wall of the stomach. The ulcer lesion was suspicious for Borrmann type II gastric cancer.

gastric mucormycosis appears as necrotizing ulcers combined with discoloration or blood clot. Because of the necrotizing tissues, gastric mucormycosis is often misdiagnosed as gastric cancer^[6,7].

Diagnostic confirmation of gastric mucormycosis can be made only through histological examination. Fungal infections are best observed in Gomori methenamine silver or PAS stain. The pathologic finding is large and non-septa hyphae with 90-degree angle branching. Additionally, the three subtypes of gastric mucormycosis are detected through histological examination. The first type only exhibits the formation of a colony without invading the surrounding tissue. The second type involves infiltration into the surrounding tissue as a presenting case. Lastly, the third type involves vascular invasion with presence of hyphae in the vessel lumen^[8]. The vascular invasion type is frequently associated with poor prognosis.

Although several studies have reported on the F-18 FDG PET/CT findings of patients with mucormycosis, the F-18 FDG PET/CT findings of patients with gastric mucormycosis has not been reported. Increased FDG uptake at the infection focus was noted at the infection site, but there was no specific finding^[9]. The F-18 FDG PET/CT finding of gastric mucormycosis in this patient also showed increased FDG uptake at the infection site. Therefore, it was difficult to differentiate gastric mucormycosis and gastric cancer by F-18 FDG PET/CT. However, as the importance of early diagnosis has been increasingly emphasized recently, some studies revealed that F-18 FDG PET/CT can be used to detect active metabolic changes reflecting inflammatory cell activity before the onset of anatomical abnormalities^[10]. Furthermore, F-18 FDG PET/CT can give functional information, which can be useful for the assessment of the overall therapeutic response^[11].

CONCLUSION

The case report suggests that there is no definite method to completely differentiate mucormycosis and malignant tumors using F-18 FDG PET/CT. However, F-18 FDG PET/CT may contribute to the early diagnosis, assessment of disease extent, and evaluation of response to therapy in patients with gastric mucormycosis.

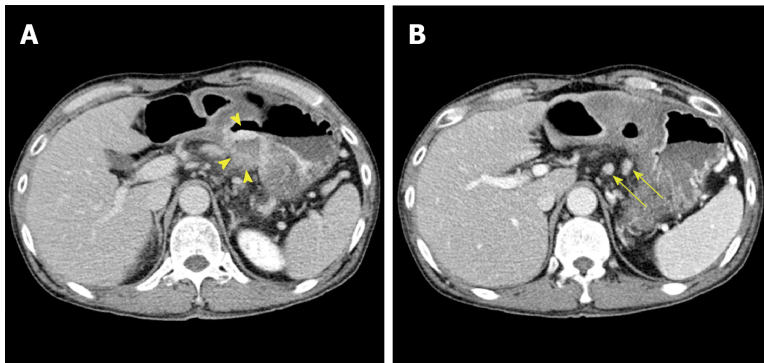


Figure 2 Contrast-enhanced abdominal computed tomography images. A: A huge ulcer lesion with diffuse wall thickening was detected in the posterior wall of the lower body of the stomach (yellow arrow head); B: Multiple enlarged left gastric lymph nodes were noted (yellow arrow).

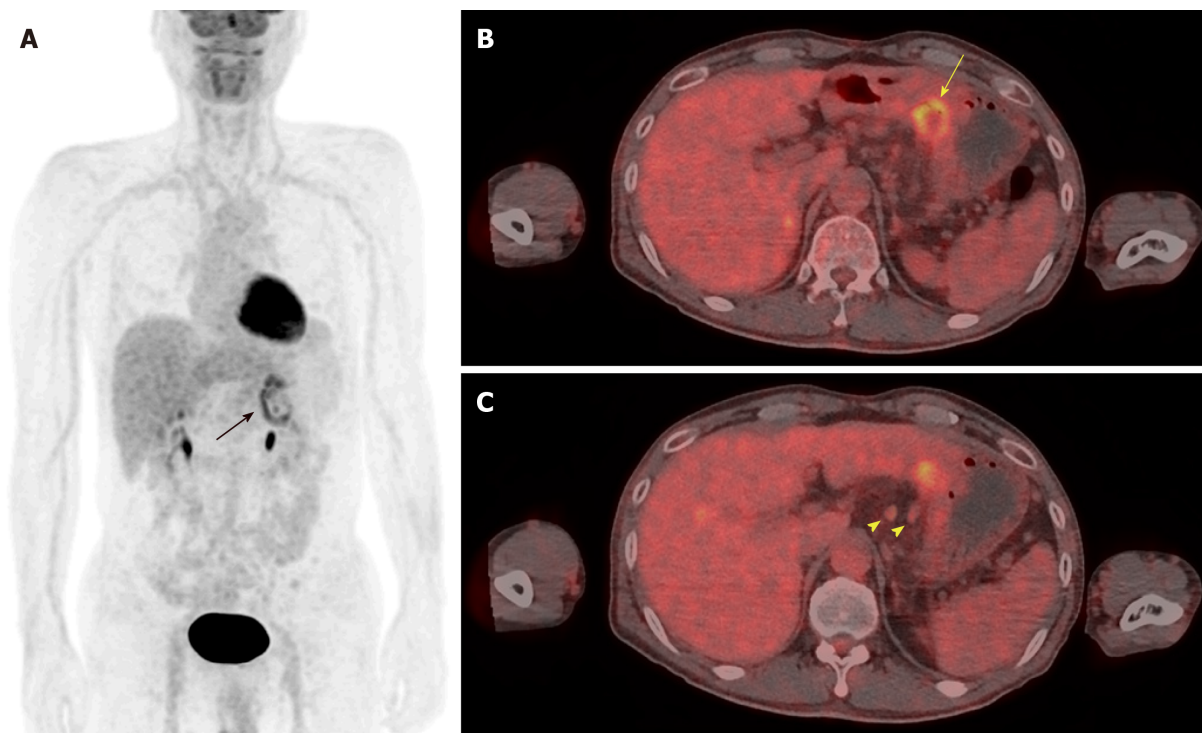


Figure 3 F-18 fluorodeoxyglucose positron emission tomography/computed tomography images. A: The maximum intensity projection image shows uneven uptake on the stomach (black arrow); B: Axial scan shows increased uptake in the posterior wall of the lower body of the stomach (yellow arrow); C: Several enlarged hypermetabolic lymph nodes were seen at the left gastric chain (yellow arrow head).

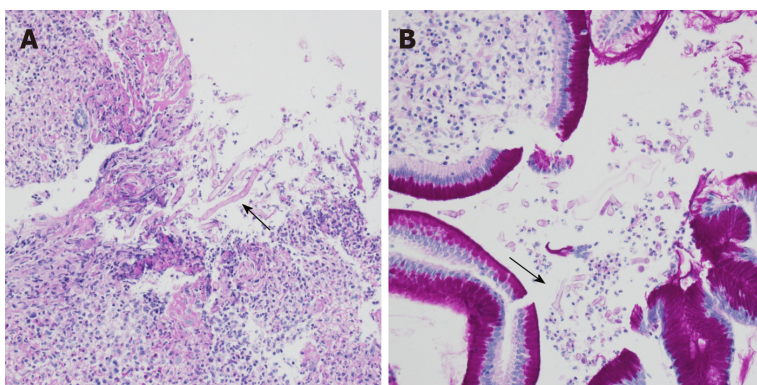


Figure 4 Periodic acid-Schiff stain. A, B: Multiple fungal hyphae with positive periodic acid-Schiff staining were observed (black arrow).

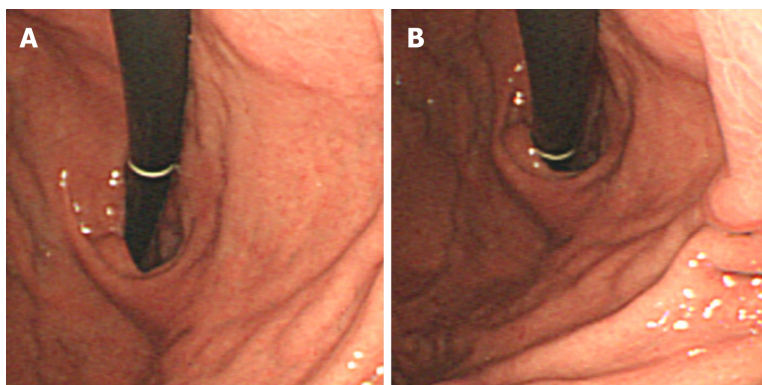


Figure 5 Follow-up upper gastrointestinal endoscopy images. A, B: The follow-up endoscopic finding reveals marked improvement of previous mucormycosis lesion.

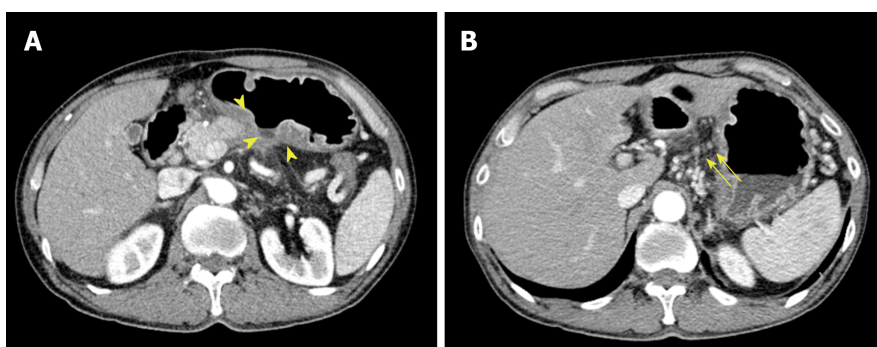


Figure 6 Follow-up contrast-enhanced abdominal computed tomography images. A: Previous mucormycosis lesion in the posterior wall of the lower body of the stomach showed much-improved state (yellow arrow head); B: Only small left gastric lymph nodes was observed (yellow arrow).

REFERENCES

- 1 **Ho YH**, Wu BG, Chen YZ, Wang LS. Gastric Mucormycosis in an Alcoholic with Review of the Literature. *Tzu Chi Med J* 2007; **19**: 169–172 [DOI: [10.1016/S1016-3190\(10\)60011-0](https://doi.org/10.1016/S1016-3190(10)60011-0)]
- 2 **Petrikos G**, Skiada A, Lortholary O, Roilides E, Walsh TJ, Kontoyiannis DP. Epidemiology and clinical manifestations of mucormycosis. *Clin Infect Dis* 2012; **54** Suppl 1: S23-S34 [PMID: [22247442](https://pubmed.ncbi.nlm.nih.gov/22247442/) DOI: [10.1093/cid/cir866](https://doi.org/10.1093/cid/cir866)]
- 3 **Roden MM**, Zaoutis TE, Buchanan WL, Knudsen TA, Sarkisova TA, Schaufele RL, Sein M, Sein T, Chiou CC, Chu JH, Kontoyiannis DP, Walsh TJ. Epidemiology and outcome of zygomycosis: a review of 929 reported cases. *Clin Infect Dis* 2005; **41**: 634–653 [PMID: [16080086](https://pubmed.ncbi.nlm.nih.gov/16080086/) DOI: [10.1086/432579](https://doi.org/10.1086/432579)]
- 4 **Walsh TJ**, Skiada A, Cornely OA, Roilides E, Ibrahim A, Zaoutis T, Groll A, Lortholary O, Kontoyiannis DP, Petrikos G. Development of new strategies for early diagnosis of mucormycosis from bench to bedside. *Mycoses* 2014; **57** Suppl 3: 2–7 [PMID: [25475924](https://pubmed.ncbi.nlm.nih.gov/25475924/) DOI: [10.1111/myc.12249](https://doi.org/10.1111/myc.12249)]
- 5 **Samet JD**, Horton KM, Fishman EK. Invasive gastric mucormycosis: CT findings. *Emerg Radiol* 2008; **15**: 349–351 [PMID: [18071767](https://pubmed.ncbi.nlm.nih.gov/18071767/) DOI: [10.1007/s10140-007-0689-7](https://doi.org/10.1007/s10140-007-0689-7)]
- 6 **Thomson SR**, Bade PG, Taams M, Chrystal V. Gastrointestinal mucormycosis. *Br J Surg* 1991; **78**: 952–954 [PMID: [1913115](https://pubmed.ncbi.nlm.nih.gov/1913115/) DOI: [10.1002/bjs.1800780819](https://doi.org/10.1002/bjs.1800780819)]
- 7 **El Hachem G**, Chamseddine N, Saidy G, Choueiry C, Afif C. Successful Nonsurgical Eradication of Invasive Gastric Mucormycosis. *Clin Lymphoma Myeloma Leuk* 2016; **16** Suppl: S145–S148 [PMID: [27521312](https://pubmed.ncbi.nlm.nih.gov/27521312/) DOI: [10.1016/j.clml.2016.02.020](https://doi.org/10.1016/j.clml.2016.02.020)]
- 8 **Feldman M**, Friedman L, Brandt L. *Sleisenger and Fordtran's Gastrointestinal and Liver Disease* 2016; 875
- 9 **Sharma P**, Mukherjee A, Karunanithi S, Bal C, Kumar R. Potential role of 18F-FDG PET/CT in patients with fungal infections. *AJR Am J Roentgenol* 2014; **203**: 180–189 [PMID: [24951213](https://pubmed.ncbi.nlm.nih.gov/24951213/) DOI: [10.2214/AJR.13.11712](https://doi.org/10.2214/AJR.13.11712)]
- 10 **Altini C**, Niccoli Asabella A, Ferrari C, Rubini D, Dicuonzo F, Rubini G. (18)F-FDG PET/CT contribution to diagnosis and treatment response of rhino-orbital-cerebral mucormycosis. *Hell J Nucl Med* 2015; **18**: 68–70 [PMID: [25679078](https://pubmed.ncbi.nlm.nih.gov/25679078/) DOI: [10.1967/s002449910167](https://doi.org/10.1967/s002449910167)]
- 11 **Liu Y**, Wu H, Huang F, Fan Z, Xu B. Utility of 18F-FDG PET/CT in diagnosis and management of mucormycosis. *Clin Nucl Med* 2013; **38**: e370–e371 [PMID: [23531773](https://pubmed.ncbi.nlm.nih.gov/23531773/) DOI: [10.1097/RLU.0b013e3182867d13](https://doi.org/10.1097/RLU.0b013e3182867d13)]



Published By Baishideng Publishing Group Inc
7041 Koll Center Parkway, Suite 160, Pleasanton, CA 94566, USA
Telephone: +1-925-2238242
Fax: +1-925-2238243
E-mail: bpgoffice@wjgnet.com
Help Desk: <https://www.f6publishing.com/helpdesk>
<https://www.wjgnet.com>

