

World Journal of *Gastrointestinal Oncology*

World J Gastrointest Oncol 2019 April 15; 11(4): 270-347



**REVIEW**

- 270** Identification of genomic features associated with immunotherapy response in gastrointestinal cancers
He Y, Liu ZX, Jiang ZH, Wang XS

ORIGINAL ARTICLE**Basic Study**

- 281** Up-regulation of tumor necrosis factor- α pathway survival genes and of the receptor TNFR2 in gastric cancer
Rossi AFT, Contiero JC, Manoel-Caetano FDS, Severino FE, Silva AE

Retrospective Cohort Study

- 295** Predictive factors of histological response of colorectal liver metastases after neoadjuvant chemotherapy
Serayssol C, Maulat C, Breibach F, Mokrane FZ, Selves J, Guimbaud R, Otal P, Suc B, Berard E, Muscari F
- 310** Iodine-125 implantation with transjugular intrahepatic portosystemic shunt for main portal vein tumor thrombus
Zhang Y, Wu YF, Yue ZD, Zhao HW, Wang L, Fan ZH, He FL, Wang T, Liu FQ

Retrospective Study

- 322** Validated model for prediction of recurrent hepatocellular carcinoma after liver transplantation in Asian population
Ma KW, She WH, Chan ACY, Cheung TT, Fung JYY, Dai WC, Lo CM, Chok KSH
- 335** Significance of HER2 protein expression and *HER2* gene amplification in colorectal adenocarcinomas
Wang XY, Zheng ZX, Sun Y, Bai YH, Shi YF, Zhou LX, Yao YF, Wu AW, Cao DF

ABOUT COVER

Editorial Board Member of *World Journal of Gastrointestinal Oncology*,
Adriana Ciocalteu, MD, PhD, Assistant Professor, Research Associate, Staff
Physician, Teaching Assistant, Department of Gastroenterology, Research
Center of Gastroenterology and Hepatology of Craiova,
University of Medicine and Pharmacy of Craiova, Craiova 200349, Romania

AIMS AND SCOPE

World Journal of Gastrointestinal Oncology (*World J Gastrointest Oncol*, *WJGO*,
online ISSN 1948-5204, DOI: 10.4251) is a peer-reviewed open access
academic journal that aims to guide clinical practice and improve diagnostic
and therapeutic skills of clinicians.

The *WJGO* covers topics concerning carcinogenesis, tumorigenesis,
metastasis, diagnosis, prevention, prognosis, clinical manifestations,
nutritional support, etc. The current columns of *WJGO* include editorial,
frontier, field of vision, review, original articles, case report.

We encourage authors to submit their manuscripts to *WJGO*. We will give
priority to manuscripts that are supported by major national and
international foundations and those that are of great clinical significance.

INDEXING/ABSTRACTING

The *WJGO* is now indexed in Science Citation Index Expanded (also known as
SciSearch®), PubMed, and PubMed Central. The 2018 edition of Journal Citation
Reports® cites the 2017 impact factor for *WJGO* as 3.140 (5-year impact factor: 3.228),
ranking *WJGO* as 39 among 80 journals in gastroenterology and hepatology (quartile in
category Q2), and 114 among 222 journals in oncology (quartile in category Q3).

**RESPONSIBLE EDITORS
FOR THIS ISSUE**

Responsible Electronic Editor: Yun-Xiaojuan Wu Proofing Editorial Office Director: Jin-Lei Wang

NAME OF JOURNAL

World Journal of Gastrointestinal Oncology

ISSN

ISSN 1948-5204 (online)

LAUNCH DATE

February 15, 2009

FREQUENCY

Monthly

EDITORS-IN-CHIEF

Monjur Ahmed, Rosa M Jimenez Rodriguez, Pashtoon Murtaza Kasi

EDITORIAL BOARD MEMBERS

<https://www.wjgnet.com/1948-5204/editorialboard.htm>

EDITORIAL OFFICE

Jin-Lei Wang, Director

PUBLICATION DATE

April 15, 2019

COPYRIGHT

© 2019 Baishideng Publishing Group Inc

INSTRUCTIONS TO AUTHORS

<https://www.wjgnet.com/bpg/gerinfo/204>

GUIDELINES FOR ETHICS DOCUMENTS

<https://www.wjgnet.com/bpg/GerInfo/287>

GUIDELINES FOR NON-NATIVE SPEAKERS OF ENGLISH

<https://www.wjgnet.com/bpg/gerinfo/240>

PUBLICATION MISCONDUCT

<https://www.wjgnet.com/bpg/gerinfo/208>

ARTICLE PROCESSING CHARGE

<https://www.wjgnet.com/bpg/gerinfo/242>

STEPS FOR SUBMITTING MANUSCRIPTS

<https://www.wjgnet.com/bpg/GerInfo/239>

ONLINE SUBMISSION

<https://www.f6publishing.com>



Retrospective Cohort Study

Iodine-125 implantation with transjugular intrahepatic portosystemic shunt for main portal vein tumor thrombus

Yue Zhang, Yi-Fan Wu, Zhen-Dong Yue, Hong-Wei Zhao, Lei Wang, Zhen-Hua Fan, Fu-Liang He, Tao Wang, Fu-Quan Liu

ORCID number: Yue Zhang (0000-0001-6295-369X); Yi-Fan Wu (0000-0003-2709-2729); Zhen-Dong Yue (0000-0001-5403-8336); Hong-Wei Zhao (0000-0001-5657-1839); Lei Wang (0000-0002-4374-059X); Zhen-Hua Fan (0000-0001-5417-1997); Fu-Liang He (0000-0003-1643-1465); Tao Wang (0000-0002-2714-9804); Fu-Quan Liu (0000-0003-1972-7712).

Author contributions: Liu FQ designed the research; Wu YF, Yue ZD, Zhao HW, Wang L, Fan ZH and He FL performed the research; Zhang Y analyzed the data and wrote the paper; Wu YF and Liu FQ critically revised the manuscript for important intellectual content.

Supported by the Beijing Municipal Science and Technology Commission project, the Capital of the Public Health Cultivation - Transcatheter Implantation combined with TACE/TAE in the treatment of portal vein tumor thrombus in clinical research, No. Z171100000417031.

Institutional review board

statement: All patients involved in this study gave their informed consent. Institutional review board approval of our hospital was obtained for this study.

Informed consent statement:

Written informed consent was obtained from all subjects (patients) in this study.

Conflict-of-interest statement: The

Yue Zhang, Fu-Quan Liu, Department of Interventional Therapy, Peking University Ninth School of Clinical Medicine, Beijing Shijitan Hospital and Capital Medical University, Beijing 100038, China

Yi-Fan Wu, Zhen-Dong Yue, Hong-Wei Zhao, Lei Wang, Zhen-Hua Fan, Fu-Liang He, Department of Interventional Therapy, Beijing Shijitan Hospital and Capital Medical University, Beijing 100038, China

Tao Wang, Department of Interventional Therapy, The affiliated Yantai Yuhuangding Hospital of Qingdao University, No.20 Yuhuangding East Road, Yantai 264000, Shandong Province, China

Corresponding author: Fu-Quan Liu, BCPS, MD, Professor, Department of Interventional Therapy, Peking University Ninth School of Clinical Medicine, Beijing Shijitan Hospital and Capital Medical University, No. 10 Tie Yi Road, Yangfangdian, Haidian District, Beijing 100010, China. lfuquan@aliyun.com

Telephone: +86-13701179758

Abstract

BACKGROUND

Main portal vein tumor thrombus (MPVTT), which has a high incidence, is the major complication of terminal liver cancer. The occurrence of MPVTT is always a negative prognostic factor for patients with hepatocellular carcinoma (HCC). Therefore, attention should be paid to the treatment of MPVTT and its complications.

AIM

To evaluate the efficacy of transarterial chemoembolization/transarterial embolization (TACE/TAE)+¹²⁵I seeds implantation with transjugular intrahepatic portosystemic shunt (TIPS) in treating MPVTT and its complications.

METHODS

From January 2007 to March 2015, 85 consecutive patients with MPVTT were nonrandomly assigned to undergo treatment with TACE/TAE + TIPS and ¹²⁵I implantation (TIPS-¹²⁵I group) or TACE/TAE + TIPS only (TIPS only group) in Beijing Shijitan Hospital, and all clinical data were collected. During 24 mo follow-up, the incidence of overall survival, stent stenosis and symptom recurrence was analyzed to evaluate the efficacy of TIPS-¹²⁵I.

authors of this manuscript declare no relationships with any companies, whose products or services may be related to the subject matter of the article.

STROBE statement: The STROBE Statement has been adopted.

Open-Access: This article is an open-access article which was selected by an in-house editor and fully peer-reviewed by external reviewers. It is distributed in accordance with the Creative Commons Attribution Non Commercial (CC BY-NC 4.0) license, which permits others to distribute, remix, adapt, build upon this work non-commercially, and license their derivative works on different terms, provided the original work is properly cited and the use is non-commercial. See: <http://creativecommons.org/licenses/by-nc/4.0/>

Manuscript source: Unsolicited manuscript

Received: January 13, 2019

Peer-review started: January 14, 2019

First decision: January 26, 2019

Revised: February 11, 2019

Accepted: March 12, 2019

Article in press: March 12, 2019

Published online: April 15, 2019

P-Reviewer: Ashley S, Klaiber U, Wang XS

S-Editor: Ji FF

L-Editor: A

E-Editor: Wu YXJ



RESULTS

During 24 mo follow-up of all patients, we collected data at 6, 12 and 24 mo. The rates of survival were 80%, 45%, and 20%, respectively, in the TIPS-¹²⁵I group, whereas those in the TIPS only group were 64.4%, 24.4%, and 4.4%, respectively ($P < 0.05$). The rates of symptom recurrence were 7.5%, 22.5%, and 35%, respectively, in the TIPS-¹²⁵I group, whereas those in the TIPS only group were 31.1%, 62.2%, and 82.2% ($P < 0.05$). The rates of stent restenosis were 12.5%, 27.5%, and 42.5%, respectively, in the TIPS-¹²⁵I group, and 42.2%, 68.9%, and 84.4%, respectively, in the TIPS only group ($P < 0.05$). TIPS-¹²⁵I was found to be significantly favorable in treating MPVTT and its complications in patients with HCC.

CONCLUSION

TACE/TAE+¹²⁵I combined with TIPS is effective in treating MPVTT and its complications, improving quality of life of patients and reducing mortality.

Key words: Iodine-125; Transjugular intrahepatic portosystemic shunt; Main portal vein tumor thrombus; Metastasis; Portal hypertension

©The Author(s) 2019. Published by Baishideng Publishing Group Inc. All rights reserved.

Core tip: ¹²⁵I implantation combined with transjugular intrahepatic portosystemic shunt (TIPS) was used to treat patients with liver cancer and main portal vein tumor thrombus. This was a controlled study to assess the efficacy of ¹²⁵I implantation combined with TIPS. Transarterial chemoembolization/transarterial embolization plus ¹²⁵I combined with TIPS was effective in treating portal vein trunk tumor thrombus and its complications, improving quality of life of patients, and reducing mortality.

Citation: Zhang Y, Wu YF, Yue ZD, Zhao HW, Wang L, Fan ZH, He FL, Wang T, Liu FQ. Iodine-125 implantation with transjugular intrahepatic portosystemic shunt for main portal vein tumor thrombus. *World J Gastrointest Oncol* 2019; 11(4): 310-321

URL: <https://www.wjgnet.com/1948-5204/full/v11/i4/310.htm>

DOI: <https://dx.doi.org/10.4251/wjgo.v11.i4.310>

INTRODUCTION

The main portal vein tumor thrombus (MPVTT), which is the major complication of terminal hepatocellular carcinoma (HCC), is mainly caused by metastasis of tumor cells from the liver to the portal vein, seriously affecting the prognosis of liver cancer^[1,2]. The survival rate of a patient with liver cancer is 38% and 24% at 3 and 4 years, respectively^[3]. The incidence of PVTT caused by liver cancer is high^[4]. PVTT is classified into the following five grades: Vp0, no tumor thrombus in the PV; Vp1, presence of a tumor thrombus distal to, but not in the second-order branches of the PV; Vp2, presence of a tumor thrombus in the second-order branches of the PV; Vp3, presence of a tumor thrombus in the first-order branches of the PV; and Vp4, presence of a tumor thrombus in the main trunk of the PV or a branch contralateral to the primarily involved lobe (or both)^[5,6]. Methods to treat PVTT are surgery, chemotherapy, transarterial chemoembolization/transarterial embolization (TACE/TAE), radiofrequency ablation, interventional therapy, and RT^[7-10]. Liver transplantation is another curative treatment for end-stage liver disease; however, its application is limited by a shortage of donors and patient refusal. Treatment for MPVTT is the most difficult. Portal hypertension, which is caused by MPVTT, can lead to many complications, such as ascites and hemorrhage of the digestive tract. Transjugular intrahepatic portosystemic shunt (TIPS) has been widely performed for the treatment of portal hypertension, because it is minimally invasive and is reported to be effective^[11,12]. However, the survival rate of TIPS is less favorable because it cannot control progression of HCC.

In the past few years, the application of low-energy radionuclides, such as ¹²⁵I, has extended the indications of brachytherapy. Some studies have reported treatment of HCC with ¹²⁵I implantation. ¹²⁵I, which can reduce the volume of PVTT, has received widespread attention^[13]. However, the patients had class A or B liver function; the

first-grade branch of the PV was unobstructed; and the patients had no intractable ascites. In addition, ^{125}I was implanted as particle strands, which limited the number of particles implanted and the position of ^{125}I could not be adjusted. No study has investigated the clinical effect of ^{125}I combined with TIPS, in which ^{125}I is placed between the TT and stents. Thus, we aimed to compare the clinical efficacy of TACE/TAE+ ^{125}I combined with TIPS and TACE/TAE + TIPS only in the treatment of liver cancer patients with MPVTT and portal hypertension.

MATERIALS AND METHODS

Study design

This study was a nonrandomized controlled trial.

Inclusion criteria

The inclusion criteria were as follows: (1) age 18–70 years; (2) presence of HCC with MPVTT; (3) clear indications for TIPS treatment, such as gastrointestinal bleeding and ascites, in liver cancer patients with portal hypertension; and (4) clear indications for TACE or TAE treatment. The exclusion criteria were as follows: (1) suspected benign thrombosis; (2) active infection or serious disorders of the heart, lung, kidney, brain, and other vital organs; (3) pregnant or lactating women; (4) estimated lifetime < 3 mo; and (5) patients who could not cooperate during the treatment and observation period.

Patients

Eighty-five patients with MPVTT were nonrandomly assigned to undergo treatment with TIPS and catheter ^{125}I seed implantation (TIPS- ^{125}I group) or TIPS only (TIPS only group) between January 2007 and March 2015. HCC was confirmed according to the criteria of the American Association for the Study of Liver Diseases^[14]. PVTT was diagnosed by consensus by re-evaluation of all available computed tomography (CT) or magnetic resonance imaging (MRI) findings by two board-certified radiologists experienced in abdominal oncological imaging. Biopsies of the confirmed PVT were performed in 31 patients who were strongly suspected to have PVTT but did not have enough imaging evidence^[15].

There were 24 cases of hepatitis B cirrhosis, 13 hepatitis C cirrhosis, 15 alcoholic cirrhosis, 10 primary biliary cirrhosis, eight autoimmune liver cirrhosis, and 15 other causes. According to the preoperative Child–Pugh classification, there were 16 cases of class A, 36 class B, and 33 class C. There were 61 patients with hemorrhage of the digestive tract, 11 with chest and abdominal dropsy, and 13 with both (Table 1). The flow chart is shown in Figure 1.

Preoperative preparation

Before TIPS, liver function tests, blood coagulation tests, routine blood tests, electrocardiography, CT and/or MRI, color Doppler ultrasonography, and esophageal radiography were performed. Gastroscopy was also performed if necessary. Before TIPS, patients' coagulation function was corrected to a normal range. The TIPS-related concerns were explained to the patients and their family members who were later asked to sign the informed consent. This study was approved by the Institutional Review Board of Beijing Shijitan Hospital and conducted in accordance with all current ethical guidelines.

TIPS

First approach: Preoperative imaging showed that intrahepatic PV flow was completely or partially opened, and TT did not completely block the blood vessels. Extrahepatic portal vein (MPV) was more serious. TIPS was performed following femoral artery puncture and artery intubation of the superior mesenteric or splenic artery through femoral artery and contrast material injection through a catheter to locate the PV. Second approach: preoperative imaging showed that intrahepatic PV flow was blocked completely. TIPS was conducted after percutaneous transhepatic portal puncture was performed directly, and a catheter was placed in the PV as a marker.

Patients were assigned nonrandomly to undergo TIPS with covered stents (Fluency; Bard, Tempe, AZ, United States), under local anesthesia at the puncture site. A needle was passed from the right jugular vein to the inferior vena cava (IVC) or hepatic vein followed by a guidewire, and then the needle was passed to the PV to measure the free PV pressure (PVP). The difference between PVP and the IVC pressure represented the portosystemic gradient (PSG). The puncture set (RUPS-100; Cook, Ind, United States) was placed in the PV. Two guide wires were placed in the

Table 1 Baseline characteristics on patients

	TIPS- ¹²⁵ I group(n = 40)	TIPS only group(n = 45)	P-value
Gender			0.961
Male	27	30	
Female	13	15	
Average age	51 ± 4.3	49 ± 6.9	0.311
Etiology			0.923
Hepatitis B or C	24	28	
Alcoholic	8	7	
Cholestasis	4	6	
Other	4	4	
Child-Push classification			0.384
A	6	10	
B	20	16	
C	14	19	
Albumin (g/L)	30 ± 11	32 ± 11	0.915
Direct bilirubin (umol/L)	23.1 ± 16.9	21 ± 15	0.43
Alanine aminotransferase (U/L)	49 ± 36	53 ± 41	0.756
Aspartate aminotransferase (U/L)	42.5 ± 26.5	50.5 ± 37.5	0.318
Na ⁺	135.5 ± 15.5	138.5 ± 16.5	0.384
K ⁺	3.73 ± 1.27	3.49 ± 1.31	0.609
MELD score	11.96 ± 1.68	12.77 ± 2.49	0.187
Clinical symptoms			0.486
Hemorrhage	29	32	
Chest and/or abdominal dropsy	6	5	
Both	5	8	
First-grade branch of portal vein			0.571
Unobstructed	18	22	
Obstructed	22	23	

TIPS: Transjugular intrahepatic portosystemic shunt; MELD score: Model for end-stage liver disease score.

splenic vein or superior mesenteric vein, through the RUPS-100. The guide wire was placed, RUPS-100 was pulled out, a 4 F catheter was inserted into the distal vessel of the TT through one guide wire, and the RUPS-100 suit was reinserted into the PV via another guide wire. Next, a pigtail catheter was advanced through the RUPS-100 to the distal end of the splenic vein or superior mesenteric vein to measure PVP and radiography was conducted. The varicose veins were embolized with coils. An 8-mm balloon was used in every patient to dilate the liver parenchyma. Both 8-mm and 10-mm covered stents were implanted. The 10-mm stent was implanted at the distal end of the TT, covering the TT, whereas the 8-mm stent was implanted in the hepatic parenchyma and at the proximal end of the TT. Measurement of PVP before and after placement of TIPS allowed assessment of the success of the procedure. If combined with percutaneous liver puncture, after TIPS, the PV catheter was pulled out, and the hepatic puncture passage was strictly blocked during the pullout to avoid intraperitoneal or thoracic hemorrhage.

¹²⁵I implantation

In the TIPS-¹²⁵I group, the patients underwent TIPS similar to those in the TIPS only group. After the shunt was successfully established, the catheter between the stent and TT was linked to the particle release gun. The catheter was slowly retreated, and at the same time, the ¹²⁵I radioactive particles (Tong Fu, Inc., China) were released through the catheter up to the proximal end of the portal vein trunk and TT. The radioactive particles were arranged as neatly as possible in all TTs. After implantation, PVP was measured and portography was performed again. ¹²⁵I emitted characteristic electrons and photons through the recession of the electron capture surface. The electrons were absorbed by the titanium alloy wall of the sealed seeds of ¹²⁵I. The photons mainly emitted X rays of 27.4 and 31.4 keV as well as γ rays of 35.5 KeV. Pictures taken during the operation are shown in [Figure 2](#).

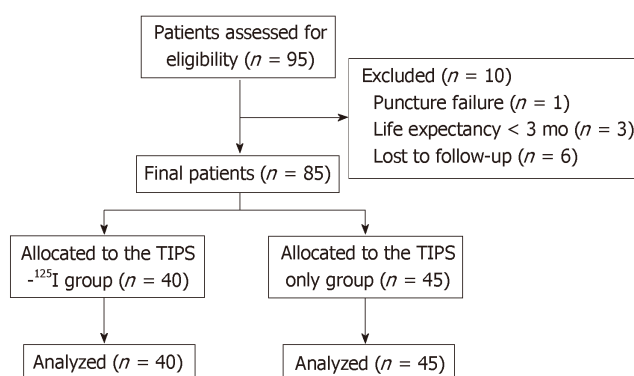


Figure 1 Study design and flow chart.

TACE/TAE procedure

Before or after TIPS, class A liver function patients were treated with TACE depending on the lesion size and its blood supply. The embolization agent of iodinated oil (3–30 mL) was used. The chemotherapeutic agents used included pirarubicin (10–20 mg) and hydroxycamptothecine (5–15 mg). Before or after TIPS, patients with class B or C liver function were treated with TAE to reduce liver dysfunction. The embolization agent of iodinated oil (5–25 mL) was used.

A needle was passed from the right or left femoral artery to the hepatic artery, and hepatic arteriography was performed. Then, a catheter was placed in the artery directly supplying blood to the cancerous lesion, as closely to the focus as possible, and the embolization and infusion of chemotherapeutic drugs were performed. The interval and number of treatments depended on the size of tumor lesion, artery status, and liver function. Treatment was usually done once every 1–6 mo. In the TIPS-¹²⁵I group, six and 34 patients were treated with TACE and TAE, respectively, whereas 10 and 35 patients were treated with TACE and TAE, respectively, in the TIPS only group, showing no significant difference ($P = 0.395$). For radiofrequency ablation, patients whose lesion was ≤ 5 cm and had a rich blood supply required TACE or TAE first and radiofrequency ablation after 3–5 d. Patients whose lesions were > 5 cm required TACE or TAE once or several times initially, and then radiofrequency ablation, when the imaging showed that the lesions had no blood supply from the hepatic artery, or the catheter could not enter into the artery of the lesions. Finally, all patients underwent radiofrequency ablation an average of 1.64 times.

Postoperative routine observation and treatment

Postoperative treatment consisted of sorafenib (Nexavar; Bayer, Leverkusen, Germany); at least 400 mg/d was recommended for ≥ 20 of the last 28 d after the first TACE procedure^[16]. Low molecular weight heparin (5000 IU, twice daily) was subcutaneously injected for 5 d, and then warfarin was administered for 1 yr. Intravenous injection of branched-chain amino acids and oral lactulose were also administered to prevent hepatic encephalopathy (HE). Coagulation function of each patient was examined every 15 d to ensure that the International Normalized Ratio ranged from 2 to 3. Complications, including abdominal cavity hemorrhage, HE, and hepatic failure, were monitored postoperatively.

Follow-up

Scheduled follow-up was performed at 6, 12 and 24 mo postoperatively. The recorded information included clinical manifestations, physical examination, shunt patency evaluation (through ultrasound and endoscopy), and laboratory tests. A telephone follow-up was performed to record the patient's condition and details of relevant clinical events.

Statistical analysis

Continuous variables are presented as the means \pm medians and were compared by independent sample t test or paired-sample t test accordingly. Categorical and ordinal variables are presented as frequencies or percentages and were compared using χ^2 test. Time-to-event outcomes were evaluated with Kaplan–Meier curves and log-rank test. Cox regression model was used to identify independent predictors. Unbalanced factors between groups were treated as covariates. Statistical analyses were performed using IBM SPSS version 22.0 (IBM, Chicago, IL, United States) and GraphPad Prism version 7.0 (La Jolla, CA, United States). Follow-up investigators and statisticians had

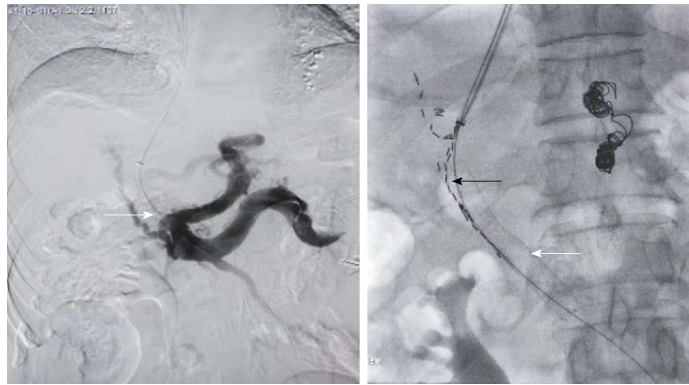


Figure 2 The two pictures in the process of the operation. This patient was with primary liver cancer and main portal vein tumor thrombus. The left picture showed the portal vein was blocked completely (the white arrow) by the tumor thrombus before the transjugular intrahepatic portosystemic shunt. The right picture showed the stent which was placed in the portal vein (the white arrow) and the ^{125}I which was placed between the stent and the tumor thrombus (the black arrow).

access to all the data and can vouch for the integrity of data analyses.

RESULTS

Baseline characteristics of patients

Eighty-five consecutive patients with MPVTT were divided into the TIPS- ^{125}I and TIPS only groups in Beijing Shijitan Hospital. All patients were followed up for 24 mo without any dropout. The baseline characteristics are presented in [Table 1](#).

Change in PSG before and after TIPS

The PSG in the TIPS- ^{125}I group decreased from 26.96 ± 5.73 to 13.1 ± 5.9 mmHg ($t = 20.88$, $P < 0.05$) after TIPS. In the TIPS only group, it decreased from 26.12 ± 5 to 12.6 ± 5.4 mmHg ($t = 22.94$, $P < 0.05$). The PSG before and after TIPS was significantly different between the two groups ([Table 2](#)). Preoperative PSG did not differ significantly between the two groups ($t = 1.103$, $P = 0.273$). After the operation, PSG still did not differ significantly between the groups ($t = 0.625$, $P = 0.534$) ([Figure 3](#)).

Time-to-event outcomes

The rates of symptom recurrence at 6, 12 and 24 mo were 7.5%, 22.5% and 35%, respectively, in the TIPS- ^{125}I group, whereas those in the TIPS only group were 31.1%, 62.2% and 82.2%, respectively, which were significantly different [log rank $P < 0.05$, hazard ratio (HR): 0.227, 95% confidence interval (CI): 0.129–0.401, [Figure 4A](#)] ([Table 3](#)). The rates of stent restenosis at 6, 12 and 24 mo were 12.5%, 27.5% and 42.5%, respectively, in the TIPS- ^{125}I group, whereas those in the TIPS only group were 42.2%, 68.9% and 84.4%, respectively, with significant differences (log rank $P < 0.05$, HR: 0.313, 95% CI: 0.182–0.536, [Figure 4B](#)) ([Table 3](#)). Median overall survival (OS) was 11.75 mo in the TIPS- ^{125}I group and 7.70 mo in the TIPS only group ($P = 0.009$). The rates of survival at 6, 12 and 24 mo were 80%, 45% and 20%, respectively, in the TIPS- ^{125}I group, whereas those in the TIPS only group were 64.4%, 24.4% and 4.4%, respectively, with significant differences (log rank $P < 0.05$, HR: 0.527, 95% CI: 0.332–0.834, [Figure 4C](#)) ([Table 3](#)). The survival rates also differed significantly depending on the Child–Pugh classification (log rank $P < 0.001$, [Figure 4D](#)).

Cox regression

Cox regression identified that etiology of liver cancer, clinical symptoms, albumin, aspartate aminotransferase, Na^+ , and K^+ had no significant effect on the survival rate. The treatment was the significant factor affecting survival rate ($P < 0.001$ HR: 4.178, 95% CI: 2.340–7.459). Child–Pugh classification, Model for End-Stage Liver Disease score, and direct bilirubin were also independent prognostic factors for survival ([Table 4](#)). The OS is shown in [Figure 5](#).

DISCUSSION

For patients with MPVTT, the ideal operation should improve survival rate, reduce

Table 2 The portosystemic pressure gradient before and after transjugular intrahepatic portosystemic shunt was significantly different in the two groups

	PPG before TIPS (mmHg)	PPG after TIPS (mmHg)	Number	t	df	P-value	SD of difference	SEM of difference	R squared
TIPS- ¹²⁵ I group	26.96 ± 5.73	13.1 ± 5.9	40	20.88	39	< 0.0001	4.367	0.6905	0.9179
TIPS only group	26.12 ± 5	12.6 ± 5.4	45	22.94	44	0.0002	4.089	0.6096	0.9228

TIPS: Transjugular intrahepatic portosystemic shunt; PPG: Portosystemic pressure gradient.

PVP, and avoid ascites and gastrointestinal bleeding. TIPS can achieve these, in addition to improving the survival rate of patients. ¹²⁵I has a good therapeutic effect and can improve the survival rate of patients^[17,18]. However, ¹²⁵I implantation documented in the literature was combined with percutaneous liver puncture or TACE in the form of particle strands, which had some disadvantages, such as limited number of particles being implanted. Moreover, the position of ¹²⁵I cannot be adjusted in these procedures. ¹²⁵I combined with TIPS can fix the particles between the stent and the TT without the need for particle strands. This approach allows for easier adjustment of the position of ¹²⁵I and the amount of ¹²⁵I being implanted. However, there has been no research on ¹²⁵I combined with TIPS for the treatment of PVTT. Thus, we investigated the efficacy of TIPS combined with ¹²⁵I in the treatment of PVTT. Overall, our study revealed the following outcomes: (1) ¹²⁵I combined with TIPS in the treatment of PVTT can significantly improve patients' survival rate and reduce stent restenosis and symptom recurrence; and (2) TIPS can reduce PVP and relieve clinical symptoms; and (3) TIPS combined with ¹²⁵I is safe and feasible.

TIPS can effectively reduce PVP and prevent the occurrence of portal hypertension and its complications. It can improve patients' quality of life and give them the opportunity to be treated for their primary lesion^[12,19-21]. However, it is unable to control the development of TT. Bettinger *et al.*^[21] studied a group of 40 HCC patients treated with TIPS, showed that TIPS implantation is an effective and safe treatment for portal hypertension in these patients, without significant impairment in liver function. Nevertheless, patients with PVT had a median OS of 5.2 (4.3-6.0) mo, whereas that in patients without PVT was 17 (3.2-18.7) mo.

Recently, the application of ¹²⁵I in treating PVTT has shown a curative effect^[18,22-24]. A retrospective matched cohort study^[2] has suggested that TACE combined with ¹²⁵I seed implantation may be a good choice for selected hepatitis B HCC patients with PVTT. Lin *et al.*^[18] found the median OS in HCC patients with PVTT, treated with ¹²⁵I brachytherapy was 7 mo in the MPV group, which was lower than that in other groups, such as the right or left portal vein group and segmental branches of portal vein group. Luo *et al.*^[8] compared the therapeutic effect between the group treated with ¹²⁵I + TACE + stent implantation (group A) and the group treated with stent implantation + TACE (group B). The median survival time was 9.3 ± 0.9 mo (95%CI: 7.6-11.0 mo) in group A and 4.9 ± 0.5 mo (95%CI: 4.0-5.8 mo) in group B. Median progression-free survival time in groups A and B was 1.8 ± 0.1 mo (95%CI: 1.6-2.0 mo) and 1.5 ± 0.1 mo (95%CI: 1.3-1.7 mo), respectively (*P* < 0.001). Median stent patency period was 9.2 ± 1.1 mo (95%CI: 7.0-11.4 mo) in group A and 4.8 ± 0.5 mo (95%CI: 3.9-5.7 mo) in group B (*P* < 0.001).

Radiotherapy (RT), which is recommended for patients with HCC and PVTT, can provide better PVTT control and OS. Li *et al.*^[25] and Im *et al.*^[26] showed that high dose RT combined with other treatments provides a significantly better survival outcome than monotherapy for unresectable HCC patients with PVTT, like TACE, especially for patients with PVTT involving main trunk. The defect of RT with high irradiation dose is the occurrence of adverse reactions, such as gastrointestinal reactions, bone marrow depression and liver function damage. ¹²⁵I seeding can release continuous low doses of X and γ rays that can damage the DNA in the nuclei of the tumor cells. In our research, the uniformly distributed ¹²⁵I seeds, which have a half-life of 59.6 d and a radiation diameter of 1.7 cm, were positioned close to the TT and fixed by TIPS stent^[27]. The close contact with MPVTT makes it possible to deliver γ-ray irradiation to the TT continuously, which greatly inhibits tumor cell growth by inducing apoptosis and shrinking the MPVTT. Therefore, TIPS combined with ¹²⁵I can avoid injury of the surrounding normal tissue with low radiation dose accumulation in the TT, and then can effectively restore the blood flow of the obstructed MPV. Certainly, there are also potential risks as migration of the ¹²⁵I seeds and heterogeneity of the radiation area.

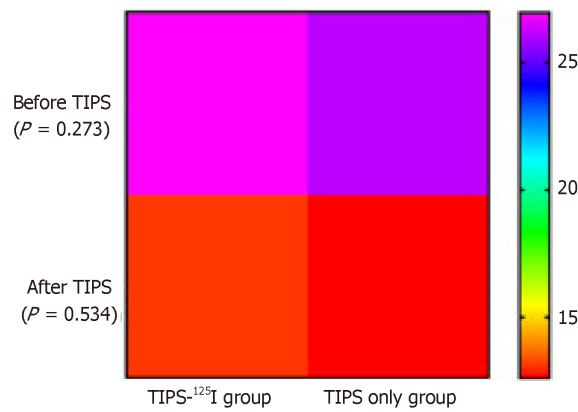


Figure 3 Heat map. Comparison of portosystemic pressure gradient (PPG) measurements before and after operation between the transjugular intrahepatic portosystemic shunt (TIPS)-¹²⁵I group and TIPS only group. Student's t test was used to compare PPG, PPG at each time point were non-difference between groups. TIPS: Transjugular intrahepatic portosystemic shunt.

Although a sufficient amount of radiation^[17] can reduce the degree of impairment to the surrounding normal tissue and improve the therapeutic effect on the PVTT, the cases reported in the literature had strict controls. For example, the first-grade branch of the PV was unobstructed, and the patients had no intractable ascites. At the same time, the patients must be categorized as class A or class B according to the Child-Pugh classification. The number of implanted particles was fixed. The patients included in our study had different characteristics compared with those reported in the literature. In our study, the clinical symptoms were worse. There were 16 patients categorized as class C liver function, with hemorrhage of the digestive tract and chest and abdominal dropsy, and obstructed first-grade branch. Thus, our results were able to demonstrate that ¹²⁵I combined with TIPS can improve patients' survival rate, reduce stent stenosis rate, and reduce symptom recurrence rate.

Our study had several limitations. First, the radiation dose was not uniformly distributed. Second, the number of enrolled patients was small, and it may have influenced the accuracy of the results. Finally, we did not analyze the particle removal rate. Therefore, the results should be interpreted with caution, and large randomized clinical trials are warranted.

In conclusion, TACE/TAE+¹²⁵I combined with TIPS is effective in treating MPVTT and its complications, in improving the quality of life of patients, and in reducing the mortality rate.

Table 3 The rates of symptom recurrence, stent restenosis and survival during follow-up

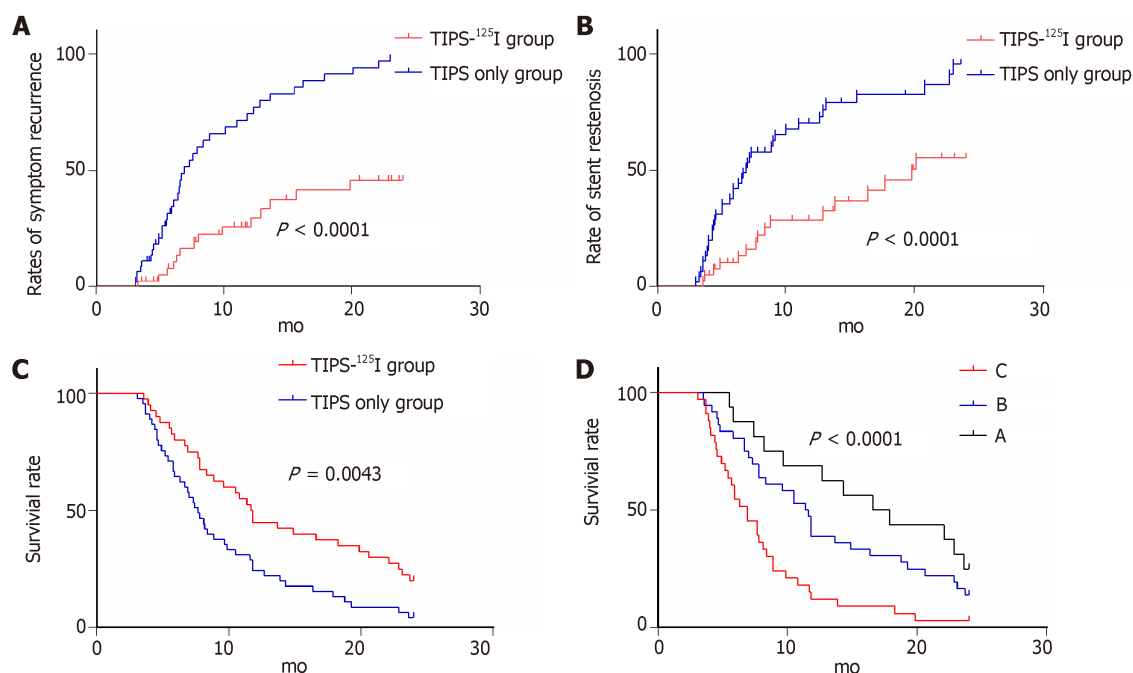
	TIPS- ¹²⁵ I group	TIPS only group	P-value
Rate of stent stenosis			< 0.05
6 mo	12.5	42.2	
12 mo	27.5	68.9	
24 mo	42.5	84.4	
Rate of symptom recurrence			< 0.05
6 mo	7.5	31.1	
12 mo	22.5	62.2	
24 mo	35	82.2	
Survival rate			< 0.05
6 mo	80	64.4	
12 mo	45	24.4	
24 mo	20	4.4	

TIPS: Transjugular intrahepatic portosystemic shunt.

Table 4 The multivariate analysis of survival

	Univariate analysis			Multivariate analysis		
	HR	95%CI	P-value	HR	95%CI	P-value
Group	1.943	1.219-3.097	0.005	2.631	1.603-4.318	< 0.001
MELD score	1.042	0.849-1.279	0.692	1.697	1.261-2.282	< 0.001
DBIL	0.988	0.965-1.012	0.338			0.161
ALT	0.991	0.979-1.003	0.150			0.078
Child-Pugh classification			< 0.001			< 0.001
B/A	1.546	0.793-3.016	0.201	3.783	1.718-8.329	
C/A	3.493	1.764-6.918	< 0.001	13.87	5.192-37.07	

MELD score: Model for end-stage liver disease score; DBIL: Direct bilirubin; ALT: Alanine aminotransferase.

**Figure 4** Kaplan-Meier curves of post-operation symptom recurrence, stent stenosis and survival. A: Rate of symptom recurrence; B: Rate of stent stenosis; C:

Survival rate on treatment; D: Survival rate on Child-Pugh classification. TIPS: Transjugular intrahepatic portosystemic shunt.

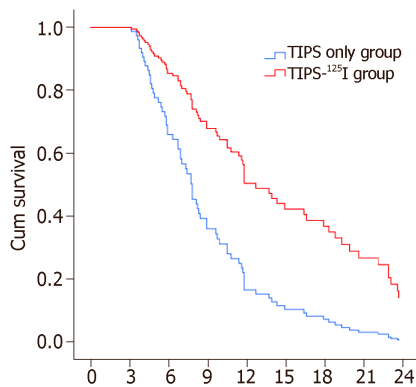


Figure 5 COX plots of overall survival in hepatocellular carcinoma patients with main portal vein tumor thrombosis. TIPS: Transjugular intrahepatic portosystemic shunt.

ARTICLE HIGHLIGHTS

Research background

The main portal vein tumor thrombus (MPVTT), which is the major complication of terminal hepatocellular carcinoma (HCC) and causes portal hypertension, seriously affects the prognosis of liver cancer. MPVTT causes portal hypertension, which leads to many complications, such as ascites and hemorrhage of the digestive tract.

Research motivation

For patients with MPVTT, the ideal treatment should improve survival rate, reduce portal vein pressure, and avoid ascites and gastrointestinal bleeding, and the main objectives are to eliminate TT and recanalization of the PV.

Research objectives

Transjugular intrahepatic portosystemic shunt (TIPS) has been widely performed for the treatment of portal hypertension because it is minimally invasive and is reported to be effective.

Research methods

Some studies have reported that treatment of HCC with ¹²⁵I implantation can reduce the volume of PVTT, which can improve the survival rate of patients. Thus, data analysis was adopted to analyze patient outcome in two groups with different treatments (plus or non-plus ¹²⁵I implantation). However, ¹²⁵I implantation documented in the literature was in the form of particle strands, which cannot be adjusted in position and implanted in limited numbers.

Research results

¹²⁵I combined with TIPS can fix the particles between the stent and the TT without the need for particle strands.

Research conclusions

This approach allows for easier adjustment of the position of ¹²⁵I and the amount of ¹²⁵I being implanted. It can significantly enhance the survival rate of patients. TIPS combined with ¹²⁵I can also reduce stent restenosis rate and symptom recurrence rate, and it is safe and feasible. However, the radiation dose is not uniformly distributed and particle fixation needs to be strengthened.

Research perspectives

In the present study, we used ¹²⁵I combined with TIPS for the treatment of MPVTT and fixed the ¹²⁵I particles between the stent and TT, without the need for particle strands. This approach allows for easier adjustment of the position of ¹²⁵I and the amount being implanted. The direction of future research should aim to find new methods that are minimally invasive and more effective.

REFERENCES

- 1 Cabibbo G, Enea M, Attanasio M, Bruix J, Craxi A, Cammà C. A meta-analysis of survival rates of untreated patients in randomized clinical trials of hepatocellular carcinoma. *Hepatology* 2010; **51**: 1274-

- 1283 [PMID: 20112254 DOI: 10.1002/hep.23485]
- 2 **Huang M**, Lin Q, Wang H, Chen J, Bai M, Wang L, Zhu K, Jiang Z, Guan S, Li Z, Qian J, Li M, Pang P, Shan H. Survival benefit of chemoembolization plus Iodine-125 seed implantation in unresectable hepatitis B-related hepatocellular carcinoma with PVTT: a retrospective matched cohort study. *Eur Radiol* 2016; **26**: 3428-3436 [PMID: 26792430 DOI: 10.1007/s00330-015-4198-x]
- 3 **Villa E**, Moles A, Ferretti I, Buttafoco P, Grottola A, Del Buono M, De Santis M, Manenti F. Natural history of inoperable hepatocellular carcinoma: estrogen receptors' status in the tumor is the strongest prognostic factor for survival. *Hepatology* 2000; **32**: 233-238 [PMID: 10915729 DOI: 10.1053/jhep.2000.9603]
- 4 **Izumi R**, Shimizu K, Ii T, Yagi M, Matsui O, Nonomura A, Miyazaki I. Prognostic factors of hepatocellular carcinoma in patients undergoing hepatic resection. *Gastroenterology* 1994; **106**: 720-727 [PMID: 8119543 DOI: 10.1016/0016-5085(94)90707-2]
- 5 **Katagiri S**, Yamamoto M. Multidisciplinary treatments for hepatocellular carcinoma with major portal vein tumor thrombus. *Surg Today* 2014; **44**: 219-226 [PMID: 23591833 DOI: 10.1007/s00595-013-0585-6]
- 6 **Yamamoto Y**, Ikoma H, Morimura R, Shoda K, Konishi H, Murayama Y, Komatsu S, Shiozaki A, Kuriu Y, Kubota T, Nakanishi M, Ichikawa D, Fujiwara H, Okamoto K, Sakakura C, Ochiai T, Otsuji E. Post-hepatectomy survival in advanced hepatocellular carcinoma with portal vein tumor thrombosis. *World J Gastroenterol* 2015; **21**: 246-253 [PMID: 25574098 DOI: 10.3748/wjg.v21.i1.246]
- 7 **Samuel D**, Colombo M, El-Serag H, Sobesky R, Heaton N. Toward optimizing the indications for orthotopic liver transplantation in hepatocellular carcinoma. *Liver Transpl* 2011; **17** Suppl 2: S6-13 [PMID: 21858912 DOI: 10.1002/lt.22423]
- 8 **Luo JJ**, Zhang ZH, Liu QX, Zhang W, Wang JH, Yan ZP. Endovascular brachytherapy combined with stent placement and TACE for treatment of HCC with main portal vein tumor thrombus. *Hepatol Int* 2016; **10**: 185-195 [PMID: 26341514 DOI: 10.1007/s12072-015-9663-8]
- 9 **Zhang YW**, Naren TG, Gao F. Color Doppler guided percutaneous oily chemoembolization for the treatment of portal vein tumor thrombus in HCC patients. *Zhongguo Jieru Yingxiang Yu Zhiliao Xue Zazhi* 2009; **2** [DOI: 10.13929/j.1672-8475.2009.02.020]
- 10 **Peng B**, Liang L, He Q, Zhou F, Luo S. Surgical treatment for hepatocellular carcinoma with portal vein tumor thrombus. *Hepatogastroenterology* 2006; **53**: 415-419 [PMID: 16795984 DOI: 10.1136/gut.2005.089136]
- 11 **Liu L**, Zhao Y, Qi X, Cai G, He C, Guo W, Yin Z, Chen H, Chen X, Fan D, Han G. Transjugular intrahepatic portosystemic shunt for symptomatic portal hypertension in hepatocellular carcinoma with portal vein tumor thrombosis. *Hepatol Res* 2014; **44**: 621-630 [PMID: 23679937 DOI: 10.1111/hepr.12162]
- 12 **Qiu B**, Li K, Dong X, Liu FQ. Transjugular Intrahepatic Portosystemic Shunt for Portal Hypertension in Hepatocellular Carcinoma with Portal Vein Tumor Thrombus. *Cardiovasc Intervent Radiol* 2017; **40**: 1372-1382 [PMID: 28488102 DOI: 10.1007/s00270-017-1655-8]
- 13 **Yang M**, Fang Z, Yan Z, Luo J, Liu L, Zhang W, Wu L, Ma J, Yang Q, Liu Q. Transarterial chemoembolisation (TACE) combined with endovascular implantation of an iodine-125 seed strand for the treatment of hepatocellular carcinoma with portal vein tumour thrombosis versus TACE alone: a two-arm, randomised clinical trial. *J Cancer Res Clin Oncol* 2014; **140**: 211-219 [PMID: 24374800 DOI: 10.1007/s00432-013-1568-0]
- 14 **Bruix J**, Sherman M; American Association for the Study of Liver Diseases. Management of hepatocellular carcinoma: an update. *Hepatology* 2011; **53**: 1020-1022 [PMID: 21374666 DOI: 10.1002/hep.24199]
- 15 **Tarantino L**, Francica G, Sordelli I, Esposito F, Giorgio A, Sorrentino P, de Stefano G, Di Sarno A, Ferraioli G, Sperlongano P. Diagnosis of benign and malignant portal vein thrombosis in cirrhotic patients with hepatocellular carcinoma: color Doppler US, contrast-enhanced US, and fine-needle biopsy. *Abdom Imaging* 2006; **31**: 537-544 [PMID: 16865315 DOI: 10.1007/s00261-005-0150-x]
- 16 **Bruix J**, Qin S, Merle P, Granito A, Huang YH, Bodoky G, Pracht M, Yokosuka O, Rosmorduc O, Breder V, Gerolami R, Masi G, Ross PJ, Song T, Bronowicki JP, Ollivier-Hourmand I, Kudo M, Cheng AL, Llovet JM, Finn RS, LeBerre MA, Baumhauer A, Meinhardt G, Han G; RESORCE Investigators. Regorafenib for patients with hepatocellular carcinoma who progressed on sorafenib treatment (RESORCE): a randomised, double-blind, placebo-controlled, phase 3 trial. *Lancet* 2017; **389**: 56-66 [PMID: 27932229 DOI: 10.1016/S0140-6736(16)32453-9]
- 17 **Sun JH**, Zhou T, Zhu T, Zhang Y, Nie C, Ai J, Zhou G, Zhang A, Dong MJ, Wang WL, Zheng SS. Portal Vein Stenting Combined with Iodine-125 Seeds Endovascular Implantation Followed by Transcatheter Arterial Chemoembolization for Treatment of Hepatocellular Carcinoma Patients with Portal Vein Tumor Thrombus. *Biomed Res Int* 2016; **2016**: 3048261 [PMID: 27999793 DOI: 10.1155/2016/3048261]
- 18 **Lin J**, Jiang H, Yang W, Jiang N, Zheng Q, Huang N, Wang X, Li A, Huang J. Predictive factors of benefit from iodine-125 brachytherapy for hepatocellular carcinoma with portal vein tumor thrombosis. *Brachytherapy* 2018; pii: S1538-4721(18)30424-0 [PMID: 30467014 DOI: 10.1016/j.brachy.2018.10.002]
- 19 **Han G**, Qi X, He C, Yin Z, Wang J, Xia J, Yang Z, Bai M, Meng X, Niu J, Wu K, Fan D. Transjugular intrahepatic portosystemic shunt for portal vein thrombosis with symptomatic portal hypertension in liver cirrhosis. *J Hepatol* 2011; **54**: 78-88 [PMID: 20932597 DOI: 10.1016/j.jhep.2010.06.029]
- 20 **Boyer TD**, Haskal ZJ. American Association for the Study of Liver Diseases Practice Guidelines: the role of transjugular intrahepatic portosystemic shunt creation in the management of portal hypertension. *J Vasc Interv Radiol* 2005; **16**: 615-629 [PMID: 15872315 DOI: 10.1097/01.RVI.0000157297.91510.21]
- 21 **Bettinger D**, Knüppel E, Euringer W, Spangenberg HC, Rössle M, Thimme R, Schultheiß M. Efficacy and safety of transjugular intrahepatic portosystemic shunt (TIPS) in 40 patients with hepatocellular carcinoma. *Aliment Pharmacol Ther* 2015; **41**: 126-136 [PMID: 25329493 DOI: 10.1111/apt.12994]
- 22 **Zhang ZH**, Liu QX, Zhang W, Ma JQ, Wang JH, Luo JJ, Liu LX, Yan ZP. Combined endovascular brachytherapy, sorafenib, and transarterial chemobolization therapy for hepatocellular carcinoma patients with portal vein tumor thrombus. *World J Gastroenterol* 2017; **23**: 7735-7745 [PMID: 29209114 DOI: 10.3748/wjg.v23.i43.7735]
- 23 **Wu YF**, Wang T, Yue ZD, Zhao HW, Wang L, Fan ZH, He FL, Liu FQ. Stents combined with iodine-125 implantation to treat main portal vein tumor thrombus. *World J Gastrointest Oncol* 2018; **10**: 496-504 [PMID: 30595803 DOI: 10.4251/wjgo.v10.i12.496]
- 24 **Zhang ZH**, Zhang W, Gu JY, Liu QX, Ma JQ, Liu LX, Wang JH, Luo JJ, Yan ZP. Treatment of Hepatocellular Carcinoma with Tumor Thrombus with the Use of Iodine-125 Seed Strand Implantation

- and Transarterial Chemoembolization: A Propensity-Score Analysis. *J Vasc Interv Radiol* 2018; **29**: 1085-1093 [PMID: 29754851 DOI: 10.1016/j.jvir.2018.02.013]
- 25 **Li XL**, Guo WX, Hong XD, Yang L, Wang K, Shi J, Li N, Wu MC, Cheng SQ. Efficacy of the treatment of transarterial chemoembolization combined with radiotherapy for hepatocellular carcinoma with portal vein tumor thrombus: A propensity score analysis. *Hepatol Res* 2016; **46**: 1088-1098 [PMID: 26783741 DOI: 10.1111/hepr.12657]
- 26 **Im JH**, Yoon SM, Park HC, Kim JH, Yu JI, Kim TH, Kim JW, Nam TK, Kim K, Jang HS, Kim JH, Kim MS, Yoon WS, Jung I, Seong J. Radiotherapeutic strategies for hepatocellular carcinoma with portal vein tumour thrombosis in a hepatitis B endemic area. *Liver Int* 2017; **37**: 90-100 [PMID: 27317941 DOI: 10.1111/liv.13191]
- 27 **Chuan-Xing L**, Xu H, Bao-Shan H, Yong L, Pei-Jian S, Xian-Yi Y, Xiao-Ning L, Li-Gong L. Efficacy of therapy for hepatocellular carcinoma with portal vein tumor thrombus: chemoembolization and stent combined with iodine-125 seed. *Cancer Biol Ther* 2011; **12**: 865-871 [PMID: 22037354 DOI: 10.4161/cbt.12.10.17676]



Published By Baishideng Publishing Group Inc
7041 Koll Center Parkway, Suite 160, Pleasanton, CA 94566, USA
Telephone: +1-925-2238242
Fax: +1-925-2238243
E-mail: bpgoffice@wjgnet.com
Help Desk: <https://www.f6publishing.com/helpdesk>
<https://www.wjgnet.com>

