


World Journal of *Gastrointestinal Surgery*

World J Gastrointest Surg 2019 March 27; 11(3): 117-197





EDITORIAL

- 117 Classification and guidelines of hemorrhoidal disease: Present and future
Rubbini M, Ascanelli S
- 122 Liver preservation prior to transplantation: Past, present, and future
Chedid MF, Pinto MA, Juchem JFG, Grezzana-Filho TJM, Kruel CRP

REVIEW

- 126 Liver graft preservation methods during cold ischemia phase and normothermic machine perfusion
Tchilikidi KY
- 143 Management of pancreatic head adenocarcinoma: From where to where?
Dolay K, Malya FU, Akbulut S

MINIREVIEWS

- 155 Conduit necrosis following esophagectomy: An up-to-date literature review
Athanasiou A, Hennessy M, Spartalis E, Tan BHL, Griffiths EA

ORIGINAL ARTICLE

Prospective Study

- 169 Learning curve of enhanced recovery after surgery program in open colorectal surgery
Lohsiriwat V

SYSTEMATIC REVIEW

- 179 Single incision laparoscopic fundoplication: A systematic review of the literature
Perivoliotis K, Sarakatsianou C, Tepetes K, Baloyiannis I

CASE REPORT

- 191 Laparoscopic celiac plexus ganglioneuroma resection: A video case report
Hemmati P, Ghanem O, Bingener J

ABOUT COVER

Editorial Board of *World Journal of Gastrointestinal Surgery*, Robert AFM Chamuleau, MD, PhD, Professor, Department of Hepatology, Academic Medical Center, University of Amsterdam, Amsterdam BK 1105, Netherlands

AIMS AND SCOPE

World Journal of Gastrointestinal Surgery (*World J Gastrointest Surg*, *WJGS*, online ISSN 1948-9366, DOI: 10.4240) is a peer-reviewed open access academic journal that aims to guide clinical practice and improve diagnostic and therapeutic skills of clinicians.

The *WJGS* covers topics concerning micro-invasive surgery; laparoscopy; hepatic, biliary, pancreatic and splenic surgery; surgical nutrition; portal hypertension, as well as associated subjects. The current columns of *WJGS* include editorial, frontier, diagnostic advances, therapeutics advances, field of vision, mini-reviews, review, original articles, case report, etc.

We encourage authors to submit their manuscripts to *WJGS*. We will give priority to manuscripts that are supported by major national and international foundations and those that are of great basic and clinical significance.

INDEXING/ABSTRACTING

The *WJGS* is now abstracted and indexed in PubMed, PubMed Central, Emerging Sources Citation Index (Web of Science), China National Knowledge Infrastructure (CNKI), China Science and Technology Journal Database (CSTJ), and Superstar Journals Database.

**RESPONSIBLE EDITORS
FOR THIS ISSUE**

Responsible Electronic Editor: Yan-Liang Zhang Proofing Editorial Office Director: Jin-Lei Wang

NAME OF JOURNAL

World Journal of Gastrointestinal Surgery

ISSN

ISSN 1948-9366 (online)

LAUNCH DATE

November 30, 2009

FREQUENCY

Monthly

EDITORS-IN-CHIEF

Varut Lohsirirawat, Shu-You Peng

EDITORIAL BOARD MEMBERS

<https://www.wjgnet.com/1948-9366/editorialboard.htm>

EDITORIAL OFFICE

Jin-Lei Wang, Director

PUBLICATION DATE

March 27, 2019

COPYRIGHT

© 2019 Baishideng Publishing Group Inc

INSTRUCTIONS TO AUTHORS

<https://www.wjgnet.com/bpg/gerinfo/204>

GUIDELINES FOR ETHICS DOCUMENTS

<https://www.wjgnet.com/bpg/GerInfo/287>

GUIDELINES FOR NON-NATIVE SPEAKERS OF ENGLISH

<https://www.wjgnet.com/bpg/gerinfo/240>

PUBLICATION MISCONDUCT

<https://www.wjgnet.com/bpg/gerinfo/208>

ARTICLE PROCESSING CHARGE

<https://www.wjgnet.com/bpg/gerinfo/242>

STEPS FOR SUBMITTING MANUSCRIPTS

<https://www.wjgnet.com/bpg/GerInfo/239>

ONLINE SUBMISSION

<https://www.f6publishing.com>



Conduit necrosis following esophagectomy: An up-to-date literature review

Antonios Athanasiou, Mairead Hennessy, Eleftherios Spartalis, Benjamin H L Tan, Ewen A Griffiths

ORCID number: Antonios Athanasiou (0000-0002-0847-6439); Mairead Hennessy (0000-0002-5470-7699); Eleftherios Spartalis (0000-0003-4451-8074); Benjamin H L Tan (0000-0002-4593-8719); Ewen A Griffiths (0000-0001-6630-3547).

Author contributions: Athanasiou A and Hennessy M contributed to study design, manuscript preparation and review; Griffiths EA contributed to critical manuscript review, critical revision; final manuscript approval; Spartalis E and Tan BHL contributed to critical manuscript review.

Conflict-of-interest statement: No potential conflicts of interest. No financial support.

Open-Access: This article is an open-access article which was selected by an in-house editor and fully peer-reviewed by external reviewers. It is distributed in accordance with the Creative Commons Attribution Non Commercial (CC BY-NC 4.0) license, which permits others to distribute, remix, adapt, build upon this work non-commercially, and license their derivative works on different terms, provided the original work is properly cited and the use is non-commercial. See: <http://creativecommons.org/licenses/by-nc/4.0/>

Manuscript source: Invited manuscript

Received: February 13, 2019

Peer-review started: February 14,

Antonios Athanasiou, Department of Upper GI, Bariatric and Minimally Invasive Surgery, St. James' University Hospital, Leeds Teaching Hospitals NHS Trust, Leeds LS9 7TF, United Kingdom

Mairead Hennessy, Department of Anaesthesia, University Hospital of Waterford, Waterford X91 ER8E, Ireland

Eleftherios Spartalis, Laboratory of Experimental Surgery and Surgical Research, University of Athens, Medical School, Athens 11527, Greece

Benjamin H L Tan, Ewen A Griffiths, Department of Upper Gastrointestinal Surgery, University Hospitals Birmingham NHS Foundation Trust, Birmingham B15 2TH, United Kingdom

Corresponding author: Antonios Athanasiou, MD, MSc, PhD, Academic Fellow, Academic Research, Research Fellow, Senior Postdoctoral Fellow, Surgeon, Department of Upper GI, Bariatric and Minimally Invasive Surgery, St. James' University Hospital, Leeds Teaching Hospitals NHS Trust, Beckett St., Leeds LS9 7TF, United Kingdom. antwnis_athanasiou@hotmail.com

Telephone: +44-775-2014764

Fax: +44-121-3715896

Abstract

Esophageal conduit ischaemia and necrosis is an uncommon but devastating complication of esophagectomy and remains one of the most challenging issues in surgical practice. The incidence, time interval to develop symptoms, and clinical presentation are highly variable with no predictable pattern. Evidence comes from case reports and case series rather than randomized controlled trials. We describe the issues surrounding conduit necrosis affecting the stomach, jejunum and colon as an esophageal replacement and the advantages, disadvantages and challenges of each type of reconstruction. Diagnosis is challenging for the most experienced surgeon. Upper gastrointestinal endoscopy and computed tomography thorax with both oral and intravenous contrast is the gold standard. Management, either conservative or interventional is also a difficult decision. Management options include conservative treatment and more aggressive treatments such as stent insertion, surgical debridement and repair of the esophagus using jejunum, colon or a musculocutaneous flap. In spite of recent advances in surgical techniques, there is no reliable strategy to manage esophageal conduit necrosis. Our review covers the pathophysiology and clinical significance of esophageal necrosis while highlighting current techniques of prevention, diagnosis and treatment of this life-threatening condition.

2019

First decision: February 26, 2019

Revised: March 21, 2019

Accepted: March 24, 2019

Article in press: March 24, 2019

Published online: March 27, 2019

P-Reviewer: Chedid MF, Musella M, Uygun I

S-Editor: Ji FF

L-Editor: A

E-Editor: Zhang YL

Key words: Esophagectomy; Esophageal cancers; Esophagogastric anastomosis

©The Author(s) 2019. Published by Baishideng Publishing Group Inc. All rights reserved.

Core tip: Esophageal conduit necrosis is an uncommon but devastating complication of esophagectomy and remains one of the most challenging issues in surgical practice. The purpose of this literature review is to provide the practicing surgeon with an up to date literature review on this complication and discuss the management of this rare condition. The incidence, time interval to develop symptoms, and clinical presentation are highly variable with no predictable pattern. Evidence comes from case reports and case series rather than randomized controlled trials. Our review details the pathophysiology, predisposing factors, clinical symptoms, diagnostic approach and we will highlight treatment options for the management of this life threatening condition.

Citation: Athanasίου A, Hennessy M, Spartalis E, Tan BHL, Griffiths EA. Conduit necrosis following esophagectomy: An up-to-date literature review. *World J Gastrointest Surg* 2019; 11(3): 155-168

URL: <https://www.wjgnet.com/1948-9366/full/v11/i3/155.htm>

DOI: <https://dx.doi.org/10.4240/wjgs.v11.i3.155>

INTRODUCTION

Esophageal cancer is one of the most common causes of cancer related mortality and morbidity worldwide^[1]. Despite improvements in the standardisation of surgical techniques, better case selection of patients for surgery, preoperative optimisation of nutritional status and improved intensive care unit (ICU) care, esophagectomy is still associated with significant rate of post-operative complications^[2]. The anastomosis between the oesophagus and the replacement conduit is challenging, with a wide variety of different surgical techniques proposed in the literature. The four main complications affecting the oesophagogastric anastomosis and the gastric conduit after the creation of neo-esophagus are anastomotic leak, anastomotic stricture, conduit ischemia and conduit necrosis^[3]. Gastric conduit necrosis is the severest of these complications and is considered to be life threatening with a high mortality rate^[3,4]. This is due to the development of widespread mediastinal sepsis, and as a result, conservative treatment is generally contraindicated. Upper gastrointestinal (GI) endoscopy is considered to be the gold standard for the diagnosis and differentiates between conduit necrosis and conduit ischemia^[5]. Patients with conduit necrosis require urgent fluid resuscitation, broad spectrum antibiotic and anti-fungal coverage, early surgical exploration with drainage of all infected collections and debridement of the necrotic conduit and esophageal diversion proximally^[6]. The purpose of this literature review is to provide the practising surgeon with an up to date literature review on this devastating complication. As such we have performed a contemporaneous systematic review and will describe and discuss the incidence of this rare complication, clinical manifestations, diagnostic strategy and management options available to help esophageal surgeons deal with this situation.

Definition

Esophageal conduit necrosis is death or ischaemia of the conduit used in the construction of the neo-esophagus, which is typically stomach, but can also occur when using the jejunum or colon for esophageal replacement. The distinction between conduit necrosis and conduit ischemia is crucial as the treatment approach is different. Fortunately, ischaemia does not always lead to conduit necrosis or anastomotic breakdown and healing can occur. The clinical range of gastric conduit ischaemia is broad and includes subclinical cases that resolve without intervention, ischemic-related anastomotic leak or stricture formation, and frank stomach necrosis. In addition, conduit ischemia may or may not be associated with anastomotic leakage.

Veeramootoo *et al*^[7] in 2009 categorised gastric conduit necrosis after esophagectomy to the following three types: Type I is consider to be Simple "anastomotic leak" without significant intramucosal necrosis. Type II is focal necrosis at the conduit tip which requires resection and refashioning of the esophago-gastric anastomosis. Type III is more extensive necrosis of the conduit requiring resection and delayed reconstruction.

Prior to 2015, there was a lack of standardization and the absence of generally accepted definitions of complications in esophageal surgery and this hampered outcome assessment after esophagectomy and made comparisons between studies very difficult. However, in 2015, 21 international esophageal surgeons collaborated to produce the Esophageal Complications Consensus Group (ECCG) guidelines to standardise all complications and adverse events occurring during in-hospital stay after esophagectomy, such as anastomotic leak, chyle leak, delayed gastric emptying^[8]. **Table 1** shows the consensus of definition for conduit necrosis and conduit ischemia^[8]. Type 1 is focal conduit ischaemia which does not require any treatment, but requires close endoscopic monitoring to ensure it resolves and does not progress to frank full thickness conduit necrosis. In this scenario is often mucosa ischaemia rather than full thickness ischaemia. Type 2 is more extensive conduit ischaemia, without associated anastomotic leakage, which requires treatment with surgery (this usually results in resection of the ischaemic area and reformation of the anastomosis). Type 3 conduit necrosis is a completely necrotic stomach which requires resection, esophageal diversion with a cervical oesophagostomy and enteral feeding access. In Type 3 conduit necrosis, delayed reconstruction if no metastases develops in the interval period is the procedure of choice. However, certain patients are not suitable for reconstruction due to inadequate fitness to undergo further surgery, early recurrence or patient choice to avoid an even more complex procedure. There is obviously some overlap between anastomotic leakage and conduit ischaemia and necrosis according to this classifications.

Clinical manifestations

The most common clinical manifestations of conduit ischaemia and necrosis are tachycardia, tachypnoea, fever and altered mental status. There is much overlap between patients presenting with gastric conduit ischaemia/necrosis and those of an anastomotic leak. Clinical suspicion, early diagnosis and expeditious management are vital to reduce morbidity and mortality. Severe sepsis or septic shock is late signs. Signs can include saliva or GI contents exuding from the neck incision or bile within the chest drain^[3]. Worrying signs of potential gastric conduit necrosis include bloody or feculent nasogastric output, lactic acidosis or haemodynamically instability such as hypotension and shock. In some patients a foul odour or “bad breath” can be apparent at the bedside and is caused by necrosis of the conduit and bacterial overgrowth in the necrotic tissue.

Diagnosis

Some surgeons routinely arrange a water soluble swallow prior to commencing oral intake, but this has some disadvantages, including the risks of aspiration, false negative results and the risk that anastomotic or conduit complications occur before the timing of the investigation^[9,10]. Whilst a water soluble (gastrograffin) swallow is helpful for patients with a high predicted probability of an anastomotic leak who are alert and able to sit up for the investigation, it can be largely normal even in advanced conduit ischaemia. This is because the contrast remains within the gastric lumen and not be associated with an anastomosis leak in some situations^[9]. In addition, contrast swallows are not appropriate for patients who are intubated and ventilated on ICU. In this scenario bedside endoscopy on the ICU, preferably performed by the operating surgeon is a better test of the viability of the gastric conduit and whether an anastomotic leak is present^[11]. It is for this reason that upper GI endoscopy and CT thorax with intravenous contrast (IV) and oral contrast are considered to be the “gold standard” for the diagnosis of conduit necrosis and anastomotic leakage.

Clear radiological evidence of anastomotic leak are more specific than the findings of conduit necrosis. However, CT is crucial for the detection of intrathoracic collections which need to be drained. CT findings include gastric and esophageal wall thickening with possible small gas bubbles in soft tissues, especially at the anastomotic level^[12]. Furthermore, CT sensitivity for detection of free extra-luminal contrast and mediastinal collections and contamination is high. Nonetheless, it has been observed that some patients with partial or non-full thickness gastric conduit ischemia can have a normal CT scan^[12].

Routine Upper GI endoscopy within one week following esophagectomy has been proposed in the literature for the evaluation of gastric conduit and the integrity of the anastomosis^[13,14]. Page *et al*^[14], assessed the efficacy and safety of upper GI endoscopy in 100 patients within one week after esophagectomy. Their results showed that endoscopy is very safe and accurate method for the diagnosis of conduit ischaemia and necrosis and allows more individualized patient management. Tom DeMeester's group has published an endoscopic classification system for the findings of gastric conduit ischaemia and necrosis (**Table 2**)^[12].

Table 1 The Esophageal Complications Consensus Group definition and classification of conduit necrosis and ischemia^[8]

Type	Diagnosis	Treatment
Type I: Conduit necrosis focal	Identified endoscopically	Additional monitoring or non-surgical therapy
Type II: Conduit necrosis focal	Identified endoscopically and not associated with free anastomotic or conduit leak	Surgical therapy not involving esophageal diversion
Type III: Conduit necrosis; extensive	Identified endoscopically	Treated with conduit resection with diversion

LITERATURE SEARCH

A systematic review was carried out according to the preferred reporting items for systematic reviews and meta-analyses (PRISMA) statement^[15]. Articles indexed in Embase and PubMed were searched from inception up to January 2019, by two authors, using the Medical Subject Headings (MeSH) for database research and text words related to: (esophagus OR esophageal) AND (esophagectomy) AND (conduit necrosis OR conduit ischemia). The process of the literature search is depicted in [Figure 1](#). Our review details the pathophysiology, predisposing factors, clinical symptoms, diagnostic approach to this problem and we will highlight treatment options for the management of this life threatening condition.

SEARCH RESULTS

Epidemiology

According to the literature, the incidence of conduit ischaemia or conduit necrosis following esophagectomy varies significantly. Much of this variation could be due to a lack of standardised definition prior to 2015. Many series report incidence of gastric tube ischemia less than 1%^[16,17]. Davis *et al*^[16] report 0.5% gastric tube ischemia in series of 959 esophagectomies. Luketich *et al*^[18] examined minimally invasive esophagectomy in a series of 1000 patients, with a 2% incidence of graft necrosis. Briel *et al*^[19] reported a very high rate of 10.4 % of gastric conduit ischemia in a series of 230 consecutive esophagectomy. He found no statistically significant difference between gastric and colon interposition. A recent systematic review and meta-analysis showed that the rate of conduit ischemia/necrosis was 0% in 13 randomized control trials and 21% in 85 observational studies^[20].

Risk factors

Identifying patients at risk of conduit ischaemia or necrosis pre-operatively is essential. This is to enable surgeons to consent patients to the increased risks of a poor outcome particularly if they have several risks factors and also to try to modify these risks prior to surgery in certain patients. Risk factors for gastric conduit ischaemia or necrosis are shown in [Table 3](#) and consist of a variety of patients related risks factors, technical/surgical factors and post-operative factors^[21-26].

Several patient related risk factors are associated with conduit ischaemic and necrosis and these include diabetes mellitus, malnutrition, steroid use, hypertension, cardiac arrhythmias, reduced cardiac contractility and peripheral vascular disease^[19]. Lainas *et al*^[27] reviewed 481 patients who underwent Ivor Lewis esophagectomy and on pre-operative CT imaging assessed the degree of coeliac artery calcification and stenosis. They found a strong association between pre-existing coeliac axis stenosis and subsequent conduit necrosis^[27]. Co-morbidities including diabetes mellitus, hypertension and peripheral arterial disease must be thoroughly reviewed and optimised prior to surgery. Patient factors such as smoking, neoadjuvant chemoradiotherapy and pre-operative weight loss were not associated with increased ischaemia^[28].

Performing a surgical resection without compromising blood supply is essential for safe esophageal reconstruction. The blood supply to the upper abdominal viscera is derived from the coeliac axis. Coeliac axis stenosis due to median arcuate ligament syndrome or atherosclerosis may impair the viability of the gastric conduit used in esophageal chest reconstruction^[27]. In most cases, the conduit of choice is the stomach, deriving its blood supply primarily from the right gastro epiploic artery^[29]. Injury to the conduit during abdominal dissection or at the time of repositioning within the thorax or neck can be detrimental^[30]. Tension on the anastomosis or venous obstruction can inhibit healing at the anastomosis. This could be due to extrinsic compression at the thoracic inlet, and is considered to contribute to an increased rate of failure in cervical anastomoses^[30]. Extrinsic compression at the hiatus can also occur

Table 2 Endoscopic classification system for the findings of gastric conduit ischaemia and necrosis^[12]

Grades	Findings
Grade 1	Dusky bluish-color mucosa around the anastomosis covered with tenacious metallic-appearing mucous that cannot be easily washed off
Grade 2	Partial disruption of the anastomosis with equivocal viability of the adjacent mucosa or the normal pink mucosa margins
Grade 3	Complete circumferential breakdown of the anastomosis with normal pink mucosa margins
Grade 4	Completely necrotic black mucosa throughout the gastric conduit with the anastomosis still intact

due to tightness, oedema or acute diaphragmatic hernia. In addition to blood flow, maintaining adequate tissue oxygenation to the anastomosis is vital for anastomosis healing.

The effect of thoracic epidural analgesia on the perfusion of the gastric conduit is controversial. The majority of units use thoracic epidural analgesia for post-operative analgesia, especially after open trans-thoracic procedures. One small study suggested that the epidural, perhaps due to the sympathetic block, improved blood supply to the gastric conduit^[31]. In another small study, Al-Rawi *et al.*^[32] showed by using laser Doppler flowmetry that thoracic epidural bupivacaine decreases significantly the arterial blood pressure and cardiac output, presumably due to block of cardiac sympathetics. This study has also shown that arterial pressure has a greater impact on the tip of the gastric conduit than on the pyloric end of the gastric tube.

Ischaemic pre-conditioning

Ischaemic pre-conditioning of the gastric conduit prior to esophagectomy in order to reduce conduit necrosis and anastomotic leak rates was first described by Urschel *et al.*^[33] in 1997. Pre-conditioning can be performed radiologically or surgically. Laparoscopic ligation or radiological embolization of the left gastric artery, left gastroepiploic artery and short gastric arteries can reduce significantly the gastric blood supply^[34]. Nevertheless, the correct timing, appropriate technique and benefits of pre-conditioning remain controversial.

Gastric conduit necrosis following esophagectomy is thought to have an increased association with minimally invasive techniques, especially in the early stages of the learning curve. Crenshaw *et al.*^[35] found that extracorporeal stapling of the gastric conduit led to a significant reduction in the incidence of gastric conduit failures when compared with the intracorporeal stapling technique. A retrospective analysis by Ramage *et al.*^[36] including 155 patients after minimally invasive esophagectomies (MIOs), showed 2.6% of conduit necrosis. The authors concluded that conduit necrosis is strongly related to the learning curve. Prophylactic measures such as ischaemic preconditioning become less relevant as the operating surgeon's experience increases. On the other hand, tension free and correct position of gastric tube, preservation of gastroepiploic arcade without injuries and sufficient defect of the diaphragmatic hiatus are crucial factors^[36].

To try to counteract the association between gastric conduit necrosis and minimally invasive esophagectomy, several authors have suggested that gastric ischaemic pre-conditioning may reduce ischaemic complications. This takes the form of dividing either the left gastric artery or short gastric vessels a week or so prior to planned oesophagectomy. The hypothesis is that the conduit has time to get "pre-conditioned" and reduces the risk of conduit necrosis. Berrisford *et al.*^[21] reviewed 77 consecutive patients who underwent a total MIO. Their results suggest that ischaemic conditioning of the stomach prior to MIO is safe and there is a trend to reduced morbidity related to gastric-conduit ischaemia^[21]. Wajed *et al.*^[37] advocate laparoscopic ischaemic conditioning by ligation of the left gastric vessels 2 weeks prior to MIO in addition to extracorporeal stapling to reduce the incidence of conduit necrosis, particularly in three stage surgery. A small randomized study by the same group did not identify any clinical benefits with ischaemic pre-conditioning^[38]. Table 4 shows the most important studies in humans regarding gastric ischaemic pre-conditioning prior to esophagectomy^[37-43].

Intra-operative assessment of the gastric conduit

Visual intra-operative clinical assessment of the conduit perfusion is not particularly accurate as it relies on the subjective assessment of the colour and viability of the conduit and rate of bleeding at the anastomotic edge. Newer more modern and less subjective ways to assess tissue perfusion have been developed to aid in intra-operative assessment of gastric conduit viability. These techniques include fluorescence angiography, laser Doppler flowmetry and spectrophotometry, transmucosal oxygen saturation measurement, hydrogen clearance, visible light

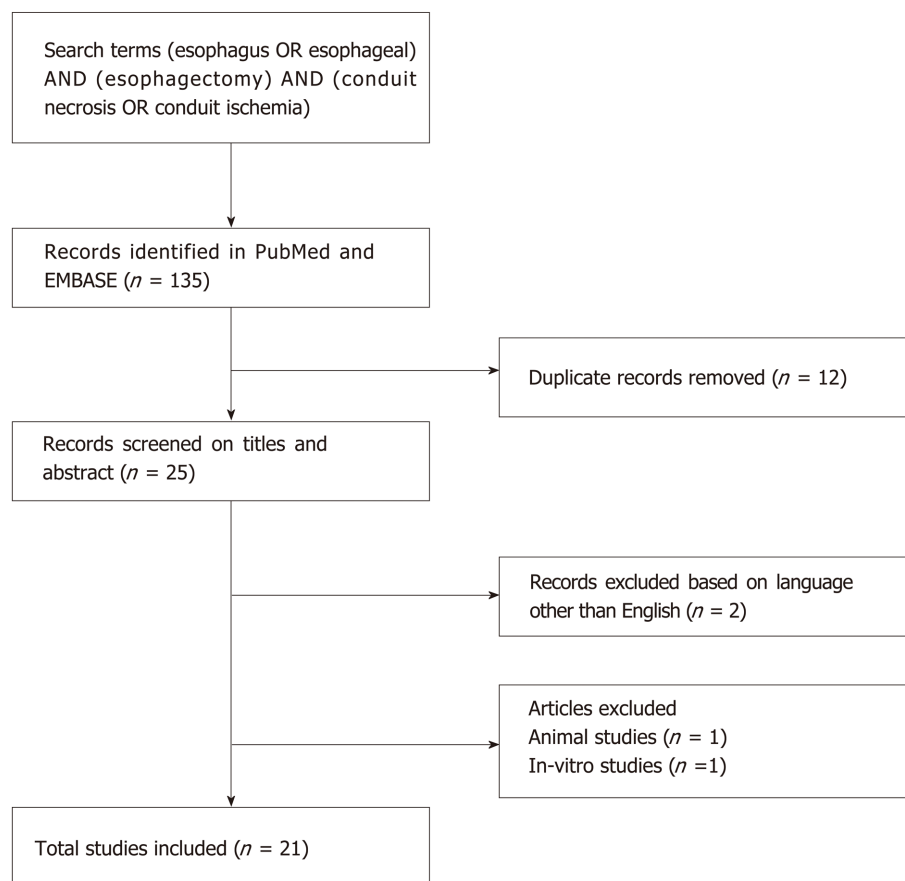


Figure 1 Schematic diagram of procedural methodology.

spectroscopy, intra-operative endoscopy, and laser-induced fluorescence of indocyanine green (ICG)^[44-57].

The most common intra-operative devices used are Doppler ultrasound and ICG fluorescence imaging, mainly because they provide adequate visualization of the vessel networks of the gastric wall^[47-56]. ICG fluorescence imaging is considered to be a potential technique for higher sensitivity, especially after the encouraging results in different tumours, mainly in colorectal and liver cancer^[58]. Table 5 illustrates the most important studies of ICG fluorescence imaging in esophageal cancer^[47-56]. The vast majority of the published articles conclude that ICG fluorescence is useful for the prediction of the risk of anastomotic leak and also can be used for intraoperative modifications with better placement of the anastomosis and resection of the ischaemic area of the fundus^[47-56]. A randomised trial in this area specifically assessing the use of ICG assessment during esophagectomy is greatly required.

MANAGEMENT OPTIONS

Intra-operative conduit ischaemia

Acute intraoperative conduit ischaemia is a challenging scenario for esophagogastric surgeons. Should the conduit look hypo-perfused due to inadequate blood flow, recognising it in a timely fashion is essential if the conduit is to be saved. The hiatus should be checked to ensure it is not too tight and there is no impingement on the gastroepiploic vessels. Additionally, the gastric conduit should be checked to ensure it is not twisted. If the situation develops during the neck phase of the procedure, then the thoracic inlet should be checked for tightness. This can be released to some extent by resection of the sternal head and the manubrium; which is mandatory should the graft be positioned at this level substernally. If there is any doubt as to the viability of the conduit, anastomosis should not be performed. If it looks like the gastric conduit is unsalvageable then it should be resected and a cervical esophagostomy formed, with subsequent plans for a delayed reconstruction instituted. Delayed reconstruction

Table 3 Risk factors for gastric conduit necrosis

Patient factors	Technical Factors	Post-operative factors
Peripheral arterial disease	Twists in the gastric conduit	Post-operative hypotension and shock
Ischaemic heart disease	Tight hiatus	Vasoconstrictor use
Stenosis of the Coeliac trunk and Aorta ^[27]	Injury to the gastro-epiploic vessels	
Cardiac failure/ impaired ejection fraction	Minimal access procedures ^[21]	
Diabetes	Tacking sutures to the pre-vertebral fascia during transhiatal esophagectomy ^[22]	
	Tight thoracic inlet when a neck anastomosis is performed	
	Narrow gastric conduit	

can be performed with colon or small bowel, depending on the clinical situation.

Oezcelik *et al*^[59] published a series of 554 patients who underwent esophagectomy with gastric pullup and described an interesting strategy. In 37 patients (7%), the combination of an ischemic graft and substantial comorbid conditions prompted a delayed neck anastomosis. To avoid a high risk anastomosis in these patients, the gastric conduit was brought up and secured in the neck, and a cervical esophagostomy was constructed. Subsequently, a delayed esophagogastric anastomosis was performed through neck incision. Outcomes were analysed at a median of 22 mo. None of the patients has developed conduit ischemia or necrosis. The authors reported well-perfused conduits at the time of reconstruction without anastomotic leak, sepsis or wound infections post-operatively. They concluded that delayed reconstruction is strongly recommended for patients with significant comorbidities and for patients with inadequate blood supply of the conduit during the esophagectomy^[59].

Post-operative conduit ischaemia /necrosis

Patients with mild ischaemic changes with a small anastomotic leak may be managed successfully with an esophageal stent, naso-gastric drainage and enteral feeding^[60]. Liang *et al*^[61] reported two patients who were salvaged using a temporary removable self-expandable metal stent (SEMS) placed endoscopically and concomitant chest washout. However, both patients had type II conduit necrosis which is most likely to have successful outcome using SEMS. The aforementioned management is considered to be effective only in a very cautiously selected patients and it is recommended only if there is minor gastric conduit necrosis, without inflammation of the mediastinum and if the patient remains clinically stable. Patients without an associated anastomotic leak should be closely monitored.

In selected cases with minor areas of peri-anastomotic ischaemia or conduit necrosis in a stable patient with no major comorbidity, the anastomosis may be suitable for re-fashioning or repaired over a T-tube. If this is not the case, it is safer to completely take down the anastomosis at the second thoracotomy with debridement of necrotic tissue, wide drainage, proximal diversion with an end cervical esophagostomy and replacement of remaining stomach within the abdomen^[3]. Nutritional access with a feeding jejunostomy should be obtained if this has not already been achieved.

Delayed reconstruction after conduit necrosis

Reconstruction can be performed in a few ways following the take down of the necrotic conduit.

Colonic reconstruction

Esophageal replacement by colonic interposition is an uncommon procedure. These reconstructions can be pedicled or free grafts with or without venous or arterial supercharging. When the colon is used as the conduit, graft necrosis after neck anastomosis has been reported as high as 16%^[62]. This is likely exacerbated by colonic bacterial contamination, particularly if the patient has not been prepped. This is usually fatal if not recognised and treated early. Fisher *et al*^[63] sought to identify the frequency of this operation in England, identify techniques and associated problems from the two largest centres performing this procedure. Fifty-two percent preferred to use the left colon with 81% preferring a substernal placement. All patients had early satiety, 20 described dysphagia and 18 regularly took anti-reflux medication. Colon interposition results in an acceptable long-term health-related quality of life. Few

Table 4 Published Series of gastric ischaemic pre-conditioning prior to oesophagectomy in humans

Ref.	Country	Study design	Patient (n)	Days prior to resection	Technique	Results
Akiyama <i>et al</i> ^[39] , 1998	Japan	Retrospective	51	14	Preoperative embolization of left gastric, right gastric, and splenic artery	PET is a safe procedure that contributes to the decrease in the frequency of anastomotic dehiscence after esophageal operation
Isomura <i>et al</i> ^[43] , 1999	Japan	Retrospective	37	14	Preoperative embolization of left gastric, right gastric, and splenic artery	Reduction of postoperative anastomotic leakage in esophageal reconstruction
Nguyen <i>et al</i> ^[40] , 2006	United States	Retrospective	9	12 ± 10	Ligation of left gastric vessels	There were no anastomotic leaks in the 9 patients
Veeramootoo <i>et al</i> ^[38] , 2012	United Kingdom	Randomized controlled trial	16	14	Ligation of left gastric vessels	Laparoscopic ischemic conditioning does not translate into an improved perfusion of the gastric conduit tip
Wajed <i>et al</i> ^[37] , 2012	United Kingdom	Retrospective	67	14	Ligation of left gastric vessels	9 of them (13.4%) developed gastric conduit failure
Bludau <i>et al</i> ^[42] , 2010	Germany	Prospective	19	4-5	Ligation of short gastric arteries and left gastric artery	Ischemic conditioning improves Mucosal oxygen saturation in the anastomotic region at the time of reconstruction
Holscher <i>et al</i> ^[41] , 2007	Germany	Retrospective	83	3-7	Laparoscopic gastric devascularisation preserving right gastroepiploic arcade	Feasible and safe technique that may contribute to the reduction of postoperative morbidity and mortality after esophagectomy

PET: Pre-operative embolization therapy.

centres regularly perform this operation, and centralizing to high-volume centres may lead to better outcomes^[63]. Supercharged colon interposition is an alternative surgical technique for the reduction of ischemic related morbidity^[64,65]. In addition to the abdominal blood supply, the venous drainage and arterial supply is augmented with additional microvascular anastomoses in the neck (branches of the carotid artery or jugular veins depending on anatomy). Small series have showed low rates of leak, bowel ischaemia and graft loss. In a retrospective series by Fujita and co-workers^[64], 24 patients underwent reconstruction without supercharged colon interposition and were compared with 29 patients with supercharged colon. The vast majority of patients underwent thoracic esophagectomy. The results revealed that the group who received supercharged colon had a significantly lower rate of conduit necrosis and anastomotic leak. These techniques require the skills of a microvascular surgeon.

According to the literature, colon interposition due to gastric conduit necrosis is recommended only after esophageal diversion and delayed neck reconstruction^[66,67]. Esophageal diversion is considered to be a staged damage-control operation in combination with mediastinal drainage, nutritional supplementation *via* a feeding jejunostomy and antimicrobial therapy.

Jejunal reconstruction

Jejunal interposition with or without vascular supercharging is an alternative option for esophageal reconstruction^[68]. Advantages of this technique include the lack of

Table 5 Clinical studies for the evaluation of ischemic gastric conditioning using indocyanine green fluorescence imaging

Ref.	Year	Patient (n)	Imaging system	Dose of ICG	Study design	Conclusions
Kitagawa <i>et al</i> ^[47]	2017	72	PDE	2.5 mg	Retrospective	Intraoperative ICG assessment of the gastric tube was associated with postoperative endoscopic assessment grading of anastomosis during ER
Ohi <i>et al</i> ^[51]	2017	120	PDE	2.5 mg	Retrospective	ICG fluorescein imaging might decrease the incidence of anastomotic leak following ER
Koyanagi <i>et al</i> ^[48]	2016	40	PDE	2.5 or 1.25 mg	Prospective cohort	ICG fluorescence is a useful means to predict the risk of anastomotic leakage after ER
Yukaya <i>et al</i> ^[55]	2015	27	Hyper Eye Medical System	0.1 mg	Prospective cohort	ICG fluorescence can be used to quantitatively measure arterial blood flow and venous return of the reconstructed gastric tube in patients undergoing ER
Zehetner <i>et al</i> ^[56]	2015	150	SPY Imaging System (Novadaq)	2.5 mg	Prospective cohort	The use of laser-assisted fluorescent-dye angiography (LAA) may contribute to reduced anastomotic morbidity
Sarkaria <i>et al</i> ^[53]	2014	30	NIFI technology	10 mg	Prospective cohort	ICG fluorescence may be a useful adjunct during MIE gastric mobilization, especially early in the learning curve for these operations
Rino <i>et al</i> ^[52]	2014	33	PDE	2.5 mg	Prospective cohort	ICG fluorescence can be used to evaluate the blood supply to the reconstructed stomach in patients undergoing ER for esophageal cancer
Kumagai <i>et al</i> ^[49]	2014	20	PDE	NA	Prospective cohort	ICG fluorescence method has potential usefulness for evaluation of blood flow in the gastric tube during ER
Pacheco <i>et al</i> ^[46]	2013	11	SPY Imaging System (Novadaq)	NA	Retrospective	ICG fluorescence might be useful in patients undergoing ER

Murawaet <i>al</i> ^[50]	2012	15	PDE	2.5 mg	Prospective cohort	ICG fluorescence imaging allows for intraoperative modifications, but patient's comorbidities and general health may also increase the risk of anastomosis leakage
Shimad <i>et al</i> ^[54]	2011	40	PDE	2.5 mg	Prospective cohort	The microcirculation detected by ICG fluorescence did not necessarily provide appropriate blood supply for a viable anastomosis

ICG: Indocyanine green; ER: Esophageal resection; PDE: Hamamatsu Photonics K.K, Hamamatsu, Japan.

need for pre-operative bowel preparation, it is relatively easy to mobilise, sizable mesenteric blood vessels, comparable size to esophagus, bowel anastomoses with low leak rates and active peristalsis. Disadvantages included that it is a rare form of esophageal replacement and only a few centres have experience of its use. Depending on circumstances its use will usually require the help of a micro-vascular surgeon to either supercharge or free graft the blood supply in the neck vessels. Augmentation of pedicle blood supply increases the length of conduit and restores more blood flow, which allows a neck anastomosis of the jejunum to be performed in the left neck^[69]. Ascoti *et al*^[68], reviewed retrospectively 26 patients who underwent reconstruction with supercharged pedicled jejunum and found a 19.2% had cervical anastomotic leak, 7.7% of graft loss and there were no mortalities. All patients underwent oesophageal reconstruction with a neck anastomosis. Use of jejunum is contra-indicated in Crohn's disease, short bowel syndrome and short fatty mesentery. Jejunal conduit necrosis is usually due to technical errors, poor vascular supply, venous thrombosis and perioperative hypotension^[70]. According to the literature, jejunal interposition after gastric or colon conduit necrosis is indicated only after esophageal diversion and delayed neck reconstruction^[64,65].

Myocutaneous flap reconstruction

An alternative method for the management of conduit necrosis using muscle flaps has been proposed in the literature. These are more applicable for dealing with partial defects in the gastric conduit in the neck, but can be used in selected cases for salvage of completely circumferential defects. Myocutaneous flap is utilized usually in order to reconstruct gastric conduit defect due to conduit necrosis as well as to cover anastomotic defect. However, is not recommended for complete oesophageal neck reconstruction by formation of tube-style tissue due to high rate of complications including stenosis and necrosis^[71]. Sternocleidomastoid, pectoralis major and trapezius flaps have all been reported to cover tissue defects in the neck. However, much of the published literature is from individual case reports. Furthermore, fasciocutaneous free flaps, for example anterolateral thigh and radial forearm have also been reported which can replace the oesophagus in the neck area with the skin side tubularised. A single pedicled pectoralis major myocutaneous for cervical-oesophageal reconstruction is the most commonly used flap due to the fact that there is no need for free tissue transfer and also because it is easier to harvest the muscle due to its location to the chest^[72]. This flap has a lower rate of flap failure compared with free flaps for cervical-oesophageal reconstruction^[73].

Morbidity and mortality

Mortality of gastric conduit necrosis has been reported to be as high as 90%^[4]. Esophageal conduit necrosis is an uncommon but disastrous complication of esophageal surgery. Postoperative conduit ischemia is reported internationally. Average rates of ischemic complications for stomach, colon, and jejunum are 3.2%, 5.1%, and 4.2%, respectively^[4].

Davis *et al*^[16] showed that gastric conduit reconstruction has less rate of anastomotic leak and conduit ischemia in compare with colon reconstruction. Moorehead *et al*^[17], in their review of 760 esophagectomy patients in whom the stomach, colon, or jejunum was used for chest or neck reconstruction, showed that gastric conduit had the lowest rate of ischemia (1%), followed by small bowel (11%), while colon had the highest rate (13.3%). Moreover, Briel *et al*^[19] compared colon and gastric conduit after two or three

stage esophagectomy and they reported 10% colon conduit ischemia and 7% gastric conduit ischemia.

CONCLUSION

In spite of recent advances in esophageal cancer surgery, the management of conduit necrosis is extremely challenging. Management options include conservative treatment and more aggressive treatments such as stent insertion, surgical debridement and repair of the esophagus using jejunum, colon or a musculocutaneous flap. Conservative management includes close clinical monitoring of patient symptoms and signs including heart rate, blood pressure, temperature, respiratory rate and oxygen saturations in addition to blood results and the administration of broad spectrum antibiotics. Identifying and acting upon any deterioration is vital. While there are several interventional options, deciding upon the most appropriate for each individual patient, is challenging for the most experienced surgeon. All interventional options are high risk. The most effective treatment method remains controversial.

The literature available for review is limited and so surgeons should endeavour to report all cases of esophageal necrosis, their management whether successful or unsuccessful. Several multi-institutional databases are in current use. For example, Esodata (<https://www.esodata.org>) under the auspices of ISDE - International Society for the Diseases of Esophagus - have developed a web portal for creating and sharing expert views and current knowledge on complications and outcomes esophageal surgery. In addition, the oesophagogastric anastomotic leak audit (<http://www.ogaa.org.uk/>) aims to collect data of anastomotic complications from esophagectomy, including conduit necrosis, from a large group of international esophageal units to define the accurate incidence and outcome of this problem. It is only with prospective and standardised data from these multi-centre registries that we can help address the void of high quality literature of this important topic. It is hoped that once we have standardised data of many patients with this devastating condition, that the precise management strategy to obtain best outcomes will become clear.

As with most complex surgical procedures, high volume surgeons and high volume centres have significantly higher success rates with esophageal resections^[74,75]. Knowledge of the potential complications, identifying them in a timely fashion and managing them appropriately is essential. The management of this problem should be individualised to the specific patient depending on severity of ischaemia and clinical features. The description in 1942 by Churchill and Sweet^[76] of their early successes with esophago-enteric anastomoses due to “unusual attention to detail” and technical “exactitude” remain a cornerstone for future advances by surgeons involved in esophageal resection and replacement.

REFERENCES

- 1 **Torre LA**, Bray F, Siegel RL, Ferlay J, Lortet-Tieulent J, Jemal A. Global cancer statistics, 2012. *CA Cancer J Clin* 2015; **65**: 87-108 [PMID: 25651787 DOI: 10.3322/caac.21262]
- 2 **Rutegård M**, Lagergren P, Rouvelas I, Mason R, Lagergren J. Surgical complications and long-term survival after esophagectomy for cancer in a nationwide Swedish cohort study. *Eur J Surg Oncol* 2012; **38**: 555-561 [PMID: 22483704 DOI: 10.1016/j.ejso.2012.02.177]
- 3 **Cassivi SD**. Leaks, strictures, and necrosis: a review of anastomotic complications following esophagectomy. *Semin Thorac Cardiovasc Surg* 2004; **16**: 124-132 [PMID: 15197687 DOI: 10.1053/j.semtcvs.2004.03.011]
- 4 **Wormuth JK**, Heitmiller RF. Esophageal conduit necrosis. *Thorac Surg Clin* 2006; **16**: 11-22 [PMID: 16696279 DOI: 10.1016/j.thorsurg.2006.01.003]
- 5 **Boyle NH**, Pearce A, Hunter D, Owen WJ, Mason RC. Intraoperative scanning laser Doppler flowmetry in the assessment of gastric tube perfusion during esophageal resection. *J Am Coll Surg* 1999; **188**: 498-502 [PMID: 10235577 DOI: 10.1016/S1072-7515(99)00016-2]
- 6 **Griffin SM**, Shaw IH, Dresner SM. Early complications after Ivor Lewis subtotal esophagectomy with two-field lymphadenectomy: risk factors and management. *J Am Coll Surg* 2002; **194**: 285-297 [PMID: 11893132 DOI: 10.1016/S1072-7515(01)01177-2]
- 7 **Veeramootoo D**, Parameswaran R, Krishnadas R, Froeschle P, Cooper M, Berrisford RG, Wajed SA. Classification and early recognition of gastric conduit failure after minimally invasive esophagectomy. *Surg Endosc* 2009; **23**: 2110-2116 [PMID: 19067058 DOI: 10.1007/s00464-008-0233-1]
- 8 **Low DE**, Alderson D, Ceconello I, Chang AC, Darling GE, D'Journo XB, Griffin SM, Hölscher AH, Hofstetter WL, Jobe BA, Kitagawa Y, Kucharczuk JC, Law SY, Lerut TE, Maynard N, Pera M, Peters JH, Pramesh CS, Reynolds JV, Smithers BM, van Lanschot JJ. International Consensus on Standardization of Data Collection for Complications Associated With Esophagectomy: Esophagectomy Complications Consensus Group (ECCG). *Ann Surg* 2015; **262**: 286-294 [PMID: 25607756 DOI: 10.1097/SLA.0000000000001098]

- 9 **Jones CM**, Clarke B, Heah R, Griffiths EA. Should routine assessment of anastomotic integrity be undertaken using radiological contrast swallow after oesophagectomy with intra-thoracic anastomosis? Best evidence topic (BET). *Int J Surg* 2015; **20**: 158-162 [PMID: [26166736](#) DOI: [10.1016/j.ijsu.2015.06.076](#)]
- 10 **Jones CM**, Heah R, Clarke B, Griffiths EA. Should routine radiological assessment of anastomotic integrity be performed after oesophagectomy with cervical anastomosis? Best evidence topic (BET). *Int J Surg* 2015; **15**: 90-94 [PMID: [25667064](#) DOI: [10.1016/j.ijsu.2015.01.034](#)]
- 11 **Low DE**. Diagnosis and management of anastomotic leaks after esophagectomy. *J Gastrointest Surg* 2011; **15**: 1319-1322 [PMID: [21557015](#) DOI: [10.1007/s11605-011-1511-0](#)]
- 12 **Oezcelik A**, Banki F, Ayazi S, Abate E, Zehetner J, Sohn HJ, Hagen JA, DeMeester SR, Lipham JC, Palmer SL, DeMeester TR. Detection of gastric conduit ischemia or anastomotic breakdown after cervical esophagogastrectomy: the use of computed tomography scan versus early endoscopy. *Surg Endosc* 2010; **24**: 1948-1951 [PMID: [20135175](#) DOI: [10.1007/s00464-010-0884-6](#)]
- 13 **Maish MS**, DeMeester SR, Choustoulakis E, Briel JW, Hagen JA, Peters JH, Lipham JC, Bremner CG, DeMeester TR. The safety and usefulness of endoscopy for evaluation of the graft and anastomosis early after esophagectomy and reconstruction. *Surg Endosc* 2005; **19**: 1093-1102 [PMID: [16027986](#) DOI: [10.1007/s00464-004-8816-y](#)]
- 14 **Page RD**, Asmat A, McShane J, Russell GN, Pennefather SH. Routine endoscopy to detect anastomotic leakage after esophagectomy. *Ann Thorac Surg* 2013; **95**: 292-298 [PMID: [23200235](#) DOI: [10.1016/j.athoracsur.2012.09.048](#)]
- 15 **Moher D**, Liberati A, Tetzlaff J, Altman DG; PRISMA Group. Preferred reporting items for systematic reviews and meta-analyses: the PRISMA statement. *PLoS Med* 2009; **6**: e1000097 [PMID: [19621072](#) DOI: [10.1371/journal.pmed.1000097](#)]
- 16 **Davis PA**, Law S, Wong J. Colonic interposition after esophagectomy for cancer. *Arch Surg* 2003; **138**: 303-308 [PMID: [12611579](#) DOI: [10.1001/archsurg.138.3.303](#)]
- 17 **Moorehead RJ**, Wong J. Gangrene in esophageal substitutes after resection and bypass procedures for carcinoma of the esophagus. *Hepatogastroenterology* 1990; **37**: 364-367 [PMID: [2210602](#) DOI: [10.1007/BF02150756](#)]
- 18 **Luketich JD**, Pennathur A, Awais O, Levy RM, Keeley S, Shende M, Christie NA, Weksler B, Landreneau RJ, Abbas G, Schuchert MJ, Nason KS. Outcomes after minimally invasive esophagectomy: review of over 1000 patients. *Ann Surg* 2012; **256**: 95-103 [PMID: [22668811](#) DOI: [10.1097/SLA.0b013e3182590603](#)]
- 19 **Briel JW**, Tamhankar AP, Hagen JA, DeMeester SR, Johansson J, Choustoulakis E, Peters JH, Bremner CG, DeMeester TR. Prevalence and risk factors for ischemia, leak, and stricture of esophageal anastomosis: gastric pull-up versus colon interposition. *J Am Coll Surg* 2004; **198**: 536-541; discussion 541-542 [PMID: [15051003](#) DOI: [10.1016/j.jamcollsurg.2003.11.026](#)]
- 20 **Blencowe NS**, Strong S, McNair AG, Brookes ST, Crosby T, Griffin SM, Blazeby JM. Reporting of short-term clinical outcomes after esophagectomy: a systematic review. *Ann Surg* 2012; **255**: 658-666 [PMID: [22395090](#) DOI: [10.1097/SLA.0b013e3182480a6a](#)]
- 21 **Berrisford RG**, Veeramootoo D, Parameswaran R, Krishnadas R, Wajed SA. Laparoscopic ischaemic conditioning of the stomach may reduce gastric-conduit morbidity following total minimally invasive oesophagectomy. *Eur J Cardiothorac Surg* 2009; **36**: 888-93; discussion 893 [PMID: [19615914](#) DOI: [10.1016/j.ejcts.2009.01.055](#)]
- 22 **Iannettoni MD**, Whyte RI, Orringer MB. Catastrophic complications of the cervical esophagogastrectomy anastomosis. *J Thorac Cardiovasc Surg* 1995; **110**: 1493-1500; discussion 1500-1501 [PMID: [7475201](#) DOI: [10.1016/S0022-5223\(95\)70072-2](#)]
- 23 **Wigley C**, Athanasίου A, Bhatti A, Sheikh A, Hodson J, Bedford M, Griffiths EA. Does the Pittsburgh Severity Score predict outcome in esophageal perforation? *Dis Esophagus* 2019; **32** [PMID: [30496380](#) DOI: [10.1093/dote/doy109](#)]
- 24 **Athanasίου A**, Spartalis M, Spartalis E. Platelets-to-lymphocyte ratio and esophageal cancer. *J Thorac Dis* 2018; **10**: E650-E651 [PMID: [30233905](#) DOI: [10.21037/jtd.2018.07.41](#)]
- 25 **Athanasίου A**, Spartalis E, Spartalis M, Charalabopoulos A. Obesity Paradox in Esophageal Cancer: Fashion or Reality? *Ann Thorac Surg* 2019; **107**: 686-687 [PMID: [30268533](#) DOI: [10.1016/j.athoracsur.2018.07.071](#)]
- 26 **Athanasίου A**, Spartalis E, Spartalis M. Prognostic value of platelet-to-lymphocyte ratio in oncologic outcomes of esophageal cancer: what should we expect from a meta-analysis? *Int J Biol Markers* 2018; **1724600818785128** [PMID: [29984613](#) DOI: [10.1177/1724600818785128](#)]
- 27 **Lainas P**, Fuks D, Gaujoux S, Machroub Z, Fregeville A, Perniceni T, Mal F, Dousset B, Gayet B. Preoperative imaging and prediction of oesophageal conduit necrosis after esophagectomy for cancer. *Br J Surg* 2017; **104**: 1346-1354 [PMID: [28493483](#) DOI: [10.1002/bjs.10558](#)]
- 28 **Dickinson KJ**, Blackmon SH. Management of Conduit Necrosis Following Esophagectomy. *Thorac Surg Clin* 2015; **25**: 461-470 [PMID: [26515946](#) DOI: [10.1016/j.thorsurg.2015.07.008](#)]
- 29 **Liebermann-Meffert DM**, Meier R, Siewert JR. Vascular anatomy of the gastric tube used for esophageal reconstruction. *Ann Thorac Surg* 1992; **54**: 1110-1115 [PMID: [1449294](#) DOI: [10.1016/0003-4975\(92\)90077-H](#)]
- 30 **Urschel JD**. Esophagogastrectomy anastomotic leaks complicating esophagectomy: a review. *Am J Surg* 1995; **169**: 634-640 [PMID: [7771633](#) DOI: [10.1016/S0002-9610\(99\)80238-4](#)]
- 31 **Michelet P**, Roch A, D'Journo XB, Blayac D, Barrau K, Papazian L, Thomas P, Auffray JP. Effect of thoracic epidural analgesia on gastric blood flow after oesophagectomy. *Acta Anaesthesiol Scand* 2007; **51**: 587-594 [PMID: [17430321](#) DOI: [10.1111/j.1399-6576.2007.01290.x](#)]
- 32 **Al-Rawi OY**, Pennefather SH, Page RD, Dave I, Russell GN. The effect of thoracic epidural bupivacaine and an intravenous adrenaline infusion on gastric tube blood flow during esophagectomy. *Anesth Analg* 2008; **106**: 884-887, table of contents [PMID: [18292435](#) DOI: [10.1213/ane.0b013e318164f153](#)]
- 33 **Urschel JD**. Ischemic conditioning of the stomach may reduce the incidence of esophagogastrectomy anastomotic leaks complicating esophagectomy: a hypothesis. *Dis Esophagus* 1997; **10**: 217-219 [PMID: [9280083](#) DOI: [10.1093/dote/10.3.217](#)]
- 34 **Kechagias A**, van Rossum PS, Ruurda JP, van Hillegersberg R. Ischemic Conditioning of the Stomach in the Prevention of Esophagogastrectomy Anastomotic Leakage After Esophagectomy. *Ann Thorac Surg* 2016; **101**: 1614-1623 [PMID: [26857639](#) DOI: [10.1016/j.athoracsur.2015.10.034](#)]
- 35 **Crenshaw GD**, Shankar SS, Brown RE, Abbas AE, Bolton JS. Extracorporeal gastric stapling reduces the incidence of gastric conduit failure after minimally invasive esophagectomy. *Am Surg* 2010; **76**: 823-828

- [PMID: 20726411]
- 36 **Ramage L**, Deguara J, Davies A, Hamouda A, Tsigrits K, Forshaw M, Botha AJ. Gastric tube necrosis following minimally invasive oesophagectomy is a learning curve issue. *Ann R Coll Surg Engl* 2013; **95**: 329-334 [PMID: 23838494 DOI: 10.1308/003588413X13629960045751]
 - 37 **Wajed SA**, Veeramootoo D, Shore AC. Video. Surgical optimisation of the gastric conduit for minimally invasive oesophagectomy. *Surg Endosc* 2012; **26**: 271-276 [PMID: 21858577 DOI: 10.1007/s00464-011-1855-2]
 - 38 **Veeramootoo D**, Shore AC, Wajed SA. Randomized controlled trial of laparoscopic gastric ischemic conditioning prior to minimally invasive esophagectomy, the LOGIC trial. *Surg Endosc* 2012; **26**: 1822-1829 [PMID: 22302533 DOI: 10.1007/s00464-011-2123-1]
 - 39 **Akiyama S**, Kodera Y, Sekiguchi H, Kasai Y, Kondo K, Ito K, Takagi H. Preoperative embolization therapy for esophageal operation. *J Surg Oncol* 1998; **69**: 219-223 [PMID: 9881938 DOI: 10.1002/(SICI)1096-9098(199812)69:4<219::AID-JSO5>3.0.CO;2-7]
 - 40 **Nguyen NT**, Longoria M, Sabio A, Chalifoux S, Lee J, Chang K, Wilson SE. Preoperative laparoscopic ligation of the left gastric vessels in preparation for esophagectomy. *Ann Thorac Surg* 2006; **81**: 2318-2320 [PMID: 16731189 DOI: 10.1016/j.athoracsur.2005.05.033]
 - 41 **Hölscher AH**, Schneider PM, Gutschow C, Schröder W. Laparoscopic ischemic conditioning of the stomach for esophageal replacement. *Ann Surg* 2007; **245**: 241-246 [PMID: 17245177 DOI: 10.1097/01.sla.0000245847.40779.10]
 - 42 **Bludau M**, Hölscher AH, Vallböhmer D, Gutschow C, Schröder W. Ischemic conditioning of the gastric conduit prior to esophagectomy improves mucosal oxygen saturation. *Ann Thorac Surg* 2010; **90**: 1121-1126 [PMID: 20868800 DOI: 10.1016/j.athoracsur.2010.06.003]
 - 43 **Isomura T**, Itoh S, Endo T, Akiyama S, Maruyama K, Ishiguchi T, Ishigaki T, Takagi H. Efficacy of gastric blood supply redistribution by transarterial embolization: preoperative procedure to prevent postoperative anastomotic leaks following esophagoplasty for esophageal carcinoma. *Cardiovasc Intervent Radiol* 1999; **22**: 119-123 [PMID: 10094991 DOI: 10.1007/s002709900346]
 - 44 **Bludau M**, Vallböhmer D, Gutschow C, Hölscher AH, Schröder W. Quantitative measurement of gastric mucosal microcirculation using a combined laser Doppler flowmeter and spectrophotometer. *Dis Esophagus* 2008; **21**: 668-672 [PMID: 18564159 DOI: 10.1111/j.1442-2050.2008.00856.x]
 - 45 **Karliczek A**, Benaron DA, Baas PC, Zeebregts CJ, van der Stoel A, Wiggers T, Plukker JT, van Dam GM. Intraoperative assessment of microperfusion with visible light spectroscopy in esophageal and colorectal anastomoses. *Eur Surg Res* 2008; **41**: 303-311 [PMID: 18797169 DOI: 10.1159/000155880]
 - 46 **Pacheco PE**, Hill SM, Henriques SM, Paulsen JK, Anderson RC. The novel use of intraoperative laser-induced fluorescence of indocyanine green tissue angiography for evaluation of the gastric conduit in esophageal reconstructive surgery. *Am J Surg* 2013; **205**: 349-52; discussion 352-3 [PMID: 23414958 DOI: 10.1016/j.amjsurg.2012.11.005]
 - 47 **Kitagawa H**, Namikawa T, Iwabu J, Fujisawa K, Uemura S, Tsuda S, Hanazaki K. Assessment of the blood supply using the indocyanine green fluorescence method and postoperative endoscopic evaluation of anastomosis of the gastric tube during esophagectomy. *Surg Endosc* 2018; **32**: 1749-1754 [PMID: 28916846 DOI: 10.1007/s00464-017-5857-6]
 - 48 **Koyanagi K**, Ozawa S, Oguma J, Kazuno A, Yamazaki Y, Ninomiya Y, Ochiai H, Tachimori Y. Blood flow speed of the gastric conduit assessed by indocyanine green fluorescence: New predictive evaluation of anastomotic leakage after esophagectomy. *Medicine (Baltimore)* 2016; **95**: e4386 [PMID: 27472732 DOI: 10.1097/MD.0000000000004386]
 - 49 **Kumagai Y**, Ishiguro T, Haga N, Kuwabara K, Kawano T, Ishida H. Hemodynamics of the reconstructed gastric tube during esophagectomy: assessment of outcomes with indocyanine green fluorescence. *World J Surg* 2014; **38**: 138-143 [PMID: 24196170 DOI: 10.1007/s00268-013-2237-9]
 - 50 **Murawa D**, Hünerbein M, Sychala A, Nowaczyk P, Polom K, Murawa P. Indocyanine green angiography for evaluation of gastric conduit perfusion during esophagectomy--first experience. *Acta Chir Belg* 2012; **112**: 275-280 [PMID: 23008991 DOI: 10.1080/00015458.2012.11680838]
 - 51 **Ohi M**, Toiyama Y, Mohri Y, Saigusa S, Ichikawa T, Shimura T, Yasuda H, Okita Y, Yoshizawa S, Kobayashi M, Araki T, Inoue Y, Kusunoki M. Prevalence of anastomotic leak and the impact of indocyanine green fluorescence imaging for evaluating blood flow in the gastric conduit following esophageal cancer surgery. *Esophagus* 2017; **14**: 351-359 [PMID: 28983231 DOI: 10.1007/s10388-017-0585-5]
 - 52 **Rino Y**, Yukawa N, Sato T, Yamamoto N, Tamagawa H, Hasegawa S, Oshima T, Yoshikawa T, Masuda M, Imada T. Visualization of blood supply route to the reconstructed stomach by indocyanine green fluorescence imaging during esophagectomy. *BMC Med Imaging* 2014; **14**: 18 [PMID: 24885891 DOI: 10.1186/1471-2342-14-18]
 - 53 **Sarkaria IS**, Bains MS, Finley DJ, Adusumilli PS, Huang J, Rusch VW, Jones DR, Rizk NP. Intraoperative near-infrared fluorescence imaging as an adjunct to robotic-assisted minimally invasive esophagectomy. *Innovations (Phila)* 2014; **9**: 391-393 [PMID: 25238427 DOI: 10.1097/IMI.0000000000000091]
 - 54 **Shimada Y**, Okumura T, Nagata T, Sawada S, Matsui K, Hori R, Yoshioka I, Yoshida T, Osada R, Tsukada K. Usefulness of blood supply visualization by indocyanine green fluorescence for reconstruction during esophagectomy. *Esophagus* 2011; **8**: 259-266 [PMID: 22557942 DOI: 10.1007/s10388-011-0291-7]
 - 55 **Yukawa T**, Saeki H, Kasagi Y, Nakashima Y, Ando K, Imamura Y, Ohgaki K, Oki E, Morita M, Maehara Y. Indocyanine Green Fluorescence Angiography for Quantitative Evaluation of Gastric Tube Perfusion in Patients Undergoing Esophagectomy. *J Am Coll Surg* 2015; **221**: e37-e42 [PMID: 26206660 DOI: 10.1016/j.jamcollsurg.2015.04.022]
 - 56 **Zehetner J**, DeMeester SR, Alicuben ET, Oh DS, Lipham JC, Hagen JA, DeMeester TR. Intraoperative Assessment of Perfusion of the Gastric Graft and Correlation With Anastomotic Leaks After Esophagectomy. *Ann Surg* 2015; **262**: 74-78 [PMID: 25029436 DOI: 10.1097/SLA.0000000000000811]
 - 57 **Athanasίου A**, Spartalis E, Spartalis M, Griffiths EA. Management of oesophageal perforation based on the Pittsburgh Perforation Severity Score: still a matter of debate. *Eur J Cardiothorac Surg* 2019; pii: ezz061 [PMID: 30843053 DOI: 10.1093/ejcts/ezz061]
 - 58 **Ishizawa T**, Fukushima N, Shibahara J, Masuda K, Tamura S, Aoki T, Hasegawa K, Beck Y, Fukayama M, Kokudo N. Real-time identification of liver cancers by using indocyanine green fluorescent imaging. *Cancer* 2009; **115**: 2491-2504 [PMID: 19326450 DOI: 10.1002/ncr.24291]
 - 59 **Oezcelik A**, Banki F, DeMeester SR, Leers JM, Ayazi S, Abate E, Hagen JA, Lipham JC, DeMeester TR.

- Delayed esophagogastrectomy: a safe strategy for management of patients with ischemic gastric conduit at time of esophagectomy. *J Am Coll Surg* 2009; **208**: 1030-1034 [PMID: 19476888 DOI: 10.1016/j.jamcollsurg.2009.02.055]
- 60 **Liang DH**, Hwang E, Meisenbach LM, Kim MP, Chan EY, Khaitan PG. Clinical outcomes following self-expanding metal stent placement for esophageal salvage. *J Thorac Cardiovasc Surg* 2017; **154**: 1145-1150 [PMID: 28416335 DOI: 10.1016/j.jtcvs.2017.03.051]
- 61 **Liang DH**, Meisenbach LM, Kim MP, Chan EY, Khaitan PG. Management of gastric conduit dehiscence with self-expanding metal stents: a case report on salvaging the gastric conduit. *J Cardiothorac Surg* 2017; **12**: 4 [PMID: 28122632 DOI: 10.1186/s13019-017-0570-z]
- 62 **Swisher SG**, Deford L, Merriman KW, Walsh GL, Smythe R, Vaporciyan A, Ajani JA, Brown T, Komaki R, Roth JA, Putnam JB. Effect of operative volume on morbidity, mortality, and hospital use after esophagectomy for cancer. *J Thorac Cardiovasc Surg* 2000; **119**: 1126-1132 [PMID: 10838528 DOI: 10.1067/mtc.2000.105644]
- 63 **Fisher RA**, Griffiths EA, Evison F, Mason RC, Zylstra J, Davies AR, Alderson D, Gossage JA. A national audit of colonic interposition for esophageal replacement. *Dis Esophagus* 2017; **30**: 1-10 [PMID: 28375436 DOI: 10.1093/dote/dow003]
- 64 **Fujita H**, Yamana H, Sueyoshi S, Shima I, Fujii T, Shirouzu K, Inoue Y, Kiyokawa K, Tanabe HY, Tai Y, Inutsuka H. Impact on outcome of additional microvascular anastomosis--supercharge--on colon interposition for esophageal replacement: comparative and multivariate analysis. *World J Surg* 1997; **21**: 998-1003 [PMID: 9361517 DOI: 10.1007/s002689900339]
- 65 **Kesler KA**, Pillai ST, Birdas TJ, Rieger KM, Okereke IC, Ceppa D, Socas J, Starnes SL. "Supercharged" isoperistaltic colon interposition for long-segment esophageal reconstruction. *Ann Thorac Surg* 2013; **95**: 1162-1168; discussion 1168-1169 [PMID: 23434255 DOI: 10.1016/j.athoracsur.2013.01.006]
- 66 **Moremen JR**, Ceppa DP, Rieger KM, Birdas TJ. Substernal reconstruction following esophagectomy: operation of last resort? *J Thorac Dis* 2017; **9**: 5040-5045 [PMID: 29312708 DOI: 10.21037/jtd.2017.11.51]
- 67 **Moore JM**, Hooker CM, Molena D, Mungo B, Brock MV, Battafarano RJ, Yang SC. Complex Esophageal Reconstruction Procedures Have Acceptable Outcomes Compared With Routine Esophagectomy. *Ann Thorac Surg* 2016; **102**: 215-222 [PMID: 27217296 DOI: 10.1016/j.athoracsur.2016.02.039]
- 68 **Ascioti AJ**, Hofstetter WL, Miller MJ, Rice DC, Swisher SG, Vaporciyan AA, Roth JA, Putnam JB, Smythe WR, Feig BW, Mansfield PF, Pisters PW, Torres MT, Walsh GL. Long-segment, supercharged, pedicled jejunal flap for total esophageal reconstruction. *J Thorac Cardiovasc Surg* 2005; **130**: 1391-1398 [PMID: 16256794 DOI: 10.1016/j.jtcvs.2005.06.032]
- 69 **Swisher SG**, Hofstetter WL, Miller MJ. The supercharged microvascular jejunal interposition. *Semin Thorac Cardiovasc Surg* 2007; **19**: 56-65 [PMID: 17403459 DOI: 10.1053/j.semtcvs.2006.11.003]
- 70 **Baker CR**, Forshaw MJ, Gossage JA, Ng R, Mason RC. Long-term outcome and quality of life after supercharged jejunal interposition for oesophageal replacement. *Surgeon* 2015; **13**: 187-193 [PMID: 24507388 DOI: 10.1016/j.surge.2014.01.004]
- 71 **Onoda S**, Kimata Y, Koshimune S, Yamaguchi K, Shirakawa Y. Salvage operation using free vascularized tissue transfer to treat esophageal conduit necrosis. *Plast Reconstr Surg* 2013; **131**: 460e-461e [PMID: 23446615 DOI: 10.1097/PRS.0b013e31827c72ff]
- 72 **Yin K**, Xu H, Cooke DT, Pu LL. Successful management of oesophageal conduit necrosis by a single-stage reconstruction with the pedicled pectoralis major myocutaneous flap. *Interact Cardiovasc Thorac Surg* 2015; **21**: 124-126 [PMID: 25862095 DOI: 10.1093/icvts/ivv093]
- 73 **Teo KG**, Rozen WM, Acosta R. The pectoralis major myocutaneous flap. *J Reconstr Microsurg* 2013; **29**: 449-456 [PMID: 23588549 DOI: 10.1055/s-0033-1343832]
- 74 **Mamidanna R**, Ni Z, Anderson O, Spiegelhalter SD, Bottle A, Aylin P, Faiz O, Hanna GB. Surgeon Volume and Cancer Esophagectomy, Gastrectomy, and Pancreatectomy: A Population-based Study in England. *Ann Surg* 2016; **263**: 727-732 [PMID: 26501701 DOI: 10.1097/SLA.0000000000001490]
- 75 **Munasinghe A**, Markar SR, Mamidanna R, Darzi AW, Faiz OD, Hanna GB, Low DE. Is It Time to Centralize High-risk Cancer Care in the United States? Comparison of Outcomes of Esophagectomy Between England and the United States. *Ann Surg* 2015; **262**: 79-85 [PMID: 24979602 DOI: 10.1097/SLA.0000000000000805]
- 76 **Churchill ED**, Sweet RH. Transthoracic Resection of Tumors of the Esophagus and Stomach. *Ann Surg* 1942; **115**: 897-920 [PMID: 17858052 DOI: 10.1097/00000658-194210000-00004]



Published By Baishideng Publishing Group Inc
7041 Koll Center Parkway, Suite 160, Pleasanton, CA 94566, USA
Telephone: +1-925-2238242
Fax: +1-925-2238243
E-mail: bpgoffice@wjgnet.com
Help Desk: <https://www.f6publishing.com/helpdesk>
<https://www.wjgnet.com>

