

World Journal of *Clinical Cases*

World J Clin Cases 2019 June 26; 7(12): 1367-1534





REVIEW

- 1367 Biomarkers *vs* imaging in the early detection of hepatocellular carcinoma and prognosis
Balaceanu LA

ORIGINAL ARTICLE

Basic Study

- 1383 Study on gene expression patterns and functional pathways of peripheral blood monocytes reveals potential molecular mechanism of surgical treatment for periodontitis
Ma JJ, Liu HM, Xu XH, Guo LX, Lin Q

Case Control Study

- 1393 Clinical differentiation of acute appendicitis and right colonic diverticulitis: A case-control study
Sasaki Y, Komatsu F, Kashima N, Sato T, Takemoto I, Kijima S, Maeda T, Ishii T, Miyazaki T, Honda Y, Shimada N, Urita Y

Retrospective Study

- 1403 Feasibility of prostatectomy without prostate biopsy in the era of new imaging technology and minimally invasive techniques
Xing NZ, Wang MS, Fu Q, Yang FY, Li CL, Li YJ, Han SJ, Xiao ZJ, Ping H
- 1410 Safety and efficacy of transfemoral intrahepatic portosystemic shunt for portal hypertension: A single-center retrospective study
Zhang Y, Liu FQ, Yue ZD, Zhao HW, Wang L, Fan ZH, He FL

Observational Study

- 1421 Impact of gastroesophageal reflux disease on the quality of life of Polish patients
Gorczyca R, Pardak P, Pękala A, Filip R

SYSTEMATIC REVIEWS

- 1430 Non-*albicans* *Candida* prosthetic joint infections: A systematic review of treatment
Koutserimpas C, Zervakis SG, Maraki S, Alpantaki K, Ioannidis A, Kofteridis DP, Samonis G

META-ANALYSIS

- 1444 Relationship between circulating irisin levels and overweight/obesity: A meta-analysis
Jia J, Yu F, Wei WP, Yang P, Zhang R, Sheng Y, Shi YQ

CASE REPORT

- 1456 Cirrhosis complicating Shwachman-Diamond syndrome: A case report
Camacho SM, McLoughlin L, Nowicki MJ

- 1461** Robot-assisted trans-gastric drainage and debridement of walled-off pancreatic necrosis using the EndoWrist stapler for the da Vinci Xi: A case report
Morelli L, Furbetta N, Gianardi D, Palmeri M, Di Franco G, Bianchini M, Stefanini G, Guadagni S, Di Candio G
- 1467** Fulminant liver failure following a marathon: Five case reports and review of literature
Figiel W, Morawski M, Grąt M, Kornasiewicz O, Niewiński G, Raszeja-Wyszomirska J, Krasnodębski M, Kowalczyk A, Holówko W, Patkowski W, Zieniewicz K
- 1475** Gaucher disease in Montenegro - genotype/phenotype correlations: Five cases report
Vujosevic S, Medenica S, Vujicic V, Dapcevic M, Bakic N, Yang R, Liu J, Mistry PK
- 1483** Longitudinal observation of ten family members with idiopathic basal ganglia calcification: A case report
Kobayashi S, Utsumi K, Tateno M, Iwamoto T, Murayama T, Sohma H, Ukai W, Hashimoto E, Kawanishi C
- 1492** Secondary lymphoma develops in the setting of heart failure when treating breast cancer: A case report
Han S, An T, Liu WP, Song YQ, Zhu J
- 1499** Removal of pediatric stage IV neuroblastoma by robot-assisted laparoscopy: A case report and literature review
Chen DX, Hou YH, Jiang YN, Shao LW, Wang SJ, Wang XQ
- 1508** Premonitory urges located in the tongue for tic disorder: Two case reports and review of literature
Li Y, Zhang JS, Wen F, Lu XY, Yan CM, Wang F, Cui YH
- 1515** Female genital tract metastasis of lung adenocarcinoma with EGFR mutations: Report of two cases
Yan RL, Wang J, Zhou JY, Chen Z, Zhou JY
- 1522** Novel heterozygous missense mutation of *SLC12A3* gene in Gitelman syndrome: A case report
Wang CL
- 1529** Thoracotomy of an asymptomatic, functional, posterior mediastinal paraganglioma: A case report
Yin YY, Yang B, Ahmed YA, Xin H

ABOUT COVER

Editorial Board Member of *World Journal of Clinical Cases*, Amirhossein Sahebkar, PharmD, PhD, Associate Professor, Biotechnology Research Center, Mashhad University of Medical Sciences, Mashhad 9177948564, Khorasan-Razavi, Iran

AIMS AND SCOPE

World Journal of Clinical Cases (*World J Clin Cases*, *WJCC*, online ISSN 2307-8960, DOI: 10.12998) is a peer-reviewed open access academic journal that aims to guide clinical practice and improve diagnostic and therapeutic skills of clinicians.

The primary task of *WJCC* is to rapidly publish high-quality Case Report, Clinical Management, Editorial, Field of Vision, Frontier, Medical Ethics, Original Articles, Meta-Analysis, Minireviews, and Review, in the fields of allergy, anesthesiology, cardiac medicine, clinical genetics, clinical neurology, critical care, dentistry, dermatology, emergency medicine, endocrinology, family medicine, gastroenterology and hepatology, *etc.*

INDEXING/ABSTRACTING

The *WJCC* is now indexed in PubMed, PubMed Central, Science Citation Index Expanded (also known as SciSearch®), and Journal Citation Reports/Science Edition. The 2018 Edition of Journal Citation Reports cites the 2017 impact factor for *WJCC* as 1.931 (5-year impact factor: N/A), ranking *WJCC* as 60 among 154 journals in Medicine, General and Internal (quartile in category Q2).

RESPONSIBLE EDITORS FOR THIS ISSUE

Responsible Electronic Editor: *Jie Wang*

Proofing Production Department Director: *Yun-Xiaojuan Wu*

NAME OF JOURNAL

World Journal of Clinical Cases

ISSN

ISSN 2307-8960 (online)

LAUNCH DATE

April 16, 2013

FREQUENCY

Semimonthly

EDITORS-IN-CHIEF

Dennis A Bloomfield, Sandro Vento

EDITORIAL BOARD MEMBERS

<https://www.wjgnet.com/2307-8960/editorialboard.htm>

EDITORIAL OFFICE

Jin-Lei Wang, Director

PUBLICATION DATE

June 26, 2019

COPYRIGHT

© 2019 Baishideng Publishing Group Inc

INSTRUCTIONS TO AUTHORS

<https://www.wjgnet.com/bpg/gerinfo/204>

GUIDELINES FOR ETHICS DOCUMENTS

<https://www.wjgnet.com/bpg/GerInfo/287>

GUIDELINES FOR NON-NATIVE SPEAKERS OF ENGLISH

<https://www.wjgnet.com/bpg/gerinfo/240>

PUBLICATION MISCONDUCT

<https://www.wjgnet.com/bpg/gerinfo/208>

ARTICLE PROCESSING CHARGE

<https://www.wjgnet.com/bpg/gerinfo/242>

STEPS FOR SUBMITTING MANUSCRIPTS

<https://www.wjgnet.com/bpg/GerInfo/239>

ONLINE SUBMISSION

<https://www.f6publishing.com>

Retrospective Study

Feasibility of prostatectomy without prostate biopsy in the era of new imaging technology and minimally invasive techniques

Nian-Zeng Xing, Ming-Shuai Wang, Qiang Fu, Fei-Ya Yang, Chang-Ling Li, Ya-Jian Li, Su-Jun Han, Ze-Jun Xiao, Hao Ping

ORCID number: Nian-Zeng Xing (0000-0003-4370-3008); Ming-Shuai Wang (0000-0003-3667-2856); Qiang Fu (0000-0002-1666-0009); Fei-Ya Yang (0000-0002-7793-8772); Chang-Ling Li (0000-0001-9480-6838); Ya-Jian Li (0000-0002-7053-8717); Su-Jun Han (0000-0002-4322-0228); Ze-Jun Xiao (0000-0002-3186-7905); Hao Ping (0000-0003-2912-0965).

Author contributions: All authors helped to perform the study; Xing NZ and Wang MS are co-first authors; Xing NZ contributed to study conception and design and manuscript writing; Wang MS contributed to study design, manuscript writing, and data analysis; Yang FY, Li YJ, Han SJ, Xiao ZJ, and Li CL contributed to data collection and manuscript writing; Ping H and Fu Q contributed to manuscript writing and data analysis.

Institutional review board

statement: As the retrospective study and data analysis were performed anonymously, this study was exempt from the ethical approval.

Informed consent statement:

Patients were not required to give informed consent to the study because the analysis used anonymous clinical data that were obtained after each patient agreed to treatment by written consent.

Conflict-of-interest statement: All authors declare no conflicts of interest related to this article.

Data sharing statement: No

Nian-Zeng Xing, Fei-Ya Yang, Chang-Ling Li, Ya-Jian Li, Su-Jun Han, Ze-Jun Xiao, Department of Urology, National Cancer Center/National Clinical Research Center for Cancer/Cancer Hospital, Chinese Academy of Medical Sciences and Peking Union Medical College, Beijing 100021, China

Ming-Shuai Wang, Institute of Urology, Capital Medical University, Department of Urology, Beijing Chaoyang Hospital, Capital Medical University, Beijing 100020, China

Qiang Fu, Department of Urology, Shandong Provincial Hospital, Jinan 250021, Shandong Province, China

Hao Ping, Department of Urology, Beijing Tongren Hospital, Capital Medical University, Beijing 100005, China

Corresponding author: Nian-Zeng Xing, MD, PhD, Chairman, Professor, Surgeon, Director, Department of Urology, National Cancer Center/National Clinical Research Center for Cancer/Cancer Hospital, Chinese Academy of Medical Sciences and Peking Union Medical College, No. 17, Pan Jia Yuan Nan Li, Chaoyang District, Beijing 100021, China. xingniansheng@hotmail.com

Telephone: +86-18612023952

Abstract

BACKGROUND

Routinely, after receiving prostate specific antigen (PSA) testing and digital rectum examination, patients with suspected prostate cancer are required to undergo prostate biopsy. However, the ability of ultrasound-guided prostate biopsy to detect prostate cancer is limited. Nowadays, a variety of diagnostic methods and more sensitive diagnostic methods, such as multi-parameter prostate magnetic resonance imaging (mpMRI) and prostate-specific membrane antigen positron emission tomography/computed tomography (PSMA PET/CT) can be applied clinically. Furthermore, laparoscopic/robot-assisted prostatectomy is also a safe and effective procedure for the treatment of benign prostatic hyperplasia. So maybe it is time to reconsider the necessary to perform prostate biopsy before radical prostatectomy.

AIM

To explore the feasibility of radical prostatectomy without prostate biopsy in the era of new imaging technology and minimally invasive techniques.

METHODS

additional data are available.

Open-Access: This is an open-access article that was selected by an in-house editor and fully peer-reviewed by external reviewers. It is distributed in accordance with the Creative Commons Attribution Non Commercial (CC BY-NC 4.0) license, which permits others to distribute, remix, adapt, build upon this work non-commercially, and license their derivative works on different terms, provided the original work is properly cited and the use is non-commercial. See: <http://creativecommons.org/licenses/by-nc/4.0/>

Manuscript source: Unsolicited manuscript

Received: February 17, 2019

Peer-review started: February 18, 2019

First decision: April 18, 2019

Revised: April 25, 2019

Accepted: May 10, 2019

Article in press: May 11, 2019

Published online: June 26, 2019

P-Reviewer: Morling JR, Sis B

S-Editor: Wang JL

L-Editor: Wang TQ

E-Editor: Xing YX



From June 2014 to November 2018, 11 cases of laparoscopic radical prostatectomy without prostate biopsy were performed at the three tertiary medical centers involved in this study. All patients received prostate magnetic resonance imaging and prostate cancer was suspected, including six patients with positive ^{68}Ga -PSMA PET/CT results. Laparoscopic radical prostatectomy and pelvic lymph node dissection were performed for all patients.

RESULTS

All surgeries were accomplished successfully. The mean age was 69 ± 7.7 year, the mean body mass index was 24.7 ± 1.6 kg/m², the range of serum PSA was 4.3 to >1000 ng/mL, and the mean prostate volume was 40.9 ± 18.3 mL. The mean operative time was 96 ± 23.3 min, the mean estimated blood loss was 90 ± 90.9 mL, and the median duration of catheter placement was 14 d. The final pathology confirmed that all specimens were prostate cancer except one case of benign prostatic hyperplasia. No major complications occurred in 90 d postoperatively.

CONCLUSION

The current practice of mandating a prostatic biopsy before prostatectomy should be reconsidered in the era of new imaging technology and minimally invasive techniques. Radical prostatectomy could be carried out without the evidence of malignancy. Large-sample randomized controlled trials are definitely required to confirm the feasibility of this new concept.

Key words: Prostate cancer; Biopsy; Prostatectomy; Magnetic resonance imaging; Prostate-specific membrane antigen positron emission tomography/computed tomography

©The Author(s) 2019. Published by Baishideng Publishing Group Inc. All rights reserved.

Core tip: The ability of ultrasound-guided prostate biopsy to detect prostate cancer is limited. Maybe prostate biopsy can be exempt before surgery when multi-parameter prostate magnetic resonance imaging and prostate-specific membrane antigen positron emission tomography/computed tomography are both positive. The current practice of mandating a prostatic biopsy before prostatectomy should be reconsidered in the era of new imaging technology and minimally invasive techniques.

Citation: Xing NZ, Wang MS, Fu Q, Yang FY, Li CL, Li YJ, Han SJ, Xiao ZJ, Ping H. Feasibility of prostatectomy without prostate biopsy in the era of new imaging technology and minimally invasive techniques. *World J Clin Cases* 2019; 7(12): 1403-1409

URL: <https://www.wjgnet.com/2307-8960/full/v7/i12/1403.htm>

DOI: <https://dx.doi.org/10.12998/wjcc.v7.i12.1403>

INTRODUCTION

Prostate cancer is one of the most common malignancies worldwide. The current methods for diagnosing prostate cancer include digital rectal examination (DRE), serum prostate specific antigen (PSA), transrectal prostate ultrasound, and magnetic resonance imaging (MRI). Routinely, after receiving one or more of these tests, patients with suspected prostate cancer are required to undergo prostate biopsy. However, the sensitivity of ultrasound-guided prostate biopsy is approximately 48%^[1]. While clinically insignificant cancers are often detected, clinically significant cancers are sometimes missed after prostate biopsy^[2,3]. Transrectal ultrasound guided (TRUS)-biopsy also carries significant morbidity and can cause life-threatening sepsis^[4]. Nowadays, we have a variety of diagnostic methods and more sensitive diagnostic methods, such as multi-parameter prostate magnetic resonance imaging (mpMRI) and prostate-specific membrane antigen positron emission tomography /computed tomography (PSMA PET/CT). The reported sensitivity of mpMRI for the detection of clinically significant disease was 93% (95%CI: 88%-96%)^[1], and ^{68}Ga -PSMA PET/CT had a 100% detection rate for index lesions at radical prostatectomy^[5]. Furthermore, laparoscopic/robot-assisted prostatectomy is also a safe and effective procedure for the treatment of benign prostatic hyperplasia^[6]. To take all the above-mentioned factors together, we hypothesized that it might be no longer necessary to

perform prostate biopsy before radical prostatectomy.

In this study, we summarized 11 cases of radical prostatectomy without prostate biopsy from three tertiary hospitals to explore the feasibility of radical prostatectomy without prostate biopsy.

MATERIALS AND METHODS

Clinical data

Between June 2014 and December 2018, five, three, and three cases of laparoscopic radical prostatectomy were performed without prostate biopsy before surgery at National Cancer Center/Cancer Hospital of Chinese Academy of Medical Sciences, Beijing Chaoyang Hospital Affiliated to Capital Medical University, and Shandong Provincial Hospital, respectively. All surgeries were performed by the same surgeon who had high volume experience of laparoscopic surgeries. All patients received serum PSA test, digital rectal examination, transrectal prostatic ultrasound, and MRI of the prostate, and six of them received ^{68}Ga -PSMA PET/CT examination. Informed consent was obtained before surgery to fully communicate with patients and family members, and to explain possible surgical risks especially postoperative pathology. Data were collected, including patient demographics, perioperative outcomes, pathological results, and complications. Postoperative complications were graded using the Clavien classification method, and the complications were classified into minor (Clavien grade I-II) and major (Clavien grade III-V)^[7].

Surgical technique

All surgeries were carried out using an extraperitoneal approach and five trocar technique as we described before^[8]. After creating a working space via an extraperitoneal approach, the prostate, bladder, and endopelvic fascia were exposed. The endopelvic fascia was incised on both sides, and blunt dissection was performed towards the apex of the prostate. The puboprostatic ligaments were preserved, and the dorsal venous complex was ligated using a 2/0 v-lok suture. The bladder neck was carefully dissected and preserved followed by dissection of the seminal vesicles and incision of the Denonvillier's fascia. The prostatic pedicles were clipped close to the prostate and cut with cold scissors step by step. Apical dissection of the prostate and division of the urethra were then performed. The urethra was cut at the middle between the external urethral sphincter and the apex of the prostate with cold scissors. Bilateral pelvic lymph node dissection was performed in all patients. All specimens were removed in a retrieval endobag.

The "sandwich" reconstruction technique was utilized during the urethrovesical anastomosis^[8]. First, the posterior reconstruction was accomplished by two-layer suturing including the Denonvillier's fascia with the median dorsal raphe (MDR) and the posterior wall of the bladder with the MDR. The second step of the reconstruction was the urethrovesical anastomosis. The third step was anterior reconstruction consisting of reattachment of the puboprostatic ligaments with the detrusor apron of the bladder.

RESULTS

All surgeries were successfully accomplished without open conversion. The patient characteristics and pathologic outcomes are shown in [Table 1](#).

The mean age was 69 ± 7.7 year and the mean BMI was 24.7 ± 1.6 kg/m². The range of serum PSA was 4.3 to >1000 ng/mL and the mean prostate volume was 40.9 ± 18.3 mL. The mean operative time was 96 ± 23.3 min, the mean estimated blood loss was 90 ± 90.9 mL, and no patient required transfusion. The median time of catheter retention was 14 d. No major complications occurred in 90 d postoperatively.

The pathological results showed ten cases of prostatic adenocarcinoma and one case of benign prostatic hyperplasia. The pathologic tumor stage revealed pT2aN0 (1 case), pT2bN0 (1 case), pT2cN0 (3 cases), pT2cN1 (1 case), pT3aN0 (3 cases), and pT3bN0 (1 case) ([Figure 1](#)). One patient developed pelvic lymph node metastasis (16/22) and no lymph node metastasis was found in other patients. There were two cases with a Gleason score of $(3 + 3 = 6)$ points, two with a score of $(3 + 4 = 7)$ points, one with a score of $(4 + 3 = 7)$ points, one with a score of $(4 + 4 = 8)$ points, and four with a score ≥ 9 points. Two cases had positive margins at the prostatic base.

Table 1 Patient characteristics and pathologic outcomes

Case	Age (yr)	BMI (kg/m ²)	Maximum PSA (ng/mL)	Prostate volume	MRI	PET/CT	Bone scan	Pathology tumor stage	Gleason score	Positive lymph nodes
1	61	25.4	8.6	40	+	/	/	T3aN0	3 + 4 = 7	0
2	71	25.3	>1000	23	+	/	+	T3bN0	4 + 5 = 9	0
3	62	24.5	>1000	30	+	/	+	T2cN1	5 + 4 = 9	16/22
4	76	25.3	18.3	80	+	/	/	T2cN0	4 + 3 = 7	0
5	79	22.4	41.2	20	+	+	/	T2cN0	5 + 5 = 10	0
6	80	23.3	15.2	46	+	/	/	Benign prostatic hyperplasia		0
7	73	23.4	27.7	31	+	+	/	T3aN0	4 + 4 = 8	0
8	56	23.2	9.2	41	+	+	/	T2aN0	3 + 3 = 6	0
9	69	26.6	22	47	+	+	/	T3aN0	4 + 5 = 9	0
10	67	24.5	4.3	27	+	+	/	T2bN0	3 + 4 = 7	0
11	65	27.6	15.9	65	+	+	/	T2cN0	3 + 3 = 6	0

+: Positive. /: not receiving the test; BMI: Body mass index; PSA: Prostatic specific antigen; MRI: Magnetic resonance imaging; PET/CT: Positron emission tomography and computed tomography.

DISCUSSION

Prostate biopsy to exclude cancer has been part of clinical practice since the beginning of the 20th century. The introduction of PSA and ultrasound into clinical practice in the 1980s and the evolution of mpMRI in the early 21st century have driven the prostate biopsy into a more scientific-based procedure. Current practice mandates a prostate biopsy before radical prostatectomy, despite many complications such as urosepsis, urinary retention, and hematuria *etc*^[9]. On the other hand, renal tumors are treated completely differently. When a renal tumor was highly suspected to be malignant by CT or MRI imaging, radical nephrectomy or partial nephrectomy is routinely carried out clinically. Renal tumor biopsy is not mandated before surgery currently^[10].

Compared to radical nephrectomy and partial nephrectomy, the procedure of radical prostatectomy is more difficult and postoperative complications seriously affect the quality of life, such as urinary incontinence and erectile dysfunction. However, with accumulation of surgical experience, improvement of surgical techniques, and advancement of surgical equipment, minimally invasive radical prostatectomy has shorter operative time, less trauma, and faster recovery, and the early continence and erectile function recover faster than before^[11-13]. Our previous data also showed that patients' early urinary continence rate and quality of life were significantly improved after laparoscopic radical prostatectomy with the "sandwich" urethrovesical anastomosis technique^[8].

The use of mpMRI and the PI-RADS prostate cancer scoring system has significantly improved the diagnostic accuracy of clinically significant prostate cancer^[14,15]. And there is evidence that mpMRI tends to detect higher risk disease and systematically overlooks low-risk disease^[1,14]. Ahmed *et al*^[1] found that the sensitivity of mpMRI for the detection of clinically significant disease was 93% (95%CI: 88%-96%), which was significantly superior to the sensitivity of TRUS biopsy (48%; 95%CI: 42%-55%). One meta-analysis showed that the pooled sensitivity and specificity of mpMRI for prostate cancer detection are 74% and 88%, respectively^[16]. Assessment of lymph node involvement can be performed by both CT and mpMRI, but both have a very low sensitivity^[17].

The use of PSMA PET/CT further enhances the accuracy of diagnosing prostate cancer, not only to assess primary lesions but also to assess metastases. Berger *et al*^[5] compared the accuracy of ⁶⁸Ga-PSMA PET/CT and mpMRI in assessing prostate cancer and found that ⁶⁸Ga-PSMA PET/CT had a 100% detection rate for index lesions at radical prostatectomy. Six patients in our study underwent ⁶⁸Ga-PSMA PET/CT and the detection rate was 100%, which was confirmed by final pathology. Besides primary lesion, PSMA PET/CT also had a high specificity and moderate sensitivity for lymph node metastasis detection for patient with intermediate- to high-risk prostate cancer^[18]. It is more accurate than morphologic imaging for detection of lymph node metastasis^[19]. Until now, no prospective study accesses the oncologic efficacy of PSMA PET/CT guided lymph node dissection compared to conventional

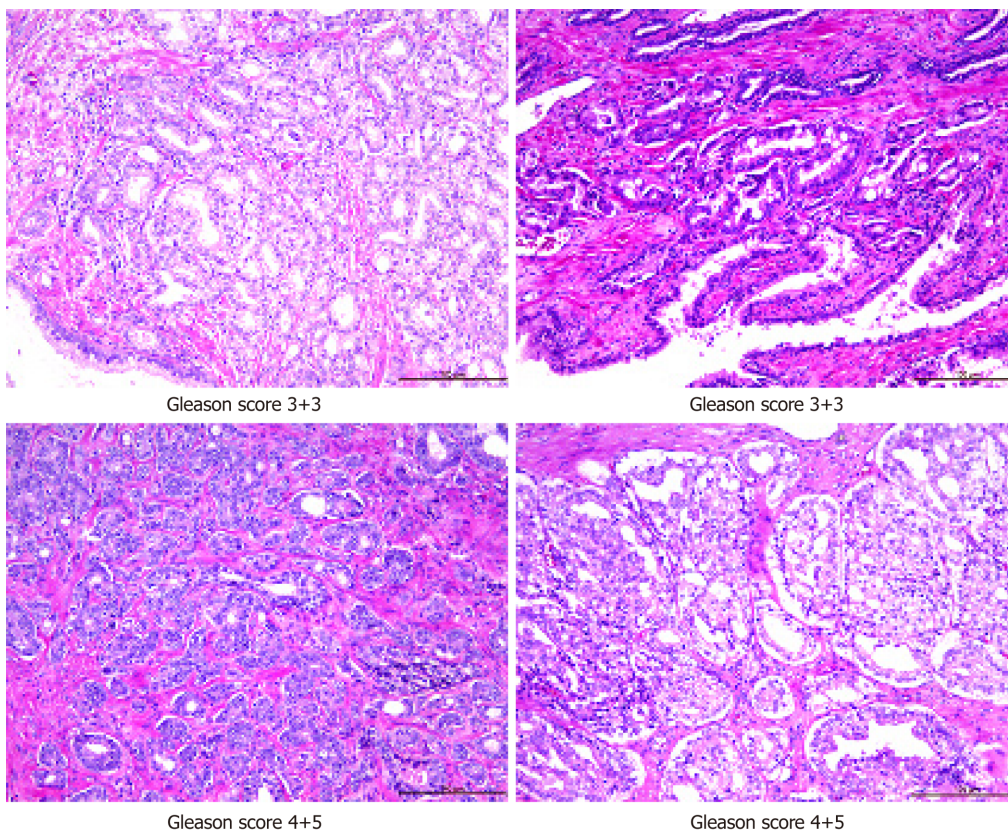


Figure 1 Pathological images of prostate cancer.

strategy.

One lesion by lesion analysis showed that combination of ^{68}Ga -PSMA PET/CT and multiparameter MRI can improve the detection of clinically significant prostate cancer^[20]. We recommend every patient being suspected of having prostate cancer to receive mpMRI and PSMA PET/CT which could help surgeons to detect clinically significant prostate cancer, and prostate biopsy can be exempt before surgery when both imaging tests are positive.

The critical concern for radical prostatectomy without biopsy is overtreatment if the pathology turns to be benign. However, the prostate is not a vital organ for the elder man. Rather it may lead to risks such as benign prostate hyperplasia and prostate cancer which influence the quality of life. Surgery is an optional treatment modality for both benign prostate hyperplasia and prostate cancer. While benign prostate hyperplasia is mostly operated by the transurethra procedure, laparoscopic and robot-assisted laparoscopic surgeries are also indicated in some patients. One meta-analysis study showed that open, laparoscopic, and robot-assisted laparoscopic surgeries can safely complete simple prostatectomy^[21]. One study comparing transurethral holmium laser enucleation of the prostate with robot-assisted simple prostatectomy showed that both procedures can effectively treat benign prostatic hyperplasia^[22]. Although the transurethral laser ablation procedure had shorter operation time, less blood loss, and shorter hospital stay, there was no significant difference in the major complications or postoperative urinary continence. One of our cases was benign prostate hyperplasia. The patient was very satisfied with the treatment since he recovered very well without major complications, while his lower urinary tracts symptoms disappeared. Therefore, it is acceptable even the final pathology is benign for some patients who received radical prostatectomy.

In summary, the current practice of mandating a prostatic biopsy before prostatectomy should be reconsidered in the era of new imaging technology and minimally invasive techniques. Radical prostatectomy could be carried out without the evidence of malignancy. Large-sample randomized controlled trials are definitely required to confirm the feasibility of this new concept.

ARTICLE HIGHLIGHTS

Research background

Prostate cancer is one of the most common malignant tumors. When the total PSA and/or digital rectum examination are positive, prostate biopsy is routinely proposed to patients. However, the detection ability of the transrectal ultrasound guided (TRUS) prostate biopsy is limited. While clinically insignificant cancers are often detected, clinically significant cancers are sometimes missed after prostate biopsy. TRUS-biopsy also carries significant morbidity and can cause life-threatening sepsis. The reported sensitivity of multi-parameter prostate magnetic resonance imaging for the detection of clinically significant disease was 93% (95%CI 88-96), and ⁶⁸Gallium-prostate-specific membrane antigen positron emission tomography/computed tomography had a 100% detection rate for index lesions at radical prostatectomy.

Research motivation

Nowadays, many imaging techniques with a very high detection rate for prostate cancer are applied clinically. Some patients are afraid of prostate biopsy, and they really want to remove the prostate immediately when they were told that they might have prostate cancer. For elder men, laparoscopic/robot-assisted prostatectomy is also a safe and effective procedure for the treatment of benign prostatic hyperplasia. So it might be no longer necessary to perform prostate biopsy before radical prostatectomy.

Research objectives

The main objective of the study was to explore the feasibility of radical prostatectomy without prostate biopsy in the era of new imaging technology and minimally invasive techniques.

Research methods

A retrospective study was designed. The cases of laparoscopic radical prostatectomy without prostate biopsy before surgery were collected at the three medical centers involved in this study between June 2014 and December 2018. The perioperative outcomes and pathology results were analyzed.

Research results

All surgeries were successfully accomplished without open conversion. The pathological results showed ten cases of prostatic adenocarcinoma and one case of benign prostatic hyperplasia. Lower urinary tract symptoms disappeared when the patient with benign prostatic hyperplasia underwent laparoscopic radical prostatectomy.

Research conclusions

The current practice of mandating a prostatic biopsy before prostatectomy should be reconsidered in the era of new imaging technology and minimally invasive techniques. Radical prostatectomy could be carried out without the evidence of malignancy.

Research perspectives

It might be no longer necessary to perform prostate biopsy before radical prostatectomy. However, large-sample randomized controlled trials are definitely required to confirm the feasibility of this new concept.

REFERENCES

- 1 Ahmed HU, El-Shater Bosaily A, Brown LC, Gabe R, Kaplan R, Parmar MK, Collaco-Moraes Y, Ward K, Hindley RG, Freeman A, Kirkham AP, Oldroyd R, Parker C, Emberton M; PROMIS study group. Diagnostic accuracy of multi-parametric MRI and TRUS biopsy in prostate cancer (PROMIS): a paired validating confirmatory study. *Lancet* 2017; **389**: 815-822 [PMID: 28110982 DOI: 10.1016/S0140-6736(16)32401-1]
- 2 Caverly TJ, Hayward RA, Reamer E, Zikmund-Fisher BJ, Connochie D, Heisler M, Fagerlin A. Presentation of Benefits and Harms in US Cancer Screening and Prevention Guidelines: Systematic Review. *J Natl Cancer Inst* 2016; **108**: djv436 [PMID: 26917630 DOI: 10.1093/jnci/djv436]
- 3 Abraham NE, Mendhiratta N, Taneja SS. Patterns of repeat prostate biopsy in contemporary clinical practice. *J Urol* 2015; **193**: 1178-1184 [PMID: 25444971 DOI: 10.1016/j.juro.2014.10.084]
- 4 Loeb S, Vellekoop A, Ahmed HU, Catto J, Emberton M, Nam R, Rosario DJ, Scattoni V, Lotan Y. Systematic review of complications of prostate biopsy. *Eur Urol* 2013; **64**: 876-892 [PMID: 23787356 DOI: 10.1016/j.eururo.2013.05.049]
- 5 Berger I, Annabattula C, Lewis J, Shetty DV, Kam J, Maclean F, Arianayagam M, Canagasingham B, Ferguson R, Khadra M, Ko R, Winter M, Loh H, Varol C. 68Ga-PSMA PET/CT vs. mpMRI for locoregional prostate cancer staging: correlation with final histopathology. *Prostate Cancer Prostatic Dis* 2018; **21**: 204-211 [PMID: 29858591 DOI: 10.1038/s41391-018-0048-7]
- 6 Nestler S, Bach T, Herrmann T, Jutzi S, Roos FC, Hampel C, Thüroff JW, Thomas C, Neisius A. Surgical treatment of large volume prostates: a matched pair analysis comparing the open, endoscopic (ThuVEP) and robotic approach. *World J Urol* 2018 [PMID: 30515596 DOI: 10.1007/s00345-018-2585-z]
- 7 Dindo D, Demartines N, Clavien PA. Classification of surgical complications: a new proposal with evaluation in a cohort of 6336 patients and results of a survey. *Ann Surg* 2004; **240**: 205-213 [PMID: 15273542]
- 8 Liao X, Qiao P, Tan Z, Shi H, Xing N. "Total reconstruction" of the urethrovesical anastomosis contributes to early urinary continence in laparoscopic radical prostatectomy. *Int Braz J Urol* 2016; **42**: 215-222 [PMID: 27256174 DOI: 10.1590/S1677-5538.IBJU.2014.0666]
- 9 Halpern JA, Sedrakyan A, Dinerman B, Hsu WC, Mao J, Hu JC. Indications, Utilization and Complications Following Prostate Biopsy: New York State Analysis. *J Urol* 2017; **197**: 1020-1025

- [PMID: 27856226 DOI: 10.1016/j.juro.2016.11.081]
- 10 **Ljungberg B**, Bensalah K, Canfield S, Dabestani S, Hofmann F, Hora M, Kuczyk MA, Lam T, Marconi L, Merseburger AS, Mulders P, Powles T, Staehler M, Volpe A, Bex A. EAU guidelines on renal cell carcinoma: 2014 update. *Eur Urol* 2015; **67**: 913-924 [PMID: 25616710 DOI: 10.1016/j.eururo.2015.01.005]
 - 11 **Sooriakumaran P**, Pini G, Nyberg T, Derogar M, Carlsson S, Stranne J, Bjartell A, Hugosson J, Steineck G, Wiklund PN. Erectile Function and Oncologic Outcomes Following Open Retropubic and Robot-assisted Radical Prostatectomy: Results from the LAParoscopic Prostatectomy Robot Open Trial. *Eur Urol* 2018; **73**: 618-627 [PMID: 28882327 DOI: 10.1016/j.eururo.2017.08.015]
 - 12 **Coughlin GD**, Yaxley JW, Chambers SK, Occhipinti S, Samaratunga H, Zajdlewicz L, Teloken P, Dungleison N, Williams S, Lavin MF, Gardiner RA. Robot-assisted laparoscopic prostatectomy versus open radical retropubic prostatectomy: 24-month outcomes from a randomised controlled study. *Lancet Oncol* 2018; **19**: 1051-1060 [PMID: 30017351 DOI: 10.1016/S1470-2045(18)30357-7]
 - 13 **Yaxley JW**, Coughlin GD, Chambers SK, Occhipinti S, Samaratunga H, Zajdlewicz L, Dungleison N, Carter R, Williams S, Payton DJ, Perry-Keene J, Lavin MF, Gardiner RA. Robot-assisted laparoscopic prostatectomy versus open radical retropubic prostatectomy: early outcomes from a randomised controlled phase 3 study. *Lancet* 2016; **388**: 1057-1066 [PMID: 27474375 DOI: 10.1016/S0140-6736(16)30592-X]
 - 14 **Turkbey B**, Brown AM, Sankineni S, Wood BJ, Pinto PA, Choyke PL. Multiparametric prostate magnetic resonance imaging in the evaluation of prostate cancer. *CA Cancer J Clin* 2016; **66**: 326-336 [PMID: 26594835 DOI: 10.3322/caac.21333]
 - 15 **Weinreb JC**, Barentsz JO, Choyke PL, Cornud F, Haider MA, Macura KJ, Margolis D, Schnall MD, Shtern F, Tempny CM, Thoeny HC, Verma S. PI-RADS Prostate Imaging - Reporting and Data System: 2015, Version 2. *Eur Urol* 2016; **69**: 16-40 [PMID: 26427566 DOI: 10.1016/j.eururo.2015.08.052]
 - 16 **Godley KC**, Syer TJ, Toms AP, Smith TO, Johnson G, Cameron D, Malcolm PN. Accuracy of high b-value diffusion-weighted MRI for prostate cancer detection: a meta-analysis. *Acta Radiol* 2018; **59**: 105-113 [PMID: 28376634 DOI: 10.1177/0284185117702181]
 - 17 **Li L**, Wang L, Feng Z, Hu Z, Wang G, Yuan X, Wang H, Hu D. Prostate cancer magnetic resonance imaging (MRI): multidisciplinary standpoint. *Quant Imaging Med Surg* 2013; **3**: 100-112 [PMID: 23630657 DOI: 10.3978/j.issn.2223-4292.2013.03.03]
 - 18 **van Leeuwen PJ**, Emmett L, Ho B, Delprado W, Ting F, Nguyen Q, Stricker PD. Prospective evaluation of 68Gallium-prostate-specific membrane antigen positron emission tomography/computed tomography for preoperative lymph node staging in prostate cancer. *BJU Int* 2017; **119**: 209-215 [PMID: 27207581 DOI: 10.1111/bju.13540]
 - 19 **Rauscher I**, Maurer T, Beer AJ, Graner FP, Haller B, Weirich G, Doherty A, Gschwend JE, Schwaiger M, Eiber M. Value of 68Ga-PSMA HBED-CC PET for the Assessment of Lymph Node Metastases in Prostate Cancer Patients with Biochemical Recurrence: Comparison with Histopathology After Salvage Lymphadenectomy. *J Nucl Med* 2016; **57**: 1713-1719 [PMID: 27261524 DOI: 10.2967/jnumed.116.173492]
 - 20 **Chen M**, Zhang Q, Zhang C, Zhao X, Marra G, Gao J, Lv X, Zhang B, Fu Y, Wang F, Qiu X, Guo H. Combination of 68Ga-PSMA PET/CT and multiparameter MRI improves the detection of clinically significant prostate cancer: a lesion by lesion analysis. *J Nucl Med* 2018 [PMID: 30552201 DOI: 10.2967/jnumed.118.221010]
 - 21 **Ferretti M**, Phillips J. Prostatectomy for benign prostate disease: open, laparoscopic and robotic techniques. *Can J Urol* 2015; **22** Suppl 1: 60-66 [PMID: 26497345]
 - 22 **Zhang MW**, El Tayeb MM, Borofsky MS, Dauw CA, Wagner KR, Lowry PS, Bird ET, Hudson TC, Lingeman JE. Comparison of Perioperative Outcomes Between Holmium Laser Enucleation of the Prostate and Robot-Assisted Simple Prostatectomy. *J Endourol* 2017; **31**: 847-850 [PMID: 28637364 DOI: 10.1089/end.2017.0095]



Published By Baishideng Publishing Group Inc
7041 Koll Center Parkway, Suite 160, Pleasanton, CA 94566, USA
Telephone: +1-925-2238242
Fax: +1-925-2238243
E-mail: bpgoffice@wjgnet.com
Help Desk: <https://www.f6publishing.com/helpdesk>
<https://www.wjgnet.com>

