

World Journal of *Clinical Cases*

World J Clin Cases 2019 June 6; 7(11): 1242-1366



**MINIREVIEWS**

- 1242** Radiation therapy for extrahepatic bile duct cancer: Current evidences and future perspectives
Koo T, Park HJ, Kim K
- 1253** Antibiotics and immunotherapy in gastrointestinal tumors: Friend or foe?
Yan C, Tu XX, Wu W, Tong Z, Liu LL, Zheng Y, Jiang WQ, Zhao P, Fang WJ, Zhang HY

ORIGINAL ARTICLE**Basic Study**

- 1262** Elevated levels of interleukin-1 β , interleukin-6, tumor necrosis factor- α and vascular endothelial growth factor in patients with knee articular cartilage injury
Wang ZW, Chen L, Hao XR, Qu ZA, Huang SB, Ma XJ, Wang JC, Wang WM

Retrospective Cohort Study

- 1270** Anti-hepatitis C virus therapy in chronic kidney disease patients improves long-term renal and patient survivals
Chen YC, Li CY, Tsai SJ, Chen YC

Observational Study

- 1282** Clinical features of syphilitic myelitis with longitudinally extensive myelopathy on spinal magnetic resonance imaging
Yuan JL, Wang WX, Hu WL

Prospective Study

- 1291** Application of pulse index continuous cardiac output system in elderly patients with acute myocardial infarction complicated by cardiogenic shock: A prospective randomized study
Zhang YB, Zhang ZZ, Li JX, Wang YH, Zhang WL, Tian XL, Han YF, Yang M, Liu Y

META-ANALYSIS

- 1302** Efficacy and safety of tranexamic acid in elderly patients with intertrochanteric fracture: An updated meta-analysis
Zhou XD, Li J, Fan GM, Huang Y, Xu NW

CASE REPORT

- 1315** Lupus enteritis as the only active manifestation of systemic lupus erythematosus: A case report
Gonzalez A, Wadhwa V, Salomon F, Kaur J, Castro FJ

- 1323** Development of a biliary multi-hole self-expandable metallic stent for bile tract diseases: A case report
Kobayashi M
- 1330** Paraneoplastic leukemoid reaction in a patient with sarcomatoid hepatocellular carcinoma: A case report
Hu B, Sang XT, Yang XB
- 1337** Multiple synchronous anorectal melanomas with different colors: A case report
Cai YT, Cao LC, Zhu CF, Zhao F, Tian BX, Guo SY
- 1344** Huge primary dedifferentiated pancreatic liposarcoma mimicking carcinosarcoma in a young female: A case report
Liu Z, Fan WF, Li GC, Long J, Xu YH, Ma G
- 1351** A large basal cell adenoma extending to the ipsilateral skull base and mastoid in the right parotid gland: A case report
Du LY, Weng XH, Shen ZY, Cheng B
- 1358** Novel *ATL1* mutation in a Chinese family with hereditary spastic paraplegia: A case report and review of literature
Xiao XW, Du J, Jiao B, Liao XX, Zhou L, Liu XX, Yuan ZH, Guo LN, Wang X, Shen L, Lin ZY

ABOUT COVER

Editorial Board Member of *World Journal of Clinical Cases*, Kassem A Barada, MD, Professor, Department of Internal Medicine, American University of Beirut Medical Center, Beirut 110 72020, Lebanon

AIMS AND SCOPE

World Journal of Clinical Cases (*World J Clin Cases*, *WJCC*, online ISSN 2307-8960, DOI: 10.12998) is a peer-reviewed open access academic journal that aims to guide clinical practice and improve diagnostic and therapeutic skills of clinicians.

The primary task of *WJCC* is to rapidly publish high-quality Case Report, Clinical Management, Editorial, Field of Vision, Frontier, Medical Ethics, Original Articles, Meta-Analysis, Minireviews, and Review, in the fields of allergy, anesthesiology, cardiac medicine, clinical genetics, clinical neurology, critical care, dentistry, dermatology, emergency medicine, endocrinology, family medicine, gastroenterology and hepatology, etc.

INDEXING/ABSTRACTING

The *WJCC* is now indexed in PubMed, PubMed Central, Science Citation Index Expanded (also known as SciSearch®), and Journal Citation Reports/Science Edition. The 2018 Edition of Journal Citation Reports cites the 2017 impact factor for *WJCC* as 1.931 (5-year impact factor: N/A), ranking *WJCC* as 60 among 154 journals in Medicine, General and Internal (quartile in category Q2).

**RESPONSIBLE EDITORS
FOR THIS ISSUE**

Responsible Electronic Editor: Yan-Xia Xing Proofing Editorial Office Director: Jin-Lei Wang

NAME OF JOURNAL

World Journal of Clinical Cases

ISSN

ISSN 2307-8960 (online)

LAUNCH DATE

April 16, 2013

FREQUENCY

Semimonthly

EDITORS-IN-CHIEF

Dennis A Bloomfield, Sandro Vento

EDITORIAL BOARD MEMBERS

<https://www.wjgnet.com/2307-8960/editorialboard.htm>

EDITORIAL OFFICE

Jin-Lei Wang, Director

PUBLICATION DATE

June 6, 2019

COPYRIGHT

© 2019 Baishideng Publishing Group Inc

INSTRUCTIONS TO AUTHORS

<https://www.wjgnet.com/bpg/gerinfo/204>

GUIDELINES FOR ETHICS DOCUMENTS

<https://www.wjgnet.com/bpg/GerInfo/287>

GUIDELINES FOR NON-NATIVE SPEAKERS OF ENGLISH

<https://www.wjgnet.com/bpg/gerinfo/240>

PUBLICATION MISCONDUCT

<https://www.wjgnet.com/bpg/gerinfo/208>

ARTICLE PROCESSING CHARGE

<https://www.wjgnet.com/bpg/gerinfo/242>

STEPS FOR SUBMITTING MANUSCRIPTS

<https://www.wjgnet.com/bpg/GerInfo/239>

ONLINE SUBMISSION

<https://www.f6publishing.com>

Basic Study

Elevated levels of interleukin-1 β , interleukin-6, tumor necrosis factor- α and vascular endothelial growth factor in patients with knee articular cartilage injury

Zhen-Wei Wang, Le Chen, Xiao-Rui Hao, Zhen-An Qu, Shi-Bo Huang, Xiao-Jun Ma, Jian-Chuan Wang, Wei-Ming Wang

ORCID number: Zhen-Wei Wang (0000-0001-5766-130X); Le Chen (0000-0002-8505-5603); Xiao-Rui Hao (0000-0002-9532-597X); Zhen-An Qu (0000-0003-2210-6044); Shi-Bo Huang (0000-0001-6812-8914); Xiao-Jun Ma (0000-0001-9349-6655); Jian-Chuan Wang (0000-0002-3091-1572); Wei-Ming Wang (0000-0002-4535-8191).

Author contributions: Wang ZW performed the majority of experiments and analyzed the data; Chen L, Hao XR, Ou ZA, Huang SB, Ma XJ and Wang JC performed the experiments; Wang WM designed the research and wrote the paper.

Institutional review board

statement: This study has been approved by the ethnic committee of Affiliated Zhongshan Hospital of Dalian University.

Conflict-of-interest statement: All authors have no conflict-of-interest to state.

Open-Access: This article is an open-access article that was selected by an in-house editor and fully peer-reviewed by external reviewers. It is distributed in accordance with the Creative Commons Attribution Non Commercial (CC BY-NC 4.0) license, which permits others to distribute, remix, adapt, build upon this work non-commercially, and license their derivative works on different terms, provided the original work is properly cited and

Zhen-Wei Wang, Le Chen, Xiao-Rui Hao, Zhen-An Qu, Shi-Bo Huang, Xiao-Jun Ma, Jian-Chuan Wang, Wei-Ming Wang, Department of Sports Medicine, Affiliated Zhongshan Hospital of Dalian University, Dalian 16000, Liaoning Province, China

Corresponding author: Wei-Ming Wang, BSc, MD, PhD, Professor, Department of Sports Medicine, Affiliated Zhongshan Hospital of Dalian University, 6 Jiefang Jie, Zhongshan District, Dalian 116001, Liaoning Province, China. wangwm_01@126.com

Telephone: +86-411-62893145

Fax: +86-411-62893145

Abstract

BACKGROUND

Inflammatory cytokines play a vital role in the occurrence of osteoarticular injury and inflammation. Whether inflammation-associated factors interleukin-1 β (IL-1 β), IL-6, tumor necrosis factor- α (TNF- α) and vascular endothelial growth factor (VEGF) are involved in the pathogenesis of knee articular cartilage injury remains poorly understood.

AIM

To measure the levels of inflammatory factors [IL-1 β , IL-6, TNF- α and VEGF] in patients with knee articular cartilage injury.

METHODS

Fifty-five patients with knee articular cartilage injury were selected as patient groups, who were divided into three grades [mild ($n = 20$), moderate ($n = 19$) and severe ($n = 16$)] according to disease severity and X-ray examinations. Meanwhile, 30 healthy individuals who underwent physical examination were selected as the control group. The levels of IL-1 β , IL-6, TNF- α and VEGF were measured by ELISA and immunohistochemical staining.

RESULTS

Compared with the control group, patient groups displayed significantly higher levels of IL-1 β , IL-6, TNF- α and VEGF, and the extent of increase was directly proportional to the severity of injury ($P < 0.05$). In addition, the number of cells with positive staining of IL-1 β , IL-6, TNF- α and VEGF in the synovial membrane were significantly increased, along with increased disease severity ($P < 0.05$). After treatment, the scores of visual analogue scale and the Western Ontario and

the use is non-commercial. See: <http://creativecommons.org/licenses/by-nc/4.0/>

Manuscript source: Unsolicited manuscript

Received: February 22, 2019

Peer-review started: February 24, 2019

First decision: March 10, 2019

Revised: March 20, 2019

Accepted: April 8, 2019

Article in press: April 9, 2019

Published online: June 6, 2019

P-Reviewer: Exbrayat JM, Wang Y

S-Editor: Ji FF

L-Editor: Filipodia

E-Editor: Xing YX



McMaster University of Orthopaedic Index in patient groups were 2.26 ± 1.13 and 15.56 ± 7.12 points, respectively, which were significantly lower than those before treatment (6.98 ± 1.32 and 49.48 ± 8.96). Correlation analysis suggested that IL-1 β and TNF- α were positively correlated with VEGF.

CONCLUSION

IL-1 β , IL-6, TNF- α and VEGF levels are increased in patients with knee articular cartilage injury, and are associated with the disease severity, indicating they might play an important role in the occurrence and development of knee articular cartilage injury. Furthermore, therapeutically targeting them might be a novel approach for the treatment of knee articular cartilage injury.

Key words: Knee articular cartilage injury; Interleukin-1 β ; Interleukin-6; Tumor necrosis factor- α ; Vascular endothelial growth factor

©The Author(s) 2019. Published by Baishideng Publishing Group Inc. All rights reserved.

Core tip: Increased levels of interleukin-1 β (IL-1 β), IL-6, tumor necrosis factor- α and vascular endothelial growth factor are found in patients with knee articular cartilage injury, and are associated with the disease severity, suggesting that they might be involved in the pathogenesis of knee articular cartilage injury. Furthermore, therapeutically targeting them might be beneficial for the treatment of knee articular cartilage injury.

Citation: Wang ZW, Chen L, Hao XR, Qu ZA, Huang SB, Ma XJ, Wang JC, Wang WM. Elevated levels of interleukin-1 β , interleukin-6, tumor necrosis factor- α and vascular endothelial growth factor in patients with knee articular cartilage injury. *World J Clin Cases* 2019; 7(11): 1262-1269

URL: <https://www.wjgnet.com/2307-8960/full/v7/i11/1262.htm>

DOI: <https://dx.doi.org/10.12998/wjcc.v7.i11.1262>

INTRODUCTION

Knee articular cartilage injury is a type of joint disease with a high incidence, and is characterized by degenerative changes, such as disintegration and reduction of articular cartilage matrix. This leads to the formation of osteophytes, accompanied by aseptic inflammation of the synovial membrane^[1-3]. It has been proven that inflammatory cytokines play a vital role in the occurrence of osteoarticular injury and inflammation^[4-6]. Tumor necrosis factor- α (TNF- α) and interleukin-1 β (IL-1 β) can trigger the production of matrix metalloproteinases, causing degradation of articular cartilage matrix, and eventually leading to osteochondral injury^[7]. IL-6 is a multifunctional cytokine that induces the proliferation and differentiation of immune cells, and plays a central role in the regulation of the complicated immune network in the body. This can lead to long-lasting chronic inflammation by inducing and activating various immune cells *in vivo*^[8-10]. Vascular endothelial growth factor (VEGF) is a platelet-derived growth factor, which is mainly expressed in articular osteoblasts and synovial fibroblasts^[11]. Elevated VEGF promotes neovascularization, and is considered to be one of the strongest angiogenic factors in the body^[12]. Considering the role of inflammatory cytokines in the pathogenesis of osteoarticular injury, whether IL-1 β , IL-6, TNF- α and VEGF are involved in the pathogenesis of knee articular cartilage injury remains poorly understood. The purpose of this study is to explore the expression profiles of IL-1 β , IL-6, TNF- α and VEGF in patients with knee articular cartilage injury, with an attempt to evaluate the clinical significance of the occurrence and development of the disease.

MATERIALS AND METHODS

Patients

A total of 55 patients consisting of 26 males and 29 females with knee osteoarthritis

caused by knee articular cartilage injury who were treated in our hospital from January 2017 to July 2017 were selected. All patients were diagnosed according to the diagnostic criteria of knee osteoarthritis formulated by the American College of Rheumatology^[13]. Patients who had been treated with hormone therapy within 3 mo, or patients with severe organ diseases or surgical contraindications, were excluded. Patients with knee articular cartilage injury were further divided into three grades [mild ($n = 20$), moderate ($n = 19$) and severe ($n = 16$)] according to clinical symptoms, disease severity and X-ray examinations. Another 30 healthy individuals who underwent physical examinations during the same period were selected as the control group. No significant differences were observed in these two groups regarding age, sex and other aspects ($P > 0.05$). This study was approved by the ethics committee of our hospital, and informed consents were received from all participants prior to this study.

Measurement of IL-1 β , IL-6, TNF- α and VEGF levels by ELISA

The fasting venous blood was drawn in the morning and centrifuged at $\times 2000$ g for 20 min to obtain serum, which was used to measure the levels of IL-1 β ; IL-6; TNF- α and VEGF by ELISA according to the manufacturer's instructions.

Immunohistochemical staining

Synovial specimens were collected during the replacement surgery and were fixed, dehydrated and immersed in wax. After embedding in paraffin, synovial specimens were sliced and processed by heating antigen retrieval. After blocking the endogenous peroxidase activity with freshly made 0.3% H2O2 in methanol for 20 min, primary antibodies against IL-1 β , IL-6, TNF- α or VEGF (Cell Signaling Technology) were added and incubated for 1 h, followed by washing and addition of a biotinylated secondary antibody (Cell Signaling Technology) for a 10 min incubation. Then, DAB substrate was added for development, followed by counter-staining and differentiation, and subsequently mounted with mounting medium (Simpomount). Mounted slides were observed and recorded under a light-field microscope. The number of positive cells with IL-1 β , IL-6, TNF- α and VEGF in synovial tissues was counted.

Evaluation indexes

Changes in clinical indicators [visual analog scale (VAS) and Western Ontario and McMaster University of Orthopaedic Index (WOMAC)] before and after treatment were observed, and the overall scores before and after treatment (i.e. the fourth week) were taken as the main evaluating indicators. VAS is an evaluating indicator that can accurately express the subjective pain of the patients. WOMAC scores are on physical function, stiffness and the degree of pain. It was divided into five grades: 0 points (no), 1 (mild), 2 (moderate), 3 (severe) and 4 (extremely severe).

Statistical analysis

The data were processed by Statistical Product and Service Solutions (SPSS) 19.0 software [International Business Machines Corporation] and displayed as mean \pm SD. Student *t*-tests were performed to compare the differences between the two groups, and one-way ANOVA was conducted to compare the difference among multiple groups. The correlation between two variables was analyzed by Pearson correlation analysis. $P < 0.05$ indicated a statistical difference.

RESULTS

Elevated levels of IL-1 β , IL-6, TNF- α and VEGF in patients

The levels of IL-1 β , IL-6, TNF- α and VEGF in the serum of patients group were 74.91 ± 3.48 , 40.35 ± 27.18 , 67.12 ± 3.15 and 224.42 ± 31.06 ng/L, respectively, which were significantly higher than those of the control group (13.41 ± 1.50 , 12.25 ± 2.58 , 6.91 ± 4.20 and 135.48 ± 20.41 ng/L) ($P < 0.05$) (Figure 1).

Levels of IL-1 β , IL-6, TNF- α and VEGF in patients with different degrees of knee articular cartilage injury

The levels of IL-1 β , IL-6, TNF- α and VEGF showed an increased trend from patients with mild, moderate or severe knee articular cartilage injury, with statistically significant differences ($P < 0.05$) (Figure 2).

Immunohistochemical staining analysis of the levels of IL-1 β , IL-6, TNF- α and VEGF in synovial membrane

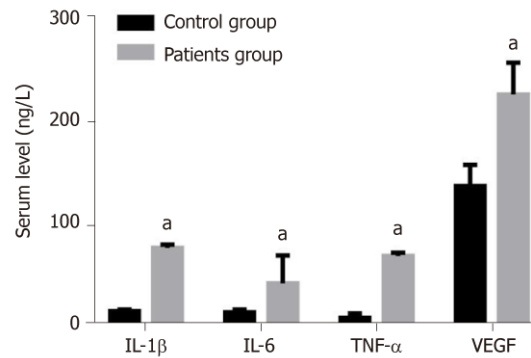


Figure 1 Levels of interleukin-1 β , interleukin-6, tumor necrosis factor- α and vascular endothelial growth factor in patient and control groups.^a $P < 0.05$, vs control group. IL-1 β : Interleukin-1 β ; TNF- α : Tumor necrosis factor- α ; VEGF: Vascular endothelial growth factor.

As seen in [Figure 3](#), the number of positive cells of IL-1 β , IL-6, TNF- α and VEGF in synovial membrane in patients with severe knee articular cartilage injury were significantly higher than those in patients with moderate knee articular cartilage injury. These were also higher than those in the group of patients with mild knee articular cartilage injury ($P < 0.05$).

Changes of clinical indices in patients before and after treatment

After the treatment, the scores of VAS and WOMAC in patients were 2.26 ± 1.13 and 15.56 ± 7.12 points, respectively, which were significantly lower than those before treatment (6.98 ± 1.32 vs 49.48 ± 8.96 points) ($P < 0.05$) ([Figure 4](#)).

Correlation analysis of inflammatory factors with VEGF

Pearson correlation analysis results showed that serum inflammatory factors (IL-1 β and TNF- α) in patients were positively correlated with VEGF ($r = 0.6763$, $r = 0.4856$, $P < 0.01$) ([Figure 5](#)). However, there was no significant correlation between IL-6 and VEGF.

DISCUSSION

In recent years, many studies have found that osteoarthritis patients have immune abnormalities, and abnormal secretions of cytokines might damage cartilage function and metabolism^[14,15]. In addition, aggravated gradual decomposition of cartilage matrix can bring irreversible injury to the joint structure of patients, which is manifested as the corresponding clinical symptoms, thus accelerating the progress of articular cartilage injury^[16,17]. IL-1 β , IL-6 and TNF- α are secreted from macrophages and immune cells, which mainly come from the lining cells of the synovial membrane. These participate in the occurrence and development of osteoarthritis^[18,19]. VEGF is an important factor in promoting neovascularization, and abnormal cell proliferation and differentiation may lead to the persistence of synovial inflammation^[20]. The mechanism of VEGF in promoting the progress of osteoarthritis is believed to promote the proliferation of vascular endothelial cells and the growth of tumor lymphatic vessels, as well as upregulate the expression of anti-apoptotic proteins^[21]. This thereby accelerates the formation of neovascularization in synovial pannus, and the subsequent division of endothelium cells, which is an important factor leading to increased vascular permeability^[22].

Consistent with the role of inflammatory cytokines in the pathogenesis of osteoarthritis, we showed in this study that levels of IL-1 β , IL-6 and TNF- α in the serum of patients with knee articular cartilage injury group were significantly higher than those in the control group ($P < 0.05$). In addition, immunohistochemical staining showed that the numbers of cells with positive staining of IL-1 β , TNF- α and VEGF were statistically increased with disease progression. This suggests that an imbalance of cellular and humoral immunity *in vivo* might be involved in the pathophysiological process of the damage and progress of synovial membrane in knee osteoarthritis^[23]. Patients with osteoarthritis are characterized by articular cartilage degeneration and changes of cartilage matrix composition, and the decrease of anti-angiogenic factors indirectly enhances the functions of pro-angiogenic factors, such as VEGF, in the pathogenesis of osteoarthritis. It was reported that different levels of VEGF are

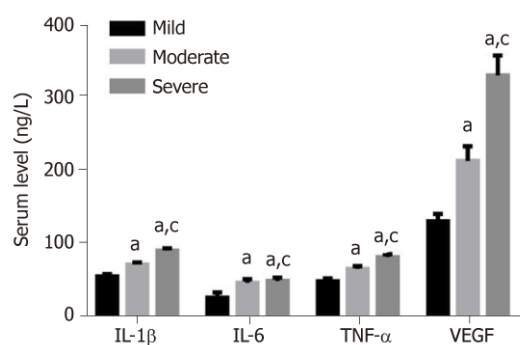


Figure 2 Serum levels of interleukin-1 β , interleukin-6 and tumor necrosis factor- α in patients with different degrees of knee articular cartilage injury.^a $P < 0.05$, vs mild; ^c $P < 0.05$, vs moderate group. IL-1 β : Interleukin-1 β ; TNF- α : Tumor necrosis factor- α ; VEGF: Vascular endothelial growth factor.

detected in patients with osteoarthritis^[24]. In accordance with this, our study showed that, along with osteoarthritis progression, the serum level of VEGF in patients was significantly increased, further supporting the role of VEGF in the pathogenesis and development of osteoarthritis.

VAS is an evaluating indicator that can accurately reflect the subjective pain of patients. Through assessment of physical function, stiffness and the degree of pain, WOMAC scores are currently widely used in the treatment of osteoarthritis to evaluate the therapeutic effect of drugs. In this study, we showed that VAS and WOMAC in patients with knee articular cartilage injury after treatment were significantly lower than those before treatment, indicating that the clinical symptoms were greatly improved. Furthermore, Pearson correlation analysis showed that serum inflammatory factors (IL-1 β and TNF- α) in patients was positively correlated with VEGF, indicating that the imbalance of the immune state *in vivo*, and the increase of factors related to neovascularization, might contribute to the development of osteoarthritis^[25].

In conclusion, IL-1 β , IL-6, TNF- α and VEGF levels are significantly increased in patients with knee articular cartilage injury, and are associated with the severity of disease. This suggests they might play an important role in the occurrence and development of knee articular cartilage injury. Thus, targeting them might be a novel approach for the treatment of knee articular cartilage injury.

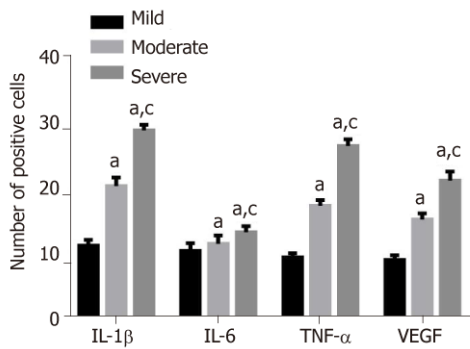


Figure 3 Immunohistochemical staining analysis of the number of positive cells of interleukin-1 β , interleukin-6, tumor necrosis factor- α and vascular endothelial growth factor in synovial membrane (%).^a $P < 0.05$, vs mild; ^c $P < 0.05$, vs moderate group. IL-1 β : Interleukin-1 β ; TNF- α : Tumor necrosis factor- α ; VEGF: Vascular endothelial growth factor.

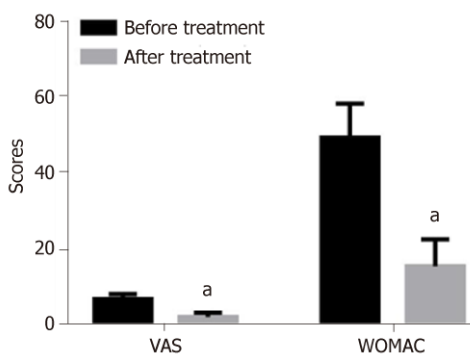


Figure 4 Comparisons of changes in clinical indices before and after treatment.^a $P < 0.05$, vs before treatment. VAS: Visual analogue scale; WOMAC: Western Ontario and McMaster University of Orthopaedic Index.

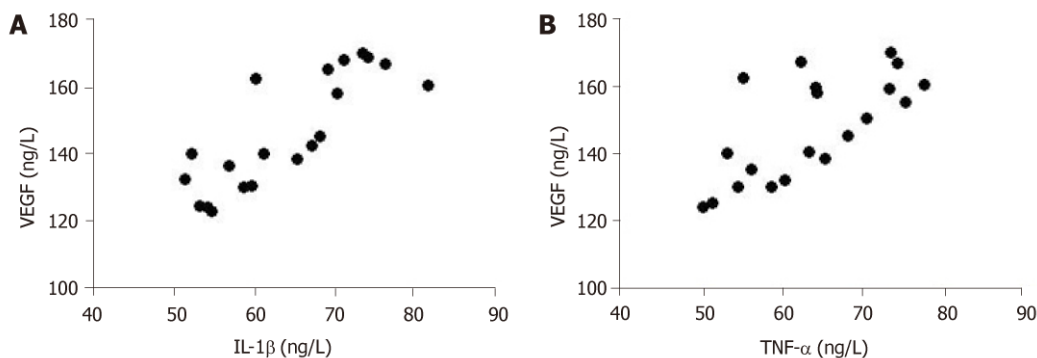


Figure 5 Correlation analysis of interleukin-1 β (A) or tumor necrosis factor- α (B) with vascular endothelial growth factor. IL-1 β : Interleukin-1 β ; TNF- α : Tumor necrosis factor- α ; VEGF: Vascular endothelial growth factor.

ARTICLE HIGHLIGHTS

Research background

Inflammatory cytokines play a vital role in the occurrence of osteoarticular injury and inflammation. Whether inflammation-associated factors interleukin-1 β (IL-1 β), IL-6, tumor necrosis factor- α (TNF- α) and vascular endothelial growth factor (VEGF) are involved in the pathogenesis of knee articular cartilage injury remains poorly understood.

Research motivation

The main topic is the inflammatory cytokines in knee articular cartilage injury.

Research objectives

To measure the levels of inflammatory factors [IL-1 β , IL-6, TNF- α and VEGF] in patients with knee articular cartilage injury.

Research methods

Fifty-five patients with knee articular cartilage injury were selected as the patients groups, and were divided into three grades [mild ($n = 20$), moderate ($n = 19$) and severe ($n = 16$)] according to disease severity and X-ray examinations. Meanwhile, 30 healthy individuals who underwent physical examination were selected as the control group. The levels of IL-1 β , IL-6, TNF- α and VEGF were measured by ELISA and immunohistochemical staining.

Research results

Compared with the control group, the patients group displayed significantly higher levels of IL-1 β , IL-6, TNF- α and VEGF, and the extent of increase was directly proportional to the severity of injury ($P < 0.05$). In addition, the number of cells with positive staining of IL-1 β , IL-6, TNF- α and VEGF in the synovial membrane was significantly increased, along with an increase in disease severity ($P < 0.05$). After treatment, the scores of visual analogue scale (VAS) and the Western Ontario and McMaster University of Orthopaedic Index in the patient group were 2.26 ± 1.13 and 15.56 ± 7.12 points, respectively, which were significantly lower than those before treatment (6.98 ± 1.32 and 49.48 ± 8.96). The correlation analysis suggested that IL-1 β and TNF- α were positively correlated with VEGF.

Research conclusions

IL-1 β , IL-6, TNF- α and VEGF levels are increased in patients with knee articular cartilage injury, and are associated with disease severity. This indicates that they might play an important role in the occurrence and development of knee articular cartilage injury. In addition, therapeutically targeting them might be a novel approach for the treatment of knee articular cartilage injury.

Research perspectives

Abnormal levels of IL-1 β , IL-6, TNF- α and VEGF were found in patients with knee articular cartilage injury, indicating that they might be novel therapeutic targets for the treatment of knee articular cartilage injury.

REFERENCES

- 1 **Ma J**, Niu DS, Wan NJ, Qin Y, Guo CJ. Elevated chemerin levels in synovial fluid and synovial membrane from patients with knee osteoarthritis. *Int J Clin Exp Pathol* 2015; **8**: 13393-13398 [PMID: 26722546]
- 2 **Abdelnaby R**, El Deeb S, Khachab A, Bläsius K, Tingart M, Rath B. Plasma level of Osteopontin does not respond to total replacement Surgery in patients with severe Primary knee/Hip Osteoarthritis. *J Orthop* 2017; **14**: 354-357 [PMID: 28706379 DOI: 10.1016/j.jor.2017.06.008]
- 3 **Yokogawa N**, Toribatake Y, Murakami H, Hayashi H, Yoneyama T, Watanabe T, Tsuchiya H. Differences in Gait Characteristics of Patients with Lumbar Spinal Canal Stenosis (L4 Radiculopathy) and Those with Osteoarthritis of the Hip. *PLoS One* 2015; **10**: e0124745 [PMID: 25893667 DOI: 10.1371/journal.pone.0124745]
- 4 **Kapoor M**, Martel-Pelletier J, Lajeunesse D, Pelletier JP, Fahmi H. Role of proinflammatory cytokines in the pathophysiology of osteoarthritis. *Nat Rev Rheumatol* 2011; **7**: 33-42 [PMID: 21119608 DOI: 10.1038/nrrheum.2010.196]
- 5 **Wojdasiewicz P**, Poniatowski LA, Szukiewicz D. The role of inflammatory and anti-inflammatory cytokines in the pathogenesis of osteoarthritis. *Mediators Inflamm* 2014; **2014**: 561459 [PMID: 24876674 DOI: 10.1155/2014/561459]
- 6 **Miller RE**, Miller RJ, Malfait AM. Osteoarthritis joint pain: the cytokine connection. *Cytokine* 2014; **70**: 185-193 [PMID: 25066335 DOI: 10.1016/j.cyto.2014.06.019]
- 7 **Yuan PW**, Liu DY, Chu XD, Hao YQ, Zhu C, Qu Q. Effects of preventive administration of juanbi capsules on TNF- α , IL-1 and IL-6 contents of joint fluid in the rabbit with knee osteoarthritis. *J Tradit Chin Med* 2010; **30**: 254-258 [PMID: 21287781 DOI: 10.1016/S0254-6272(10)60052-0]
- 8 **Funck-Brentano T**, Cohen-Solal M. Subchondral bone and osteoarthritis. *Curr Opin Rheumatol* 2015; **27**: 420-426 [PMID: 26002035 DOI: 10.1097/BOR.0000000000000181]
- 9 **Tanaka T**, Narazaki M, Kishimoto T. IL-6 in inflammation, immunity, and disease. *Cold Spring Harb Perspect Biol* 2014; **6**: a016295 [PMID: 25190079 DOI: 10.1101/cshperspect.a016295]
- 10 **Gabay C**. Interleukin-6 and chronic inflammation. *Arthritis Res Ther* 2006; **8** Suppl 2: S3 [PMID: 16899107 DOI: 10.1186/ar1917]
- 11 **Nagao M**, Hamilton JL, Kc R, Berendsen AD, Duan X, Cheong CW, Li X, Im HJ, Olsen BR. Vascular Endothelial Growth Factor in Cartilage Development and Osteoarthritis. *Sci Rep* 2017; **7**: 13027 [PMID: 29026147 DOI: 10.1038/s41598-017-13417-w]
- 12 **Liu M**, Yang S, Zhang D, Shui P, Song S, Yao J, Dai Y, Sun Q. Fructopyranose-(1 \rightarrow 4)-glucopyranose inhibits the proliferation of liver cancer cells and angiogenesis in a VEGF/VEGFR dependent manner. *Int J Clin Exp Med* 2014; **7**: 3859-3869 [PMID: 25550894]
- 13 **Cojocaru IM**, Ștefănescu V, Trașcă D, Șerban-Perețeanu A, Chicoș B, Cojocaru M. Multiple Intracerebral Hemorrhages in an Old Patient with Rheumatoid Arthritis. *Rom J Intern Med* 2015; **53**: 365-373 [PMID: 26939215 DOI: 10.1515/rjim-2015-0048]
- 14 **Steinhaus ME**, Christ AB, Cross MB. Total Knee Arthroplasty for Knee Osteoarthritis: Support for a Foregone Conclusion? *HSS J* 2017; **13**: 207-210 [PMID: 28690473 DOI: 10.1007/s11420-017-9558-4]
- 15 **Kong R**, Gao J, Si Y, Zhao D. Combination of circulating miR-19b-3p, miR-122-5p and miR-486-5p expressions correlates with risk and disease severity of knee osteoarthritis. *Am J Transl Res* 2017; **9**: 2852-2864 [PMID: 28670374]
- 16 **Loures FB**, Carrara RJ, Góes RFA, Albuquerque RSPE, Barretto JM, Kinder A, Gameiro VS, Marchiori

- E. Anthropometric study of the knee in patients with osteoarthritis: intraoperative measurement versus magnetic resonance imaging. *Radiol Bras* 2017; **50**: 170-175 [PMID: [28670028](#) DOI: [10.1590/0100-3984.2016.0007](#)]
- 17 **Willett M**, Duda J, Gautrey C, Fenton S, Greig C, Rushton A. Effectiveness of behavioural change techniques in physiotherapy interventions to promote physical activity adherence in patients with hip and knee osteoarthritis: a systematic review protocol. *BMJ Open* 2017; **7**: e015833 [PMID: [28667221](#) DOI: [10.1136/bmjopen-2017-015833](#)]
 - 18 **Lim SH**, Hong BY, Oh JH, Lee JI. Relationship between knee alignment and the electromyographic activity of quadriceps muscles in patients with knee osteoarthritis. *J Phys Ther Sci* 2015; **27**: 1261-1265 [PMID: [25995602](#) DOI: [10.1589/jpts.27.1261](#)]
 - 19 **Bar-Or D**, Rael LT, Thomas GW, Brody EN. Inflammatory Pathways in Knee Osteoarthritis: Potential Targets for Treatment. *Curr Rheumatol Rev* 2015; **11**: 50-58 [PMID: [26002457](#) DOI: [10.2174/1573397111666150522094131](#)]
 - 20 **Bai J**, Li G, Shen M, Sui D, Lin S. Primary central nervous system histiocytic sarcoma mimicking glioma. *Neurol India* 2014; **62**: 684-685 [PMID: [25591690](#) DOI: [10.4103/0028-3886.149409](#)]
 - 21 **Minchenko OH**, Garmash IA, Kovalevska OV, Tsybal DO, Minchenko DO. Expression of phosphoribosyl pyrophosphate synthetase genes in U87 glioma cells with ERN1 knockdown: effect of hypoxia and endoplasmic reticulum stress. *Ukr Biochem J* 2014; **86**: 74-83 [PMID: [25816608](#) DOI: [10.15407/ubj86.06.074](#)]
 - 22 **Ozawa A**, Kadowaki E, Haga Y, Sekiguchi H, Hemmi N, Kaneko T, Maki T, Sakabe K, Hara S, Yamamoto M, Arishima K, Sakaue M. Acetylcholine esterase is a regulator of GFAP expression and a target of dichlorvos in astrocytic differentiation of rat glioma C6 cells. *Brain Res* 2013; **1537**: 37-45 [PMID: [24001591](#) DOI: [10.1016/j.brainres.2013.08.031](#)]
 - 23 **Wang XP**, Deng XL, Li LY. MicroRNA-584 functions as a tumor suppressor and targets PTTG1IP in glioma. *Int J Clin Exp Pathol* 2014; **7**: 8573-8582 [PMID: [25674221](#)]
 - 24 **Lee SS**, Joo YS, Kim WU, Min DJ, Min JK, Park SH, Cho CS, Kim HY. Vascular endothelial growth factor levels in the serum and synovial fluid of patients with rheumatoid arthritis. *Clin Exp Rheumatol* 2001; **19**: 321-324 [PMID: [11407088](#) DOI: [10.1002/1529-0131\(200105\)44:5<1229::AID-ANR209>3.0.CO;2-E](#)]
 - 25 **Sun XP**, Dong X, Lin L, Jiang X, Wei Z, Zhai B, Sun B, Zhang Q, Wang X, Jiang H, Krissansen GW, Qiao H, Sun X. Up-regulation of survivin by AKT and hypoxia-inducible factor 1 α contributes to cisplatin resistance in gastric cancer. *FEBS J* 2014; **281**: 115-128 [PMID: [24165223](#) DOI: [10.1111/febs.12577](#)]



Published By Baishideng Publishing Group Inc
7041 Koll Center Parkway, Suite 160, Pleasanton, CA 94566, USA
Telephone: +1-925-2238242
Fax: +1-925-2238243
E-mail: bpgoffice@wjgnet.com
Help Desk: <https://www.f6publishing.com/helpdesk>
<https://www.wjgnet.com>

