

World Journal of *Gastroenterology*

World J Gastroenterol 2019 July 21; 25(27): 3468-3663



**OPINION REVIEW**

- 3468** Stricter national standards are required for credentialing of endoscopic-retrograde-cholangiopancreatography in the United States
Cappell MS, Friedel DM
- 3484** Colorectal peritoneal metastases: Optimal management review
Sánchez-Hidalgo JM, Rodríguez-Ortiz L, Arjona-Sánchez Á, Rufián-Peña S, Casado-Adam Á, Cosano-Álvarez A, Briceño-Delgado J

REVIEW

- 3503** Eosinophils in the gastrointestinal tract and their role in the pathogenesis of major colorectal disorders
Loktionov A
- 3527** Immune suppression in chronic hepatitis B infection associated liver disease: A review
Li TY, Yang Y, Zhou G, Tu ZK

MINIREVIEWS

- 3538** Device-assisted enteroscopy: A review of available techniques and upcoming new technologies
Schneider M, Höllerich J, Beyna T
- 3546** Identifying high-risk individuals for gastric cancer surveillance from western and eastern perspectives: Lessons to learn and possibility to develop an integrated approach for daily practice
Quach DT, Hiyama T, Gotoda T
- 3563** Is the treatment outcome of hepatocellular carcinoma inferior in elderly patients?
Chu KKW, Chok KSH

ORIGINAL ARTICLE**Basic Study**

- 3572** Mucosal healing progression after acute colitis in mice
Vidal-Lletjós S, Andriamihaja M, Blais A, Grauso M, Lepage P, Davila AM, Gaudichon C, Leclerc M, Blachier F, Lan A
- 3590** Lingguizhugan decoction attenuates diet-induced obesity and hepatosteatosis *via* gut microbiota
Liu MT, Huang YJ, Zhang TY, Tan LB, Lu XF, Qin J

Retrospective Cohort Study

- 3607** Intermediate-advanced hepatocellular carcinoma in Argentina: Treatment and survival analysis
Piñero F, Marciano S, Fernández N, Silva J, Anders M, Zerega A, Ridruejo E, Romero G, Ameigeiras B, D'Amico C, Gaité L, Bermúdez C, Reggiardo V, Colombato L, Gadano A, Silva M

Retrospective Study

- 3619** Quantitative diffusion-weighted magnetic resonance enterography in ileal Crohn's disease: A systematic analysis of intra and interobserver reproducibility
Yu H, Shen YQ, Tan FQ, Zhou ZL, Li Z, Hu DY, Morelli JN

SYSTEMATIC REVIEWS

- 3634** Bioartificial liver support systems for acute liver failure: A systematic review and meta-analysis of the clinical and preclinical literature
He YT, Qi YN, Zhang BQ, Li JB, Bao J

META-ANALYSIS

- 3649** Immunotherapy with dendritic cells and cytokine-induced killer cells for hepatocellular carcinoma: A meta-analysis
Cao J, Kong FH, Liu X, Wang XB

ABOUT COVER

Editorial board member of *World Journal of Gastroenterology*, Dar-In Tai, MD, PhD, Attending Doctor, Chief Doctor, Professor, Department of Gastroenterology and Hepatology, Chang Gung Memorial Hospital, Taipei 105, Taiwan

AIMS AND SCOPE

World Journal of Gastroenterology (*World J Gastroenterol*, *WJG*, print ISSN 1007-9327, online ISSN 2219-2840, DOI: 10.3748) is a peer-reviewed open access journal. The *WJG* Editorial Board consists of 701 experts in gastroenterology and hepatology from 58 countries.

The primary task of *WJG* is to rapidly publish high-quality original articles, reviews, and commentaries in the fields of gastroenterology, hepatology, gastrointestinal endoscopy, gastrointestinal surgery, hepatobiliary surgery, gastrointestinal oncology, gastrointestinal radiation oncology, etc. The *WJG* is dedicated to become an influential and prestigious journal in gastroenterology and hepatology, to promote the development of above disciplines, and to improve the diagnostic and therapeutic skill and expertise of clinicians.

INDEXING/ABSTRACTING

The *WJG* is now indexed in Current Contents®/Clinical Medicine, Science Citation Index Expanded (also known as SciSearch®), Journal Citation Reports®, Index Medicus, MEDLINE, PubMed, PubMed Central, and Scopus. The 2019 edition of Journal Citation Report® cites the 2018 impact factor for *WJG* as 3.411 (5-year impact factor: 3.579), ranking *WJG* as 35th among 84 journals in gastroenterology and hepatology (quartile in category Q2). CiteScore (2018): 3.43.

RESPONSIBLE EDITORS FOR THIS ISSUE

Responsible Electronic Editor: *Yu-Jie Ma*

Proofing Production Department Director: *Yun-Xiaojuan Wu*

NAME OF JOURNAL

World Journal of Gastroenterology

ISSN

ISSN 1007-9327 (print) ISSN 2219-2840 (online)

LAUNCH DATE

October 1, 1995

FREQUENCY

Weekly

EDITORS-IN-CHIEF

Subrata Ghosh, Andrzej S. Tarnawski

EDITORIAL BOARD MEMBERS

<http://www.wjgnet.com/1007-9327/editorialboard.htm>

EDITORIAL OFFICE

Ze-Mao Gong, Director

PUBLICATION DATE

July 21, 2019

COPYRIGHT

© 2019 Baishideng Publishing Group Inc

INSTRUCTIONS TO AUTHORS

<https://www.wjgnet.com/bpg/gerinfo/204>

GUIDELINES FOR ETHICS DOCUMENTS

<https://www.wjgnet.com/bpg/GerInfo/287>

GUIDELINES FOR NON-NATIVE SPEAKERS OF ENGLISH

<https://www.wjgnet.com/bpg/gerinfo/240>

PUBLICATION MISCONDUCT

<https://www.wjgnet.com/bpg/gerinfo/208>

ARTICLE PROCESSING CHARGE

<https://www.wjgnet.com/bpg/gerinfo/242>

STEPS FOR SUBMITTING MANUSCRIPTS

<https://www.wjgnet.com/bpg/GerInfo/239>

ONLINE SUBMISSION

<https://www.f6publishing.com>



Colorectal peritoneal metastases: Optimal management review

Juan Manuel Sánchez-Hidalgo, Lidia Rodríguez-Ortiz, Álvaro Arjona-Sánchez, Sebastián Rufián-Peña, Ángela Casado-Adam, Antonio Cosano-Álvarez, Javier Briceño-Delgado

ORCID number: Juan Manuel Sánchez-Hidalgo (0000-0002-0258-0673); Lidia Rodríguez-Ortiz (0000-0003-1201-7128); Álvaro Arjona-Sánchez (0000-0002-3024-3009); Sebastián Rufián-Peña (0000-0003-3060-2881); Ángela Casado-Adam (0000-0001-5988-7310); Antonio Cosano-Álvarez (0000-0003-3101-1362); Javier Briceño-Delgado (0000-0001-7027-7898).

Author contributions: Sánchez-Hidalgo JM, Arjona-Sánchez A and Rodríguez-Ortiz L contributed to the conception and design of the review; Sánchez-Hidalgo JM, Rodríguez-Ortiz L, Casado-Adam A and Cosano-Álvarez A contributed to literature review and analysis; Sánchez-Hidalgo JM, Rodríguez-Ortiz L wrote the article; Sánchez-Hidalgo JM, Rodríguez-Ortiz L and Arjona-Sánchez A contributed to drafting and critical revision and editing; Sánchez-Hidalgo JM, Rufián-Peña S and Briceño-Delgado J approved the final version.

Conflict-of-interest statement: Any author has any potential conflicts of interest to declare. No financial support was received for this review.

Open-Access: This article is an open-access article which was selected by an in-house editor and fully peer-reviewed by external reviewers. It is distributed in accordance with the Creative Commons Attribution Non Commercial (CC BY-NC 4.0) license, which permits others to distribute, remix, adapt, build

Juan Manuel Sánchez-Hidalgo, Lidia Rodríguez-Ortiz, Álvaro Arjona-Sánchez, Sebastián Rufián-Peña, Ángela Casado-Adam, Antonio Cosano-Álvarez, Javier Briceño-Delgado, Department of General and Digestive Surgery, Reina Sofia University Hospital, Cordoba 14004, Spain

Corresponding author: Juan Manuel Sánchez-Hidalgo, MD, PhD, Doctor, Surgical Oncologist, Department of General and Digestive Surgery, Reina Sofia University Hospital, Avda. Menéndez Pidal s/n, Cordoba 14004, Spain. juanmanuel Sanchezhidalgo@hotmail.com
Telephone: +34-957-010000

Abstract

The peritoneum is a common site of dissemination for colorectal cancer, with a poorer prognosis than other sites of metastases. In the last two decades, it has been considered as a locoregional disease progression and treated as such with curative intention treatments. Cytoreductive surgery (CRS) and hyperthermic intraperitoneal chemotherapy (HIPEC) is the actual reference treatment for these patients as better survival results have been reached as compared to systemic chemotherapy alone, but its therapeutic efficacy is still under debate. Actual guidelines recommend that the management of colorectal cancer with peritoneal metastases should be led by a multidisciplinary team carried out in experienced centers and consider CRS + HIPEC for selected patients. Accumulative evidence in the last three years suggests that this is a curative treatment that may improve patients disease-free survival, decrease the risk of recurrence, and does not increase the risk of treatment-related mortality. In this review we aim to gather the latest results from referral centers and opinions from experts about the effectiveness and feasibility of CRS + HIPEC for treating peritoneal disease from colorectal malignancies.

Key words: Peritoneal metastases; Colorectal cancer; Cytoreductive surgery; Hyperthermic intraperitoneal chemotherapy; Peritoneal carcinomatosis

©The Author(s) 2019. Published by Baishideng Publishing Group Inc. All rights reserved.

Core tip: Patients with peritoneal metastases from colorectal cancer have classically been associated with limited survival and treated only with palliative surgery and systemic support. Cytoreductive surgery and hyperthermic intraperitoneal chemotherapy, often combined with systemic treatment, are increasingly performed with a curative intent for well-selected patients. Recent data suggests an important improvement of overall and disease-free survival for these patients. This article aims to review the state of art for the management of peritoneal metastases from colorectal origin and to confine the latest experts' consensus and future directives.

upon this work non-commercially, and license their derivative works on different terms, provided the original work is properly cited and the use is non-commercial. See: <http://creativecommons.org/licenses/by-nc/4.0/>

Manuscript source: Invited manuscript

Received: February 27, 2019

Peer-review started: March 1, 2019

First decision: April 5, 2019

Revised: May 20, 2019

Accepted: June 22, 2019

Article in press: June 23, 2019

Published online: July 21, 2019

P-Reviewer: Azer SA, Fekaj E, Hiraki M

S-Editor: Yan JP

L-Editor: A

E-Editor: Wang J



Citation: Sánchez-Hidalgo JM, Rodríguez-Ortiz L, Arjona-Sánchez Á, Rufián-Peña S, Casado-Adam Á, Cosano-Álvarez A, Briceño-Delgado J. Colorectal peritoneal metastases: Optimal management review. *World J Gastroenterol* 2019; 25(27): 3484-3502
URL: <https://www.wjnet.com/1007-9327/full/v25/i27/3484.htm>
DOI: <https://dx.doi.org/10.3748/wjg.v25.i27.3484>

INTRODUCTION

We conducted a literature review to provide a comprehensive and updated overview of the actual management of colorectal cancer (CRC) with peritoneal metastases (PM) as the only site of spread. Our specific purpose is to enhance our understanding of the following aspects of this disease: (1) To know the biological pathway for PM, the concept of its locoregional spread, and the associated genetic and molecular factors; (2) To update our knowledge about the prognosis factors of peritoneal disease; (3) To delve into the multidisciplinary approach of peritoneal metastatic CRC, both synchronous and metachronous; (4) To show the recent scientific evidence on clinical trials and meta-analyses on disease-free and overall survival after treatment with cytoreductive surgery (CRS) plus hyperthermic intraperitoneal chemotherapy (HIPEC); and (5) To show the new and more promising investigation lines and trials for the future management of peritoneal metastatic CRC.

EPIDEMIOLOGY

CRC is the third most common cancer and the second most common cancer-related mortality globally. Patients have a favorable prognosis when diagnosed at an early stage: 70%-80% are eligible for curative-intent surgery, with a 5-year survival of 72%-93% for stages I-II^[1]. Approximately 25% of the remaining patients present metastases at the time of diagnosis^[2]. Among these individuals, up to 8% have synchronous peritoneal carcinomatosis, and approximately 20% already have liver metastases^[3]. Recurrent or systemic disease during the follow-up period after curative treatment of the primary tumor will develop in 20%-30% of patients. Half of these recurrences will develop liver metastases^[3].

Although it was believed that metachronous PM occur in less than 10% of cases of CRC, being the third most frequent site of recurrence after liver and lung, its prevalence is still not well known. As an example of the underestimation, due to the lack of reliability of traditional imaging and unspecific symptomatology, one study of autopsied patients that did from CRC reported an incidence of 40%-80% unknown metachronous peritoneal carcinomatosis^[4]. The peritoneum is the only dissemination location in 4.8% of cases and is more frequent for colon tumors (5.7%) than for rectal tumors (1.7%)^[2]. Thus, thorough studies must be performed to exclude another site of metastatic disease because of the high possibility of further spread.

PATHOPHYSIOLOGY OF COLORECTAL PERITONEAL METASTASES

Peritoneal seeding as a dissemination pathway of an invasive cancer is believed to be the final result of the specific expression of oncogenes and binding proteins that allow the detachment of tumor cells to proliferate in the peritoneal environment^[5]. The actual deep knowledge of genetics and molecular cancer mechanisms is becoming a strong tool to determine the likelihood for peritoneal spread, to avoid locoregional relapse after the first curative surgery and to assess the real implication on prognosis.

The molecular genetic influence

Many different genetic alterations characterize the two main pathways that have been described for the development of CRC: The conventional adenoma-carcinoma pathway and the serrated pathway. Notably, 80% of sporadic cases of CRC involve chromosomal instability, which includes the molecular targets for most of the novel chemotherapy agents, including K-RAS, B-RAF or pT53. Another group encompasses microsatellite instability (MSI) as a result of inactivation, mutation and/or epigenetic alteration of mismatch repair genes. This mechanism is one of the main causes of hereditary nonpolyposis CRC but also entails 10%-20% of sporadic CRCs. Depending

on the proportion and type of microsatellite marker mutation, these tumors are classified into two groups: High (MSI-H) and low MSI or microsatellite stability (MSI-L/MSS)^[2,6,7].

MSI-H has been reported as a better prognosis condition, with a lower metastatic potential for distant recurrence than MSI-L tumors. However, a large single-center study^[8] on outcomes for CRCs with MSI showed that MSI-H recurrences, most of them located on the peritoneum, had a worse survival than MSI-L carcinomas. These studies showed that most of these relapses are not eligible for curative resection and that this type of tumor progression is able to avoid immune mechanisms of protection by several means, which increases its malignant potential. Advanced tumor stages for MSI-H tumors have also been associated with BRAF mutations^[9].

The BRAF V600E mutation is observed in 10% of CRCs, and it has been widely related to a worse prognosis. A recent meta-analysis described a more than two times higher risk of mortality in patients carrying this alteration^[10]. The mild response to modern chemotherapy is attributed to a frequent acquired resistance to BRAF-inhibitor development^[11]. This mutation has also been strongly associated with PM^[12]. However, other studies have reported a more encouraging prognosis when the BRAF V600E mutation is found in early-stage cancers^[13] or when the mutation is a non-V600E BRAF mutation^[14].

KRAS mutations are present in up to 40% of CRCs sporadic cases, and evidence has shown that codon 12 KRAS mutations encompass a negative prognosis but not codon 13 KRAS mutations^[15]. This biomarker has also been reported as a risk factor for a worse prognosis in patients with PM from CRC origin, and its detection has played a major role in patient selection for CRC+HIPEC in recent years^[16]. A new oncogenic mechanism that constrains the tumor cell phenotype switch, called the epithelial-mesenchymal transition, has been suggested to be an aggressive subtype for the high rates of this mutation detected on carcinomatous nodules in a recent publication^[17].

Peritoneal seeding theory

Peritoneal implants are believed to be the consequences of primary abdominal tumor cell detachment or malignant cell dissemination during surgical manipulation of the tumor when the margins of resection are very close and for lymphatic or blood vessel transection. These cells attach to the peritoneum as a result of the molecular interaction between cancer cells and host elements, and invade the subperitoneal layer, where angiogenesis promotes their growth. Furthermore, numerous metachronous peritoneal implants developed along the surgical planes that were opened during the first surgery, becoming trapped by fibrin as part of the healing process, which can be a difficult location to reach by systemic chemotherapy^[5].

CLINICAL PRESENTATION

Risk factors for developing peritoneal metastases from colorectal cancer

Population-based studies agree on a set of risk factors for developing metachronous PM for CRC, which includes the stage at diagnosis (incidence for pT4 stage, established as an independent risk factor, has been reported to be 17%-50%; and for pT3 stage of 5%-10%)^[18,19], intraabdominal colon location, principally right-side colon cancer, infiltrative and ulcero-infiltrative carcinomas, mucinous adenocarcinoma, younger patients than 70-75 years, emergency procedures because of obstructive or perforated cancer at diagnosis, lymph node metastases and nonradical oncological resection during the first surgery^[20-22] (Table 1). By knowing which patients are more likely to develop peritoneal spread of the disease, several prophylactic or early detection strategies have been designed, as listed below.

Complicated disease presentation: Recommendation for management

Clinical presentation of intestinal obstruction and/or perforation involves a poor prognosis, independent of stage. Even uncommon, if this situation occurs in the context of a synchronous PM scenario, with the main aim of offering the best prognosis possible to these patients, the expert global recommendations include the following: (1) To perform the minimal surgical action needed to resolve the emergency situation. Primary resection should only be performed in perforated tumors. Obstructed patients should be treated by creating derivative stomas. Non-obstructed tumors should not be resected but treated by stomas or stents, although colonic stenting should be avoided in patient candidates for antiangiogenic agents because of higher rates of perforation reported^[1]; (2) Always provide adequate biopsies of the primary tumor and/or peritoneal implants; (3) Describe the extension of the peritoneal disease using the peritoneal cancer index (PCI) score. If limited peritoneal

Table 1 Risk factors for metachronous peritoneal metastases

Risk factors for metachronous peritoneal metastases
Advanced T stage
Lymph node metastases
Synchronous ovarian metastases
Poor differentiation
Colon origin (versus rectal origin)
Uncomplete primary tumor resection
Mucinous adenocarcinoma
Signet ring histology
Emergency surgery at diagnosis
Young age

disease is found, there is still a high recommendation to not perform surgical resection in the emergency context because it does not add a better free-disease survival and could hinder a better combined treatment modality^[23,24].

THE NATURAL EVOLUTION OF COLORECTAL PERITONEAL DISEASE

PM is a negative prognostic factor in patients with metastatic CRC. Patients with isolated nonperitoneal sites (including liver and lungs) had significantly better overall survival than that of patients with isolated peritoneal metastatic CRC. A recent large cohort study^[25] showed that the combination of peritoneal involvement with two nonperitoneal sites had a similar survival compared with peritoneal metastasis alone. In fact, given the poor prognosis of PM itself, in the eighth edition of the tumor-node-metastasis classification published in 2017, CRC with peritoneal metastasis is categorized as M1c, with or without other organ involvement, separately from M1a (one organ metastases) and M1b (\geq two organ metastases).

Historically, as peritoneal carcinomatosis was considered a terminal stage of disease, patients used to receive only supportive treatment or palliative chemotherapy. Generally, survival did not reach 6 mo, and patients were extremely symptomatic because of abdominal distension, intestinal obstruction and tumoral cachexia for constitutional syndrome^[26]. Palliative surgery was not a better option, since it reached a high perioperative mortality and morbidity (over 12% and 22%, respectively)^[27]. Currently, the best survival reported for only systemic modern chemotherapy and supportive care for PM from colorectal origin is 15.2-23.4 mo^[28,29]. These poor results prompted the need to find a more effective approach for this stage of disease.

CYTOREDUCTIVE SURGERY AND HYPERTHERMIC INTRAPERITONEAL CHEMOTHERAPY

Why should this treatment be considered?

In the 1980s, according to Sugarbaker *et al*^[30] publications, peritoneal carcinomatosis ceased to be considered a systemic metastatic disease and therefore a terminal condition. Currently, peritoneal carcinomatosis is referred to as PM, and it is determined to be a locoregional spread that is eligible for a curative intent approach based on optimal CRS plus HIPEC^[25,28,31-34]. This treatment entails a major, expensive and complex surgery that requires an optimal selection of the patients, with an adequate performance status and an accurate preoperative extension study, and the key for the best survival outcomes is to ensure a complete cytoreduction with no residual tumor remaining. Therefore, a presurgical study is paramount to optimizing the indications of the patients who would benefit the most from this treatment.

Patients selection

The performance status of the patient is a fundamental aspect considering the morbidity of CRC+HIPEC. Eastern Cooperative Oncology Group or World Health Organization indices > 2 and serious comorbidities (severe cardiopulmonary or renal failure) are considered major contraindications^[35]. Age is a factor to be considered

globally, but there is no cut-off to contraindicate CRS plus HIPEC.

Preoperative scores: Tools for prognosis and surgical indication

Peritoneal carcinomatosis index: PCI is the most accepted score for both evaluating the tumor burden and estimating the patient prognosis, suggesting this score as a helpful tool for surgical indication as well (Figure 1). Faron *et al*^[36] showed a significant relationship between two factors: 5-year survival was noticeably higher (53%) for PCI < 10, up to 23% for PCI between 10-20 and only 12% for PCI > 20. Currently, the majority of guidelines accept a PCI > 20 as a contraindication for CRS plus HIPEC^[37].

Peritoneal surface disease severity score: The peritoneal surface disease severity score (PSDSS) is another commonly used and validated preoperative severity score. Some experts consider a PSDSS > IV (10 points) a contraindication for CRS due to its ominous outcomes. No additional benefit has been shown for PSDSS over PCI^[38].

Completeness of the cytoreduction score: Completeness of the cytoreduction score is another useful tool widely used to assess prognosis. A complete resection of macroscopic tumors is a necessary requirement for the long-term benefit of CRS; thus, incomplete resections or debulking have shown survival improvement^[32,39]. In other words, CRS must not be performed if less than a CC1 (< 2.5 mm) cytoreduction cannot be assured (for peritoneal disease, that small amount of residual tumor is expected to be eradicated by HIPEC)^[40].

Resectability

For every patient diagnosed with CRC, abdomen and chest computed tomography (CT) and complete colonoscopy (or a CT colonography if the former cannot be done^[41]) with biopsies for histopathological study must be performed. Positron emission tomography (PET) is not routinely recommended by the experts, although PET is considered a helpful tool for a more truthful evaluation of the tumor extension in cases of extra-abdominal disease suspicion and for obtaining additional information on equivocal lesions. Special attention should be paid to the detection of radiological signs of peritoneal metastasis on the abdominal CT scan to contemplate the best treatment approach for the patient. These signs include ascites, mesenteric effacement, peritoneal nodules or masses, luminal narrowing, peritoneal thickening and enhancement (Figure 2).

Assessment of a preoperative PCI with imaging would allow a preliminary evaluation of complete tumor resectability that can be useful to avoid unnecessary surgeries. However, a nonnegligible rate of inaccuracy between radiological PCI and surgical PCI has been observed, mainly because of the underestimation of tumor burden and operator dependence^[42]. Implant sizes less than 5 mm and locations are the main factors for missing disease^[43]. Magnetic resonance imaging has been reported to have a higher sensitivity than CT scan, especially for implants located on the small bowel (quadrants 9 to 12) and for unexperienced radiologists^[42,44]. Combining both techniques can also increase the precision of preoperative estimation^[45].

Sugarbaker *et al*^[46] proposed a series of radiologic features that could predict, if two or more are present, unresectability, suboptimal surgical resection or complex resections due to the tumor burden. PET/CT has demonstrated good sensitivity and specificity for the detection of peritoneal disease^[47]. However, its accuracy can be altered in cases of small implants, mucinous and gastric tumors, as well as under some inflammatory conditions (*e.g.*, inflammatory bowel disease or abscesses).

Consideration of synchronous lymph node infiltration

Lymph node infiltration is widely recognized as a poor prognosis factor for recurrence in the setting of the primary tumor. Publications on this theme also note that lymph node metastases present a more aggressive tumor biology at the time of CRS+HIPEC and have a dismal effect on survival^[48,49].

Consideration of synchronous liver metastases

Concurrent liver and PM were initially considered a nonresectable condition due to the poor prognosis. However, the more recent consideration of liver implants with a poorer metastatic potential than peritoneal lesions and its excellent response (up to 60%) to modern systemic chemotherapy have changed the minds of surgeons concerning its approach[a].

In the last decade, several publications have suggested the feasibility and shown the survival improvement of liver metastases resection without adding morbidity^[50,51]. There is no consensus on the number of liver metastases that limits the indication for CRS plus HIPEC as long as complete resection can be fulfilled^[52]. Elias developed a nomogram to estimate the prognosis of patients according to the number of liver metastases and the PCI^[53].

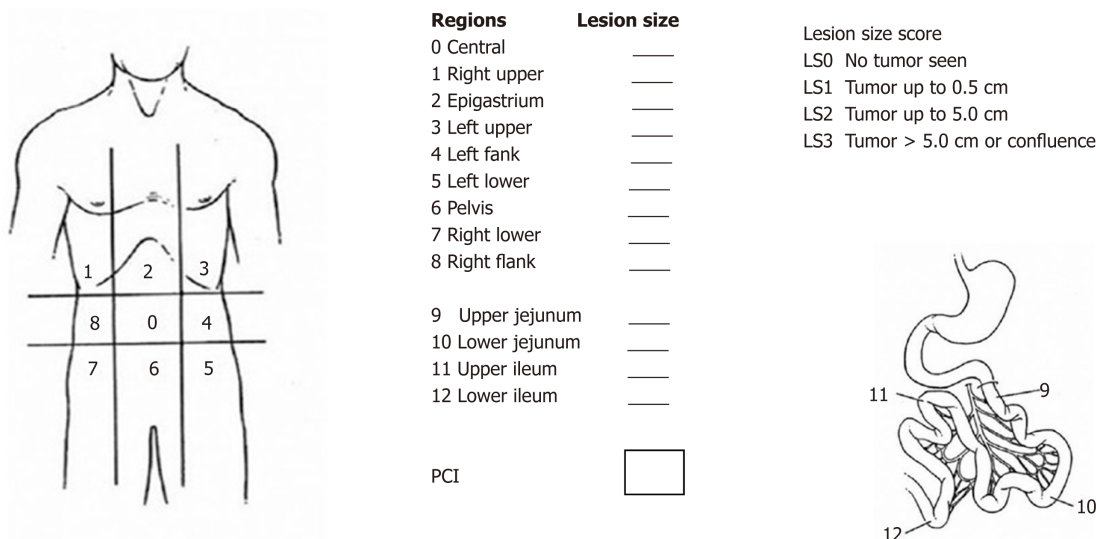


Figure 1 Peritoneal carcinomatosis index described by Sugarbaker P.

Although the presence and amount of liver disease are no longer a contraindication for CRS plus HIPEC, a recent meta-analysis on the survival benefit of these patients found a negative or no significant impact on survival in most of the studies compared to patients with PM alone^[54]. However, ablation or resection of liver metastases has proven to offer better survival compared to palliative treatment^[55]. Therefore, multidisciplinary consensus and individual evaluation must be considered for every particular case.

Absolute exclusion criteria for CRS plus HIPEC

Absolute exclusion criteria for CRS plus HIPEC: Bulky and/or diffuse peritoneal metastasis (Figure 3); Unresectable extra-abdominal metastases; Vast small bowel serosa or small bowel mesentery involvement; Multi-segmentary malignant bowel obstruction or non-affected length of small bowel < 150 cm; Massive affection of the hepatic hilus; The presence of unresectable liver metastases or the requirement of a major hepatectomy, which could lead to insufficient hepatic function.

THE ROLE OF SYSTEMIC CHEMOTHERAPY

The effectiveness of neoadjuvant and adjuvant systemic chemotherapy for patients with CRS and PM has long been controversial among different publications.

Neoadjuvant chemotherapy

With the present experience, no survival benefits can be attributed to the administration of neoadjuvant chemotherapy for PM from CRC origin, without extra-abdominal disease. A recent systematic review found no strong evidence for its efficacy regarding overall survival^[56]. Neoadjuvancy has only shown survival improvement in univariate analysis in some publications, and even in two papers^[57,58] multivariate analysis suggested a worse median survival when neoadjuvant chemotherapy was used. A prospective study reported the first experience using modern systemic chemotherapy with and without biological agents^[59] and showed no effects on unresectable disease, considering a minimal study sample and a high percentage of unfavorable histology.

Notably, there are wide and non-standardized chemotherapy regimens used for the different teams and no randomized controlled trial has been performed in this context, which hinders the potential implication of this therapy. Similarly, there is no reliable data concerning the safety of the surgery following neoadjuvant chemotherapy with biological agents, such as bevacizumab, a vascular endothelial growth factor inhibitor that has been suggested as a risk factor for anastomotic leaks due to its implication in tissue regeneration. There are few publications on this issue, initially brought to light by Eveno *et al*^[60], whose retrospective analysis showed a statistically significant increase in major morbidity (mainly because of intraabdominal abscesses) when bevacizumab was included in the neoadjuvant treatment. Subsequently, Ceelen *et al*^[61] published their experience using bevacizumab neoadjuvant regimens, and they

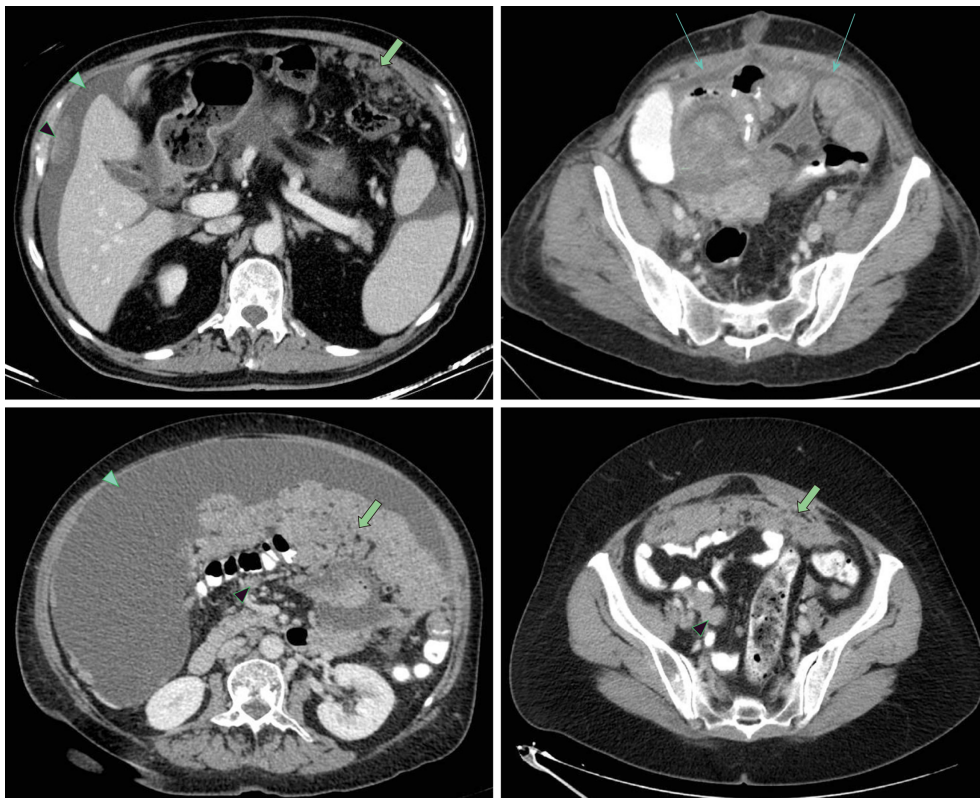


Figure 2 Radiological computed tomography signs for peritoneal disease. Wide green arrow: Omental cake; Thin green arrow: Peritoneal thickening; Green arrow-head: Malignant ascites; Black arrow-head: Peritoneal nodules.

not only found worsening of the postoperative morbidity but also reported a beneficial effect on overall survival. Other recent publications describe no major postoperative complications related to the use of bevacizumab in the neoadjuvant protocol^[62,63], but there are no further studies specifically on CRC.

Adjuvant chemotherapy

The same systematic review^[56] suggests the positive effect of adjuvant chemotherapy on overall survival, despite the heterogeneity of the studies. The most recent publications concur on reporting improvement in median survival with modern versus standard chemotherapy protocols^[64], and these authors also agree on the actual approach of M1c as a curable stage for CRC^[65]. The clinical value of biological therapies remains uncertain. The concept of blocking angiogenesis was a new promising tool for metastatic CRC and has gained popularity in recent years. Previous publications described no increase in survival using these agents after resectable or unresectable disease^[64,66]. Conversely, a recent meta-analysis^[67] on the different types of anti-VEGF antibody combination therapies has shown a significant improvement in progression-free survival, overall survival and response rate.

The number of adjuvant chemotherapy cycles did not demonstrate a clear relationship with survival in previous publications^[56]. A recent study^[68] encompassing six phase III trials evaluating the noninferiority of 3 versus 6 months administration of adjuvant modern chemotherapies with either FOLFOX (fluorouracil, leucovorin, and oxaliplatin) or CAPOX (capecitabine and oxaliplatin) was conducted. Among 12384 patients with stage III colon cancer, the 6-month duration of FOLFOX therapy increased the rate of disease-free survival, particularly among patients with high-risk cancers (T4, N2, or both). However, efficacy was maintained with the 3-month duration for low-risk patients and for the CAPOX regimen, which suggests that this protocol could be evaluated to prevent adverse effects, such as persistent neurotoxicity associated with oxaliplatin.

However, the most important independent factor for a better survival is the radical resection of the tumor with curative intent^[69]; thus, the effectiveness of any treatment highly depends on the extent of the tumor and the completeness of cytoreduction, attempting to avoid a delay of adjuvant treatment due to surgical complications.

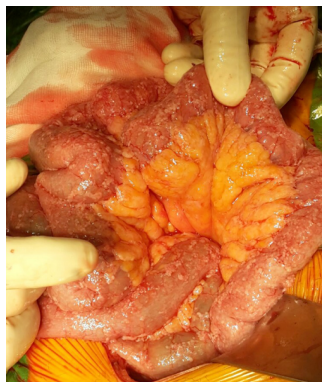

Figure 3 Diffuse miliumary carcinomatosis on the small bowel as an example of contraindication for complete cytoreductive surgery.

OUTCOMES OF CYTOREDUCTIVE SURGERY PLUS HYPERTHERMIC INTRAPERITONEAL CHEMOTHERAPY

Morbidity and mortality

A large meta-analysis^[65] found that intention-to-cure treatments improved overall survival in patients with CRC + PM better than palliative strategies. The risks reported have progressively decreased (recent studies report 1%-5% mortality rates at centers of excellence). The morbidity associated with curative treatments was higher, but it did not increase the risk of treatment-related mortality or caused an early termination of the treatment. Additionally, the reported morbidity rates are similar to those of other major abdominal procedures: Increased treatment-related complications, longer hospital stays and higher rates of short-term readmission^[33,70,71] (Table 2).

A consideration that should be highlighted is that experience and learning curve play an important role in the morbidity and mortality outcomes, so it is strongly recommended that patients should be treated in experienced centers, mentored by specialized institutions for peritoneal diseases, such as PSOGI^[70]. Regarding the laparoscopic approach, HIPEC delivery by the laparoscopic approach has already been accepted as a safe and feasible procedure that is performed for different indications. However, there is a lack of knowledge about the oncological quality of laparoscopy CRS for CRC with peritoneal implants. Some groups have published their early experiences in this field; all of these reports suggested the careful selection for thin patients with a PCI < 10 to ensure a complete resection^[72-74].

Survival outcomes

In recent years, CRS plus HIPEC plus systemic chemotherapy (both neoadjuvant and after surgery) comprise the multidisciplinary treatment performed in most of the referral centers. Overall survival results with this management can reach up to 62 mo if optimal cytoreduction is achieved (this means, following the cytoreduction completeness score: CCO, no tumor nodules left or CC1, implants ≤ 2.5 mm in maximum dimension)^[25]. Increasing evidence from large multicenter cohort studies and some randomized controlled trials suggests that, in selected patients, CRS plus HIPEC as a combined management definitely provides improved overall and disease-free survival compared to that conferred by systemic chemotherapy alone, and possibly a major part of this benefit has to be attributed to cytoreduction^[25,28,31,34,65,75] (Table 3).

A recent review of current guidelines about the management of patients with colorectal PM shows no definitive agreement about the role of CRS plus HIPEC, but most of them recommend this approach as a standard therapy for selected patients, reaching a consensus in 71% with a level of evidence 1b^[35]. The treatment approach for these patients should always be assessed by a multidisciplinary team discussion, which includes at least a surgeon (ideally, an oncologist surgeon), an oncologist and a radiologist expert^[52]. Considering these concepts, the latest National Comprehensive Cancer Network (NCCN) guidelines^[32] recommend that CRS plus HIPEC for colorectal PM be considered only at experienced centers for selected patients with limited PM for whom complete cytoreduction is deemed to be achieved.

The role of HIPEC

The lack of consensus about the role of HIPEC may be due to several reasons: The marked heterogeneity of protocols, drugs, carrier solutions and methods of HIPEC

Table 2 Patient and operative factors associated with cytoreductive and hyperthermic intraperitoneal chemotherapy morbidity (modified from Newton *et al*^[70])

Patients characteristics	Operative factors
Age > 60-70 yr	Pancreatic resections
Performance status	Bowel resection and anastomosis
Hypoalbuminemia	Surgeon experience
	Peritoneal carcinomatosis index

administration (open, semi-open, closed techniques) and the discrepancy concerning patient eligibility and lack of randomized trials in the era of modern chemotherapy and targeted therapy.

The preliminary results of the PRODIGE 7 trial^[76], presented at the American Society of Clinical Oncology (ASCO) meeting in 2018, questioned the widespread conviction of the beneficial effects of HIPEC. After complete cytoreduction of M1c CRC, 265 patients were randomized to standard treatment plus HIPEC with oxaliplatin or standard treatment alone. No significant difference in overall survival was found, with a median of 41.7 months in the HIPEC arm *vs* 41.2 mo in the non-HIPEC arm [Hazard ratio (HR) = 1.00, 95% confidence interval (CI): 0.73-1.37] and no significant difference in relapse-free survival (13.1 *vs* 11.1 mo, HR = 0.90, 95%CI: 0.69-1.90). However, a trend toward better disease-free survival was found on the Kaplan-Meier curves for the first 18 months after surgery, and a subgroup analysis for patients with a PCI between 11 and 15 showed significantly better overall and recurrence-free survival for the HIPEC group.

Regarding morbidity, the study reported a higher late, grade 3-5 morbidity (up to 60 d after surgery) in the HIPEC arm (24.1% *vs* 13.6%, *P* = 0.03). The unexpected results have encouraged the scientific community to continue searching for the role of HIPEC in PM, as its advantageous effects have been extensively reported in the biomedical literature for CRC and recently proven for other origins^[77]. To our knowledge, high quality and complete cytoreduction has been confirmed once again as a pivotal pillar of treatment for peritoneal dissemination of CRC. Efforts are now focused on electing patients who would benefit the most from HIPEC because this trial remarks high PCI as an already known impaired factor.

Another goal is to ascertain the real morbidity (as most of the publications only report the 30-day morbidity-mortality and have widely been compared, similar to other major abdominal surgeries^[78]) and reduce the side-effects of HIPEC^[79]. This may be achieved by either minimizing drug doses (which has been one critic of the PRODIGE 7, considering previous experimental studies)^[80], establishing the benefits of hyperthermia alone and combined with the chemotherapy agents, or trying different drugs or delivery systems. Additionally, the final results are published; to date, only one multicenter randomized trial studying the effects of HIPEC *vs* standard treatment for patients with established PM of CRC origin (NCT02179489). Therefore, the search is ongoing, and further trials are needed to determine what HIPEC can offer.

REITERATIVE CYTOREDUCTIVE PROCEDURES

Approximately 70-80% of the patients undergoing CRS plus HIPEC will develop recurrence disease, despite the curative intention of this approach. Half of these recurrences will be confined to the peritoneal cavity^[81]. This reality has led to the study of the feasibility and safety of reiterative CRS and even HIPEC procedures in recent years. The morbidity and mortality of these surgeries are similar to those of the first procedure in high volume centers^[82]. Furthermore, this active approach to recurrent abdominal disease has reported a median survival from 39 to 42.9 mo, a clearly better long-term survival compared to that obtained with systemic treatment alone^[82-84].

Keeping in mind that HIPEC therapy has not been proven to be an independent risk factor itself for postoperative complications^[71] and that the morbidity reported for CRS in experienced centers is similar to that in other major surgeries, the combined CRS plus HIPEC approach seems an acceptable strategy for this poor stage of disease, as studies continue to show further evidence. Moreover, traditional adjuvant systemic chemotherapy can still be performed following surgery (as it would be the only treatment if surgery could not be performed or it would be rejected). Issues such as the adjunctive contribution of intraperitoneal chemotherapy to CRS and optimal

Table 3 Survival of patients with peritoneal metastases from colorectal cancer treated by cytoreductive surgery plus hyperthermic intraperitoneal chemotherapy

Author/ Years/ Country	1-yr SR (%)	3-yr SR (%)	5-yr SR (%)	Mortality rate (%)	Morbidity rate (%)	Median OS (mo)	OS 95%CI (mo)	PFS 95%CI (mo)	DFS/RFS 95%CI (mo)	Follow-up times (range) (mo)
Controlled studies										
Franko/2010/ America ^[109]	92	51	28	NR	NR	34.7	NR	NR	NR	NR
Gervais/2013/ Canada ^[110]	92	61	36	4	20	54	NR	NR	8	22.8 (2-81)
Goéré/2015/ France ^[11]	90	52	32	5.8	29.5	35	NR	NR	NR	60 (47-74)
Huang/2014/ China ^[112]	63.6	16	NR	0	28.6	13.7	10.0-16.5	NR	NR	41.5 (11.5-70.9)
HIPEC single arm studies										
Cao/2009/ Australia ^[11]	83.6	51.4	32.1	NR	NR	37.0	1-72	NR	NR	19 (1-72)
Ceelen/2014/ Belgium ^[6]	75 (NNT) 75 (NCA) 96 (NCB)	39 (NNT) 30 (NCA) 71 (NCB)	25 (NNT) 13 (NCA)	NR	NR	25 (NNT) 22 (NCA) 39 (NCB) 30 (AC) 22 (NAC)	19.1-30.9 (NNT) 12.9-31.1 (NCA) 17.6-60.4 (NCB) 20.7-39.3 (AC) 14.2-29.8 (NAC)	NR	NR	18
Elias/2014/ France ^[53]	91.4	54	36.5	4.2	17	41	NR	NR	NR	62.4 (55.6-77.6)
Frøysnes/2016/ Norway ^[114]	93	65	36	0	15.5	47	42-52	NR	10 (7-12)	45 (35-55)
Hamilton/2011/ Canada ^[115]	79	38	34	NR	NR	27	0-87	NR	9 (0-87) 3-yr 34% 5-yr 26%	28 (0-119) (all)
Hompes/2012/ Belgium ^[116]	97.9	84	NA	0	52.1	NA	NA	NR	19.8 (RFS)	22.7 (3.2-55.7)
Passot/2016/ France ^[11]	83	51	31	NR	30	36	NR	NR	11	NR
Prada-Villaverde/2014/ Spain ^[118]	85	45	35	NR	NR	31.4	NR	NR	NR	NR
Quenet/2011/ France ^[119]	92	36	44	4.1	47.2	41	32-60	NR	10.9 3-yr 15%	30.3 (2-88)

Adapted from Huang *et al*^[112]. SR: Survival rate; OS: Overall survival; PFS: Progression-free survival; RFS: Recurrence-free survival; DFS: Disease-free survival; NA: Not achieved; NR: Not reported; NNT: Non-neoadjuvant therapy; NCA: Neoadjuvant chemotherapy alone; NCB: Neoadjuvant chemotherapy + bevacizumab; AC: Adjuvant chemotherapy; NAC: Non-adjuvant chemotherapy; CI: Confidence interval.

chemotherapy regimens still require further study.

IMPORTANCE AND RECOMMENDATION FOR THE FOLLOW-UP

At present, there are no shared guidelines for the ideal duration and intervals for CRC patient follow-up. The NCCN and European Society of Medical Oncology guidelines recommend abdomen and chest CT surveillance every 6 to 12 mo for 3 to 5 years. The American Society of Clinical Oncology (ASCO) and American Cancer Society

recommend CT every 12 mo for 5 years.

Ultrasonography provides no additional advantages for the early detection of CRC recurrence^[85]. Colonoscopy is recommended at approximately 1 year after the resection (or at 3-6 mo if not performed preoperatively because of emergency surgery), then at the third year, and every 5 years thereafter. Additionally, 18FDG-PET/CT was proposed as a complementary tool for prompt detection of asymptomatic recurrence, but consecutive studies have shown additional costs with no particular benefit for resectable disease and, hence, no improvement of overall survival^[86]. Currently, it is only advisable for patients with tumor marker elevation without other evidence of disease or for those in whom recurrences are suspected with normal serum marker levels^[87].

Several studies have focused on the role of an intensive follow-up after curative surgery for CRC, combining imaging resources plus CEA level screening. The global results report an improved rate of recurrence detection that could be treated by intentionally curative iterative surgery^[88]. However, these early findings of metachronous disease do not seem to correspond to better results on overall survival, independent of the stage at diagnosis^[89-92]. No advantage has been observed in the CEA and CT combination, and any strategy has proven a better survival advantage over a symptom-based approach^[93]. Peculiarly, these findings are not consistent with the early treatment of recurrences found in rectal cancer, below the peritoneal reflection, which seem to benefit from a more intensive follow-up in pursuit of better survival^[90].

Despite the limitations and bias reported in these studies, the optimal follow-up regimen for CRC patients of any stage remains controversial, and care should be taken concerning unnecessary radiation exposure of the patients and the cost-effectiveness of overly intense schedules. Notwithstanding, as radical surgery is the only actual curative treatment for colon cancer, intensive surveillance can be justified in high-risk patients, while quality evidence is achieved.

CURRENT AND FUTURE LINES OF RESEARCH

Prophylactic approach to peritoneal metastases from CRC

As mentioned before, knowing the risk factors for peritoneal spread (Table 1) allows proactive strategies for patients with high risk of developing PM to be value to set the benefit of a radical resection of located disease over the morbidity added to a patient without objective tumor spread (for example, in cases of pT4 colon cancer, which can develop peritoneal recurrence at rates of 30%-40%)

Second look surgery and prophylactic HIPEC

Second-look evaluation has always gone together with a close follow-up by CT of the chest, abdomen and pelvis, colonoscopies and CEA level surveillance. Although combined with adjuvant chemotherapy treatment, the results of the different follow-up protocols and guidelines are still heterogeneous, and the optimal management remains controversial.

Some studies have found encouraging survival outcomes for proactive strategies, such as the second-look approach^[94,95], prophylactic resection of target organs for peritoneal implants during the first surgery (omentectomy, appendectomy, hepatic round ligament resection and bilateral adnexectomy)^[96] or prophylactic HIPEC administration in locally advanced tumors without peritoneal carcinomatosis^[97-99].

Several phase III trials are currently ongoing for the evaluation of the influence of prophylactic HIPEC in high-risk patients^[100] (Table 4). For example, the ProphylCHIP trial led by Elias has already reported some preliminary data showing no morbidity increased on patients who received second-look surgery, but no advantages in 3-year disease-free survival or overall survival have been found over classical follow-up^[101]. The initial results from the COLOPEC trial, presented at ASCO 2019, do not show adjuvant HIPEC to improved 18 mo over adjuvant systemic chemotherapy on PM-free survival for high-risk patients^[102].

The role of laparoscopy in the staging and second-look for peritoneal disease has been shown as a useful and feasible tool, even in previously laparotomized patients for restaging. Some experienced centers even use laparoscopy as a routine step for all the elective cytoreductive surgeries to prevent patients from an unnecessary xypho-pubic incision. Recent publications highlight the relevance of wide small bowel involvement over a proper estimation of the PCI to reject CRS^[103], which could enhance the value of the laparoscopic approach in this context. Although the risk factors for peritoneal recurrence are well known and firmly confirmed by numerous publications, there is currently no strong evidence of the benefit of proactive strategies

Table 4 Studies on the ClinicalTrials.gov registry investigating the role of cytoreductive surgery and hyperthermic intraperitoneal chemotherapy on high risk patients for preventing peritoneal metastases from colorectal origin

ClinicalTrials.gov ID	Phase	High risk criteria	Control vs Treatment arms
NCT01226394 ProphylCHIP trial	Phase III	Complete resection of minimal abdominal synchronous metastases or perforated tumors	Surveillance <i>vs</i> second-look laparotomy with HIPEC (intraperitoneal oxaliplatin and intravenous 5-FU) after primary resection
NCT02231086 COLOPEC trial	Phase III	T4, N0-2M0 or perforated colon cancer	Adjuvant systemic therapy only <i>vs</i> adjuvant systemic therapy + HIPEC, without resection of target organs
NCT02974556 PROMENADE trial	Phase III	T3-T4 tumors	Resection of target organs for peritoneal implants, plus HIPEC with oxaliplatin and concomitant <i>i.v.</i> , 5-fluorouracil/leucovorin
NCT02179489	Phase III	T4M0 and complete resection of minimal abdominal synchronous metastases or perforated tumors	Surgery <i>vs</i> surgery and HIPEC with mitomycin C (without preventive excision of target organs)
NCT02965248 APEC trial	Phase II	T4NanyM0 and T3-NanyM0 + mucinous or signet ring cells histology	Adjuvant systemic chemotherapy alone (arm A) <i>vs</i> systemic chemo + HIPEC with raltitrexed (arm B) or oxaliplatin (arm C)
NCT02614534 HIPEC T4	Phase III	Complete resection of T4a, bNanyM0	Surgery <i>vs</i> prophylactic HIPEC with mitomycin plus target organs excision
NCT03413254 COLOPEC-II	Phase III	Complete resection of T4a, bN0-2M0	Routine follow-up (arm A) <i>vs</i> a second exploratory laparoscopy (arm B) and third exploratory laparoscopy (arm C) if the work-up is negative
NCT02974556	Phase III	Complete resection of T3-4NanyM0	Systemic chemotherapy alone <i>vs</i> CRS/HIPEC with oxaliplatin and systemic therapy
NCT02758951	Phase II/III	Complete resection of colorectal tumors with $\leq 50\%$ of signet ring cells.	Upfront CRS-HIPEC alone <i>vs</i> pre/post perioperative systemic chemotherapy and CRS-HIPEC
NCT02830139	Phase II	Complete resection of T3-4NanyM0	CRS + systemic chemotherapy <i>vs</i> CRS + HIPEC with paclitaxel + 5-FU + postoperative chemotherapy

CRS: Complete cytoreductive surgery; HIPEC: Hyperthermic intraperitoneal chemotherapy.

versus adequate surveillance for high-risk patients. We still await the results of the process phase III trials to shed light on the optimal management.

Pressurized intraperitoneal aerosol chemotherapy

Better survival results have been tried to achieve by boosting the cytotoxic effect of chemotherapy agents of HIPEC. A novel example of this effort is the development of a new drug delivery system known as pressurized intraperitoneal aerosol chemotherapy (PIPAC). In the context of experimental trials, this procedure is being used for patients with peritoneal region as only place of metastases from different cancer origins, but without indication for cytoreductive plus HIPEC surgery as no complete resection can be performed.

This laparoscopic and iterative procedure nebulizes the cytotoxic agents into the expanded peritoneal cavity and maintains a steady pressure with the aim of increasing drug penetration into the tissues with a more homogeneous distribution than with liquid chemotherapy. Theoretically, as the pressure decreases venous blood outflow, drugs would spend more time in contact with the tissues, so higher drug concentrations could be reached with lower doses (therefore, this would minimize systemic toxicity).

In recent years, its feasibility and safety have been extensively reported, and its efficacy for a histological response and survival benefits has been described by several teams^[104]. Referring to CRC, there is still little experience but encouraging results published^[105], and currently, 4 prospective clinical trials are ongoing evaluating the oncological efficacy of PIPAC for selected patients who currently would be considered for palliative care (Table 5). Pursuing an optimal macroscopic cytoreduction for the best guarantee of prognosis, some trials have proposed the use of

intraoperative imaging techniques that can guide the detection of malignant lesions using tumortargeted fluorescence traces^[106].

Some other trials have attempted to rescue high PCI patients for an eventual CRS surgery by using a combination of intraperitoneal plus systemic chemotherapy regimens. The aim of this bidirectional chemotherapy is to reach peritoneal implants not only from the peritoneal cavity but also from subperitoneal blood vessels^[107,108].

CONCLUSION

CRS plus HIPEC combined with systemic modern chemotherapy is feasible for the management for PM of CR origin most widely accepted by experts, as accumulative evidence suggests that it improves recurrences as well as overall and peritoneal disease-free survival. Because of the lack of randomized clinical trials and the conflicting data on clinical efficacy, this approach remains controversial. Optimization of preoperative imaging assessment of tumor burden and molecular biology categorization are two promising approaches for better individualized treatment. In referral centers, the morbidity and mortality associated with this procedure do not seem to be higher than other major abdominal surgeries. Iterative CRS for local recurrences has proven to improve overall survival without adding a significant morbidity. It is paramount that patients with peritoneal carcinomatosis continue to be referred to experienced centers that can offer a multidisciplinary, tailored evaluation and high-quality surgery. As complete CRS has confidently proven to improve patient survival, future strategy targets are focused on assessing the real role of modern systemic chemotherapy and HIPEC for the treatment and prevention of PM in high-risk patients.

Table 5 Studies on the ClinicalTrials.gov registry investigating the role of pressurized intraperitoneal aerosol chemotherapy

Number Clinical Trial	Experimental therapy	Malignant origin	Cytotoxic drugs	Primary outcomes
NCT03280511 The PIPAC-OPC3 CC Trial	Exploratory Laparoscopy + biopsies + 1 st PIPAC 2 mo after radical primary resection+/-adjuvant chemo + 2 nd PIPAC 5 wk later	High risk colorectal cancer patients	Oxaliplatin (92 mg/m ²)	Peritoneal recurrence
NCT03246321 CRC-PIPAC	ePIPAC + leucovorin + 5-FU iv	Colorectal / appendiceal carcinomas	Oxaliplatin (92 mg/m ²)	Major toxicity
NCT03210298	PIPAC/PITAC	Peritoneal metastasis of various origins	Depends on tumor origin	Overall survival
NCT02604784 PI-CaP	PIPAC fixed repeated dose vs PIPAC increasing single dose	Gastric, colorectal and ovarian cancers or primary peritoneal tumors	Cisplatin + doxorubicin or oxaliplatin (92 mg/m ²)	Overall response rate

PIPAC: Pressurized intraperitoneal aerosol chemotherapy; ePIPAC: Electrostatic pressurised intraperitoneal aerosol chemotherapy.

REFERENCES

- 1 **Finlay A**, Johanna B. Clinical presentation, diagnosis, and staging of colorectal cancer. Waltham, Mass.: UpToDate, 2018. Available from: <https://www.uptodate.com/contents/clinical-presentation-diagnosis-and-staging-of-colorectal-cancer>
- 2 **Massalou D**, Benizri E, Chevallier A, Duranton-Tanneur V, Pedetour F, Benchimol D, Béréder JM. Peritoneal carcinomatosis of colorectal cancer: Novel clinical and molecular outcomes. *Am J Surg* 2017; **213**: 377-387 [PMID: 27816197 DOI: 10.1016/j.amjsurg.2016.03.008]
- 3 **Sugarbaker PH**. Colorectal cancer: Prevention and management of metastatic disease. *Biomed Res Int* 2014; **2014**: 782890 [PMID: 24783222 DOI: 10.1155/2014/782890]
- 4 **Koppe MJ**, Boerman OC, Oyen WJ, Bleichrodt RP. Peritoneal carcinomatosis of colorectal origin: Incidence and current treatment strategies. *Ann Surg* 2006; **243**: 212-222 [PMID: 16432354 DOI: 10.1097/01.sla.0000197702.46394.16]
- 5 **Aditi B**. (2018) Management of Peritoneal Metastases- Cytoreductive Surgery, HIPEC and Beyond. Singapore: Springer. [DOI: 10.1007/978-981-10-7053-2]
- 6 **Pawlik TM**, Raut CP, Rodriguez-Bigas MA. Colorectal carcinogenesis: MSI-H versus MSI-L. *Dis Markers* 2004; **20**: 199-206 [PMID: 15528785 DOI: 10.1155/2004/368680]
- 7 **Klingbiel D**, Saridaki Z, Roth AD, Bosman FT, Delorenzi M, Tejpar S. Prognosis of stage II and III colon cancer treated with adjuvant 5-fluorouracil or FOLFIRI in relation to microsatellite status: Results of the PETACC-3 trial. *Ann Oncol* 2015; **26**: 126-132 [PMID: 25361982 DOI: 10.1093/annonc/mdl499]
- 8 **Kim CG**, Ahn JB, Jung M, Beom SH, Kim C, Kim JH, Heo SJ, Park HS, Kim JH, Kim NK, Min BS, Kim H, Koom WS, Shin SJ. Effects of microsatellite instability on recurrence patterns and outcomes in colorectal cancers. *Br J Cancer* 2016; **115**: 25-33 [PMID: 27228287 DOI: 10.1038/bjc.2016.161]
- 9 **Fujiyoshi K**, Yamamoto G, Takenoya T, Takahashi A, Arai Y, Yamada M, Kakuta M, Yamaguchi K, Akagi Y, Nishimura Y, Sakamoto H, Akagi K. Metastatic Pattern of Stage IV Colorectal Cancer with High-Frequency Microsatellite Instability as a Prognostic Factor. *Anticancer Res* 2017; **37**: 239-247 [PMID: 28011498 DOI: 10.21873/anticancer.11313]
- 10 **Safaei Ardekani G**, Jafarnejad SM, Tan L, Saeedi A, Li G. The prognostic value of BRAF mutation in colorectal cancer and melanoma: A systematic review and meta-analysis. *PLoS One* 2012; **7**: e47054 [PMID: 23056577 DOI: 10.1371/journal.pone.0047054]
- 11 **Testa U**, Pelosi E, Castelli G. Colorectal cancer: Genetic abnormalities, tumor progression, tumor heterogeneity, clonal evolution and tumor-initiating cells. *Med Sci (Basel)* 2018; **6**: pii: E31 [PMID: 29652830 DOI: 10.3390/medsci6020031]
- 12 **Prasanna T**, Karapetis CS, Roder D, Tie J, Padbury R, Price T, Wong R, Shapiro J, Nott L, Lee M, Chua YJ, Craft P, Piantadosi C, Sorich M, Gibbs P, Yip D. The survival outcome of patients with metastatic colorectal cancer based on the site of metastases and the impact of molecular markers and site of primary cancer on metastatic pattern. *Acta Oncol* 2018; **57**: 1438-1444 [PMID: 30035653 DOI: 10.1080/0284186X.2018.1487581]
- 13 **Chen KH**, Lin YL, Liao JY, Tsai JH, Tseng LH, Lin LI, Liang JT, Lin BR, Hung JS, Chang YL, Yeh KH, Cheng AL. BRAF mutation may have different prognostic implications in early- and late-stage colorectal cancer. *Med Oncol* 2016; **33**: 39 [PMID: 27034263 DOI: 10.1007/s12032-016-0756-6]
- 14 **Jones JC**, Renfro LA, Al-Shamsi HO, Schrock AB, Rankin A, Zhang BY, Kasi PM, Voss JS, Leal AD, Sun J, Ross J, Ali SM, Hubbard JM, Kipp BR, McWilliams RR, Kopetz S, Wolff RA, Grothey A. Non-V600 BRAF Mutations Define a Clinically Distinct Molecular Subtype of Metastatic Colorectal Cancer. *J Clin Oncol* 2017; **35**: 2624-2630 [PMID: 28486044 DOI: 10.1200/JCO.2016.71.4394]
- 15 **Imamura Y**, Morikawa T, Liao X, Lochhead P, Kuchiba A, Yamauchi M, Qian ZR, Nishihara R, Meyerhardt JA, Haigis KM, Fuchs CS, Ogino S. Specific mutations in KRAS codons 12 and 13, and patient prognosis in 1075 BRAF wild-type colorectal cancers. *Clin Cancer Res* 2012; **18**: 4753-4763 [PMID: 22753589 DOI: 10.1158/1078-0432.CCR-11-3210]
- 16 **Schneider MA**, Eden J, Pache B, Laminger F, Lopez-Lopez V, Steffen T, Hübner M, Kober F, Roka S, Campos PC, Roth L, Gupta A, Siebenhüner A, Kepenekian V, Passot G, Gertsch P, Glehen O, Lehmann K. Mutations of RAS/RAF Proto-oncogenes Impair Survival After Cytoreductive Surgery and HIPEC for Peritoneal Metastasis of Colorectal Origin. *Ann Surg* 2018; **268**: 845-853 [PMID: 30303876 DOI: 10.1097/SLA.0000000000002899]
- 17 **Shelygin YA**, Pospekhova NI, Shubin VP, Kashnikov VN, Frolov SA, Sushkov OI, Achkasov SI,

- Tsukanov AS. Epithelial-mesenchymal transition and somatic alteration in colorectal cancer with and without peritoneal carcinomatosis. *Biomed Res Int* 2014; **2014**: 629496 [PMID: [25157365](#) DOI: [10.1155/2014/629496](#)]
- 18 **van Santvoort HC**, Braam HJ, Spekrijse KR, Koning NR, de Bruin PC, de Vries Reilingh TS, Boerma D, Smits AB, Wiezer MJ, van Ramshorst B. Peritoneal carcinomatosis in t4 colorectal cancer: Occurrence and risk factors. *Ann Surg Oncol* 2014; **21**: 1686-1691 [PMID: [24398543](#) DOI: [10.1245/s10434-013-3461-0](#)]
- 19 **van Gestel YR**, Thomassen I, Lemmens VE, Puijth JF, van Herk-Sukel MP, Rutten HJ, Creemers GJ, de Hingh IH. Metachronous peritoneal carcinomatosis after curative treatment of colorectal cancer. *Eur J Surg Oncol* 2014; **40**: 963-969 [PMID: [24183168](#) DOI: [10.1016/j.ejso.2013.10.001](#)]
- 20 **Quere P**, Facy O, Manfredi S, Jooste V, Faivre J, Lepage C, Bouvier AM. Epidemiology, Management, and Survival of Peritoneal Carcinomatosis from Colorectal Cancer: A Population-Based Study. *Dis Colon Rectum* 2015; **58**: 743-752 [PMID: [26163953](#) DOI: [10.1097/DCR.0000000000000412](#)]
- 21 **Segelman J**, Granath F, Holm T, Machado M, Mahteme H, Martling A. Incidence, prevalence and risk factors for peritoneal carcinomatosis from colorectal cancer. *Br J Surg* 2012; **99**: 699-705 [PMID: [22287157](#) DOI: [10.1002/bjs.8679](#)]
- 22 **Honoré C**, Goéré D, Souadka A, Dumont F, Elias D. Definition of patients presenting a high risk of developing peritoneal carcinomatosis after curative surgery for colorectal cancer: A systematic review. *Ann Surg Oncol* 2013; **20**: 183-192 [PMID: [23090572](#) DOI: [10.1245/s10434-012-2473-5](#)]
- 23 **Gelli M**, Huguenin JF, Cerebelli C, Benhaim L, Honoré C, Elias D, Goéré D. Strategies to prevent peritoneal carcinomatosis arising from colorectal cancer. *Future Oncol* 2017; **13**: 907-918 [PMID: [28052691](#) DOI: [10.2217/fon-2016-0389](#)]
- 24 **Libérale G**, Van Den Eynde M, Hendlisz A, El Nakadi I. Recommendations for general surgeons facing incidental peritoneal carcinomatosis of colorectal origin. *Eur J Surg Oncol* 2008; **34**: 725-726 [PMID: [18313880](#) DOI: [10.1016/j.ejso.2008.01.021](#)]
- 25 **Franko J**, Shi Q, Meyers JP, Maughan TS, Adams RA, Seymour MT, Saltz L, Punt CJA, Koopman M, Tournigand C, Tebbutt NC, Diaz-Rubio E, Souglakos J, Falcone A, Chibaudel B, Heinemann V, Moen J, De Gramont A, Sargent DJ, Grothey A; Analysis and Research in Cancers of the Digestive System (ARCAD) Group. Prognosis of patients with peritoneal metastatic colorectal cancer given systemic therapy: An analysis of individual patient data from prospective randomised trials from the Analysis and Research in Cancers of the Digestive System (ARCAD) database. *Lancet Oncol* 2016; **17**: 1709-1719 [PMID: [27743922](#) DOI: [10.1016/S1470-2045\(16\)30500-9](#)]
- 26 **Sadeghi B**, Arvieux C, Glehen O, Beaujard AC, Rivoire M, Baulieux J, Fontaumar E, Brachet A, Caillot JL, Faure JL, Porcheron J, Peix JL, François Y, Vignal J, Gilly FN. Peritoneal carcinomatosis from non-gynecologic malignancies: Results of the EVOCAPE 1 multicentric prospective study. *Cancer* 2000; **88**: 358-363 [PMID: [10640968](#) DOI: [10.1002/\(SICI\)1097-0142\(20000115\)88:2<358::AID-CNCR16>3.0.CO;2-O](#)]
- 27 **Krouse RS**, Nelson RA, Farrell BR, Grube B, Juarez G, Wagman LD, Chu DZ. Surgical palliation at a cancer center: Incidence and outcomes. *Arch Surg* 2001; **136**: 773-778 [PMID: [11448388](#) DOI: [10.1001/archsurg.136.7.773](#)]
- 28 **Klaver YL**, Simkens LH, Lemmens VE, Koopman M, Teerenstra S, Bleichrodt RP, de Hingh IH, Punt CJ. Outcomes of colorectal cancer patients with peritoneal carcinomatosis treated with chemotherapy with and without targeted therapy. *Eur J Surg Oncol* 2012; **38**: 617-623 [PMID: [22572106](#) DOI: [10.1016/j.ejso.2012.03.008](#)]
- 29 **Arjona-Sánchez A**, Medina-Fernández FJ, Muñoz-Casares FC, Casado-Adam A, Sánchez-Hidalgo JM, Rufián-Peña S. Peritoneal metastases of colorectal origin treated by cytoreduction and HIPEC: An overview. *World J Gastrointest Oncol* 2014; **6**: 407-412 [PMID: [25320657](#) DOI: [10.4251/wjgo.v6.i10.407](#)]
- 30 **Sugarbaker PH**. Patient selection and treatment of peritoneal carcinomatosis from colorectal and appendiceal cancer. *World J Surg* 1995; **19**: 235-240 [PMID: [7754629](#) DOI: [10.1007/bf00308632](#)]
- 31 **Elias D**, Lefevre JH, Chevalier J, Brouquet A, Marchal F, Classe JM, Ferron G, Guilloit JM, Meeus P, Goéré D, Bonastre J. Complete cytoreductive surgery plus intraperitoneal chemohyperthermia with oxaliplatin for peritoneal carcinomatosis of colorectal origin. *J Clin Oncol* 2009; **27**: 681-685 [PMID: [19103728](#) DOI: [10.1200/JCO.2008.19.7160](#)]
- 32 **NCCN**. NCCN guidelines: colon cancer. 2018. Available from: http://www.nccn.org/professionals/physician_gls/pdf/colon.pdf
- 33 **Shida D**, Yoshida T, Tanabe T, Tsukamoto S, Ochiai H, Kanemitsu Y. Prognostic Impact of R0 Resection and Targeted Therapy for Colorectal Cancer with Synchronous Peritoneal Metastasis. *Ann Surg Oncol* 2018; **25**: 1646-1653 [PMID: [29572704](#) DOI: [10.1245/s10434-018-6436-3](#)]
- 34 **Verwaal VJ**, Bruin S, Boot H, van Slooten G, van Tinteren H. 8-year follow-up of randomized trial: Cytoreduction and hyperthermic intraperitoneal chemotherapy versus systemic chemotherapy in patients with peritoneal carcinomatosis of colorectal cancer. *Ann Surg Oncol* 2008; **15**: 2426-2432 [PMID: [18521686](#) DOI: [10.1245/s10434-008-9966-2](#)]
- 35 **Klaver CE**, Groenen H, Morton DG, Laurberg S, Bemelman WA, Tanis PJ; research committee of the European Society of Coloproctology. Recommendations and consensus on the treatment of peritoneal metastases of colorectal origin: A systematic review of national and international guidelines. *Colorectal Dis* 2017; **19**: 224-236 [PMID: [28008728](#) DOI: [10.1111/codi.13593](#)]
- 36 **Faron M**, Macovei R, Goéré D, Honoré C, Benhaim L, Elias D. Linear Relationship of Peritoneal Cancer Index and Survival in Patients with Peritoneal Metastases from Colorectal Cancer. *Ann Surg Oncol* 2016; **23**: 114-119 [PMID: [26014158](#) DOI: [10.1245/s10434-015-4627-8](#)]
- 37 **Elias D**, Gilly F, Boutitie F, Quenet F, Bereder JM, Mansvelt B, Lorimier G, Dubé P, Glehen O. Peritoneal colorectal carcinomatosis treated with surgery and perioperative intraperitoneal chemotherapy: Retrospective analysis of 523 patients from a multicentric French study. *J Clin Oncol* 2010; **28**: 63-68 [PMID: [19917863](#) DOI: [10.1200/JCO.2009.23.9285](#)]
- 38 **Ng JL**, Ong WS, Chia CS, Tan GH, Soo KC, Teo MC. Prognostic Relevance of the Peritoneal Surface Disease Severity Score Compared to the Peritoneal Cancer Index for Colorectal Peritoneal Carcinomatosis. *Int J Surg Oncol* 2016; **2016**: 2495131 [PMID: [27006828](#) DOI: [10.1155/2016/2495131](#)]
- 39 **Esquivel J**, Sticca R, Sugarbaker P, Levine E, Yan TD, Alexander R, Baratti D, Bartlett D, Barone R, Barrios P, Bieligg S, Bretcha-Boix P, Chang CK, Chu F, Chu Q, Daniel S, de Bree E, Deraco M, Dominguez-Parra L, Elias D, Flynn R, Foster J, Garofalo A, Gilly FN, Glehen O, Gomez-Portilla A, Gonzalez-Bayon L, Gonzalez-Moreno S, Goodman M, Gushchin V, Hanna N, Hartmann J, Harrison L,

- Hoefler R, Kane J, Kecmanovic D, Kelley S, Kuhn J, Lamont J, Lange J, Li B, Loggie B, Mahteme H, Mann G, Martin R, Misih RA, Moran B, Morris D, Onate-Ocana L, Petrelli N, Philippe G, Pingpank J, Pitroff A, Piso P, Quinones M, Riley L, Rutstein L, Saha S, Alrawi S, Sardi A, Schneebaum S, Shen P, Shibata D, Spellman J, Stojadinovic A, Stewart J, Torres-Melero J, Tuttle T, Verwaal V, Villar J, Wilkinson N, Younan R, Zeh H, Zoetmulder F, Sebbag G; Society of Surgical Oncology Annual Meeting. Cytoreductive surgery and hyperthermic intraperitoneal chemotherapy in the management of peritoneal surface malignancies of colonic origin: A consensus statement. Society of Surgical Oncology. *Ann Surg Oncol* 2007; **14**: 128-133 [PMID: 17072675 DOI: 10.1245/s10434-006-9185-7]
- 40 Mo S, Cai G. Multidisciplinary Treatment for Colorectal Peritoneal Metastases: Review of the Literature. *Gastroenterol Res Pract* 2016; **2016**: 1516259 [PMID: 28105045 DOI: 10.1155/2016/1516259]
- 41 Kim DH, Moreno CC, Pickhardt PJ. Computed Tomography Colonography: Pearls and Pitfalls. *Radiol Clin North Am* 2018; **56**: 719-735 [PMID: 30119770 DOI: 10.1016/j.rcl.2018.05.004]
- 42 Torkzad MR, Casta N, Bergman A, Ahlström H, Pahlman L, Mahteme H. Comparison between MRI and CT in prediction of peritoneal carcinomatosis index (PCI) in patients undergoing cytoreductive surgery in relation to the experience of the radiologist. *J Surg Oncol* 2015; **111**: 746-751 [PMID: 25580825 DOI: 10.1002/jso.23878]
- 43 Esquivel J, Chua TC, Stojadinovic A, Melero JT, Levine EA, Gutman M, Howard R, Piso P, Nissán A, Gomez-Portilla A, Gonzalez-Bayon L, Gonzalez-Moreno S, Shen P, Stewart JH, Sugarbaker PH, Barone RM, Hoefler R, Morris DL, Sardi A, Sticca RP. Accuracy and clinical relevance of computed tomography scan interpretation of peritoneal cancer index in colorectal cancer peritoneal carcinomatosis: A multi-institutional study. *J Surg Oncol* 2010; **102**: 565-570 [PMID: 20976729 DOI: 10.1002/jso.21601]
- 44 Low RN, Barone RM. Imaging for Peritoneal Metastases. *Surg Oncol Clin N Am* 2018; **27**: 425-442 [PMID: 29935681 DOI: 10.1016/j.soc.2018.02.002]
- 45 Dohan A, Hoeffel C, Soyer P, Jannot AS, Valette PJ, Thiviolet A, Passot G, Glehen O, Rousset P. Evaluation of the peritoneal carcinomatosis index with CT and MRI. *Br J Surg* 2017; **104**: 1244-1249 [PMID: 28376270 DOI: 10.1002/bjs.10527]
- 46 Sugarbaker PH, Sardi A, Brown G, Dromain C, Rousset P, Jelinek JS. Concerning CT features used to select patients for treatment of peritoneal metastases, a pictorial essay. *Int J Hyperthermia* 2017; **33**: 497-504 [PMID: 28540832 DOI: 10.1080/02656736.2017.1317368]
- 47 Kim SJ, Lee SW. Diagnostic accuracy of ¹⁸F-FDG PET/CT for detection of peritoneal carcinomatosis; a systematic review and meta-analysis. *Br J Radiol* 2018; **91**: 20170519 [PMID: 29099613 DOI: 10.1259/bjr.20170519]
- 48 Baumgartner JM, Tobin L, Heavey SF, Kelly KJ, Roeland EJ, Lowy AM. Predictors of progression in high-grade appendiceal or colorectal peritoneal carcinomatosis after cytoreductive surgery and hyperthermic intraperitoneal chemotherapy. *Ann Surg Oncol* 2015; **22**: 1716-1721 [PMID: 25145504 DOI: 10.1245/s10434-014-3985-y]
- 49 Kuijpers AM, Mehta AM, Boot H, van Leerdam ME, Hauptmann M, Aalbers AG, Verwaal VJ. Perioperative systemic chemotherapy in peritoneal carcinomatosis of lymph node positive colorectal cancer treated with cytoreductive surgery and hyperthermic intraperitoneal chemotherapy. *Ann Oncol* 2014; **25**: 864-869 [PMID: 24667719 DOI: 10.1093/annonc/mdu031]
- 50 El-Nakeep S, Rashad N, Oweira H, Schmidt J, Helbling D, Giryes A, Petrausch U, Mehrabi A, Decker M, Abdel-Rahman O. Intraperitoneal chemotherapy and cytoreductive surgery for peritoneal metastases coupled with curative treatment of colorectal liver metastases: An updated systematic review. *Expert Rev Gastroenterol Hepatol* 2017; **11**: 249-258 [PMID: 28099818 DOI: 10.1080/17474124.2017.1284586]
- 51 Elias D, Benizri E, Pocard M, Ducreux M, Boige V, Lasser P. Treatment of synchronous peritoneal carcinomatosis and liver metastases from colorectal cancer. *Eur J Surg Oncol* 2006; **32**: 632-636 [PMID: 16621428 DOI: 10.1016/j.ejso.2006.03.013]
- 52 Bushati M, Rovers KP, Sommariva A, Sugarbaker PH, Morris DL, Yonemura Y, Quadros CA, Somashekhar SP, Ceelen W, Dubé P, Li Y, Verwaal VJ, Glehen O, Piso P, Spiliotis J, Teo MCC, González-Moreno S, Cashin PH, Lehmann K, Deraco M, Moran B, de Hingh IHJT. The current practice of cytoreductive surgery and HIPEC for colorectal peritoneal metastases: Results of a worldwide web-based survey of the Peritoneal Surface Oncology Group International (PSOGI). *Eur J Surg Oncol* 2018; **44**: 1942-1948 [PMID: 30075978 DOI: 10.1016/j.ejso.2018.07.003]
- 53 Elias D, Faron M, Goéré D, Dumont F, Honoré C, Boige V, Malka D, Ducreux M. A simple tumor load-based nomogram for surgery in patients with colorectal liver and peritoneal metastases. *Ann Surg Oncol* 2014; **21**: 2052-2058 [PMID: 24499829 DOI: 10.1245/s10434-014-3506-z]
- 54 Kwakman R, Schrama AM, van Olmen JP, Otten RH, de Lange-de Klerk ES, de Cuba EM, Kazemier G, Te Velde EA. Clinicopathological Parameters in Patient Selection for Cytoreductive Surgery and Hyperthermic Intraperitoneal Chemotherapy for Colorectal Cancer Metastases: A Meta-analysis. *Ann Surg* 2016; **263**: 1102-1111 [PMID: 26756756 DOI: 10.1097/SLA.0000000000001593]
- 55 Randle RW, Doud AN, Levine EA, Clark CJ, Swett KR, Shen P, Stewart JH, Votanopoulos KI. Peritoneal surface disease with synchronous hepatic involvement treated with Cytoreductive Surgery (CRS) and hyperthermic intraperitoneal chemotherapy (HIPEC). *Ann Surg Oncol* 2015; **22**: 1634-1638 [PMID: 25120252 DOI: 10.1245/s10434-014-3987-9]
- 56 Waite K, Youssef H. The Role of Neoadjuvant and Adjuvant Systemic Chemotherapy with Cytoreductive Surgery and Heated Intraperitoneal Chemotherapy for Colorectal Peritoneal Metastases: A Systematic Review. *Ann Surg Oncol* 2017; **24**: 705-720 [PMID: 28058545 DOI: 10.1245/s10434-016-5712-3]
- 57 Gilly FN; International Registry of Colorectal Carcinomatosis. Phase II studies: International registry of colorectal carcinomatosis. *Eur J Surg Oncol* 2006; **32**: 648-654 [PMID: 16678380 DOI: 10.1016/j.ejso.2006.03.030]
- 58 Glehen O, Kwiatkowski F, Sugarbaker PH, Elias D, Levine EA, De Simone M, Barone R, Yonemura Y, Cavaliere F, Quenet F, Gutman M, Tentes AA, Lorimier G, Bernard JL, Bereder JM, Porcheron J, Gomez-Portilla A, Shen P, Deraco M, Rat P. Cytoreductive surgery combined with perioperative intraperitoneal chemotherapy for the management of peritoneal carcinomatosis from colorectal cancer: A multi-institutional study. *J Clin Oncol* 2004; **22**: 3284-3292 [PMID: 15310771 DOI: 10.1200/JCO.2004.10.012]
- 59 Hompes D, Aalbers A, Boot H, van Velthuisen ML, Vogel W, Prevoo W, van Tinteren H, Verwaal V. A prospective pilot study to assess neoadjuvant chemotherapy for unresectable peritoneal carcinomatosis from colorectal cancer. *Colorectal Dis* 2014; **16**: O264-O272 [PMID: 24433532 DOI: 10.1111/codi.12560]
- 60 Eveno C, Passot G, Goéré D, Soyer P, Gayat E, Glehen O, Elias D, Pocard M. Bevacizumab doubles the early postoperative complication rate after cytoreductive surgery with hyperthermic intraperitoneal

- chemotherapy (HIPEC) for peritoneal carcinomatosis of colorectal origin. *Ann Surg Oncol* 2014; **21**: 1792-1800 [PMID: 24337648 DOI: 10.1245/s10434-013-3442-3]
- 61 **Ceelen W**, Van Nieuwenhove Y, Putte DV, Pattyn P. Neoadjuvant chemotherapy with bevacizumab may improve outcome after cytoreduction and hyperthermic intraperitoneal chemoperfusion (HIPEC) for colorectal carcinomatosis. *Ann Surg Oncol* 2014; **21**: 3023-3028 [PMID: 24756812 DOI: 10.1245/s10434-014-3713-7]
- 62 **Rouzier R**, Gouy S, Selle F, Lambaudie E, Floquet A, Fourchette V, Pomel C, Colombo PE, Kalbacher E, Martin-Francoise S, Fauvet R, Follana P, Lesoin A, Lecuru F, Ghazi Y, Dupin J, Chereau E, Zohar S, Cottu P, Joly F. Efficacy and safety of bevacizumab-containing neoadjuvant therapy followed by interval debulking surgery in advanced ovarian cancer: Results from the ANTHALYA trial. *Eur J Cancer* 2017; **70**: 133-142 [PMID: 27914243 DOI: 10.1016/j.ejca.2016.09.036]
- 63 **Bear HD**, Tang G, Rastogi P, Geyer CE, Zoon CK, Kidwell KM, Robidoux A, Baez-Diaz L, Brufsky AM, Mehta RS, Fehrenbacher L, Young JA, Senecal FM, Gaur R, Margolese RG, Adams PT, Gross HM, Costantino JP, Paik S, Swain SM, Mamounas EP, Wolmark N. The Effect on Surgical Complications of Bevacizumab Added to Neoadjuvant Chemotherapy for Breast Cancer: NRG Oncology/NSABP Protocol B-40. *Ann Surg Oncol* 2017; **24**: 1853-1860 [PMID: 27864694 DOI: 10.1245/s10434-016-5662-9]
- 64 **Chua TC**, Morris DL, Saxena A, Esquivel J, Liauw W, Doerfer J, Germer CT, Kerscher AG, Pelz JO. Influence of modern systemic therapies as adjunct to cytoreduction and perioperative intraperitoneal chemotherapy for patients with colorectal peritoneal carcinomatosis: A multicenter study. *Ann Surg Oncol* 2011; **18**: 1560-1567 [PMID: 21203904 DOI: 10.1245/s10434-010-1522-1]
- 65 **Wu W**, Yan S, Liao X, Xiao H, Fu Z, Chen L, Mou J, Yu H, Zhao L, Liu X. Curative versus palliative treatments for colorectal cancer with peritoneal carcinomatosis: A systematic review and meta-analysis. *Oncotarget* 2017; **8**: 113202-113212 [PMID: 29348899 DOI: 10.18632/oncotarget.21912]
- 66 **Glimelius B**, Cavalli-Björkman N. Metastatic colorectal cancer: Current treatment and future options for improved survival. Medical approach--present status. *Scand J Gastroenterol* 2012; **47**: 296-314 [PMID: 22242568 DOI: 10.3109/00365521.2012.640828]
- 67 **Xu R**, Xu C, Liu C, Cui C, Zhu J. Efficacy and safety of bevacizumab-based combination therapy for treatment of patients with metastatic colorectal cancer. *Onco Targets Ther* 2018; **11**: 8605-8621 [PMID: 30584320 DOI: 10.2147/OTT.S171724]
- 68 **Shi Q**, Sobrero A, Shields A, Yoshino T, Paul J, Taieb J, Souglakos I, Kerr R, Labianca R, Meyerhardt J, Bonnetain F, Watanabe T, Boukovinas I, Renfro L, Grothey A, Niedzwiecki D, Torri V, Andre T, Sargent D, Iveson T. Prospective pooled analysis of six phase III trials investigating duration of adjuvant (adjuv) oxaliplatin-based therapy (3 vs 6 months) for patients (pts) with stage III colon cancer (CC): The IDEA (International Duration Evaluation of Adjuvant chemotherapy) collaboration. *J Clin Oncol* 2017; **35** [DOI: 10.1200/JCO.2017.35.18_suppl.LBA1]
- 69 **Cashin PH**, Mahteme H, Spång N, Syk I, Frödin JE, Torkzad M, Glimelius B, Graf W. Cytoreductive surgery and intraperitoneal chemotherapy versus systemic chemotherapy for colorectal peritoneal metastases: A randomised trial. *Eur J Cancer* 2016; **53**: 155-162 [PMID: 26751236 DOI: 10.1016/j.ejca.2015.09.017]
- 70 **Piso P**, Nedelcut SD, Rau B, Königsrainer A, Glockzin G, Ströhllein MA, Hörbelt R, Pelz J. Morbidity and Mortality Following Cytoreductive Surgery and Hyperthermic Intraperitoneal Chemotherapy: Data from the DGAV StuDoQ Registry with 2149 Consecutive Patients. *Ann Surg Oncol* 2019; **26**: 148-154 [PMID: 30456672 DOI: 10.1245/s10434-018-6992-6]
- 71 **Newton AD**, Bartlett EK, Karakousis GC. Cytoreductive surgery and hyperthermic intraperitoneal chemotherapy: A review of factors contributing to morbidity and mortality. *J Gastrointest Oncol* 2016; **7**: 99-111 [PMID: 26941988 DOI: 10.3978/j.issn.2078-6891.2015.100]
- 72 **Arjona-Sanchez A**, Esquivel J, Glehen O, Passot G, Turaga KK, Labow D, Rufian-Peña S, Morales R, van der Speeten K. A minimally invasive approach for peritonectomy procedures and hyperthermic intraperitoneal chemotherapy (HIPEC) in limited peritoneal carcinomatosis: The American Society of Peritoneal Surface Malignancies (ASPSM) multi-institution analysis. *Surg Endosc* 2019; **33**: 854-860 [PMID: 30003349 DOI: 10.1007/s00464-018-6352-4]
- 73 **Salti GI**, Naffouje SA. Feasibility of hand-assisted laparoscopic cytoreductive surgery and hyperthermic intraperitoneal chemotherapy for peritoneal surface malignancy. *Surg Endosc* 2019; **33**: 52-57 [PMID: 29926165 DOI: 10.1007/s00464-018-6265-2]
- 74 **Ha SH**, Park SY, Park JS, Kim HJ, Woo IT, Park IK, Kim JG, Kang BW, Lee SJ, Lee WK, Choi GS. Short-term outcomes after laparoscopic cytoreductive surgery in patients with limited peritoneal metastases from colorectal cancer. *Surgery* 2019; **165**: 775-781 [PMID: 30467037 DOI: 10.1016/j.surg.2018.09.017]
- 75 **Goéré D**, Malka D, Tzanis D, Gava V, Boige V, Eveno C, Maggiori L, Dumont F, Ducreux M, Elias D. Is there a possibility of a cure in patients with colorectal peritoneal carcinomatosis amenable to complete cytoreductive surgery and intraperitoneal chemotherapy? *Ann Surg* 2013; **257**: 1065-1071 [PMID: 23299520 DOI: 10.1097/SLA.0b013e31827e9289]
- 76 **Quenet F**, Elias D, Roca L, Goéré D, Ghouti L, Pocard M, Facy O, Arvieux C, Lorimier G, Pezet D, Marchal F, Loi V, Meeus P, De Forges H, Stanbury T, Paineau J, Glehen O; On behalf of Prodige Group. A UNICANCER phase III trial of hyperthermic intra-peritoneal chemotherapy (HIPEC) for colorectal peritoneal carcinomatosis (PC): PRODIGE 7. *Eur J Surg Oncol* 2019; **45**: e17 [DOI: 10.1016/j.ejso.2018.10.086]
- 77 **van Driel WJ**, Koole SN, Sikorska K, Schagen van Leeuwen JH, Schreuder HWR, Hermans RHM, de Hingh IHJT, van der Velden J, Arts HJ, Massuger LFAG, Aalbers AGJ, Verwaal VJ, Kieffer JM, Van de Vijver KK, van Tinteren H, Aaronson NK, Sonke GS. Hyperthermic Intraperitoneal Chemotherapy in Ovarian Cancer. *N Engl J Med* 2018; **378**: 230-240 [PMID: 29342393 DOI: 10.1056/NEJMoa1708618]
- 78 **Huang CQ**, Min Y, Wang SY, Yang XJ, Liu Y, Xiong B, Yonemura Y, Li Y. Cytoreductive surgery plus hyperthermic intraperitoneal chemotherapy improves survival for peritoneal carcinomatosis from colorectal cancer: A systematic review and meta-analysis of current evidence. *Oncotarget* 2017; **8**: 55657-55683 [PMID: 28903452 DOI: 10.18632/oncotarget.17497]
- 79 **Kelly KJ**, Cajas L, Baumgartner JM, Lowy AM. Factors Associated with 60-Day Readmission Following Cytoreduction and Hyperthermic Intraperitoneal Chemotherapy. *Ann Surg Oncol* 2018; **25**: 91-97 [PMID: 29090402 DOI: 10.1245/s10434-017-6108-8]
- 80 **Ceelen W**. HIPEC with oxaliplatin for colorectal peritoneal metastasis: The end of the road? *Eur J Surg Oncol* 2019; **45**: 400-402 [PMID: 30392745 DOI: 10.1016/j.ejso.2018.10.542]
- 81 **Mogal H**, Chouliaras K, Levine EA, Shen P, Votanopoulos KI. Repeat cytoreductive surgery with

- hyperthermic intraperitoneal chemotherapy: Review of indications and outcomes. *J Gastrointest Oncol* 2016; **7**: 129-142 [PMID: 26941991 DOI: 10.3978/j.issn.2078-6891.2015.131]
- 82 **Golse N**, Bakrin N, Passot G, Mohamed F, Vaudoyer D, Gilly FN, Glehen O, Cotte E. Iterative procedures combining cytoreductive surgery with hyperthermic intraperitoneal chemotherapy for peritoneal recurrence: postoperative and long-term results. *J Surg Oncol* 2012; **106**: 197-203 [PMID: 22331814 DOI: 10.1002/jso.23062]
- 83 **Bijelic L**, Yan TD, Sugarbaker PH. Treatment failure following complete cytoreductive surgery and perioperative intraperitoneal chemotherapy for peritoneal dissemination from colorectal or appendiceal mucinous neoplasms. *J Surg Oncol* 2008; **98**: 295-299 [PMID: 18726900 DOI: 10.1002/jso.21084]
- 84 **Alzahrani NA**, Valle SJ, Fisher OM, Sugarbaker PH, Yonemura Y, Glehen O, Goere D, Honore C, Brigand C, de Hingh I, Verwaal VJ, Deraco M, Baratti D, Kusamura S, Pocard M, Piso P, Maerz L, Marchal F, Moran B, Levine EA, Dumont F, Pezet D, Abboud K, Kozman MA, Liauw W, Morris DL; Peritoneal Surface Oncology Group International (PSOGI) and Big-RENAPE groups. Iterative cytoreductive surgery with or without hyperthermic intraperitoneal chemotherapy for colorectal peritoneal metastases: A multi-institutional experience. *J Surg Oncol* 2019; **119**: 336-346 [PMID: 30554404 DOI: 10.1002/jso.25277]
- 85 **Suman G**, Baheti AD, Ankathi SK, Shetty N, Kulkarni S, Ostwal V, Saklani AP. Role of Ultrasonography in the Surveillance of Disease-Free Patients with Colorectal Cancer: A Retrospective Audit. *Indian J Surg Oncol* 2018; **9**: 452-455 [PMID: 30538371 DOI: 10.1007/s13193-018-0815-x]
- 86 **Sobhani I**, Itti E, Luciani A, Baumgaertner I, Layese R, André T, Ducreux M, Gornet JM, Goujon G, Aparicio T, Taieb J, Bachet JB, Hemery F, Retbi A, Mons M, Flicoteaux R, Rhein B, Baron S, Cherrak I, Rufat P, Le Corvoisier P, de'Angelis N, Natella PA, Maoulida H, Tournigand C, Durand Zaleski I, Bastuji-Garin S. Colorectal cancer (CRC) monitoring by 6-monthly 18FDG-PET/CT: An open-label multicentre randomised trial. *Ann Oncol* 2018; **29**: 931-937 [PMID: 29365058 DOI: 10.1093/annonc/mdy031]
- 87 **Peng NJ**, Hu C, King TM, Chiu YL, Wang JH, Liu RS. Detection of resectable recurrences in colorectal cancer patients with 2-[18F]fluoro-2-deoxy-D-glucose-positron emission tomography/computed tomography. *Cancer Biother Radiopharm* 2013; **28**: 479-487 [PMID: 23713869 DOI: 10.1089/cbr.2012.1382]
- 88 **Jeffery M**, Hickey BE, Hider PN, See AM. Follow-up strategies for patients treated for non-metastatic colorectal cancer. *Cochrane Database Syst Rev* 2016; **11**: CD002200 [PMID: 27884041 DOI: 10.1002/14651858.CD002200.pub3]
- 89 **Mant D**, Gray A, Pugh S, Campbell H, George S, Fuller A, Shinkins B, Corkhill A, Mellor J, Dixon E, Little L, Perera-Salazar R, Primrose J. A randomised controlled trial to assess the cost-effectiveness of intensive versus no scheduled follow-up in patients who have undergone resection for colorectal cancer with curative intent. *Health Technol Assess* 2017; **21**: 1-86 [PMID: 28641703 DOI: 10.3310/hta21320]
- 90 **Mokhles S**, Macbeth F, Farewell V, Fiorentino F, Williams NR, Younes RN, Takkenberg JJ, Treasure T. Meta-analysis of colorectal cancer follow-up after potentially curative resection. *Br J Surg* 2016; **103**: 1259-1268 [PMID: 27488593 DOI: 10.1002/bjs.10233]
- 91 **Snyder RA**, Hu CY, Cuddy A, Francescatti AB, Schumacher JR, Van Loon K, You YN, Kozower BD, Greenberg CC, Schrag D, Venook A, McKellar D, Winchester DP, Chang GJ; Alliance for Clinical Trials in Oncology Network Cancer Surveillance Optimization Working Group. Association Between Intensity of Posttreatment Surveillance Testing and Detection of Recurrence in Patients With Colorectal Cancer. *JAMA* 2018; **319**: 2104-2115 [PMID: 29800181 DOI: 10.1001/jama.2018.5816]
- 92 **Wille-Jørgensen P**, Syk I, Smedh K, Laurberg S, Nielsen DT, Petersen SH, Renehan AG, Horváth-Puhó E, Pahlman L, Sørensen HT; COLOFOL Study Group. Effect of More vs Less Frequent Follow-up Testing on Overall and Colorectal Cancer-Specific Mortality in Patients With Stage II or III Colorectal Cancer: The COLOFOL Randomized Clinical Trial. *JAMA* 2018; **319**: 2095-2103 [PMID: 29800179 DOI: 10.1001/jama.2018.5623]
- 93 **Primrose JN**, Perera R, Gray A, Rose P, Fuller A, Corkhill A, George S, Mant D; FACS Trial Investigators. Effect of 3 to 5 years of scheduled CEA and CT follow-up to detect recurrence of colorectal cancer: The FACS randomized clinical trial. *JAMA* 2014; **311**: 263-270 [PMID: 24430319 DOI: 10.1001/jama.2013.285718]
- 94 **Serrano Del Moral Á**, Pérez Viejo E, Manzanedo Romero I, Rodríguez Caravaca G, Pereira Pérez F. Systematic Second-look Surgery Plus HIPEC in Patients Without Evidence of Recurrence, at High Risk of Carcinomatosis After Colorectal Cancer Resection. *Cir Esp* 2018; **96**: 96-101 [PMID: 29397879 DOI: 10.1016/j.ciresp.2017.11.006]
- 95 **Elias D**, Honoré C, Dumont F, Ducreux M, Boige V, Malka D, Burtin P, Dromain C, Goéré D. Results of systematic second-look surgery plus HIPEC in asymptomatic patients presenting a high risk of developing colorectal peritoneal carcinomatosis. *Ann Surg* 2011; **254**: 289-293 [PMID: 21709543 DOI: 10.1097/SLA.0b013e31822638f6]
- 96 **Sammartino P**, Sibio S, Biacchi D, Cardi M, Mingazzini P, Rosati MS, Cornali T, Sollazzo B, Atta JM, Di Giorgio A. Long-term results after proactive management for locoregional control in patients with colonic cancer at high risk of peritoneal metastases. *Int J Colorectal Dis* 2014; **29**: 1081-1089 [PMID: 24980687 DOI: 10.1007/s00384-014-1929-4]
- 97 **Tentes AAK**, Kakolyris S, Pallas N, Korakianitis O, Mavroudis C, Zorbas G, Sarlis P. Preliminary results with the use of hyperthermic intraperitoneal intraoperative chemotherapy or systemic chemotherapy in high-risk colorectal cancer patients. *Transl Gastrointest Cancer* 2013; **2**: 6-10 [DOI: 10.3978/j.issn.2224-4778.2012.10.02]
- 98 **Baratti D**, Kusamura S, Iusco D, Gimondi S, Pietrantonio F, Milione M, Guaglio M, Bonomi S, Grassi A, Virzi S, Leo E, Deraco M. Hyperthermic Intraperitoneal Chemotherapy (HIPEC) at the Time of Primary Curative Surgery in Patients with Colorectal Cancer at High Risk for Metachronous Peritoneal Metastases. *Ann Surg Oncol* 2017; **24**: 167-175 [PMID: 27519353 DOI: 10.1245/s10434-016-5488-5]
- 99 **Sloothaak DA**, Mirck B, Punt CJ, Bemelman WA, van der Bilt JD, D'Hoore A, Tanis PJ. Intraperitoneal chemotherapy as adjuvant treatment to prevent peritoneal carcinomatosis of colorectal cancer origin: A systematic review. *Br J Cancer* 2014; **111**: 1112-1121 [PMID: 25025964 DOI: 10.1038/bjc.2014.369]
- 100 **Arjona-Sánchez A**, Barrios P, Boldo-Roda E, Camps B, Carrasco-Campos J, Concepción Martín V, García-Fadrigue A, Gutiérrez-Calvo A, Morales R, Ortega-Pérez G, Pérez-Viejo E, Prada-Villaverde A, Torres-Melero J, Vicente E, Villarejo-Campos P, Sánchez-Hidalgo JM, Casado-Adam A, García-Martin R, Medina M, Caro T, Villar C, Aranda E, Cano-Osuna MT, Díaz-López C, Torres-Tordera E, Briceño-Delgado FJ, Rufián-Peña S. HIPECT4: multicentre, randomized clinical trial to evaluate safety and efficacy of Hyperthermic intra-peritoneal chemotherapy (HIPEC) with Mitomycin C used during surgery

- for treatment of locally advanced colorectal carcinoma. *BMC Cancer* 2018; **18**: 183 [PMID: 29439668 DOI: 10.1186/s12885-018-4096-0]
- 101 **Diane G**, Olivier G, Francois Q, Michel D, Jean-Marc G, Matthieu T, Ellen B, Dominique E. Results of a randomized phase 3 study evaluating the potential benefit of a second-look surgery plus HIPEC in patients at high risk of developing colorectal peritoneal metastases (PROPHYLOCHIP- NTC01226394). *J Clin Oncol* 2018; **36**: 3531-3531 [DOI: 10.1200/JCO.2018.36.15_suppl.3531]
- 102 **Charlotte K**, Daniel D, Cornelis J, Petur S, Johannes C, Arend A, Bemelman WA, Brandt A, Bremers A, Burger J, van Greverstein W, Hemmer P, de Hingh I, Kok N, Tuynman J, Wiezer M, de Wilt J, Dijkgraaf M, Tanis P. Adjuvant HIPEC in patients with colon cancer at high risk of peritoneal metastases: Primary outcome of the COLOPEC multicenter randomized trial. *J Clin Oncol* 2019; **37**: 482-482 [DOI: 10.1200/JCO.2019.37.4_suppl.482]
- 103 **von Breitenbuch P**, Boerner T, Jeiter T, Piso P, Schlitt HJ. Laparoscopy as a useful selection tool for patients with prior surgery and peritoneal metastases suitable for multimodality treatment strategies. *Surg Endosc* 2018; **32**: 2288-2294 [PMID: 29218669 DOI: 10.1007/s00464-017-5923-0]
- 104 **Kurtz F**, Struller F, Horvath P, Solass W, Bösmüller H, Königsrainer A, Reymond MA. Feasibility, Safety, and Efficacy of Pressurized Intraperitoneal Aerosol Chemotherapy (PIPAC) for Peritoneal Metastasis: A Registry Study. *Gastroenterol Res Pract* 2018; **2018**: 2743985 [PMID: 30473706 DOI: 10.1155/2018/2743985]
- 105 **Demtröder C**, Solass W, Zieren J, Strumberg D, Giger-Pabst U, Reymond MA. Pressurized intraperitoneal aerosol chemotherapy with oxaliplatin in colorectal peritoneal metastasis. *Colorectal Dis* 2016; **18**: 364-371 [PMID: 26400556 DOI: 10.1111/codi.13130]
- 106 **Hentzen JEKR**, de Jongh SJ, Hemmer PHJ, van der Plas WY, van Dam GM, Kruijff S. Molecular fluorescence-guided surgery of peritoneal carcinomatosis of colorectal origin: A narrative review. *J Surg Oncol* 2018; **118**: 332-343 [PMID: 29938400 DOI: 10.1002/jso.25106]
- 107 **Yonemura Y**, Elnemr A, Endou Y, Ishibashi H, Mizumoto A, Miura M, Li Y. Effects of neoadjuvant intraperitoneal/systemic chemotherapy (bidirectional chemotherapy) for the treatment of patients with peritoneal metastasis from gastric cancer. *Int J Surg Oncol* 2012; **2012**: 148420 [PMID: 22900159 DOI: 10.1155/2012/148420]
- 108 **Sgarbura O**, Samalin E, Carrere S, Mazard T, de Forges H, Alline M, Pissas MH, Portales F, Ychou M, Quenet F. Preoperative intraperitoneal oxaliplatin for unresectable peritoneal carcinomatosis of colorectal origin: A pilot study. *Pleura Peritoneum* 2016; **1**: 209-215 [PMID: 30911625 DOI: 10.1515/pp-2016-0018]
- 109 **Franko J**, Ibrahim Z, Gusani NJ, Holtzman MP, Bartlett DL, Zeh HJ. Cytoreductive surgery and hyperthermic intraperitoneal chemoperfusion versus systemic chemotherapy alone for colorectal peritoneal carcinomatosis. *Cancer* 2010; **116**: 3756-3762 [PMID: 20564081 DOI: 10.1002/encr.25116]
- 110 **Gervais MK**, Dubé P, McConnell Y, Drolet P, Mitchell A, Sideris L. Cytoreductive surgery plus hyperthermic intraperitoneal chemotherapy with oxaliplatin for peritoneal carcinomatosis arising from colorectal cancer. *J Surg Oncol* 2013; **108**: 438-443 [PMID: 24018983 DOI: 10.1002/jso.23431]
- 111 **Goéré D**, Souadka A, Faron M, Cloutier AS, Viana B, Honoré C, Dumont F, Elias D. Extent of colorectal peritoneal carcinomatosis: Attempt to define a threshold above which HIPEC does not offer survival benefit: A comparative study. *Ann Surg Oncol* 2015; **22**: 2958-2964 [PMID: 25631064 DOI: 10.1245/s10434-015-4387-5]
- 112 **Huang CQ**, Feng JP, Yang XJ, Li Y. Cytoreductive surgery plus hyperthermic intraperitoneal chemotherapy improves survival of patients with peritoneal carcinomatosis from colorectal cancer: A case-control study from a Chinese center. *J Surg Oncol* 2014; **109**: 730-739 [PMID: 24374987 DOI: 10.1002/jso.23545]
- 113 **Cao CQ**, Yan TD, Liauw W, Morris DL. Comparison of optimally resected hepatectomy and peritonectomy patients with colorectal cancer metastasis. *J Surg Oncol* 2009; **100**: 529-533 [PMID: 19697395 DOI: 10.1002/jso.21369]
- 114 **Froysnes IS**, Larsen SG, Spasojevic M, Dueland S, Flatmark K. Complete cytoreductive surgery and hyperthermic intraperitoneal chemotherapy for colorectal peritoneal metastasis in Norway: Prognostic factors and oncologic outcome in a national patient cohort. *J Surg Oncol* 2016; **114**: 222-227 [PMID: 27173150 DOI: 10.1002/jso.24290]
- 115 **Hamilton T**, Lanuke K, Mack LA, Temple WJ. Long-term follow-up in the treatment of peritoneal carcinomatosis. *Am J Surg* 2011; **201**: 650-654 [PMID: 21545916 DOI: 10.1016/j.amjsurg.2011.01.013]
- 116 **Hompes D**, D'Hoore A, Van Cutsem E, Fieus S, Ceelen W, Peeters M, Van der Speeten K, Bertrand C, Legendre H, Kerger J. The treatment of peritoneal carcinomatosis of colorectal cancer with complete cytoreductive surgery and hyperthermic intraperitoneal peroperative chemotherapy (HIPEC) with oxaliplatin: A Belgian multicentre prospective phase II clinical study. *Ann Surg Oncol* 2012; **19**: 2186-2194 [PMID: 22395983 DOI: 10.1245/s10434-012-2264-z]
- 117 **Simkens GA**, van Oudheusden TR, Luyer MD, Nienhuijs SW, Nieuwenhuijzen GA, Rutten HJ, de Hingh IH. Serious Postoperative Complications Affect Early Recurrence After Cytoreductive Surgery and HIPEC for Colorectal Peritoneal Carcinomatosis. *Ann Surg Oncol* 2015; **22**: 2656-2662 [PMID: 25515200 DOI: 10.1245/s10434-014-4297-y]
- 118 **Prada-Villaverde A**, Esquivel J, Lowy AM, Markman M, Chua T, Pelz J, Baratti D, Baumgartner JM, Berri R, Bretcha-Boix P, Deraco M, Flores-Ayala G, Glehen O, Gomez-Portilla A, González-Moreno S, Goodman M, Halkia E, Kusamura S, Moller M, Passot G, Pocard M, Salti G, Sardi A, Senthil M, Spiliotis J, Torres-Melero J, Turaga K, Trout R. The American Society of Peritoneal Surface Malignancies evaluation of HIPEC with Mitomycin C versus Oxaliplatin in 539 patients with colon cancer undergoing a complete cytoreductive surgery. *J Surg Oncol* 2014; **110**: 779-785 [PMID: 25088304 DOI: 10.1002/jso.23728]
- 119 **Quenet F**, Goéré D, Mehta SS, Roca L, Dumont F, Hessissen M, Saint-Aubert B, Elias D. Results of two bi-institutional prospective studies using intraperitoneal oxaliplatin with or without irinotecan during HIPEC after cytoreductive surgery for colorectal carcinomatosis. *Ann Surg* 2011; **254**: 294-301 [PMID: 21772129 DOI: 10.1097/SLA.0b013e3182263933]



Published By Baishideng Publishing Group Inc
7041 Koll Center Parkway, Suite 160, Pleasanton, CA 94566, USA
Telephone: +1-925-2238242
Fax: +1-925-2238243
E-mail: bpgoffice@wjgnet.com
Help Desk: <http://www.f6publishing.com/helpdesk>
<http://www.wjgnet.com>

