

World Journal of *Clinical Cases*

World J Clin Cases 2019 September 26; 7(18): 2658-2915



**OPINION REVIEW**

- 2658** Effective use of the Japan Narrow Band Imaging Expert Team classification based on diagnostic performance and confidence level
Hirata D, Kashida H, Iwatate M, Tochio T, Teramoto A, Sano Y, Kudo M

MINIREVIEWS

- 2666** Low fermentable oligosaccharides, disaccharides, monosaccharides, and polyols diet in children
Fodor I, Man SC, Dumitrascu DL
- 2675** High-resolution colonic manometry and its clinical application in patients with colonic dysmotility: A review
Li YW, Yu YJ, Fei F, Zheng MY, Zhang SW

ORIGINAL ARTICLE**Retrospective Study**

- 2687** Predictors of rebleeding and in-hospital mortality in patients with nonvariceal upper digestive bleeding
Lazăr DC, Ursoniu S, Goldiș A
- 2704** Analgesic effect of parecoxib combined with ropivacaine in patients undergoing laparoscopic hepatectomy
Huang SS, Lv WW, Liu YF, Yang SZ
- 2712** Prognostic significance of 14v-lymph node dissection to D2 dissection for lower-third gastric cancer
Zheng C, Gao ZM, Sun AQ, Huang HB, Wang ZN, Li K, Gao S

Observational Study

- 2722** Wall shear stress can improve prediction accuracy for transient ischemic attack
Liu QY, Duan Q, Fu XH, Jiang M, Xia HW, Wan YL

Prospective Study

- 2734** Characterization of microbiota in systemic-onset juvenile idiopathic arthritis with different disease severities
Dong YQ, Wang W, Li J, Ma MS, Zhong LQ, Wei QJ, Song HM

SYSTEMATIC REVIEWS

- 2746** Sinusoidal obstruction syndrome: A systematic review of etiologies, clinical symptoms, and magnetic resonance imaging features
Zhang Y, Jiang HY, Wei Y, Song B

META-ANALYSIS

- 2760** Respiratory training interventions improve health status of heart failure patients: A systematic review and network meta-analysis of randomized controlled trials
Wang MH, Yeh ML

CASE REPORT

- 2776** *Mycobacterium chimaera* infections following cardiac surgery in Treviso Hospital, Italy, from 2016 to 2019: Cases report
Inojosa WO, Giobbia M, Muffato G, Minniti G, Baldasso F, Carniato A, Farina F, Forner G, Rossi MC, Formentini S, Rigoli R, Scotton PG
- 2787** Giant squamous cell carcinoma of the gallbladder: A case report
Junior MAR, Favaro MDL, Santin S, Silva CM, Iamarino APM
- 2794** Liver re-transplantation for donor-derived neuroendocrine tumor: A case report
Mrzljak A, Kocman B, Skrtic A, Furac I, Popic J, Franusic L, Zunec R, Mayer D, Mikulic D
- 2802** Calcifying fibrous tumor originating from the gastrohepatic ligament that mimicked a gastric submucosal tumor: A case report
Kwan BS, Cho DH
- 2808** Pancreatitis, panniculitis, and polyarthritis syndrome caused by pancreatic pseudocyst: A case report
Jo S, Song S
- 2815** Glomus tumor of uncertain malignant potential of the brachial plexus: A case report
Thanindrarn P, Chobpenthai T, Phorkhar T, Nelson SD
- 2823** Conservative pulp treatment for Oehlers type III dens invaginatus: A case report
Lee HN, Chen YK, Chen CH, Huang CY, Su YH, Huang YW, Chuang FH
- 2831** Propofol pump controls nonconvulsive status epilepticus in a hepatic encephalopathy patient: A case report
Hor S, Chen CY, Tsai ST
- 2838** Teriparatide as nonoperative treatment for femoral shaft atrophic nonunion: A case report
Tsai MH, Hu CC
- 2843** Successful repair of acute type A aortic dissection during pregnancy at 16th gestational week with maternal and fetal survival: A case report and review of the literature
Chen SW, Zhong YL, Ge YP, Qiao ZY, Li CN, Zhu JM, Sun LZ
- 2851** Inferior pancreaticoduodenal artery pseudoaneurysm in a patient with calculous cholecystitis: A case report
Xu QD, Gu SG, Liang JH, Zheng SD, Lin ZH, Zhang PD, Yan J

- 2857** ALK-positive anaplastic large cell lymphoma of the thoracic spine occurring in pregnancy: A case report
Yang S, Jiang WM, Yang HL
- 2864** Endoscopic mucosal resection of a bile duct polyp: A case report
Yang S, Yang L, Wang XY, Yang YM
- 2871** Multiple gastric adenocarcinoma of fundic gland type: A case report
Chen O, Shao ZY, Qiu X, Zhang GP
- 2879** Repair of the portal vein using a hepatic ligamentum teres patch for laparoscopic pancreatoduodenectomy: A case report
Wei Q, Chen QP, Guan QH, Zhu WT
- 2888** Drug coated balloon angioplasty for renal artery stenosis due to Takayasu arteritis: Report of five cases
Bi YH, Ren JZ, Yi MF, Li JD, Han XW
- 2894** Entrapment of the temporal horn secondary to postoperative gamma-knife radiosurgery in intraventricular meningioma: A case report
Liu J, Long SR, Li GY
- 2899** Pleomorphic lipoma in the anterior mediastinum: A case report
Mao YQ, Liu XY, Han Y
- 2905** Guillain-Barré syndrome in a patient with multiple myeloma after bortezomib therapy: A case report
Xu YL, Zhao WH, Tang ZY, Li ZQ, Long Y, Cheng P, Luo J
- 2910** Bowen's disease on the palm: A case report
Yu SR, Zhang JZ, Pu XM, Kang XJ

ABOUT COVER

Editorial Board Member of *World Journal of Clinical Cases*, Shao-Ping Yu, MD, Associate Professor, Chief Doctor, Department of Gastroenterology and Hepatology, Dongguan Kanghua Hospital, Dongguan 523080, Guangdong Province, China

AIMS AND SCOPE

The primary aim of *World Journal of Clinical Cases* (*WJCC*, *World J Clin Cases*) is to provide scholars and readers from various fields of clinical medicine with a platform to publish high-quality clinical research articles and communicate their research findings online.

WJCC mainly publishes case reports, case series, and articles reporting research results and findings obtained in the field of clinical medicine and covering a wide range of topics including diagnostic, therapeutic, and preventive modalities.

INDEXING/ABSTRACTING

The *WJCC* is now indexed in PubMed, PubMed Central, Science Citation Index Expanded (also known as SciSearch®), and Journal Citation Reports/Science Edition. The 2019 Edition of Journal Citation Reports cites the 2018 impact factor for *WJCC* as 1.153 (5-year impact factor: N/A), ranking *WJCC* as 99 among 160 journals in Medicine, General and Internal (quartile in category Q3).

RESPONSIBLE EDITORS FOR THIS ISSUE

Responsible Electronic Editor: Ji-Hong Liu

Proofing Production Department Director: Yun-Xiaoqian Wu

NAME OF JOURNAL

World Journal of Clinical Cases

ISSN

ISSN 2307-8960 (online)

LAUNCH DATE

April 16, 2013

FREQUENCY

Semimonthly

EDITORS-IN-CHIEF

Dennis A Bloomfield, Bao-Gan Peng, Sandro Vento

EDITORIAL BOARD MEMBERS

<https://www.wjgnet.com/2307-8960/editorialboard.htm>

EDITORIAL OFFICE

Jin-Lei Wang, Director

PUBLICATION DATE

September 26, 2019

COPYRIGHT

© 2019 Baishideng Publishing Group Inc

INSTRUCTIONS TO AUTHORS

<https://www.wjgnet.com/bpg/gerinfo/204>

GUIDELINES FOR ETHICS DOCUMENTS

<https://www.wjgnet.com/bpg/GerInfo/287>

GUIDELINES FOR NON-NATIVE SPEAKERS OF ENGLISH

<https://www.wjgnet.com/bpg/gerinfo/240>

PUBLICATION MISCONDUCT

<https://www.wjgnet.com/bpg/gerinfo/208>

ARTICLE PROCESSING CHARGE

<https://www.wjgnet.com/bpg/gerinfo/242>

STEPS FOR SUBMITTING MANUSCRIPTS

<https://www.wjgnet.com/bpg/GerInfo/239>

ONLINE SUBMISSION

<https://www.f6publishing.com>

Sinusoidal obstruction syndrome: A systematic review of etiologies, clinical symptoms, and magnetic resonance imaging features

Yun Zhang, Han-Yu Jiang, Yi Wei, Bin Song

ORCID number: Yun Zhang (0000-0001-9621-1408); Han-Yu Jiang (0000-0002-7726-1618); Yi Wei (0000-0003-3993-9747); Bin Song (0000-0001-7007-6367).

Author contributions: Zhang Y, Jiang HY, and Wei Y contributed equally to the work; Zhang Y conceptualized and designed the review together with Wei Y; Zhang Y and Jiang HY carried out the analysis; Zhang Y drafted the initial manuscript; Song B reviewed and approved the final manuscript as submitted.

Conflict-of-interest statement: The authors report no relevant conflicts of interest.

PRISMA 2009 Checklist statement: The manuscript was prepared and revised according to the PRISMA 2009 Checklist.

Open-Access: This article is an open-access article which was selected by an in-house editor and fully peer-reviewed by external reviewers. It is distributed in accordance with the Creative Commons Attribution Non Commercial (CC BY-NC 4.0) license, which permits others to distribute, remix, adapt, build upon this work non-commercially, and license their derivative works on different terms, provided the original work is properly cited and the use is non-commercial. See: <http://creativecommons.org/licenses/by-nc/4.0/>

Manuscript source: Invited manuscript

Received: March 23, 2019

Yun Zhang, Han-Yu Jiang, Yi Wei, Bin Song, Department of Radiology, Sichuan University West China Hospital, Chengdu 610041, Sichuan Province, China

Corresponding author: Bin Song, MD, Chief Doctor, Director, Professor, Department of Radiology, Sichuan University West China Hospital, No. 37, Guoxue Alley, Chengdu 610041, Sichuan Province, China. cjr.songbin@vip.163.com

Telephone: +86-28-85423680

Fax: +86-28-85582499

Abstract

BACKGROUND

Sinusoidal obstruction syndrome (SOS) is a kind of rare liver disease which is characterized by damage to small hepatic vessels, affecting particularly the sinusoidal endothelium. Due to the special etiology and high mortality, early diagnosis of SOS is significant for clinical survival and prognosis.

AIM

To generalize the common etiologies and clinical symptoms of SOS and summarize the characteristic magnetic resonance imaging (MRI) features so as to provide more valuable information for early diagnosis of SOS.

METHOD

We searched PubMed, Web of science, Wanfang Data, China Knowledge Resource Integrated, VIP, and Cochrane Library databases without a limiting period and the types of articles. The search process mainly revolved around the etiologies, common clinical symptoms, and MRI imaging features of SOS. Ultimately, 29 full articles were included in this review and 222 articles were excluded.

RESULTS

Eleven case reports included 13 patients. The etiologies of these patients including chemotherapy (5/13), medicinal herbs containing pyrrolidine alkaloids (PAs, e.g. Tusanqi) (4/13), hematopoietic stem cell transplantation (HSCT) (2/13), drug toxicity (6-thioguanine) (1/13), and "poppers", a recreational drug used during anal intercourse (1/13). Eighteen case series including 497 patients, and SOS in 465 (93.6%) patients was caused by PAs. Ascites, abdominal pain and swelling, jaundice were the most common clinical symptoms. Alanine aminotransferase (ALT), aspartate aminotransferase (AST), alkaline phosphatase (ALP), gamma-glutamyl transpeptidase (GGT), total bilirubin (TBil), direct bilirubin (DBil), and prothrombin time (PT) had varying degrees of elevation.

Peer-review started: March 26, 2019
First decision: August 1, 2019
Revised: August 17, 2019
Accepted: August 26, 2019
Article in press: August 27, 2019
Published online: September 26, 2019

P-Reviewer: Valek V
S-Editor: Wang JL
L-Editor: Wang TQ
E-Editor: Liu JH



Heterogeneous signals on T1 weighted imaging/T2 weighted imaging (T1WI/T2WI), heterogeneous enhancement of liver parenchyma, ascites, hepatomegaly, narrowing and blurring of intrahepatic inferior vena cava and three main hepatic veins, edema around the portal vein, and gallbladder wall edema were the most common MRI imaging features of SOS.

CONCLUSION

In the West, SOS was mostly secondary to HSCT. Some SOS developed in the process of chemotherapy for hepatic metastatic tumor. A few SOS were caused by toxicity of certain drugs. In the East, Tusanqi was a major cause of SOS. Ascites, abdominal pain and swelling, jaundice were the common clinical symptoms. Elevations of ALT, AST, GGT, ALP, TBil, and DBil could be used as predictors of liver function damage. Numerous characteristic MRI imaging features could provide more valuable information for early diagnosis of SOS.

Key words: Sinusoidal obstruction syndrome; Hematopoietic stem cell transplantation; Chemotherapy; Tusanqi; Ascites

©The Author(s) 2019. Published by Baishideng Publishing Group Inc. All rights reserved.

Core tip: In total, 11 case reports and 18 case series were systematically reviewed. These articles stated the main causes of sinusoidal obstruction syndrome (SOS) and summarized the common clinical symptoms and abnormal laboratory indicators. Numerous characteristic magnetic resonance imaging features could provide more valuable information for early diagnosis of SOS.

Citation: Zhang Y, Jiang HY, Wei Y, Song B. Sinusoidal obstruction syndrome: A systematic review of etiologies, clinical symptoms, and magnetic resonance imaging features. *World J Clin Cases* 2019; 7(18): 2746-2759

URL: <https://www.wjgnet.com/2307-8960/full/v7/i18/2746.htm>

DOI: <https://dx.doi.org/10.12998/wjcc.v7.i18.2746>

INTRODUCTION

Sinusoidal obstruction syndrome (SOS) is a rare liver vascular injury disease, characterized by damage to small hepatic vessels, affecting particularly the sinusoidal endothelium, which result in complications such as intrahepatic congestion, liver damage, and portal hypertension^[1]. SOS was previously called as hepatic veno-occlusive disease until some researchers suggested that the main site of toxic injury is hepatic sinusoidal endothelium rather than hepatic veins^[2]. Hepatomegaly, ascites, and elevated serum bilirubin levels are the characteristic manifestations of SOS. In addition, severe SOS is associated with a high mortality rate and most deaths result from multi-organ failure^[3].

Although liver biopsy is the gold standard for the diagnosis of SOS, leukopenia and poor liver function resulting from hematological diseases or advanced tumors make this operation difficult. The Baltimore criteria, the modified Seattle criteria, and the European Society for Blood and Marrow Transplantation criteria are the three main criteria for diagnosing SOS^[4,5]. However, these criteria are usually appropriated for SOS secondary to haematopoietic stem cell transplantation (HSCT), including a little of clinical information but not involving imaging findings. In recent years, magnetic resonance imaging (MRI) has been increasingly used to detect and evaluate liver diseases. In 2017, Chinese scholars combined the etiologies of SOS in Chinese and proposed the new diagnostic criteria for SOS, namely, the Nanjing criteria. The criteria focus on the diagnosis of SOS caused by pyrrolidine alkaloids (PAs), and incorporate clinical information and imaging findings^[6].

Considering the complexity of etiologies and the limitation of liver biopsy, non-invasive imaging methods are significant for SOS differential diagnosis. This systematic review collected the current research on SOS, aiming at generalizing the common etiologies and clinical symptoms of SOS and summarizing the characteristic MRI imaging features for providing more valuable information in SOS early diagnosis.

MATERIALS AND METHODS

Protocol and registration

This systematic review was registered at the international prospective register of systematic reviews platform (PROSPERO; registration number: CRD42019127258). This study followed the recommendations of the Preferred Reporting Items for Systematic Reviews and Meta-Analyses.

Search strategy

We searched all the literature from PubMed, Web of science, Cochrane Library, Wanfang Data, China Knowledge Resource Integrated, and VIP databases. The following set of keywords was used for the English search strategy: [(sinusoidal obstruction syndrome) OR (hepatic veno-occlusive disease)] AND [(MRI) OR (magnetic resonance imaging) OR (MR imaging)]. Chinese search items were used in the latter three databases, as follows: [(Gandou Zuse) OR (Gan Xiaojingmai Bise)] AND [(Cigongzhen) OR (MRI)]. Last search was performed on January 28, 2019.

Study selection

All articles related to SOS etiologies, clinical symptoms, and MRI findings were considered. The exclusion criteria were as follows: (1) Duplicate publications among databases; (2) Duplicate publications by the same author; (3) Letter, comments, or conference papers; (4) Reviews; (5) Neither in English nor in Chinese; (6) Not related to human; (7) Not related to this systematic review; and (8) Cannot extract detailed data.

Data extraction

Twenty-nine studies were included in the final analysis, and none of them were randomized controlled trials or cohort studies. We classified the included studies into two categories: Case reports and case series. If detailed data could be extracted for every patient in studies, it would be classified as case reports, otherwise case series.

The following data were collected by two independent investigators: Author, country, published year, patient enrollment, number, age, sex, primary disease, etiology, time of duration, diagnosis method, MRI equipment information, scanning sequence, frequent clinical symptoms, laboratory indexes, and main MRI findings. A third author participated in a disagreement in the findings of two authors, which was solved by discussion.

Study quality

Given the characteristics of our included articles, there was no ready-made quality assessment scale for case reports and case series. Therefore, we referred to some literature^[7] and revised the existing quality assessment scale as follows: (1) Patient enrollment: Are the patients consecutively and prospectively enrolled? (2) Demographic data: Is the basic information of sex and age clearly reported? (3) Clinical presentation data: Are the clinical symptoms clearly reported? (4) Laboratory test data: Are the laboratory test data clearly reported? (5) Diagnostic workup: Is the diagnosis based on pathological results? and (6) Imaging findings: Are the imaging manifestations clearly reported?

Notably, case reports were not related to patient enrollment, therefore patient enrollment was not assessed in the study quality.

RESULTS

Search results

A total of 251 articles were initially searched. After removal of duplicates ($n = 37$), 214 articles were subjected to screening of abstracts and full-texts. Following careful review of abstracts and full-texts, a total of 185 articles were excluded due to not meeting the inclusion criteria. Finally, 29 articles met the inclusion criteria and were included in this systematic review (Figure 1).

Characteristics of the studies

Among 29 articles included in this systematic review, 20 were in Chinese and 9 in English. According to the case number and information integrity of the literature, 29 articles were classified as either case reports ($n = 11$) or case series ($n = 18$).

According to the quality assessment criteria above, we conducted the quality evaluation of all the included literature. The evaluation results are shown in Tables 1 and 2, and we used two stars to represent the highest quality. The characteristic information of all the patients in 29 studies is shown in Tables 3 and 4.

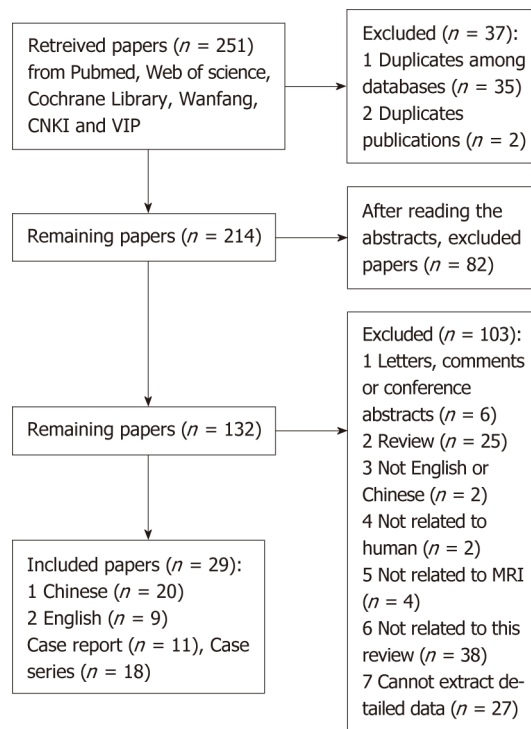


Figure 1 Flowchart of study inclusion.

Etiologies and clinical symptoms of SOS

Eleven cases reports included 13 individual cases of SOS from 6 countries (USA, Netherlands, UK, Japan, Korea, and China). These patients were admitted from 1999 to 2017. Among the 13 cases, 7 were males and 6 were females (average age: 47.9 ± 18.0 ; age range: 17-75).

The clinical characteristics of 13 cases are shown in Table 5. Five cases were secondary to chemotherapy after liver metastases. The chemotherapy cycles ranged from 4 to 8. All the 5 cases presented no obvious clinical symptoms, but the laboratory examination data indicated different degrees of liver damage. In addition, 4 cases were caused by Tusanqi. Ascites was the most common clinical symptom.

Seventeen out of 18 case series were reported by Chinese researchers, and the other one was reported by researchers in Hong Kong, China. All the patients were admitted from 1998 to 2017. Patient enrollment was neither consecutive nor prospective in any case series. Eighteen case series included 497 patients, including 310 males and 187 females. All studies had specific demographic data.

Of the 18 cases series, the patients in 8 cases series were reported to have underlying diseases, including trauma, stroke, alcoholic liver cirrhosis, chronic body pain, hypertension, myocardial infarction, drinking, diabetes, diseases of the respiratory system (tuberculosis and upper respiratory infection), and some diseases related to Chinese medicine (menstrual disorder). SOS in about 465 (93.6%) patients was caused by PAs (Tusanqi), and the time of duration from 10 days to 18 months. Five cases were secondary to tumor chemotherapy or immunotherapy, and four were caused by HSCT. The rest of the patients had no obvious inducing factors.

Not all the 497 patients had detailed records of clinical manifestations and laboratory examination data. Most of the studies recorded the presence or absence of clinical symptoms and described the variation trend of laboratory indicators. Stomach ache, abdominal swelling, and jaundice were the major three symptoms. More serious symptoms were reported in 3 cases series, including hepatic encephalopathy, upper gastrointestinal bleeding, and yellow urine staining. The increase of laboratory indexes, including alanine aminotransferase (ALT), aspartate aminotransferase (AST), gamma-glutamyl transpeptidase (GGT), alkaline phosphatase (ALP), total bilirubin (TBil), and direct bilirubin (DBil), were reported in 16 case series.

Characteristic MRI imaging features

Of all the 510 patients, 250 underwent 256 MRI examinations (12 patients underwent 18 MRI examinations in one study). The scanning sequences included T1WI, T2WI, and multi-phase dynamic enhanced scanning. Among 256 MRI examinations, 8 cases underwent diffusion weighted imaging scans, 22 cases underwent hepatobiliary

Table 1 Quality assessment of 11 case reports

Case No.	Authors	Demographic data	Clinical symptom data	laboratory examination data	Diagnostic workup	Imaging findings
1	Hu <i>et al</i> ^[17]	**	**	**	*	**
2	Kang <i>et al</i> ^[18]	**	**	**	**	**
3	Yan ^[20]	**	**	**	*	**
4	Yoneda <i>et al</i> ^[21]	**	*	*	**	*
5	Kawa <i>et al</i> ^[31]	**	*	**	**	**
6	Mortelé <i>et al</i> ^[8]	**	**	*	**	**
7	van den Bosch <i>et al</i> ^[13]	**	**	**	**	**
8	Marasco <i>et al</i> ^[9]	**	*	*	*	**
9	Liu <i>et al</i> ^[32]	**	*	**	**	*
10	Choi <i>et al</i> ^[28]	**	*	**	**	**
11	Arakawa <i>et al</i> ^[29]	**	*	**	**	**

*: Quality assessment score.

scans, and 39 cases underwent susceptibility weighted imaging (SWI) scans. In all valid imaging data, the main MRI imaging features were heterogeneous signals on T1WI/T2WI, heterogeneous enhancement, and ascites. All characteristic MRI imaging features are shown in Table 6.

DISCUSSION

This article systematically reviewed the current available literature related to the etiologies, clinical symptoms, and MRI imaging findings of SOS. In the West, SOS was mostly secondary to HSCT, while some SOS developed in the process of chemotherapy for hepatic metastatic tumor. However, the toxic effects of some special drugs also resulted in the occurrence of SOS, although they have been rarely reported^[8,9]. In the East, especially in China, SOS was often caused by Tusanqi, a plant containing PA that always be used in the herbal medicines. Ascites, abdominal pain and swelling, and jaundice were the common symptoms. ALT, AST, ALP, GGT, and TBil were the main laboratory indicators for diagnosing liver damage. Heterogeneous signals on T1WI/T2WI, heterogeneous enhancement of liver parenchyma, ascites, hepatomegaly, narrowing and blurring of inferior vena cava (IVC) and three main hepatic veins, edema around the portal vein, and gallbladder wall edema were the most common MRI imaging features of SOS.

Our article presents several advantages. First of all, this is the first systematic review that combined clinical information and MRI imaging features of SOS. Second, English and Chinese databases were retrieved at the same time for ensuring the comprehensiveness of this review. To avoid duplicate articles or data, the rigorous studies screening program was also developed. In addition, we formulated the unique quality evaluation criteria based on the nature of the included literature.

SOS was first reported as an early complication of HSCT in 1979^[10]. The cause of the disease is usually associated with sinusoidal endothelial cell cytotoxicity induced by a series of conditioning treatments prior to HSCT. The overall incidence of SOS is related to the diagnosis criteria and type of transplantation, with an incidence of up to 60%^[11]. Some risk factors for SOS related to HSCT have been identified, including existing liver disease (chronic hepatitis, liver fibrosis, and cirrhosis), prior history of liver radiant examination, and the effects of some drugs used in the process of conditioning^[12]. In addition, Al Jefri *et al*^[4] pointed out that if a patient was too young or too old, or accepted allogeneic transplantation, the possibility of morbidity was greatly increased. In our included literature, van den Bosch *et al*^[13] reported 2 patients who received HSCT due to a history of leukemia. Both of the patients had no history of chronic liver disease, and one of the patients was only 17 years old. However, both of the patients developed severe abdominal pain, hepatomegaly, and ascites approximately 2 wk after receiving HSCT, and the patients who received allogeneic transplantation progressed rapidly to upper gastrointestinal bleeding. Therefore, we believed that the occurrence of these 2 SOS cases is consistent with that mentioned by Al Jefri *et al*^[4].

In recent years, preoperative chemotherapy has been widely used as a primary

Table 2 Quality assessment of 18 case series

Case No.	Authors	Patients enrollment	Demographic data	Clinical symptom data	Laboratory examination data	Diagnostic workup	Imaging findings
1	Chen <i>et al</i> ^[33]	*	**	*	*	**	**
2	Xu ^[34]	*	**	*	*	**	**
3	Ye <i>et al</i> ^[35]	*	**	*	**	**	**
4	Zheng <i>et al</i> ^[36]	*	**	*	*	*	**
5	Ren <i>et al</i> ^[37]	*	**	**	**	**	**
6	Geng <i>et al</i> ^[38]	*	**	*	*	*	**
7	Chen <i>et al</i> ^[39]	*	**	*	*	**	**
8	Zhang <i>et al</i> ^[40]	*	**	*	*	**	**
9	Li <i>et al</i> ^[41]	*	**	*	**	**	**
10	Hu <i>et al</i> ^[42]	*	**	*	*	*	**
11	Li <i>et al</i> ^[43]	*	**	*	*	*	**
12	Li <i>et al</i> ^[44]	*	**	*	**	*	**
13	Yu <i>et al</i> ^[24]	*	**	*	*	*	**
14	Rong ^[45]	*	**	**	*	*	**
15	Pei <i>et al</i> ^[46]	*	**	*	*	**	**
16	Zhou <i>et al</i> ^[47]	*	**	*	*	**	**
17	Guo ^[48]	*	**	*	*	*	**
18	Yang ^[49]	*	**	**	**	*	**

*: Quality assessment score.

means of prolonging the survival rate of patients with liver metastasis from gastrointestinal cancer, especially colorectal cancer^[14,15]. Whereas, the use of several cytotoxic agents has been reported to link with irreversible liver damage^[16]. Oxaliplatin, as an important composition of the modern chemotherapy regimens, has been proven several times in relation to the incidence of SOS^[17-19]. Indeed, out of 13 patients in 11 case reports, 5 patients were related to chemotherapy for liver metastasis from colorectal cancer and gastric adenocarcinoma^[17,18,20,21]. All the patients received oxaliplatin-based adjuvant chemotherapy or S-1 and oxaliplatin (SOX) regimen chemotherapy. Five patients were identified with SOS during the chemotherapy cycle from 4 wk to 11 wk. All the 5 patients had abnormalities in laboratory indicators and moderate to severe splenomegaly. Overman *et al*^[22] have shown that a 50% increase in spleen volume after oxaliplatin chemotherapy can be used as a predictor of SOS. These studies suggested that SOS should be considered if the cancer patient suddenly presented signs of splenomegaly or TBil elevation or persistent thrombocyte decline after a period of chemotherapy.

Furthermore, an animal study revealed that hepatic sinusoidal endothelial cells were equally sensitive to the toxic effects of PAs^[23]. It has been reported that PAs-containing medicinal herbs (Tusanqi) can cause SOS^[7,24]. A systematic review^[7] has demonstrated that Tusanqi is a principal cause of SOS in China and the disease could develop within several days. Moreover, the elevation levels of bilirubin and ALT were significantly associated with poor outcomes. As showed in our study, 465 (93.6%) of the 497 patients were caused by Tusanqi, and these patients were almost Chinese. Most of them used Tusanqi soaked in wine to relieve body pain or to treat traumatic injury, and some others took it as a nutritional supplement. The duration of intake of Tusanqi ranged from 3 d to 4 years. The differences in onset time may be linked to personal physique and dose and mode of the medicine herbs. In addition, we found that patients caused by Tusanqi more likely presented obvious clinical symptoms. This might be related to the mixed ingredients of the herbal medicines, which might contain a variety of toxic ingredients in addition to PAs. However, we were not sure if intaking PAs-containing herbs for multiple doses as a nutritional supplement was associated with the toxic accumulation and severer symptoms.

In view of the limitations of current diagnostic criteria for SOS, more non-invasive diagnosis methods have to be confirmed. Recently, an increasing number of studies have demonstrated that many characteristic imaging features can improve the early diagnostic efficiency for SOS^[25-27]. Through analyzing MRI features of our included cases, we found that heterogeneous signals on T1WI/T2WI, heterogeneous

Table 3 Characteristic information of patients in 11 case reports

No.	Authors	Country	Publication year	Patient No.	Sex (male/female)	Age (average)	Primary disease	Etiology	Time of duration	Diagnostic method
1	Hu <i>et al</i> ^[17]	China	2014	2	(2/0)	71/63	/	Tusanqi	UK	Clinical manifestations + laboratory examination + imaging
2	Kang <i>et al</i> ^[18]	China	2015	1	Female	62	/	Tusanqi	UK	Biopsy
3	Yan ^[20]	China	2015	1	Male	65	Liver cirrhosis	Tusanqi (300g)	UK	Clinical manifestations + laboratory examination + imaging
4	Yoneda <i>et al</i> ^[21]	Japan	2015	1	Female	75	Hepatic metastasis of colonic carcinoma	Preoperative chemotherapy (Pmab + m-FOLFOX6)	6 cycles (preoperative) + 4.5 month (postoperative)	Biopsy
5	Kawa <i>et al</i> ^[31]	Japan	2016	1	Female	40	Rectal cancer underwent high anterior resection and partial liver resection due to liver metastasis	Oxaliplatin-based chemotherapy (mFOLFOX6)	6 mo	Biopsy
6	Mortelé <i>et al</i> ^[8]	USA	2001	1	Male	32	/	"Poppers", a recreational drug used during anal intercourse	UK	Biopsy
7	van den Bosch <i>et al</i> ^[13]	Netherlands	1999	2	(1/1)	17/34	Lymphocytic leukemia/acute myeloid leukemia	Bone marrow transplantation	UK	Percutaneous puncture + histological examination /autopsy
8	Marasco <i>et al</i> ^[9]	UK	2016	1	Male	50	Ulcerative colitis	6-thioguanine	UK	Clinical manifestations + imaging
9	Liu <i>et al</i> ^[32]	China	2017	1	Male	52	Gastric adenocarcinoma	S-1 and oxaliplatin (SOX) regimen	Five cycles	Biopsy
10	Choi <i>et al</i> ^[28]	Korea	2016	1	Female	22	Laparoscopic right hemicolectomy for ascending colon cancer	Oxaliplatin-based adjuvant chemotherapy	Four cycles	Biopsy
11	Arakawa <i>et al</i> ^[29]	Japan	2013	1	Female	40	Low anterior resection for advanced rectal cancer	Oxaliplatin-based chemotherapy	Eight cycles	Biopsy

UK: Unknown.

enhancement of liver parenchyma, ascites, hepatomegaly, narrowing and blurring of intrahepatic IVC and hepatic veins, periportal edema, and gallbladder wall edema were the major MRI features of SOS. Most of the patients presented patchy or diffuse

Table 4 Characteristic information of patients in 18 case series

No.	Authors	Country	Publication year	Patient enrollment	Patient No.	Year range	Sex (male/female)	Age (range, average)	Primary disease	Etiology	Time of duration	Diagnostic method
1	Chen <i>et al</i> ^[33]	China	2016	Retro-spective	8	2006-2013	5/3	21-67, 42	/	Tusanqi	3-18 mo	Biopsy (5) Clinical manifestations + imaging (3)
2	Xu ^[34]	China	2015	Retro-spective	11	2004-2012	9/2	37-65, 49	/	Tusanqi (350-800 g)	15-50 d	Biopsy (2) Clinical manifestations + imaging (9)
3	Ye <i>et al</i> ^[35]	China	2015	Retro-spective	20	2010-2012	1/19	36-76, 51	Trauma or stroke	Tusanqi	10 d-6 mo	Biopsy (12) Clinical manifestations + laboratory examination + imaging (8)
4	Zheng <i>et al</i> ^[36]	China	2015	Retro-spective	4	2012-2014	4/0	45-66	Alcoholic liver cirrhosis, trauma, body pain	Tusanqi (600-1500 g)	1-4 mo	Clinical manifestations + imaging
5	Ren <i>et al</i> ^[37]	China	2017	Retro-spective	239	2010-2017	151/88	15-86 (59.6 ± 10.9)	Trauma, hypertension, extravasated blood, URI	Tusanqi	UK	Biopsy (48), Clinical manifestations + imaging
6	Geng <i>et al</i> ^[38]	China	2009	Retro-spective	4	2007-2008	1/3	42-72, 57	/	Tusanqi	12-60 d	Clinical manifestations
7	Chen <i>et al</i> ^[39]	China	2012	Retro-spective	45	1998-2011	23/22	33-73, 57	Trauma	Tusanqi	2-16 wk	Biopsy (21) Clinical manifestations + laboratory examination + imaging (8)
8	Zhang <i>et al</i> ^[40]	China	2012	Retro-spective	15	2005-2011	12/3	42-65	/	Tusanqi	1-6 mo	Biopsy (6) DSA (1) Clinical manifestations + laboratory examination + MRI
9	Li <i>et al</i> ^[41]	China	2011	Retro-spective	4	2009-2011	2/2	27-63, 35	/	Tusanqi (3), chemotherapy (1)	Tusanqi (1-3 mo)	Biopsy (2) Clinical manifestations + imaging
10	Hu <i>et al</i> ^[42]	China	2011	Retro-spective	5	2006-2011	4/1	40-60	Trauma history (3), health fitness (1)	Tusanqi	≥1 mo	Biopsy (2) Clinical manifestations + imaging

11	Li <i>et al</i> ^[43]	China	2015	Retro-spective	4	2009-2014	3/1	35-61	Myocardial infarction (1)	Tusanqi	/	UK
12	Li <i>et al</i> ^[44]	China	2014	Retro-spective	8	2011-2014	5/3	21-71, 44.9	/	Tusanqi (2) Chemo-therapy or immune suppressive therapy (9)	/	Biopsy
13	Yu <i>et al</i> ^[24]	China	2013	Retro-spective	6	2002-2012	1/5	10-62 (36.5 ± 20.2)	Trauma (5) Irregular menstruation (1)	Tusanqi (200-700 g)	8-30 d	Biopsy
14	Rong ^[45]	China	2015	Retro-spective	51	2009-2015	36/15	20-79	Drinking (14) Hypertension (1) Diabetes (1) TB (1) RA (1)	Tusanqi (27) HSCT (4),	3 d-4 yr	Biopsy (6) Clinical manifestations + imaging
15	Pei <i>et al</i> ^[46]	China	2010	Retro-spective	6	2006-2008	2/4	17-46	/	Tusanqi (5)	30 d	Biopsy (3) Clinical manifestations + imaging
16	Zhou <i>et al</i> ^[47]	Hong Kong, China	2014	Retro-spective	16	2009-2011	12/4	22-72, 55.6	/	Intake of <i>Gynura segetum</i>	UK	Liver transplantation (1) Clinical manifestations
17	Guo ^[48]	China	2015	Retro-spective	12	2013-2014	9/3	45-62, 53	/	Tusanqi	UK	Clinical manifestations + imaging
18	Yang ^[49]	China	2018	Retro-spective	39	2010-2016	9/30	36-74, 59.18 ± 9.36	/	Pyrrolizidine alkaloid (PA)-containing herbals	UK	Clinical manifestations + imaging

UK: Unknown.

abnormal enhancement of liver parenchyma, some were focused on the second hepatic portal and presented “clover”, “claw-shaped”, or irregular enhancement, and a few presented hepatic lobe predominant enhancement. “Clover” and “claw-shaped” types of enhancement were the two distinctive MRI imaging features. This may be related to the opening of small blood vessels around the main hepatic veins resulting from obstruction of the hepatic sinus outflow tract, which resulted in an increase in blood supply. Ascites, periportal edema, and gallbladder wall edema may be associated with blockage of portal blood flow and impaired liver function.

In addition, several studies^[7,20,21] reported that the patients who underwent hepatobiliary scans presented diffuse or reticular low signals in the liver parenchyma. Yoneda *et al*^[21] conducted a correlation analysis between organic anion transporting polypeptides 1B3 (OATP1B3) and function of hepatocytes. The results showed that SOS led to hepatocyte function impairment and the signal in the hepatobiliary phase was related to the degree of hepatocyte injury. In addition, Choi *et al*^[28] and Arakawa *et al*^[29] reported SOS cases of focal hepatic lesions during oxaliplatin chemotherapy, which were misdiagnosed as liver metastases. This result suggested that sometimes the focal hepatic lesions should be considered as the occurrence of SOS, and liver biopsy instead of hepatectomy should be used as the initial examination plan. Furthermore, Guo *et al*^[30] indicated that the lesion areas presenting hypo-intensity on SWI and T2*WI were consistent with the abnormal enhancement in the portal vein phase in enhanced MRI. It may be related to the phenomenon that macrophages phagocytose and decompose red blood cells, and the decomposed red blood cells flow

Table 5 Clinical characteristics of 13 patients in 11 case reports, *n* (%)

Variable	No. of patients with available data	Value
Sex (male/female)	13	7/6
Age, yr	13	47.9
Underlying disease		
None	13	4 (30.8)
Postoperative liver metastasis of advanced colorectal cancer	13	3 (23.1)
Leukemia	13	2 (15.4)
Liver cirrhosis	13	1 (7.7)
Hepatic metastasis of colonic carcinoma	13	1 (7.7)
Gastric adenocarcinoma	13	1 (7.7)
Clinical symptom		
Ascites	13	7 (53.8)
Abdominal swelling	13	4 (30.8)
Pleural effusion	13	4 (30.8)
Hepatomegaly	13	3 (23.1)
Jaundice	13	3 (23.1)
Stomach ache	13	3 (23.1)
Weak	13	3 (23.1)
Lower limbs edema	13	2 (15.4)
Lower limbs lassitude	13	2 (15.4)
Loss of appetite	13	2 (15.4)
Yellow urine	13	2 (15.4)
Oliguria	13	1 (7.7)
Esophageal varices	13	1 (7.7)
PVH	13	1 (7.7)
Etiology		
Chemotherapy	13	5 (38.5)
Tusanqi	13	4 (30.8)
Hematopoietic stem cell transplantation	13	2 (15.4)
"Poppers," a recreational drug used during anal intercourse	13	1 (7.7)
Drug toxicity (6-thioguanine)	13	1 (7.7)
Laboratory index		
ALP, U/L	11	206.4
ALT, U/L	9	836.2
AST, U/L	8	1284.25
GGT, U/L	7	155.42
LDH, U/L	3	5608.33
TBil, $\mu\text{mol/L}$	9	63.11
DBil, $\mu\text{mol/L}$	5	35
Alb, g/L	5	37.52
TBA, g/L	2	27.65
T-CHE, U/L	2	3242
TP, g/L	1	47.7
CA-125, U/mL	1	299.1

PVH: Portal hypertension; ALT: Alanine aminotransferase; AST: Aspartate aminotransferase; ALP: Alkaline phosphatase; GGT: Gamma-glutamyl transpeptidase; TBil: Total bilirubin; DBil: Direct bilirubin; prothrombin time; ALB: Albumin; TBA: Total bile acid.

into the DISSE gap, which produces a large amount of hemosiderin. This result provided a new possibility for the diagnosis of SOS, especially for the patients with renal insufficiency or allergies to contrast agents.

This systematic review had several limitations. First, due to the low incidence of SOS, not enough high-quality literature was included in our study. Second, due to the lack of more complicate data, we were not able to analyze the relationship between MRI features and patient survival prognosis. In addition, some of the included

Table 6 Magnetic resonance imaging features of all 256 examinations, *n* (%)

MRI feature	Number of cases
Heterogeneous signals on T1WI/T2WI	221 (86.3)
Heterogeneous enhancement	189 (73.8)
Ascites	189 (73.8)
Hepatomegaly	167 (65.2)
Narrowing and blurring of intrahepatic IVC	167 (56.6)
Gallbladder wall edema	121 (47.3)
Narrowing of three main hepatic veins	105 (41.1)
Edema around the portal vein, "cuffing"	90 (35.2)
Narrowing and blurring of intrahepatic veins	52 (20.3)
Collateral circulation opens	37 (14.6)
Splenomegaly	32 (12.5)
Narrowing and blurring of portal vein	28 (10.9)
Dilated and twisted small vessels	17 (6.6)
Hypo-intensity on HBP	17 (6.6)
Dilated hepatic arteries	12 (4.7)
"Halo signs" around the hepatic vein and intrahepatic IVC	11 (4.3)
Restricted diffusion	5 (2.0)
Gastrointestinal edema	4 (1.6)
Multiple hyperplasia nodules	2 (0.8)
Caudate lobe enlargement	2 (0.8)
Focal nodules or masses	1 (0.4)
Dilated spleen vein	1 (0.4)

MRI: Magnetic resonance imaging; IVC: Inferior vena cava.

literature was relatively obsolete, and the MRI models and parameters of each center were also different, which may lead to misjudgment of image results due to insufficient understanding of MRI signs.

Summary and outlook

Although with low incidence, SOS still requires clinical attention because of its rapid progression and high mortality. In the West, in addition to being secondary to HSCT, the patients with liver metastasis from colorectal cancer should be highly alert to the occurrence of SOS. Furthermore, the hepatotoxic effects of some special drugs have to be brought to the attention of the public again. In the East, especially in China, while recognizing the efficacy of Chinese herbal medicine, we cannot ignore the potential harm to liver sinusoidal endothelial cells either. Ascites, abdominal pain and swelling, and jaundice are the common symptoms for the diagnosis of SOS. ALT, AST, ALP, GGT, and TBil can be used as predictors of liver function damage induced by SOS. Heterogeneous signals on T1WI/T2WI, heterogeneous enhancement of liver parenchyma, hepatomegaly, narrowing and blurring of intrahepatic IVC and hepatic veins, periportal edema, and gallbladder wall edema are the major MRI features of SOS. In addition, to further improve the non-invasive diagnosis of SOS, more MRI techniques need to be developed and applied, such as hepatobiliary scan of Gd-EOB MRI, SWI, and other functional imaging methods.

ARTICLE HIGHLIGHTS

Research background

Sinusoidal obstruction syndrome (SOS), also referred to as veno-occlusive disease, is a rare liver vascular injury that is highly lethal. It is pathologically characterized by the damage of hepatic sinusoidal endothelial cells, impeded sinusoidal blood flow, congestive sinusoidal dilatation, and perisinusoidal fibrosis. Understanding the epidemiological characteristics and imaging features of SOS is vital for clinical diagnosis and treatment.

Research motivation

Although biopsy is the golden standard for SOS diagnosis, it is invasive and cannot be easily implemented in practice work. Currently, the diagnosis of SOS usually depends on clinical

criteria, such as the Baltimore criteria and the modified Seattle criteria. However, the diagnosis of SOS only based on clinical criteria is lack of high specificity. In recent years, magnetic resonance imaging (MRI) has been increasingly used in the differential diagnosis of SOS and shows a good prospect. Combining clinical information and MRI features of SOS could greatly improve the efficiency of SOS diagnosis.

Research objectives

The main objective of this systematic review is to summarize the major etiologies, clinical symptoms, and MRI features of SOS.

Research methods

Published articles on PubMed, Web of Science, Wanfang Data, China Knowledge Resource Integrated, VIP, and Cochrane Library databases were searched. The search process mainly revolved around the etiologies, common clinical symptoms, and MRI imaging features of SOS. Last search was performed on January 28, 2019.

Research results

In total, 11 case reports and 18 case series were systematically reviewed. Chemotherapy for patients with liver metastasis of colorectal cancer, intake of medicine herbs containing pyrrolidine alkaloids (PAs, *e.g.* Tusanqi), and condition treatment prior to haemopoietic stem cell transplantation were the main etiologies of SOS. Hepatomegaly, ascites, abdominal swelling, and jaundice were the frequent clinical symptoms of SOS. Some laboratory indexes, including alanine aminotransferase, aspartate aminotransferase, alkaline phosphatase, gamma-glutamyl transpeptidase, total bilirubin, and direct bilirubin had varying degrees of elevation. Hepatic parenchyma heterogeneity, ascites, hepatomegaly, narrowing of intrahepatic inferior vena cava and hepatic veins, edema around the portal vein, and gallbladder wall edema were the most common MRI imaging features of SOS.

Research conclusions

Although this systematic review included not enough high-quality publications due to the low incidence of SOS, the findings of this review help clinicians to know about the epidemiological and imaging features of SOS and provide a more reliable and accurate diagnosis of SOS.

Research perspectives

In the future, more high-quality prospective studies need to be conducted. Moreover, to further improve the diagnostic efficiency for SOS, some up-to-date imaging techniques, such as functional MRI, need to be developed and applied, including hepatobiliary scan of Gd-EOB MRI, susceptibility weighted imaging, and other functional imaging methods.

REFERENCES

- Valla DC, Cazals-Hatem D. Sinusoidal obstruction syndrome. *Clin Res Hepatol Gastroenterol* 2016; **40**: 378-385 [PMID: 27038846 DOI: 10.1016/j.clinre.2016.01.006]
- DeLeve LD, Shulman HM, McDonald GB. Toxic injury to hepatic sinusoids: sinusoidal obstruction syndrome (veno-occlusive disease). *Semin Liver Dis* 2002; **22**: 27-42 [PMID: 11928077 DOI: 10.1055/s-2002-23204]
- Coppel JA, Richardson PG, Soiffer R, Martin PL, Kernan NA, Chen A, Guinan E, Vogelsang G, Krishnan A, Giral S, Revta C, Carreau NA, Iacobelli M, Carreras E, Ruutu T, Barbui T, Antin JH, Niederwieser D. Hepatic veno-occlusive disease following stem cell transplantation: incidence, clinical course, and outcome. *Biol Blood Marrow Transplant* 2010; **16**: 157-168 [PMID: 19766729 DOI: 10.1016/j.bbmt.2009.08.024]
- Al Jefri AH, Abujazar H, Al-Ahmari A, Al Rawas A, Al Zahrani Z, Alhejazi A, Bekadja MA, Ibrahim A, Lahoucine M, Ousia S, Bazarbachi A. Veno-occlusive disease/sinusoidal obstruction syndrome after haematopoietic stem cell transplantation: Middle East/North Africa regional consensus on prevention, diagnosis and management. *Bone Marrow Transplant* 2017; **52**: 588-591 [PMID: 27892944 DOI: 10.1038/bmt.2016.300]
- Mohty M, Malard F, Abecassis M, Aerts E, Alaskar AS, Aljurf M, Arat M, Bader P, Baron F, Bazarbachi A, Blaise D, Ciceri F, Corbacioglu S, Dalle JH, Dignan F, Fukuda T, Huynh A, Masszi T, Michallet M, Nagler A, NiChonghaile M, Okamoto S, Pagliuca A, Peters C, Petersen FB, Richardson PG, Ruutu T, Savani BN, Wallhult E, Yakoub-Agha I, Duarte RF, Carreras E. Revised diagnosis and severity criteria for sinusoidal obstruction syndrome/veno-occlusive disease in adult patients: a new classification from the European Society for Blood and Marrow Transplantation. *Bone Marrow Transplant* 2016; **51**: 906-912 [PMID: 27183098 DOI: 10.1038/bmt.2016.130]
- Zhuge Y, Liu Y, Xie W, Zou X, Xu J, Wang J; Chinese Society of Gastroenterology Committee of Hepatobiliary Disease. Expert consensus on the clinical management of pyrrolizidine alkaloid-induced hepatic sinusoidal obstruction syndrome. *J Gastroenterol Hepatol* 2019; **34**: 634-642 [PMID: 30669184 DOI: 10.1111/jgh.14612]
- Wang X, Qi X, Guo X. Tusanqi-Related Sinusoidal Obstruction Syndrome in China: A Systematic Review of the Literatures. *Medicine (Baltimore)* 2015; **94**: e942 [PMID: 26061322 DOI: 10.1097/md.0000000000000942]
- Mortelé KJ, Van Vlierberghe H, Wiesner W, Ros PR. Hepatic veno-occlusive disease: MRI findings. *Abdom Imaging* 2002; **27**: 523-526 [PMID: 12172990 DOI: 10.1007/s00261-001-0097-5]
- Marasco G, Scaoli E, Renzulli M, Colecchia A, Golfieri R, Festi D, Bazzoli F, Digby RJ, Belluzzi A. MRI Patterns in a Case of 6-Thioguanine-Related Hepatic Sinusoidal Obstruction Syndrome. *Am J Gastroenterol* 2016; **111**: 767 [PMID: 27249976 DOI: 10.1038/ajg.2016.210]
- Jacobs P, Miller JL, Uys CJ, Dietrich BE. Fatal veno-occlusive disease of the liver after chemotherapy,

- whole-body irradiation and bone marrow transplantation for refractory acute leukaemia. *S Afr Med J* 1979; **55**: 5-10 [PMID: [371033](#)]
- 11 **Tuncer HH**, Rana N, Milani C, Darko A, Al-Homsi SA. Gastrointestinal and hepatic complications of hematopoietic stem cell transplantation. *World J Gastroenterol* 2012; **18**: 1851-1860 [PMID: [22563164](#) DOI: [10.3748/wjg.v18.i16.1851](#)]
 - 12 **Dignan FL**, Wynn RF, Hadzic N, Karani J, Quaglia A, Pagliuca A, Veys P, Potter MN; Haemato-oncology Task Force of British Committee for Standards in Haematology; British Society for Blood and Marrow Transplantation. BCSH/BSBMT guideline: diagnosis and management of veno-occlusive disease (sinusoidal obstruction syndrome) following haematopoietic stem cell transplantation. *Br J Haematol* 2013; **163**: 444-457 [PMID: [24102514](#) DOI: [10.1111/bjh.12558](#)]
 - 13 **van den Bosch MA**, van Hoe L. MR imaging findings in two patients with hepatic veno-occlusive disease following bone marrow transplantation. *Eur Radiol* 2000; **10**: 1290-1293 [PMID: [10939493](#) DOI: [10.1007/s003300000330](#)]
 - 14 **Zorzi D**, Laurent A, Pawlik TM, Lauwers GY, Vauthey JN, Abdalla EK. Chemotherapy-associated hepatotoxicity and surgery for colorectal liver metastases. *Br J Surg* 2007; **94**: 274-286 [PMID: [17315288](#) DOI: [10.1002/bjs.5719](#)]
 - 15 **Douillard JY**, Cunningham D, Roth AD, Navarro M, James RD, Karasek P, Jandik P, Iveson T, Carmichael J, Alakl M, Gruia G, Awad L, Rougier P. Irinotecan combined with fluorouracil compared with fluorouracil alone as first-line treatment for metastatic colorectal cancer: a multicentre randomised trial. *Lancet* 2000; **355**: 1041-1047 [PMID: [10744089](#)]
 - 16 **Duwe G**, Knitter S, Pesthy S, Beierle AS, Bahra M, Schmelzle M, Schmuck RB, Lohneis P, Raschzok N, Öllinger R, Sinn M, Struecker B, Sauer IM, Pratschke J, Andreou A. Hepatotoxicity following systemic therapy for colorectal liver metastases and the impact of chemotherapy-associated liver injury on outcomes after curative liver resection. *Eur J Surg Oncol* 2017; **43**: 1668-1681 [PMID: [28599872](#) DOI: [10.1016/j.ejso.2017.05.008](#)]
 - 17 **Hu JS**, Xia RM, Zhu GF. MRI in the diagnosis of small hepatic veno-occlusive disease (report of 2 cases and review of literature). *Zhongguo Linchuang Yixue Yingxiang Zazhi* 2014; **25**: 53-55
 - 18 **Kang Z**, Guo H. Veno-occlusive disease: A case report. *Beijing Yixue* 2015; **3**: 301-302 [DOI: [10.15932/j.0253-9713.2015.3.035](#)]
 - 19 **Robinson SM**, Wilson CH, Burt AD, Manas DM, White SA. Chemotherapy-associated liver injury in patients with colorectal liver metastases: a systematic review and meta-analysis. *Ann Surg Oncol* 2012; **19**: 4287-4299 [PMID: [22766981](#) DOI: [10.1245/s10434-012-2438-8](#)]
 - 20 **Yan L**. Clinical analysis of hepatic veno-occlusive disease induced by gynecological cancer: one Case report and review of the literature. *Ann Surg Oncol* 2015; **22**: 100-105 [PMID: [25111111](#) DOI: [10.1245/s10434-015-0503-z](#)]
 - 21 **Yoneda N**, Matsui O, Ikeno H, Inoue D, Yoshida K, Kitao A, Kozaka K, Kobayashi S, Gabata T, Ikeda H, Nakamura K, Ohta T. Correlation between Gd-EOB-DTPA-enhanced MR imaging findings and OATP1B3 expression in chemotherapy-associated sinusoidal obstruction syndrome. *Abdom Imaging* 2015; **40**: 3099-3103 [PMID: [26187715](#) DOI: [10.1007/s00261-015-0503-z](#)]
 - 22 **Overman MJ**, Maru DM, Charnsangavej C, Loyer EM, Wang H, Pathak P, Eng C, Hoff PM, Vauthey JN, Wolff RA, Kopetz S. Oxaliplatin-mediated increase in spleen size as a biomarker for the development of hepatic sinusoidal injury. *J Clin Oncol* 2010; **28**: 2549-2555 [PMID: [20406923](#) DOI: [10.1200/jco.2009.27.5701](#)]
 - 23 **DeLeve LD**, McCuskey RS, Wang X, Hu L, McCuskey MK, Epstein RB, Kanel GC. Characterization of a reproducible rat model of hepatic veno-occlusive disease. *Hepatology* 1999; **29**: 1779-1791 [PMID: [10347121](#) DOI: [10.1002/hep.510290615](#)]
 - 24 **Wang JY**, Gao H. Tusanqi and hepatic sinusoidal obstruction syndrome. *J Dig Dis* 2014; **15**: 105-107 [PMID: [24528632](#) DOI: [10.1111/1751-2980.12112](#)]
 - 25 **Yu S**, Fang Z, Bao Q, Su J, Du R. MRI features of 6 cases of Sinusoidal Obstruction Syndrome. *Zhongguo Yixue Yingxiang Jishu* 2013; **11**: 861-863 [DOI: [10.3969/j.issn.1005-5185.2013.11.018](#)]
 - 26 **Shin NY**, Kim MJ, Lim JS, Park MS, Chung YE, Choi JY, Kim KW, Park YN. Accuracy of gadoteric acid-enhanced magnetic resonance imaging for the diagnosis of sinusoidal obstruction syndrome in patients with chemotherapy-treated colorectal liver metastases. *Eur Radiol* 2012; **22**: 864-871 [PMID: [22108766](#) DOI: [10.1007/s00330-011-2333-x](#)]
 - 27 **Li X**, Yang X, Xu D, Li Q, Kong X, Lu Z, Bai T, Xu K, Ye J, Song Y. Magnetic Resonance Imaging Findings in Patients With Pyrrolizidine Alkaloid-Induced Hepatic Sinusoidal Obstruction Syndrome. *Clin Gastroenterol Hepatol* 2017; **15**: 955-957 [PMID: [28126425](#) DOI: [10.1016/j.cgh.2017.01.009](#)]
 - 28 **Choi JH**, Won YW, Kim HS, Oh YH, Lim S, Kim HJ. Oxaliplatin-induced sinusoidal obstruction syndrome mimicking metastatic colon cancer in the liver. *Oncol Lett* 2016; **11**: 2861-2864 [PMID: [27073565](#) DOI: [10.3892/ol.2016.4286](#)]
 - 29 **Arakawa Y**, Shimada M, Utsunomya T, Imura S, Morine Y, Ikemoto T, Hanaoka J, Sugimoto K, Bando Y. Oxaliplatin-related sinusoidal obstruction syndrome mimicking metastatic liver tumors. *Hepatol Res* 2013; **43**: 685-689 [PMID: [23730707](#) DOI: [10.1111/j.1872-034X.2012.01114.x](#)]
 - 30 **Guo T**, Li X, Yang X, Kong X, Liu H, Bai T, Xu K, Ye J, Song Y. Gadoteric Acid-Enhanced Hepatobiliary-Phase Magnetic Resonance Imaging for Pyrrolizidine Alkaloid-Induced Hepatic Sinusoidal Obstruction Syndrome and Association with Liver Function. *Sci Rep* 2019; **9**: 1231 [PMID: [30718698](#) DOI: [10.1038/s41598-018-37775-1](#)]
 - 31 **Kawai T**, Yamazaki S, Iwama A, Higaki T, Sugitani M, Takayama T. Focal Sinusoidal Obstruction Syndrome Caused by Oxaliplatin-Induced Chemotherapy: A Case Report. *Hepat Mon* 2016; **16**: e37572 [PMID: [27822263](#) DOI: [10.5812/hepatmon.37572](#)]
 - 32 **Liu F**, Cao X, Ye J, Pan X, Kan X, Song Y. Oxaliplatin-induced hepatic sinusoidal obstruction syndrome in a patient with gastric cancer: A case report. *Mol Clin Oncol* 2018; **8**: 453-456 [PMID: [29468059](#) DOI: [10.3892/mco.2017.1540](#)]
 - 33 **Chen ZH**, Tang D, Gao ZF, Zhang YS. MRI analysis of 8 cases of acute hepatic sinus obstruction syndrome caused by "tusanqi". *Zhongguo Xiangcun Yiyao* 2016; **23**: 57-58 [DOI: [10.3969/j.issn.1006-5180.2016.07.033](#)]
 - 34 **Xu XL**. Diagnostic value of low field MRI in hepatic venous occlusion caused by "tusanqi". *Zhejiang Linchuang Yixue* 2015; **7**: 1194-1195
 - 35 **Ye TH**, Liang HM, Ye J, Zheng CS, Xiong B, Pan F, Xia XW. CT and MR findings of hepatic sinusoidal obstruction syndrome caused by Gynura segetum. *Zhonghua Jieru Fangshexue Dianzi Zazhi* 2015; **3**: 27-33 [DOI: [10.3877/cma.j.issn.2095-5782.2015.01.007](#)]
 - 36 **Zheng WK**, Wang MR. Clinical characteristic analysis of hepatic veno-occlusive disease induced by

- gynura segetum in patients with alcoholic liver cirrhosis. *Zhongguo Ganzangbing Zazhi (Dianzi Ban)* 2015; **1**: 51-54 [DOI: [10.3969/j.issn.1674-7380.2015.01.18](https://doi.org/10.3969/j.issn.1674-7380.2015.01.18)]
- 37 **Ren XF**, Zhu Ge YZ, Chen SY, Yang L, Jiang HX, Zhang XL, Ma X, Xie WF, Liu YM, Xu JM; Gastroenterology HCGoCSO. Gynura segetum-related hepatic sinusoidal obstruction syndrome: a national multicenter clinical study. *Zhonghua Xiaohua Zazhi* 2017; **37**: 523-529 [DOI: [10.3760/cma.j.issn.0254-1432.2017.08.004](https://doi.org/10.3760/cma.j.issn.0254-1432.2017.08.004)]
- 38 **Geng CZ**, Gao Y, Fan SF. MRI of hepatic sinusoidal obstruction syndrome caused by Gynura segetum. *Zhonghua Fangshexue Zazhi* 2009; **43**: 312-314 [DOI: [10.3760/cma.j.issn.1005-1201.2009.03.020](https://doi.org/10.3760/cma.j.issn.1005-1201.2009.03.020)]
- 39 **Chen HZ**, Shao H, Geng CZ, Lv JS, Zhang ZQ. Value of liver imaging scan in diagnosing hepatic veno-occlusive disease caused by Sedum Aizoon. *Linchuang Gandanbing Zazhi* 2012; **28**: 376-379
- 40 **Zhang LX**, Wu JP, Xu H, Zu MH, Jiao XD, Zhou JH, Bao ZW, Liu JH. The diagnosis and differential diagnosis of hepatic veno-occlusive disease. *Jieru Fangshexue Zazhi* 2012; **21**: 987-990 [DOI: [10.3969/j.issn.1008-794X.2012.12.005](https://doi.org/10.3969/j.issn.1008-794X.2012.12.005)]
- 41 **Li YF**, Li HJ. Imaging findings in four patients with hepatic veno-occlusive disease. *Cigongzhen Chengxiang* 2011; **2**: 416-419 [DOI: [10.3969/j.issn.1674-8034.2011.06.005](https://doi.org/10.3969/j.issn.1674-8034.2011.06.005)]
- 42 **Hu Z**, Zhang P, Yao HQ. The Value of CT and Low Field MRI in the Diagnosis of Hepatic Veno-occlusive Disease (5 cases report and literature review). *Zhongguo CT He MRI Zazhi* 2011; **46**: 11-12, 24 [DOI: [10.3969/j.issn.1672-5131.2011.06.004](https://doi.org/10.3969/j.issn.1672-5131.2011.06.004)]
- 43 **Li YB**, Gao XM, Chen JL. MRI findings of Hepatic Veno-occlusive Disease. *Zhengzhou Daxue Xuebao (Yixue Ban)* 2015; **50**: 289-291, 292 [DOI: [10.13705/j.issn.1671-6825.2015.02.039](https://doi.org/10.13705/j.issn.1671-6825.2015.02.039)]
- 44 **Li C**, Xu K, Hou JX. The Differential Diagnosis of BCS (type II) and Hepatic Sinusoidal Obstruction Syndrome by CE-MRA. *Zhongguo CT He MRI Zazhi* 2014; **49**: 95-98 [DOI: [10.3969/j.issn.1672-5131.2014.08.31](https://doi.org/10.3969/j.issn.1672-5131.2014.08.31)]
- 45 **Rong XX**. Clinical features of Hepatic sinusoidal obstruction syndrome and progress in diagnosis and therapy: analysis of 51 cases. M.Sc. Thesis, Huazhong University of Science and Technology. 2015
- 46 **Pei YG**, Hu DY, Shen YQ, Wang QX, Hu LW. The value of MSCT and MRI in the diagnosis of hepatic veno-occlusive disease. *Zhonghua Ganbingxue Zazhi* 2010; **18**: 150-152 [DOI: [10.3760/cma.j.issn.1007-3418.2010.02.018](https://doi.org/10.3760/cma.j.issn.1007-3418.2010.02.018)]
- 47 **Zhou H**, Wang YX, Lou HY, Xu XJ, Zhang MM. Hepatic sinusoidal obstruction syndrome caused by herbal medicine: CT and MRI features. *Korean J Radiol* 2014; **15**: 218-225 [PMID: [24643319](https://pubmed.ncbi.nlm.nih.gov/24643319/)] DOI: [10.3348/kjr.2014.15.2.218](https://doi.org/10.3348/kjr.2014.15.2.218)]
- 48 **Guo TT**. Additional value in the diagnosis of hepatic diseases clinical researches based on Gadoteric Acid-Enhanced Magnetic Resonance Imaging. M.Sc. Thesis, Huazhong University of Science and Technology. 2015
- 49 **Yang XQ**. Magnetic Resonance Imaging Features in Pyrrolizidine Alkaloid-induced Hepatic Sinusoidal Obstruction Syndrome. M.Sc. Thesis, Huazhong University of Science and Technology. 2018



Published By Baishideng Publishing Group Inc
7041 Koll Center Parkway, Suite 160, Pleasanton, CA 94566, USA
Telephone: +1-925-2238242
E-mail: bpgoffice@wjgnet.com
Help Desk: <https://www.f6publishing.com/helpdesk>
<https://www.wjgnet.com>

