

World Journal of *Clinical Cases*

World J Clin Cases 2019 September 6; 7(17): 2413-2657



**MINIREVIEWS**

- 2413** Multifocal G1-G2 gastric neuroendocrine tumors: Differentiating between Type I, II and III, a clinicopathologic review
Algashaamy K, Garcia-Buitrago M
- 2420** Attention deficit hyperactivity disorder and comorbidity: A review of literature
Gnanavel S, Sharma P, Kaushal P, Hussain S

ORIGINAL ARTICLE**Case Control Study**

- 2427** Dietary manipulation and testosterone replacement therapy may explain changes in body composition after spinal cord injury: A retrospective case report
Gorgey AS, Lester RM, Ghatas MP, Sistrun SN, Lavis T

Retrospective Study

- 2438** Risk factors, clinical features, and short-term prognosis of spontaneous fungal peritonitis in cirrhosis: A matched case-control study
Huang CH, Pang LT, Xu LC, Ge TT, Xu QM, Chen Z
- 2450** Incidence of portal vein thrombosis after splenectomy and its influence on transjugular intrahepatic portosystemic shunt stent patency
Dong F, Luo SH, Zheng LJ, Chu JG, Huang H, Zhang XQ, Yao KC

Observational Study

- 2463** Multiplex gene expression profile in inflamed mucosa of patients with Crohn's disease ileal localization: A pilot study
Giudici F, Lombardelli L, Russo E, Cavalli T, Zambonin D, Logiodice F, Kullolli O, Giusti L, Bargellini T, Fazi M, Biancone L, Scaringi S, Clemente AM, Perissi E, Delfino G, Torcia MG, Ficari F, Tonelli F, Piccinni MP, Malentacchi C

Prospective Study

- 2477** Analysis of the postoperative hemostatic profile of colorectal cancer patients subjected to liver metastasis resection surgery
Perez Navarro G, Pascual Bellosta AM, Ortega Lucea SM, Serradilla Martín M, Ramirez Rodriguez JM, Martinez Ubieta J

SYSTEMATIC REVIEW

- 2487** Systematic review of ablative therapy for the treatment of renal allograft neoplasms
Favi E, Raison N, Ambrogi F, Delbue S, Clementi MC, Lamperti L, Perego M, Bischeri M, Ferraresso M

CASE REPORT

- 2505** Subcutaneous sarcoidosis of the upper and lower extremities: A case report and review of the literature
Mehrzaad R, Festa J, Bhatt R
- 2513** Atypical cutaneous lesions in advanced-stage Hodgkin lymphoma: A case report
Massaro F, Ferrari A, Zendri E, Zanelli M, Merli F
- 2519** Characteristics of multiple nodules in a patient with pulmonary Langerhans cell histiocytosis: A case report
Kanaji N, Tokunaga Y, Ishikawa R, Watanabe N, Kadowaki N
- 2526** Impact of continuous local lavage on pancreatic juice-related postoperative complications: Three case reports
Hori T, Ogawa K, Yamamoto H, Harada H, Matsumura K, Yamamoto M, Yamada M, Yazawa T, Kuriyama K, Tani M, Yasukawa D, Kamada Y, Aisu Y, Tani R, Aoyama R, Nakayama S, Sasaki Y, Nishimoto K, Zaima M
- 2536** Adult intussusception caused by colonic anisakis: A case report
Choi YI, Park DK, Cho HY, Choi SJ, Chung JW, Kim KO, Kwon KA, Kim YJ
- 2542** Robotic-assisted resection of ovarian tumors in children: A case report
Xie XX, Wang N, Wang ZH, Zhu YY, Wang JR, Wang XQ
- 2549** Synovial sarcoma in the plantar region: A case report and literature review
Gao J, Yuan YS, Liu T, Lv HR, Xu HL
- 2556** Severe serous cavity bleeding caused by acquired factor V deficiency associated with lymphatic leakage in a hemodialysis patient: A case report
Zhao WB, Chen YR, Luo D, Lin HC, Long B, Wu ZY, Peng H
- 2562** Supermicrosurgery in fingertip defects-split tibial flap of the second toe to reconstruct multiple fingertip defects: A case report
Wang KL, Zhang ZQ, Buckwalter JA, Yang Y
- 2567** Ultrasound-guided fascia iliaca compartment block combined with general anesthesia for amputation in an acute myocardial infarction patient after percutaneous coronary intervention: A case report
Ling C, Liu XQ, Li YQ, Wen XJ, Hu XD, Yang K
- 2573** Rare spontaneous intrahepatic portosystemic shunt in hepatitis B-induced cirrhosis: A case report
Tan YW, Sheng JH, Tan HY, Sun L, Yin YM
- 2580** Imaging of mixed epithelial and stromal tumor of the kidney: A case report and review of the literature
Ye J, Xu Q, Zheng J, Wang SA, Wu YW, Cai JH, Yuan H
- 2587** Allogenic tooth transplantation using 3D printing: A case report and review of the literature
Xu HD, Miron RJ, Zhang XX, Zhang YF

- 2597** Fecal microbiota transplantation as an effective initial therapy for pancreatitis complicated with severe *Clostridium difficile* infection: A case report
Hu Y, Xiao HY, He C, Lv NH, Zhu L
- 2605** Organ-associated pseudosarcomatous myofibroblastic proliferation with ossification in the lower pole of the kidney mimicking renal pelvic carcinoma: A case report
Zhai TY, Luo BJ, Jia ZK, Zhang ZG, Li X, Li H, Yang JJ
- 2611** Treating aplasia cutis congenita in a newborn with the combination of ionic silver dressing and moist exposed burn ointment: A case report
Lei GF, Zhang JP, Wang XB, You XL, Gao JY, Li XM, Chen ML, Ning XQ, Sun JL
- 2617** Cause of postprandial vomiting - a giant retroperitoneal ganglioneuroma enclosing large blood vessels: A case report
Zheng X, Luo L, Han FG
- 2623** Carcinoma ex pleomorphic adenoma of the trachea: A case report
Gao HX, Li Q, Chang WL, Zhang YL, Wang XZ, Zou XX
- 2630** Wilson disease associated with immune thrombocytopenia: A case report and review of the literature
Ma TJ, Sun GL, Yao F, Yang ZL
- 2637** Calcifying fibrous tumor of the mediastinum: A case report
Qi DJ, Zhang QF
- 2644** Brachiocephalic artery stenting through the carotid artery: A case report and review of the literature
Xu F, Wang F, Liu YS
- 2652** An extremely rare pedunculated lipoma of the hypopharynx: A case report
Sun Q, Zhang CL, Liu ZH

ABOUT COVER

Editorial Board Member of *World Journal of Clinical Cases*, Marianna Luongo, MD, Doctor, Surgeon, Department of Neurosurgery, Azienda Ospedaliera Regionale San Carlo, Potenza 85100, Italy

AIMS AND SCOPE

The primary aim of the *World Journal of Clinical Cases (WJCC)* is to provide scholars and readers from various fields of clinical medicine with a platform to publish high-quality clinical research articles and communicate their research findings online.

The *WJCC* mainly publishes case reports, case series, research results and findings in the field of clinical medicine covering a wide range of topics including diagnostic, therapeutic, and preventive modalities.

INDEXING/ABSTRACTING

The *WJCC* is now indexed in PubMed, PubMed Central, Science Citation Index Expanded (also known as SciSearch®), and Journal Citation Reports/Science Edition. The 2019 Edition of Journal Citation Reports cites the 2018 impact factor for *WJCC* as 1.153 (5-year impact factor: N/A), ranking *WJCC* as 99 among 160 journals in Medicine, General and Internal (quartile in category Q3).

RESPONSIBLE EDITORS FOR THIS ISSUE

Responsible Electronic Editor: *Yan-Xia Xing*

Proofing Production Department Director: *Yun-Xiaojian Wu*

NAME OF JOURNAL

World Journal of Clinical Cases

ISSN

ISSN 2307-8960 (online)

LAUNCH DATE

April 16, 2013

FREQUENCY

Semimonthly

EDITORS-IN-CHIEF

Dennis A Bloomfield, Bao-Gan Peng, Sandro Vento

EDITORIAL BOARD MEMBERS

<https://www.wjgnet.com/2307-8960/editorialboard.htm>

EDITORIAL OFFICE

Jin-Lei Wang, Director

PUBLICATION DATE

September 6, 2019

COPYRIGHT

© 2019 Baishideng Publishing Group Inc

INSTRUCTIONS TO AUTHORS

<https://www.wjgnet.com/bpg/gerinfo/204>

GUIDELINES FOR ETHICS DOCUMENTS

<https://www.wjgnet.com/bpg/GerInfo/287>

GUIDELINES FOR NON-NATIVE SPEAKERS OF ENGLISH

<https://www.wjgnet.com/bpg/gerinfo/240>

PUBLICATION MISCONDUCT

<https://www.wjgnet.com/bpg/gerinfo/208>

ARTICLE PROCESSING CHARGE

<https://www.wjgnet.com/bpg/gerinfo/242>

STEPS FOR SUBMITTING MANUSCRIPTS

<https://www.wjgnet.com/bpg/GerInfo/239>

ONLINE SUBMISSION

<https://www.f6publishing.com>

Calcifying fibrous tumor of the mediastinum: A case report

Dian-Jun Qi, Qing-Fu Zhang

ORCID number: Dian-Jun Qi (0000-0003-0468-1651); Qing-Fu Zhang (0000-0002-9891-1296).

Author contributions: Qi DJ and Zhang QF conceived the study; Qi DJ searched the published articles, analyzed the data, and wrote the manuscript; Zhang QF reviewed and confirmed the final version of the manuscript and provided funding.

Supported by Natural Science Foundation of Liaoning Province in China, No. 81572621 and No. 2019-MS-370.

Informed consent statement: Informed written consent was obtained from the patient for publication of this report and any accompanying images.

Conflict-of-interest statement: The authors declare that they have no conflicts of interest.

Open-Access: This article is an open-access article which was selected by an in-house editor and fully peer-reviewed by external reviewers. It is distributed in accordance with the Creative Commons Attribution Non Commercial (CC BY-NC 4.0) license, which permits others to distribute, remix, adapt, build upon this work non-commercially, and license their derivative works on different terms, provided the original work is properly cited and the use is non-commercial. See: <http://creativecommons.org/licenses/by-nc/4.0/>

Manuscript source: Unsolicited Manuscript

Received: April 19, 2019

Peer-review started: April 22, 2019

Dian-Jun Qi, Department of General Practice, the First Affiliated Hospital of China Medical University, Shenyang 110001, Liaoning Province, China

Qing-Fu Zhang, Department of Pathology, the First Affiliated Hospital and College of Basic Medical Sciences of China Medical University, Shenyang 110001, Liaoning Province, China

Corresponding author: Qing-Fu Zhang, MD, Associate Professor, Department of Pathology, the First Affiliated Hospital and College of Basic Medical Sciences of China Medical University, No. 155, Nanjing North Street, Heping District, Shenyang 110001, Liaoning Province, China. qfzhang@cmu.edu.cn

Telephone: +86-24-83282946

Fax: +86-24-83282946

Abstract

BACKGROUND

Calcifying fibrous tumor (CFT) is a rare benign mesenchymal tumor that often occurs in deep soft tissue of children and young adults. CFT rarely occurs in the mediastinum.

CASE SUMMARY

In this paper, we describe a 31-year-old male patient with CFT in the mediastinum. The patient did not have any symptoms, and the posterior mediastinal lesion was unintentionally found during routine re-examination of thyroid cancer. The tumor had no adhesion to the surrounding tissue and was successfully and completely removed. Pathology showed a large amount of collagen-rich fibrous connective tissue. There was scattered dystrophic calcification and gravel in the fibrous tissue and a small amount of lymphocyte and plasma cell infiltration and lymphoid follicle formation in the interstitial fluid. In addition, findings showed 20 IgG4+ plasma cells per high-powered field of the diseased tissue, an IgG4+/IgG ratio of about 20%, and normal serum IgG4 levels. The final diagnosis was CFT of the mediastinum (CFTM). No evidence of tumor recurrence was observed by computed tomography at 3 mo after surgery.

CONCLUSION

IgG4+ plasma cell enlargement may occur in CFTM, but clinical manifestations and serological tests suggest that it is not IgG4-related disease. We speculate that it may be an independent tumor subtype.

Key words: Calcifying fibrous tumor; Mediastinum; IgG4-related diseases; Case report

©The Author(s) 2019. Published by Baishideng Publishing Group Inc. All rights reserved.

First decision: June 12, 2019
Revised: June 27, 2019
Accepted: July 20, 2019
Article in press: July 20, 2019
Published online: September 6, 2019

P-Reviewer: Movahed A
S-Editor: Cui LJ
L-Editor: Wang TQ
E-Editor: Zhou BX



Core tip: Calcifying fibrous tumor of the mediastinum (CFTM) is a rare benign mesenchymal tumor that often occurs in children and young adults. Calcifying fibrous tumor rarely occurs in the mediastinum. Histological examination is the most important basis for diagnosis. Surgical resection is currently the primary means of treatment. There are no reports of recurrence of CFTM.

Citation: Qi DJ, Zhang QF. Calcifying fibrous tumor of the mediastinum: A case report. *World J Clin Cases* 2019; 7(17): 2637-2643
URL: <https://www.wjnet.com/2307-8960/full/v7/i17/2637.htm>
DOI: <https://dx.doi.org/10.12998/wjcc.v7.i17.2637>

INTRODUCTION

Calcifying fibrous tumor (CFT) is formerly called calcifying fibrous pseudotumor (CFP) and childhood fibrous tumor with psammoma bodies^[1,2]. CFT often occurs in children and adolescents^[2], with an average age of incidence of about 34 years^[3]. It is slightly more predominant in female patients, with a male to female ratio of 1:1.27^[3]. To the best of our knowledge, no deaths from CFT have been reported in the international literature, thus CFT *per se* is a benign mesenchymal tumors; nonetheless, 10% of cases recur after resection^[3]. The etiology of CFT is unclear and may be related to myofibroblastic tumors, genetic and embryologic factors, and trauma^[3]. The occurrence of CFT is rare, with only slightly more than 100 cases reported in the international literature as of 2018^[2,3]. The most common locations of CFT include the stomach, small intestine, pleura, peritoneum, and mesentery, but it may occasionally be found in other places such as the heart and maxilla^[3-5]; in particular, there are just nine reports of CFT in the mediastinum (CFTM)^[6-13].

CASE PRESENTATION

Chief complaints and history of present illness

A 31-year-old male patient underwent thyroidectomy for thyroid cancer six months previously. A postoperative computed tomography (CT) examination revealed an oval mass in the posterior mediastinum. The patient had no symptoms such as cough, pain, or difficulty breathing.

History of past illness

Six months previously, the patient was diagnosed with thyroid cancer and underwent thyroidectomy.

Physical examination

No meaningful positive results were noted in the physical examination, except for the thyroid incision in the neck.

Laboratory examinations

Serum levels of tumor markers (α -fetoprotein, β -human chorionic gonadotrophin, and carcinoembryonic antigen) were normal. Serum IgG4 levels, erythrocyte sedimentation rate, rheumatoid factor, and anti-streptolysin and anti-nuclear antibodies were normal.

Imaging examinations

Chest CT examination revealed an oval tumor in the right posterior mediastinum, close to the spine; the tumor was of uniform density with a clear boundary and measured about 4.5 × 3.0 cm. The CT value was about 57 HU, and the enhanced CT value was about 113 HU (Figure 1). No tumor metastasis was detected on lung radiography, head CT, bone scan, or abdominal ultrasonography. The patient did not have a chest CT scan prior to the first surgery for thyroid cancer.

TREATMENT

Intraoperative exploration revealed that the oval mass was located in the right lower

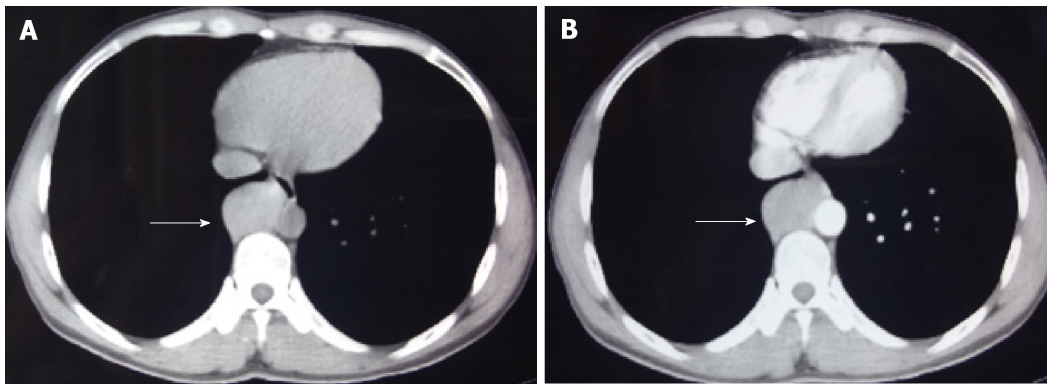


Figure 1 Chest computed tomography. The oval tumor (shown by the arrows) was located on the lateral wall of the abdominal aortic artery, with uniform density and a size of about 4.5 cm × 3.0 cm. The boundary with surrounding tissues is clear. The computed tomography (CT) value of the flat scan is about 57 HU (A), and the enhanced CT value is about 113 HU (B).

posterior mediastinum, was adjacent to T7–T9 and the descending aorta, and had no adhesion to the surrounding tissue. After the vessel was processed, the tumor was completely removed. The resected tumor was 5.5 cm × 3.5 cm × 2.5 cm in size and firm; the cut surface was grayish white.

Histological manifestations are as follows. Hematoxylin and eosin staining showed a large amount of collagenous fibrous connective tissue. There was scattered dystrophic calcification and boulder formation in the fibrous tissue. A small amount of lymphocytes and plasma cells had infiltrated the interstitial space, and lymphoid follicle formation was observed locally at 40× magnification (Figure 2A and Figure 2B).

Immunohistochemical examination showed that the tumor cells expressed CD99 and CD38, thus revealing the presence of plasma cells. The remaining immunohistochemical findings were EMA (–), SOX-10 (–), S100 (–), CD34 (–), SMA (–), ALK 1 (–), FXIIIa (–), and beta-catenin (–), and the Ki-67 proliferation index was about 5%. There were 20 IgG4+ plasma cells per high-powered field (HPF) and an IgG4+/IgG ratio of about 20%. The patient recovered smoothly after surgery and was discharged three days later. He did not receive radiotherapy or chemotherapy.

FINAL DIAGNOSIS

The final diagnosis of the presented case was CFTM.

OUTCOME AND FOLLOW-UP

The patient was followed 4 mo after surgery. The incision healed well, and there was no discomfort. Chest CT findings showed no tumor recurrence.

DISCUSSION

Including the present case, there are ten reported cases of CFTM, with a male to female ratio of 1.5 (six females and four males); this is slightly lower than the ratio of male to female in CFT (1:1.27)^[3]. The age range for CFTM is 8–54 years, with an average of 31.3 years; this is slightly lower than the average age of CFT (about 34 years old)^[3]. Six patients had no symptoms, and masses were found during a regular radiological examination or a review of a chest radiographic test^[7,9,11,13]. Regarding symptoms, three patients had persistent cough^[6,10,12], one patient had sternal discomfort^[6], and one patient had hemoptysis and weight loss^[10]. Regarding location, seven tumors occurred in the anterior mediastinum, and three occurred in the posterior mediastinum^[6–13]. Most CFTMs were single tumors, and only one case exhibited multiple tumors^[10]. Most CFTMs had clear boundaries with the surrounding tissues, and only two cases invaded the surrounding tissues, including the vein and thoracic duct^[11,13]. Tumors were generally oval, and the longest diameter of a single tumor ranged from 4–11 cm^[6,11]. The longest diameter of multiple tumors was less than 2 cm^[10].

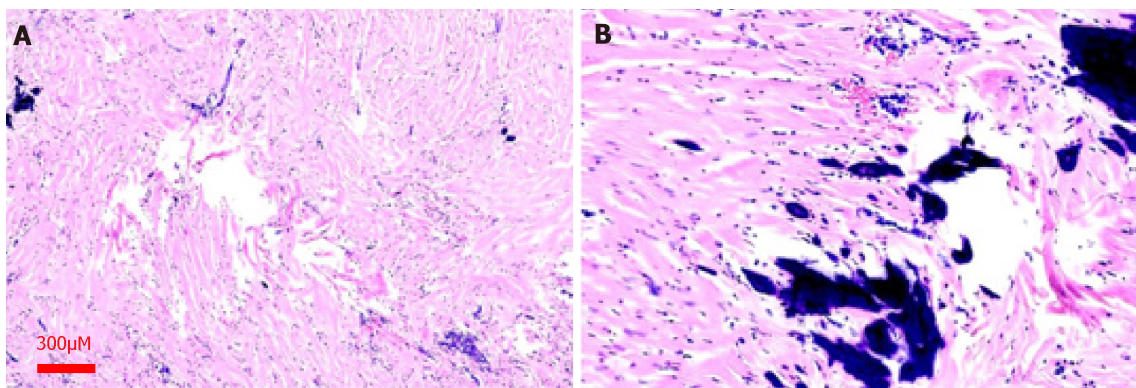


Figure 2 Hematoxylin and eosin staining. A: Tumor tissue consists of a large number of collagen fibrous connective tissue. The fibrous tissue can be seen to have scattered calcified foci. The interstitium is infiltrated by a small number of lymphocytes and plasma cells. The formation of lymphatic follicles is locally visible (magnification, $\times 40$); B: Image shows dystrophic calcifications and gravel formation (magnification, $\times 100$).

The diagnosis of CFTM has the following characteristics. First, CT shows isolated or multiple solid soft tissue tumors with a clear boundary^[10], and the CT signal of the tumor is slightly enhanced after contrast injection. Some tumors show calcification on CT^[13], whereas others have no significant calcification. Second, gross examination shows an oval tumor, with the longest diameter of 3-11 cm, a clear boundary, and an incomplete capsule. The cut surface is grayish-white, solid, and hard and could be accompanied by gritty and scattered yellowish lesion. Third, microscopic histological features include aberrant hyalinized collagen, fibrotic proliferation, lymphoplasmacytic infiltration, and psammomatous or dystrophic calcification^[2,6]. Immunohistochemical spindle cells are positive for vimentin, CD10, FXIIIa, and occasionally CD34; they are negative for actin, desmin, S-100, NF, CK, CD31, and ALK1. To date, there are no specific immunohistochemical or genetic ectopic abnormalities that have been discovered in CFTM.

CFTM needs to be differentiated from other pleural intrapulmonary lesions such as solitary fibrous tumor (SFT), inflammatory myofibroblastic tumor (IMT), fibromatosis, and sclerosing thymoma. First, for SFT, there is a morphological feature that contains collagen fibers of varying thickness and shape; these can be keloid-like and resemble CFT. However, SFT can alternate between cell-poor and cell-rich regions. The spindle-shaped nuclei are vacuolated, are diffusely positive for CD34 and STAT6, and do not contain widely distributed gravel or dystrophic calcification. Second, for IMT, there is a late histologically visible scar-like structure, which is rich in plate-shaped collagen and exhibits low cell density and a small amount of plasma cell infiltration; however, IMT occasionally shows gravel and coarse calcification as well as proliferating myofibroblasts with hyaline-denaturing, cell-free collagen. Immunohistochemical staining of the proliferating fibroblasts shows diffusely actin-positive (50%) and ALK1-positive (50%) spindle cells; in contrast, CFT is actin-negative and diffusely FVIII-positive^[8]. Third, regarding fibromatosis, characteristics include an unclear tumor mass, invasive growth, no capsule, frequent invasion of adjacent tissues, and presence in the muscle, aponeurosis, and deep fascia. Microscopic examination shows bundles of fibroblasts in the tumor. Calcification is rare, and β -catenin is positive. Fourth, in sclerosing thymoma, the interstitium has rich and transparent degeneration-like collagen similar to CFT, but contains epithelial cells and lymphocytes and is positive for epithelial markers.

The pathogenesis of CFT remains unclear. It was previously thought that part of the CFT was late stage sclerosis of IMT, but many scholars objected to it on the grounds that ALK-1 expression in the two lesions was different^[8,9]. So far, there has been no molecular evidence that CFT is clonal^[13] (Table 1), and there is no evidence of genetic dislocation in CFT. The pathological changes of CFT and IgG4-related diseases (IgG4-RD) are similar, and in recent years, some CFT cases have been found to have IgG4+ plasma cells and observable transparent vascular cavity calcification in the CFT lesion site^[14,15]; accordingly, it has been considered that vascular lumen calcification in CFT results from occlusive vasculitis^[16]. Therefore, it is speculated that CFT is related to IgG4-RD and that CFT may be a stage of development for IgG4-RD or an undiscovered IgG4-RD^[17]. A study^[17] reported one case of CFT in the ileum in which the lesion site showed 122 IgG+ plasma cells/HPF, of which 69 were IgG4+ pulp cells (56.56% of IgG+ plasma cells). Prochaska *et al*^[18] reported one case of adrenal CFT, with an average of 183 IgG+ and 11 IgG4+ plasma cells in the lesion at high magnification. Zhang *et al*^[15] reported one case of gastric CFT, with 62 IgG4+ plasma

cells in the lesion at high magnification; IgG4+ cells comprised 41% of IgG+ cells. Due to the current low number of cases and insufficient evidence, it is not clear whether the recurrence of cases is related to IgG4 levels and the effectiveness of the application of hormones or rituximab in treatment. As a result, the relationship between CFT and IgG4-RD needs further study. In addition, the report summarizes six other cases of IgG4-related CFT.

The present case was also been found to have about 20 IgG4+ plasma cells per HPF in the lesion tissue, with IgG4+ comprising 20% of IgG+ cells; however, we do not believe that the case can be diagnosed as IgG4-RD, mainly based on the following reasons. First, the patient was relatively young, and the site of the disease was not an immune-related organ. Second, the patient's serum was IgG4-negative, and there were no abnormalities in erythrocyte sedimentation rate, rheumatoid factor, anti-Streptococcus hemolysin, or anti-nuclear antibody. Third, the ratio of the total number of IgG4+ plasma cells to IgG+ plasma cells under the microscope was less than 40%. Fourth, no other physiological system was affected. This is consistent with CFT, which appears to be a benign tumor with a main treatment method of complete surgical resection^[11]. Moreover, in a few cases, CFT can recur, and the recurrent lesion shows the same pathological morphology as the primary lesion^[14]. In the ten published cases of CFTM, none exhibited recurrence, although this may be related to the small sample size and short follow-up time^[19].

CONCLUSION

This article reports a case of CFTM. In some cases, CFT may have an increase in IgG4+ plasma cells and a cross-sectional histomorphology. However, it lacks the systematic clinical manifestations and serological manifestations of IgG4-RD. Clinicians should be vigilant not to misdiagnose it as IgG4-RD based on a clinical diagnosis.

Table 1 Characteristics of ten cases of calcifying fibrous tumor of mediastinum

Ref	Year	Age/sex	Symptoms duration	Localization	Gross examination	Treatment	Follow-up
Dumont <i>et al</i> ^[6]	1997	23/F	Cough with retrosternal discomfort	Anterior mediastinum	Firm, gray-white, homogeneous, and well circumscribed, non-encapsulated, 11 × 8 × 5 cm, 235 g	OP	Alive, NED after 18 mo follow-up
Jeong <i>et al</i> ^[7]	1997	54/F	-	Posterior mediastinum	8.5 × 6 × 5 cm, 320 g, clear boundary, grayish white, scattered in light, yellow specks	OP	Alive, NED after 49 mo follow-up
Sigel <i>et al</i> ^[8]	2001	37/F	NA	Anterior mediastinum	7.0 cm	NA	NA
Nascimento <i>et al</i> ^[9]	2002	27/M	-	Posterior mediastinum	7 cm	OP	NA
Nascimento <i>et al</i> ^[9]	2002	31/F	-	Anterior mediastinum	5.5 cm	OP	NA
Sleigh <i>et al</i> ^[10]	2010	22/F	Persistent cough, hemoptysis, weight loss	Anterior mediastinum and pleura	Circular mass, about 4.7 × 3.3 cm, clear boundary, uncoated film, gray-white; bilateral pleural nodules, 2–4.8 cm or smaller in diameter	OP (the anterior mediastinal and left pleural nodules were all removed, and the right side was not removed)	There was no recurrence in the left after 18 mo follow-up. No change in right lesion
Chang <i>et al</i> ^[11]	2011	51/M	-	Anterior mediastinum, involving vein	4.2 cm × 2.7 cm × 2.1 cm, clear boundary, uncoated film, gray to yellow	OP	NED after 11 mo follow-up
Chauhan <i>et al</i> ^[12]	2014	8/M	Chronic cough	Anterior mediastinum	7 cm × 5.5 cm × 3.6 cm, clear boundary, white, firm	OP	No recurrence (follow-up time not recorded)
Dissanayake <i>et al</i> ^[13]	2016	29/F	-	Anterior mediastinum, involving the thoracic duct	10 × 6 × 5.5 cm, 242 g, whitish tan, fleshy, homogeneous, surfaces with focal areas of yellowish tan, firm calcifications	OP (the thoracic duct was resected along with the mass)	NED after 3 mo follow-up
Present case	2019	31/M	-	Posterior mediastinum	5.5 cm × 3.5 cm × 2.5 cm, firm, grayish white	OP	Alive, NED after 4 mo follow-up

M: Male; F: Female; OP: Operation; NA: Not available; ND: Not done; NED: No evidence of disease; +: Yes; -: No.

REFERENCES

- 1 Lee S, Jahng J, Han W. Gastric Calcifying Fibrous Tumor Manifesting as a Subepithelial Tumor. *J Gastrointest Surg* 2018; **22**: 1127-1129 [PMID: 29196941 DOI: 10.1007/s11605-017-3639-z]
- 2 Prucker J, Salaheddin-Nassr Y, Leidl S. Calcifying fibrous tumor of the terminal ileum mesentery: Case report. *Medicine (Baltimore)* 2018; **97**: e13351 [PMID: 30572439 DOI: 10.1097/MD.00000000000013351]
- 3 Chorti A, Papavramidis TS, Michalopoulos A. Calcifying Fibrous Tumor: Review of 157 Patients Reported in International Literature. *Medicine (Baltimore)* 2016; **95**: e3690 [PMID: 27196478 DOI: 10.1097/MD.00000000000003690]
- 4 Okamura K, Nawata K, Shimada S, Ono M. Complete resection of a giant calcifying fibrous tumor of myocardial origin. *Gen Thorac Cardiovasc Surg* 2019 [PMID: 30850932 DOI: 10.1007/s11748-019-01103-9]
- 5 Qureshi TA, Akhtar S, Abid M. Calcifying fibrous pseudotumour of maxilla: A rare entity mimicking malignancy: A case report. *J Pak Med Assoc* 2018; **68**: 1521-1524 [PMID: 30317354]
- 6 Dumont P, de Muret A, Skrobala D, Robin P, Toumieux B. Calcifying fibrous pseudotumor of the

- mediastinum. *Ann Thorac Surg* 1997; **63**: 543-544 [PMID: 9033339 DOI: 10.1016/S0003-4975(96)01022-3]
- 7 **Jeong HS**, Lee GK, Sung R, Ahn JH, Song HG. Calcifying fibrous pseudotumor of mediastinum--a case report. *J Korean Med Sci* 1997; **12**: 58-62 [PMID: 9142662 DOI: 10.3346/jkms.1997.12.1.58]
- 8 **Sigel JE**, Smith TA, Reith JD, Goldblum JR. Immunohistochemical analysis of anaplastic lymphoma kinase expression in deep soft tissue calcifying fibrous pseudotumor: evidence of a late sclerosing stage of inflammatory myofibroblastic tumor? *Ann Diagn Pathol* 2001; **5**: 10-14 [PMID: 11172201 DOI: 10.1053/adpa.2001.21474]
- 9 **Nascimento AF**, Ruiz R, Hornick JL, Fletcher CD. Calcifying fibrous 'pseudotumor': clinicopathologic study of 15 cases and analysis of its relationship to inflammatory myofibroblastic tumor. *Int J Surg Pathol* 2002; **10**: 189-196 [PMID: 12232572 DOI: 10.1177/106689690201000304]
- 10 **Sleigh KA**, Lai W, Keen CE, Berrisford RG. Calcifying fibrous pseudotumours: an unusual case with multiple pleural and mediastinal lesions. *Interact Cardiovasc Thorac Surg* 2010; **10**: 652-653 [PMID: 19955173 DOI: 10.1510/icvts.2009.211581]
- 11 **Chang JW**, Kim JH, Maeng YH. Calcifying fibrous pseudotumor of the anterior mediastinum. *Korean J Thorac Cardiovasc Surg* 2011; **44**: 318-320 [PMID: 22263180 DOI: 10.5090/kjtes.2011.44.4.318. DOI: 10.5090/kjtes.2011.44.4.318]
- 12 **Chauhan KR**, Shah HU, Trivedi PP, Shah MJ. Calcifying fibrous pseudotumor of the mediastinum: a rare case report. *Indian J Pathol Microbiol* 2014; **57**: 155-156 [PMID: 24739864 DOI: 10.4103/0377-4929.130936]
- 13 **Dissanayake SN**, Hagen J, Fedenko A, Lee C. Calcifying Fibrous Pseudotumor of the Posterior Mediastinum With Encapsulation of the Thoracic Duct. *Ann Thorac Surg* 2016; **102**: e39-e40 [PMID: 27343527 DOI: 10.1016/j.athoracsur.2015.12.041]
- 14 **Vasilakaki T**, Skafida E, Tsavari A, Arkoumani E, Koulia K, Myoteri D, Grammatoglou X, Moustou E, Firfiris N, Zisis D. Gastric calcifying fibrous tumor: a very rare case report. *Case Rep Oncol* 2012; **5**: 455-458 [PMID: 23109921 DOI: 10.1159/000342137]
- 15 **Zhang H**, Jin Z, Ding S. Gastric calcifying fibrous tumor: A case of suspected immunoglobulin G4-related gastric disease. *Saudi J Gastroenterol* 2015; **21**: 423-426 [PMID: 26655140 DOI: 10.4103/1319-3767.170950]
- 16 **Stone JH**, Khosroshahi A, Deshpande V, Chan JK, Heathcote JG, Aalberse R, Azumi A, Bloch DB, Brugge WR, Carruthers MN, Cheuk W, Cornell L, Castillo CF, Ferry JA, Forcione D, Klöppel G, Hamilos DL, Kamisawa T, Kasashima S, Kawa S, Kawano M, Masaki Y, Notohara K, Okazaki K, Ryu JK, Saeki T, Sahani D, Sato Y, Smyrk T, Stone JR, Takahira M, Umehara H, Webster G, Yamamoto M, Yi E, Yoshino T, Zamboni G, Zen Y, Chari S. Recommendations for the nomenclature of IgG4-related disease and its individual organ system manifestations. *Arthritis Rheum* 2012; **64**: 3061-3067 [PMID: 22736240 DOI: 10.1002/art.34593]
- 17 **Koizumi S**, Kamisawa T, Kuruma S, Tabata T, Chiba K, Iwasaki S, Endo Y, Kuwata G, Koizumi K, Shimosegawa T, Okazaki K, Chiba T. Immunoglobulin G4-related gastrointestinal diseases, are they immunoglobulin G4-related diseases? *World J Gastroenterol* 2013; **19**: 5769-5774 [PMID: 24124321 DOI: 10.3748/wjg.v19.i35.5769]
- 18 **Prochaska EC**, Sciallis AP, Miller BS. Retroperitoneal calcifying fibrous tumor mimicking an adrenal tumor. *J Surg Case Rep* 2016; 2016 [PMID: 27252518 DOI: 10.1093/jscr/rjw049]
- 19 **Pezhouh MK**, Rezaei MK, Shabihkhani M, Ghosh A, Belchis D, Montgomery EA, Voltaggio L. Clinicopathologic study of calcifying fibrous tumor of the gastrointestinal tract: a case series. *Hum Pathol* 2017; **62**: 199-205 [PMID: 28153506 DOI: 10.1016/j.humpath.2017.01.002]



Published By Baishideng Publishing Group Inc
7041 Koll Center Parkway, Suite 160, Pleasanton, CA 94566, USA
Telephone: +1-925-2238242
Fax: +1-925-2238243
E-mail: bpgoffice@wjgnet.com
Help Desk: <https://www.f6publishing.com/helpdesk>
<https://www.wjgnet.com>

