

World Journal of *Clinical Cases*

World J Clin Cases 2019 September 6; 7(17): 2413-2657



**MINIREVIEWS**

- 2413** Multifocal G1-G2 gastric neuroendocrine tumors: Differentiating between Type I, II and III, a clinicopathologic review
Algashaamy K, Garcia-Buitrago M
- 2420** Attention deficit hyperactivity disorder and comorbidity: A review of literature
Gnanavel S, Sharma P, Kaushal P, Hussain S

ORIGINAL ARTICLE**Case Control Study**

- 2427** Dietary manipulation and testosterone replacement therapy may explain changes in body composition after spinal cord injury: A retrospective case report
Gorgey AS, Lester RM, Ghatas MP, Sistrun SN, Lavis T

Retrospective Study

- 2438** Risk factors, clinical features, and short-term prognosis of spontaneous fungal peritonitis in cirrhosis: A matched case-control study
Huang CH, Pang LT, Xu LC, Ge TT, Xu QM, Chen Z
- 2450** Incidence of portal vein thrombosis after splenectomy and its influence on transjugular intrahepatic portosystemic shunt stent patency
Dong F, Luo SH, Zheng LJ, Chu JG, Huang H, Zhang XQ, Yao KC

Observational Study

- 2463** Multiplex gene expression profile in inflamed mucosa of patients with Crohn's disease ileal localization: A pilot study
Giudici F, Lombardelli L, Russo E, Cavalli T, Zambonin D, Logiodice F, Kullolli O, Giusti L, Bargellini T, Fazi M, Biancone L, Scaringi S, Clemente AM, Perissi E, Delfino G, Torcia MG, Ficari F, Tonelli F, Piccinni MP, Malentacchi C

Prospective Study

- 2477** Analysis of the postoperative hemostatic profile of colorectal cancer patients subjected to liver metastasis resection surgery
Perez Navarro G, Pascual Bellosta AM, Ortega Lucea SM, Serradilla Martín M, Ramirez Rodriguez JM, Martinez Ubieta J

SYSTEMATIC REVIEW

- 2487** Systematic review of ablative therapy for the treatment of renal allograft neoplasms
Favi E, Raison N, Ambrogi F, Delbue S, Clementi MC, Lamperti L, Perego M, Bischeri M, Ferraresso M

CASE REPORT

- 2505** Subcutaneous sarcoidosis of the upper and lower extremities: A case report and review of the literature
Mehrzaad R, Festa J, Bhatt R
- 2513** Atypical cutaneous lesions in advanced-stage Hodgkin lymphoma: A case report
Massaro F, Ferrari A, Zendri E, Zanelli M, Merli F
- 2519** Characteristics of multiple nodules in a patient with pulmonary Langerhans cell histiocytosis: A case report
Kanaji N, Tokunaga Y, Ishikawa R, Watanabe N, Kadowaki N
- 2526** Impact of continuous local lavage on pancreatic juice-related postoperative complications: Three case reports
Hori T, Ogawa K, Yamamoto H, Harada H, Matsumura K, Yamamoto M, Yamada M, Yazawa T, Kuriyama K, Tani M, Yasukawa D, Kamada Y, Aisu Y, Tani R, Aoyama R, Nakayama S, Sasaki Y, Nishimoto K, Zaima M
- 2536** Adult intussusception caused by colonic anisakis: A case report
Choi YI, Park DK, Cho HY, Choi SJ, Chung JW, Kim KO, Kwon KA, Kim YJ
- 2542** Robotic-assisted resection of ovarian tumors in children: A case report
Xie XX, Wang N, Wang ZH, Zhu YY, Wang JR, Wang XQ
- 2549** Synovial sarcoma in the plantar region: A case report and literature review
Gao J, Yuan YS, Liu T, Lv HR, Xu HL
- 2556** Severe serous cavity bleeding caused by acquired factor V deficiency associated with lymphatic leakage in a hemodialysis patient: A case report
Zhao WB, Chen YR, Luo D, Lin HC, Long B, Wu ZY, Peng H
- 2562** Supermicrosurgery in fingertip defects-split tibial flap of the second toe to reconstruct multiple fingertip defects: A case report
Wang KL, Zhang ZQ, Buckwalter JA, Yang Y
- 2567** Ultrasound-guided fascia iliaca compartment block combined with general anesthesia for amputation in an acute myocardial infarction patient after percutaneous coronary intervention: A case report
Ling C, Liu XQ, Li YQ, Wen XJ, Hu XD, Yang K
- 2573** Rare spontaneous intrahepatic portosystemic shunt in hepatitis B-induced cirrhosis: A case report
Tan YW, Sheng JH, Tan HY, Sun L, Yin YM
- 2580** Imaging of mixed epithelial and stromal tumor of the kidney: A case report and review of the literature
Ye J, Xu Q, Zheng J, Wang SA, Wu YW, Cai JH, Yuan H
- 2587** Allogenic tooth transplantation using 3D printing: A case report and review of the literature
Xu HD, Miron RJ, Zhang XX, Zhang YF

REVIEW

- 2597 Fecal microbiota transplantation as an effective initial therapy for pancreatitis complicated with severe *Clostridium difficile* infection: A case report
Hu Y, Xiao HY, He C, Lv NH, Zhu L

CASE REPORT

- 2605 Organ-associated pseudosarcomatous myofibroblastic proliferation with ossification in the lower pole of the kidney mimicking renal pelvic carcinoma: A case report
Zhai TY, Luo BJ, Jia ZK, Zhang ZG, Li X, Li H, Yang JJ
- 2611 Treating aplasia cutis congenita in a newborn with the combination of ionic silver dressing and moist exposed burn ointment: A case report
Lei GF, Zhang JP, Wang XB, You XL, Gao JY, Li XM, Chen ML, Ning XQ, Sun JL
- 2617 Cause of postprandial vomiting - a giant retroperitoneal ganglioneuroma enclosing large blood vessels: A case report
Zheng X, Luo L, Han FG
- 2623 Carcinoma ex pleomorphic adenoma of the trachea: A case report
Gao HX, Li Q, Chang WL, Zhang YL, Wang XZ, Zou XX
- 2630 Wilson disease associated with immune thrombocytopenia: A case report and review of the literature
Ma TJ, Sun GL, Yao F, Yang ZL
- 2637 Calcifying fibrous tumor of the mediastinum: A case report
Qi DJ, Zhang QF
- 2644 Brachiocephalic artery stenting through the carotid artery: A case report and review of the literature
Xu F, Wang F, Liu YS
- 2652 An extremely rare pedunculated lipoma of the hypopharynx: A case report
Sun Q, Zhang CL, Liu ZH

ABOUT COVER

Editorial Board Member of *World Journal of Clinical Cases*, Marianna Luongo, MD, Doctor, Surgeon, Department of Neurosurgery, Azienda Ospedaliera Regionale San Carlo, Potenza 85100, Italy

AIMS AND SCOPE

The primary aim of the *World Journal of Clinical Cases (WJCC)* is to provide scholars and readers from various fields of clinical medicine with a platform to publish high-quality clinical research articles and communicate their research findings online.

The *WJCC* mainly publishes case reports, case series, research results and findings in the field of clinical medicine covering a wide range of topics including diagnostic, therapeutic, and preventive modalities.

INDEXING/ABSTRACTING

The *WJCC* is now indexed in PubMed, PubMed Central, Science Citation Index Expanded (also known as SciSearch®), and Journal Citation Reports/Science Edition. The 2019 Edition of Journal Citation Reports cites the 2018 impact factor for *WJCC* as 1.153 (5-year impact factor: N/A), ranking *WJCC* as 99 among 160 journals in Medicine, General and Internal (quartile in category Q3).

RESPONSIBLE EDITORS FOR THIS ISSUE

Responsible Electronic Editor: *Yan-Xia Xing*

Proofing Production Department Director: *Yun-Xiaojuan Wu*

NAME OF JOURNAL

World Journal of Clinical Cases

ISSN

ISSN 2307-8960 (online)

LAUNCH DATE

April 16, 2013

FREQUENCY

Semimonthly

EDITORS-IN-CHIEF

Dennis A Bloomfield, Sandro Vento

EDITORIAL BOARD MEMBERS

<https://www.wjnet.com/2307-8960/editorialboard.htm>

EDITORIAL OFFICE

Jin-Lei Wang, Director

PUBLICATION DATE

September 6, 2019

COPYRIGHT

© 2019 Baishideng Publishing Group Inc

INSTRUCTIONS TO AUTHORS

<https://www.wjnet.com/bpg/gerinfo/204>

GUIDELINES FOR ETHICS DOCUMENTS

<https://www.wjnet.com/bpg/GerInfo/287>

GUIDELINES FOR NON-NATIVE SPEAKERS OF ENGLISH

<https://www.wjnet.com/bpg/gerinfo/240>

PUBLICATION MISCONDUCT

<https://www.wjnet.com/bpg/gerinfo/208>

ARTICLE PROCESSING CHARGE

<https://www.wjnet.com/bpg/gerinfo/242>

STEPS FOR SUBMITTING MANUSCRIPTS

<https://www.wjnet.com/bpg/GerInfo/239>

ONLINE SUBMISSION

<https://www.f6publishing.com>

Ultrasound-guided fascia iliaca compartment block combined with general anesthesia for amputation in an acute myocardial infarction patient after percutaneous coronary intervention: A case report

Chen Ling, Xing-Qing Liu, Yi-Qun Li, Xian-Jie Wen, Xu-Dong Hu, Kai Yang

ORCID number: Chen Ling (0000-0002-7022-2296); Xing-Qing Liu (0000-0003-4796-4387); Yi-Qun Li (0000-0002-3861-9744); Xian-Jie Wen (0000-0001-9373-9821); Xu-Dong Hu (0000-0001-5018-5873); Kai Yang (0000-0001-9583-7863).

Author contributions: Ling C, Liu XQ and Li YQ contributed equally to this work. Ling C collected the case data and administered the anesthesia; Li YQ formulated the surgery regimen and administered the surgery; Liu XQ collected the case data and administered the anesthesia; Wen XJ formulated the anesthesia regimen, guided the anesthesia, and wrote the manuscript; Hu XD and Yang K administered the anesthesia.

Informed consent statement: Informed consent was obtained from the patient to publish relevant data.

Conflict-of-interest statement: The authors declare that there is no conflict of interest regarding the publication of this paper.

CARE Checklist (2016) statement: The authors have read the CARE Checklist (2016) and the manuscript was prepared and revised according to the CARE Checklist (2016).

Open-Access: This article is an open-access article that was selected by an in-house editor and fully peer-reviewed by external reviewers. It is distributed in accordance with the Creative Commons Attribution Non

Chen Ling, Xing-Qing Liu, Yi-Qun Li, Xian-Jie Wen, Xu-Dong Hu, Kai Yang, Department of Anesthesiology, Affiliated Foshan Hospital of Southern Medical University and Second People's Hospital of Foshan, Foshan 528000, Guangdong Province, China

Corresponding author: Xian-Jie Wen, MD, Doctor, Chief Physician of Anesthesiology, Department of Anesthesiology, Affiliated Foshan Hospital of Southern Medical University and Second People's Hospital of Foshan, No. 78, Weiguo Road, Chancheng District, Foshan 528000, Guangdong Province, China. xjwen166@126.com

Telephone: +86-15899807105

Fax: +86-757-88032178

Abstract

BACKGROUND

Fascia iliaca compartment block is a technique that blocks three nerves, similar to a 3-in-1 nerve block. This block provides analgesia for patients undergoing lower limb surgery, and is a simple technique that is easy to implement. Here, we report a case of fascia iliaca compartment block in a patient with myocardial infarction who underwent emergency middle thigh amputation.

CASE SUMMARY

A 78-year-old female patient weighing 38 kg with gangrene and occlusive peripheral atherosclerosis of the right leg underwent an emergency middle thigh amputation. The patient had a history of hypertension, coronary heart disease, cerebral infarction, anterior wall myocardial infarction, and had recently undergone percutaneous coronary intervention consisting of coronary angiography and right coronary artery stent implantation. Considering the patient's condition, an ultrasound-guided fascia iliaca compartment block combined with general anesthesia was implemented for amputation. The fascia iliaca compartment block provided analgesia for the operation, and reduced the dosage of general anesthetics. It also alleviated adverse cardiovascular effects caused by pain stress, and ensured the safety of the patient during the perioperative period. This block also provided postoperative analgesia. The patient had a good prognosis, and was subsequently discharged from hospital.

CONCLUSION

Fascia iliaca compartment block provides surgical analgesia. It also alleviates adverse cardiovascular effects, and ensures patient safety during the perioperative period.

Commercial (CC BY-NC 4.0) license, which permits others to distribute, remix, adapt, build upon this work non-commercially, and license their derivative works on different terms, provided the original work is properly cited and the use is non-commercial. See: <http://creativecommons.org/licenses/by-nc/4.0/>

Manuscript source: Unsolicited manuscript

Received: April 9, 2019

Peer-review started: April 12, 2019

First decision: May 31, 2019

Revised: June 30, 2019

Accepted: July 20, 2019

Article in press: July 20, 2019

Published online: September 6, 2019

P-Reviewer: Ueda H

S-Editor: Dou Y

L-Editor: Filipodia

E-Editor: Xing YX



Key words: Ultrasound-guided; Fascia iliaca compartment block; Acute myocardial infarction; Case report; Percutaneous coronary intervention

©The Author(s) 2019. Published by Baishideng Publishing Group Inc. All rights reserved.

Core tip: Ultrasound-guided fascia iliaca compartment block combined with general anesthesia can provide better intraoperative analgesia for thigh surgery, reduce the dosage of general anesthetics, and alleviate the adverse cardiovascular effects caused by pain stress. In this case report, we describe the effects of fascia iliaca compartment block in a patient with myocardial infarction who underwent an emergency middle thigh amputation. Use of this block ensured the safety of the patient during the perioperative period.

Citation: Ling C, Liu XQ, Li YQ, Wen XJ, Hu XD, Yang K. Ultrasound-guided fascia iliaca compartment block combined with general anesthesia for amputation in an acute myocardial infarction patient after percutaneous coronary intervention: A case report. *World J Clin Cases* 2019; 7(17): 2567-2572

URL: <https://www.wjgnet.com/2307-8960/full/v7/i17/2567.htm>

DOI: <https://dx.doi.org/10.12998/wjcc.v7.i17.2567>

INTRODUCTION

Thigh surgery presents a challenging clinical problem commonly encountered by medical staff. Traditional analgesia for thigh surgery involves opioids and regional nerve blockade, which have been demonstrated to be effective. Emergency surgery is often encountered in the elderly, and presents special demands for the anesthesiologist. Fascia iliaca compartment block is a technique that blocks three nerves similar to a 3-in-1 nerve block. The fascia iliaca space has the iliopsoas muscle behind, the fascia iliaca in front, and the fascia lata covering the superficial fascia of the fascia iliaca. The femoral nerve, the lateral femoral cutaneous nerve, and the obturator nerve are located below the fascia iliaca at the pelvic segment. The fascia iliaca compartment block is used to block these three nerves to meet the needs of lower limb analgesia and anesthesia. From references^[1,2], we know that fascia iliaca compartment block can provide superior analgesia and decreased opioid consumption with minimal side effects. It can be deployed in a relatively quick fashion after a small amount of training, and can be executed with high success rates under ultrasound guidance. Compared with general anesthesia, fascia iliaca compartment block combined with general anesthesia reduces the dosage of general anesthetics required, stabilizes the hemodynamics, and improves postoperative analgesia. Here, we report a case of fascia iliaca compartment block in a patient with myocardial infarction who underwent emergency middle thigh amputation.

CASE PRESENTATION

Chief complaints

Shortness of breath and dyspnea for 10 d.

History of present illness

A 78-year-old female patient weighing 38 kg was diagnosed with acute non-ST segment elevation myocardial infarction 10 d previously in another hospital, which manifested as chest pain, shortness of breath and dyspnea, and was treated with tracheal intubation, ventilator-assisted ventilation and vasodilation. Serum troponin concentration was 0.7 ng/mL. The patient was transferred to the intensive care unit (ICU) at our hospital.

History of past illness

Hypertension and coronary heart disease for 15 years, cerebral infarction for 8 years, and anterior wall myocardial infarction for 5 years.

Physical examination

The patient had decreased blood pressure, increased heart rate and fever, characterized by septic shock, cardiogenic shock, and blood oxygen saturation (SpO₂) fluctuations above 97% when tracheal intubation was connected to the ventilator. The lungs demonstrated thick breath sounds, and the lower lungs showed slight moist rale. Her heart rate was 100 bpm, the heart sound was low and blunt, and there was no noise in each valve area. Dry necrosis of the right lower foot and visible scattered ecchymoses were observed.

Laboratory examinations

The serum creatine kinase-MB concentration was 25.8 ng/mL, and the white blood cell count was $24.25 \times 10^9/L$.

Imaging examinations

The bedside digital radiography chest X-ray showed double lung infection. Color Doppler ultrasound showed moderate mitral regurgitation and mild aortic regurgitation.

FINAL DIAGNOSIS

Non-ST segment elevation acute myocardial infarction, right leg gangrene, and right leg peripheral arterial occlusive disease.

TREATMENT

In the ICU, the patient had been given imipenem and cilastatin sodium for anti-infection, as well as dopamine and norepinephrine as anti-shock treatment. Three days previous, the patient had undergone percutaneous coronary intervention (PCI) consisting of coronary angiography and right coronary artery stent implantation by a cardiologist. The coronary angiography showed that there was no obvious stenosis in the left main coronary artery, 70%-80% stenosis in the middle part of the anterior descending artery, 80% stenosis in the opening of the circumflex artery, and 90% stenosis in the proximal part of the right coronary artery. The patient was diagnosed with right coronary artery dominant type and three-vessel coronary lesions. Considering the patient's condition, a stent was implanted in the right coronary artery, and the effect of vascular opening was good. Following PCI, the patient's body temperature further increased (38.5-39 °C), and the white blood cell count was $33.74 \times 10^9/L$. The right lower extremity showed dry skin necrosis and scattered ecchymoses. The right middle iliac artery showed occlusion. The patient had an endotracheal tube in place and presented with fever, and the SpO₂ was over 97% with medium flow oxygen inhalation. Following multi-disciplinary team consultation, the patient was scheduled for mid-thigh amputation.

The patient was conscious and entered the operating room with a tracheal catheter in place. Dopamine was pumped continuously at 5 µg/kg per min, and norepinephrine was pumped at 0.06 µg/kg per min into the right internal jugular vein. The patient's non-invasive blood pressure was 95/45 mmHg, heart rate was 98 bpm, and SpO₂ was 99%. A left radial artery puncture catheter was used to monitor arterial blood pressure. The anesthesia system was connected to the tracheal catheter to assist ventilation.

Ultrasound-guided right-side improved fascia iliaca compartment block was used for surgical analgesia. The procedures were as follows: The ultrasound probe was vertically placed on the outer third of the inguinal ligament to identify the hourglass sign in the obliquus internus abdominis, sartorius muscle and iliopsoas muscle^[3] (Figure 1). The in-plane technique was used to implant the needle from the tail end to the head of the patient to reach the deep surface of the fascia iliaca. Local anesthetics (0.33% ropivacaine hydrochloride 30 mL) was injected into the space between the obliquus internus abdominis and iliopsoas muscle. The anesthetic plane was tested by acupuncture after 5 min and 10 min to ensure the block effect. After blocking, midazolam 2 mg, sufentanil 10 µg, cisatracurium 6 mg and etomidate 6 mg were intravenously injected to induce anesthesia, and 1% sevoflurane inhalation anesthesia-maintained anesthesia.

The operation duration was 65 min. The bispectral index was maintained between 45 and 60. Vasoactive drugs were used to regulate blood pressure and heart rate. Vital signs were stable during the perioperative period. The Critical Care Pain Observation Tool (CPOT) score can be used to assess pain in critically ill patients with no hypnotic, opioid-based analgo-sedation^[4,5], the CPOT score was 2 at 6 h after surgery, and the

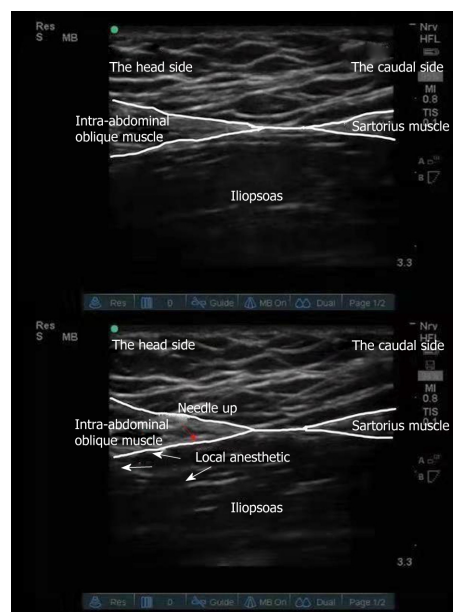


Figure 1 Procedure for ultrasound-guided fascia iliaca compartment block. The ultrasound probe was vertically placed on the outer third of the inguinal ligament to identify the hourglass sign of the obliquus internus abdominis, sartorius muscle and iliopsoas muscle.

Ramsay sedation score was 3. The effect of postoperative analgesia was satisfactory. Two days after the operation, inflammatory indicators improved, and tracheal intubation was removed.

OUTCOME AND FOLLOW-UP

No serious adverse cardiovascular events occurred during the perioperative period, and the patient was subsequently discharged.

DISCUSSION

The incremental risk of noncardiac surgery on adverse cardiac events among post-stent patients is highest in the initial 6 mo following stent implantation, and stabilizes at 1.0% after 6 mo^[6,7]. From references^[8], in the case of emergency surgery, it is particularly important for anesthesiologists to prevent, monitor and treat myocardial ischemia during surgery.

Our patient suffered from an acute myocardial infarction approximately 2 wk previous, and had undergone PCI. Due to vascular occlusion and necrosis of the right lower extremity, the patient presented with septic shock, and underwent both tracheal intubation and artificial ventilation. She also had multiple organ dysfunction. It was necessary to perform an urgent right lower extremity amputation to eliminate the source of infection. For amputation patients, intraspinal anesthesia is the preferred method of anesthesia. However, this patient was administered anticoagulation therapy after PCI, and coagulation function was abnormal; thus, intraspinal anesthesia was unsuitable.

As this patient had suffered from a recent acute myocardial infarction and her cardiac function was poor, it was crucial to maintain stable circulation, as well as a balance between oxygen supply and demand during surgery. If only general anesthesia was selected, deep anesthesia would be required. Anesthetic agents can depress myocardial contraction^[9]. A large dosage of general anesthetics would aggravate myocardial depression and induce adverse cardiac events. Krych *et al*^[10] reported that the quality of perioperative analgesia provided by the fascia iliaca blockade was excellent, and resulted in both low opioid consumption and a high quality of pain relief. Ultrasound-guided fascia iliaca compartment block provided the perfect analgesia, and decreased the consumption of general anesthetics, which avoided cardiac and circulatory function depression. This was caused by deep general anesthesia and the stress reaction caused by light anesthesia. Considering the patient's condition, ultrasound-guided fascia iliaca compartment block combined with general

anesthesia was employed for amputation.

The fascia iliaca space has the iliopsoas muscle behind, the fascia iliaca in front, and the fascia lata covering the superficial fascia of the fascia iliaca^[11-13]. The femoral nerve, the lateral femoral cutaneous nerve, and the obturator nerve are located below the fascia iliaca at the pelvic segment^[14]. Fascia iliaca compartment block is used to block these nerves to meet the needs of lower limb analgesia and anesthesia. It is used for anesthesia and analgesia of the hip, knee and thigh^[15,16]. Ultrasound-guided fascia iliaca compartment block can be divided into parallel puncture of the inguinal ligament, and improved vertical puncture of the inguinal ligament. In a parallel puncture of the inguinal ligament, drugs spread to the lower part of the inguinal ligament, while the modified fascia iliaca compartment block technique under real-time ultrasound guidance and local anesthetics spread to the head^[17,18]. As the distribution of the femoral nerve, lateral femoral cutaneous nerve and obturator nerve is concentrated above the inguinal ligaments, the number of local anesthetics needed in the improved vertical method is reduced. Due to infection, the patient required emergency amputation, and the improved vertical method of fascia iliaca compartment block combined with general anesthesia was adopted.

CONCLUSION

Ultrasound-guided fascia iliaca compartment block provided analgesia for surgery, and reduced the dosage of general anesthetics. It also alleviated adverse cardiovascular effects caused by pain stress, and ensured the safety of the patient during the perioperative period. The fascia iliaca compartment block also provided postoperative analgesia. The patient had a good prognosis and was subsequently discharged from the hospital.

REFERENCES

- 1 Haines L, Dickman E, Ayvazyan S, Pearl M, Wu S, Rosenblum D, Likourezos A. Ultrasound-guided fascia iliaca compartment block for hip fractures in the emergency department. *J Emerg Med* 2012; **43**: 692-697 [PMID: 22494596 DOI: 10.1016/j.jemermed.2012.01.050]
- 2 Bullock WM, Yalamuri SM, Gregory SH, Auyong DB, Grant SA. Ultrasound-Guided Suprainguinal Fascia Iliaca Technique Provides Benefit as an Analgesic Adjunct for Patients Undergoing Total Hip Arthroplasty. *J Ultrasound Med* 2017; **36**: 433-438 [PMID: 27943417 DOI: 10.7863/ultra.16.03012]
- 3 Singh H, Jones D. Hourglass-pattern recognition simplifies fascia iliaca compartment block. *Reg Anesth Pain Med* 2013; **38**: 467-468 [PMID: 23970058 DOI: 10.1097/AAP.0b013e3182a1f772]
- 4 Frandsen JB, O'Reilly Poulsen KS, Laerkner E, Stroem T. Validation of the Danish version of the Critical Care Pain Observation Tool. *Acta Anaesthesiol Scand* 2016; **60**: 1314-1322 [PMID: 27468726 DOI: 10.1111/aas.12770]
- 5 Kotfis K, Zegan-Barańska M, Strzelbicka M, Safranow K, Żukowski M, Ely EW; POL-CPOT Study Group. Validation of the Polish version of the Critical Care Pain Observation Tool (CPOT) to assess pain intensity in adult, intubated intensive care unit patients: the POL-CPOT study. *Arch Med Sci* 2018; **14**: 880-889 [PMID: 30002708 DOI: 10.5114/aoms.2017.69752]
- 6 Holcomb CN, Graham LA, Richman JS, Rhyne RR, Itani KM, Maddox TM, Hawn MT. The incremental risk of noncardiac surgery on adverse cardiac events following coronary stenting. *J Am Coll Cardiol* 2014; **64**: 2730-2739 [PMID: 25541124 DOI: 10.1016/j.jacc.2014.09.072]
- 7 Smith BB, Warner MA, Warner NS, Hanson AC, Smith MM, Rihal CS, Gulati R, Bell MR, Nuttall GA. Cardiac Risk of Noncardiac Surgery After Percutaneous Coronary Intervention With Second-Generation Drug-Eluting Stents. *Anesth Analg* 2019; **128**: 621-628 [PMID: 30169404 DOI: 10.1213/ANE.0000000000003408]
- 8 Fleisher LA, Fleischmann KE, Auerbach AD, Barnason SA, Beckman JA, Bozkurt B, Davila-Roman VG, Gerhard-Herman MD, Holly TA, Kane GC, Marine JE, Nelson MT, Spencer CC, Thompson A, Ting HH, Uretsky BF, Wijeyesundera DN. 2014 ACC/AHA guideline on perioperative cardiovascular evaluation and management of patients undergoing noncardiac surgery: a report of the American College of Cardiology/American Heart Association Task Force on Practice Guidelines. *Circulation* 2014; **130**: e278-e333 [PMID: 25085961 DOI: 10.1161/CIR.000000000000106]
- 9 Ren X, Schmidt W, Huang Y, Lu H, Liu W, Bu W, Eckenhoof R, Cammarato A, Gao WD. Fropofol decreases force development in cardiac muscle. *FASEB J* 2018; **32**: 4203-4213 [PMID: 29522375 DOI: 10.1096/fj.201701442R]
- 10 Krych AJ, Baran S, Kuzma SA, Smith HM, Johnson RL, Levy BA. Utility of multimodal analgesia with fascia iliaca blockade for acute pain management following hip arthroscopy. *Knee Surg Sports Traumatol Arthrosc* 2014; **22**: 843-847 [PMID: 24061718 DOI: 10.1007/s00167-013-2665-y]
- 11 Hebbard P, Ivanusic J, Sha S. Ultrasound-guided supra-inguinal fascia iliaca block: a cadaveric evaluation of a novel approach. *Anaesthesia* 2011; **66**: 300-305 [PMID: 21401544 DOI: 10.1111/j.1365-2044.2011.06628.x]
- 12 Capdevila X, Biboulet P, Bouregba M, Barthelet Y, Rubenovitch J, d'Athis F. Comparison of the three-in-one and fascia iliaca compartment blocks in adults: clinical and radiographic analysis. *Anesth Analg* 1998; **86**: 1039-1044 [PMID: 9585293]
- 13 Deniz S, Atım A, Kürklü M, Çaycı T, Kurt E. Comparison of the postoperative analgesic efficacy of an ultrasound-guided fascia iliaca compartment block versus 3 in 1 block in hip prosthesis surgery. *Agri* 2014; **26**: 151-157 [PMID: 25551810 DOI: 10.5505/agri.2014.76993]

- 14 **Vermeylen K**, Soetens F, Leunen I, Hadzic A, Van Boxtael S, Pomés J, Prats-Galino A, Van de Velde M, Neyrinck A, Sala-Blanch X. The effect of the volume of supra-inguinal injected solution on the spread of the injectate under the fascia iliaca: a preliminary study. *J Anesth* 2018; **32**: 908-913 [PMID: [30250982](#) DOI: [10.1007/s00540-018-2558-9](#)]
- 15 **Foss NB**, Kristensen BB, Bundgaard M, Bak M, Heiring C, Virkelyst C, Hougaard S, Kehlet H. Fascia iliaca compartment blockade for acute pain control in hip fracture patients: a randomized, placebo-controlled trial. *Anesthesiology* 2007; **106**: 773-778 [PMID: [17413915](#) DOI: [10.1097/01.anes.0000264764.56544.d2](#)]
- 16 **Hards M**, Brewer A, Bessant G, Lahiri S. Efficacy of Prehospital Analgesia with Fascia Iliaca Compartment Block for Femoral Bone Fractures: A Systematic Review. *Prehosp Disaster Med* 2018; **33**: 299-307 [PMID: [29855397](#) DOI: [10.1017/S1049023X18000365](#)]
- 17 **Bang S**, Chung J, Jeong J, Bak H, Kim D. Efficacy of ultrasound-guided fascia iliaca compartment block after hip hemiarthroplasty: A prospective, randomized trial. *Medicine (Baltimore)* 2016; **95**: e5018 [PMID: [27684871](#) DOI: [10.1097/MD.0000000000005018](#)]
- 18 **Stevens M**, Harrison G, McGrail M. A modified fascia iliaca compartment block has significant morphine-sparing effect after total hip arthroplasty. *Anaesth Intensive Care* 2007; **35**: 949-952 [PMID: [18084988](#) DOI: [10.1177/0310057X0703500615](#)]



Published By Baishideng Publishing Group Inc
7041 Koll Center Parkway, Suite 160, Pleasanton, CA 94566, USA
Telephone: +1-925-2238242
Fax: +1-925-2238243
E-mail: bpgoffice@wjgnet.com
Help Desk: <https://www.f6publishing.com/helpdesk>
<https://www.wjgnet.com>

