

World Journal of *Clinical Cases*

World J Clin Cases 2019 September 6; 7(17): 2413-2657





MINIREVIEWS

- 2413** Multifocal G1-G2 gastric neuroendocrine tumors: Differentiating between Type I, II and III, a clinicopathologic review
Algashaamy K, Garcia-Buitrago M
- 2420** Attention deficit hyperactivity disorder and comorbidity: A review of literature
Gnanavel S, Sharma P, Kaushal P, Hussain S

ORIGINAL ARTICLE

Case Control Study

- 2427** Dietary manipulation and testosterone replacement therapy may explain changes in body composition after spinal cord injury: A retrospective case report
Gorgey AS, Lester RM, Ghatas MP, Sistrun SN, Lavis T

Retrospective Study

- 2438** Risk factors, clinical features, and short-term prognosis of spontaneous fungal peritonitis in cirrhosis: A matched case-control study
Huang CH, Pang LT, Xu LC, Ge TT, Xu QM, Chen Z
- 2450** Incidence of portal vein thrombosis after splenectomy and its influence on transjugular intrahepatic portosystemic shunt stent patency
Dong F, Luo SH, Zheng LJ, Chu JG, Huang H, Zhang XQ, Yao KC

Observational Study

- 2463** Multiplex gene expression profile in inflamed mucosa of patients with Crohn's disease ileal localization: A pilot study
Giudici F, Lombardelli L, Russo E, Cavalli T, Zamboni D, Logiodice F, Kullolli O, Giusti L, Bargellini T, Fazi M, Biancone L, Scaringi S, Clemente AM, Perissi E, Delfino G, Torcia MG, Ficari F, Tonelli F, Piccinni MP, Malentacchi C

Prospective Study

- 2477** Analysis of the postoperative hemostatic profile of colorectal cancer patients subjected to liver metastasis resection surgery
Perez Navarro G, Pascual Bellosta AM, Ortega Lucea SM, Serradilla Martín M, Ramirez Rodriguez JM, Martinez Ubieta J

SYSTEMATIC REVIEW

- 2487** Systematic review of ablative therapy for the treatment of renal allograft neoplasms
Favi E, Raison N, Ambrogi F, Delbue S, Clementi MC, Lamperti L, Perego M, Bischeri M, Ferraresso M

CASE REPORT

- 2505** Subcutaneous sarcoidosis of the upper and lower extremities: A case report and review of the literature
Mehrzad R, Festa J, Bhatt R
- 2513** Atypical cutaneous lesions in advanced-stage Hodgkin lymphoma: A case report
Massaro F, Ferrari A, Zendri E, Zanelli M, Merli F
- 2519** Characteristics of multiple nodules in a patient with pulmonary Langerhans cell histiocytosis: A case report
Kanaji N, Tokunaga Y, Ishikawa R, Watanabe N, Kadowaki N
- 2526** Impact of continuous local lavage on pancreatic juice-related postoperative complications: Three case reports
Hori T, Ogawa K, Yamamoto H, Harada H, Matsumura K, Yamamoto M, Yamada M, Yazawa T, Kuriyama K, Tani M, Yasukawa D, Kamada Y, Aisu Y, Tani R, Aoyama R, Nakayama S, Sasaki Y, Nishimoto K, Zaima M
- 2536** Adult intussusception caused by colonic anisakis: A case report
Choi YI, Park DK, Cho HY, Choi SJ, Chung JW, Kim KO, Kwon KA, Kim YJ
- 2542** Robotic-assisted resection of ovarian tumors in children: A case report
Xie XX, Wang N, Wang ZH, Zhu YY, Wang JR, Wang XQ
- 2549** Synovial sarcoma in the plantar region: A case report and literature review
Gao J, Yuan YS, Liu T, Lv HR, Xu HL
- 2556** Severe serous cavity bleeding caused by acquired factor V deficiency associated with lymphatic leakage in a hemodialysis patient: A case report
Zhao WB, Chen YR, Luo D, Lin HC, Long B, Wu ZY, Peng H
- 2562** Supermicrosurgery in fingertip defects-split tibial flap of the second toe to reconstruct multiple fingertip defects: A case report
Wang KL, Zhang ZQ, Buckwalter JA, Yang Y
- 2567** Ultrasound-guided fascia iliaca compartment block combined with general anesthesia for amputation in an acute myocardial infarction patient after percutaneous coronary intervention: A case report
Ling C, Liu XQ, Li YQ, Wen XJ, Hu XD, Yang K
- 2573** Rare spontaneous intrahepatic portosystemic shunt in hepatitis B-induced cirrhosis: A case report
Tan YW, Sheng JH, Tan HY, Sun L, Yin YM
- 2580** Imaging of mixed epithelial and stromal tumor of the kidney: A case report and review of the literature
Ye J, Xu Q, Zheng J, Wang SA, Wu YW, Cai JH, Yuan H
- 2587** Allogenic tooth transplantation using 3D printing: A case report and review of the literature
Xu HD, Miron RJ, Zhang XX, Zhang YF

REVIEW

- 2597 Fecal microbiota transplantation as an effective initial therapy for pancreatitis complicated with severe *Clostridium difficile* infection: A case report
Hu Y, Xiao HY, He C, Lv NH, Zhu L

CASE REPORT

- 2605 Organ-associated pseudosarcomatous myofibroblastic proliferation with ossification in the lower pole of the kidney mimicking renal pelvic carcinoma: A case report
Zhai TY, Luo BJ, Jia ZK, Zhang ZG, Li X, Li H, Yang JJ
- 2611 Treating aplasia cutis congenita in a newborn with the combination of ionic silver dressing and moist exposed burn ointment: A case report
Lei GF, Zhang JP, Wang XB, You XL, Gao JY, Li XM, Chen ML, Ning XQ, Sun JL
- 2617 Cause of postprandial vomiting - a giant retroperitoneal ganglioneuroma enclosing large blood vessels: A case report
Zheng X, Luo L, Han FG
- 2623 Carcinoma ex pleomorphic adenoma of the trachea: A case report
Gao HX, Li Q, Chang WL, Zhang YL, Wang XZ, Zou XX
- 2630 Wilson disease associated with immune thrombocytopenia: A case report and review of the literature
Ma TJ, Sun GL, Yao F, Yang ZL
- 2637 Calcifying fibrous tumor of the mediastinum: A case report
Qi DJ, Zhang QF
- 2644 Brachiocephalic artery stenting through the carotid artery: A case report and review of the literature
Xu F, Wang F, Liu YS
- 2652 An extremely rare pedunculated lipoma of the hypopharynx: A case report
Sun Q, Zhang CL, Liu ZH

ABOUT COVER

Editorial Board Member of *World Journal of Clinical Cases*, Marianna Luongo, MD, Doctor, Surgeon, Department of Neurosurgery, Azienda Ospedaliera Regionale San Carlo, Potenza 85100, Italy

AIMS AND SCOPE

The primary aim of the *World Journal of Clinical Cases (WJCC)* is to provide scholars and readers from various fields of clinical medicine with a platform to publish high-quality clinical research articles and communicate their research findings online.

The *WJCC* mainly publishes case reports, case series, research results and findings in the field of clinical medicine covering a wide range of topics including diagnostic, therapeutic, and preventive modalities.

INDEXING/ABSTRACTING

The *WJCC* is now indexed in PubMed, PubMed Central, Science Citation Index Expanded (also known as SciSearch®), and Journal Citation Reports/Science Edition. The 2019 Edition of Journal Citation Reports cites the 2018 impact factor for *WJCC* as 1.153 (5-year impact factor: N/A), ranking *WJCC* as 99 among 160 journals in Medicine, General and Internal (quartile in category Q3).

RESPONSIBLE EDITORS FOR THIS ISSUE

Responsible Electronic Editor: *Yan-Xia Xing*

Proofing Production Department Director: *Yun-Xiaojuan Wu*

NAME OF JOURNAL

World Journal of Clinical Cases

ISSN

ISSN 2307-8960 (online)

LAUNCH DATE

April 16, 2013

FREQUENCY

Semimonthly

EDITORS-IN-CHIEF

Dennis A Bloomfield, Sandro Vento

EDITORIAL BOARD MEMBERS

<https://www.wjnet.com/2307-8960/editorialboard.htm>

EDITORIAL OFFICE

Jin-Lei Wang, Director

PUBLICATION DATE

September 6, 2019

COPYRIGHT

© 2019 Baishideng Publishing Group Inc

INSTRUCTIONS TO AUTHORS

<https://www.wjnet.com/bpg/gerinfo/204>

GUIDELINES FOR ETHICS DOCUMENTS

<https://www.wjnet.com/bpg/GerInfo/287>

GUIDELINES FOR NON-NATIVE SPEAKERS OF ENGLISH

<https://www.wjnet.com/bpg/gerinfo/240>

PUBLICATION MISCONDUCT

<https://www.wjnet.com/bpg/gerinfo/208>

ARTICLE PROCESSING CHARGE

<https://www.wjnet.com/bpg/gerinfo/242>

STEPS FOR SUBMITTING MANUSCRIPTS

<https://www.wjnet.com/bpg/GerInfo/239>

ONLINE SUBMISSION

<https://www.f6publishing.com>

Allogenic tooth transplantation using 3D printing: A case report and review of the literature

Hu-Di Xu, Richard J Miron, Xiao-Xin Zhang, Yu-Feng Zhang

ORCID number: Hu-Di Xu (0000-0002-7715-7220); Richard J Miron (0000-0003-3290-3418); Xiao-Xin Zhang (0000-0001-7077-9863); Yu-Feng Zhang (0000-0001-8702-5291).

Author contributions: Zhang XX, Xu HD, and Zhang YF contributed to the case report design; Xu HD collected and provided the data; Xu HD and Miron RJ drafted the manuscript; Zhang XX was the principle author of the paper, had full access to all data, and is the guarantor; Zhang YF supervised the report and the publication process; all authors read and confirmed the final version of this article.

Supported by the National Natural Science Foundation of China, No. 81600906, No. 81771050, and No. 81570954; the Natural Science Foundation of Hubei Province, No.2017CFA025; and the National Key R&D Program of China, No. 2018YFC1105300.

Informed consent statement: Informed consent was received from the patient for the publication of the report and accompanying images. The patient read the submitted version of the report and confirmed its content.

Conflict-of-interest statement: All authors declare that there are no conflicts of interest involved.

CARE Checklist (2016) statement: The authors have read the CARE Checklist (2016), and the manuscript was prepared and revised according to the CARE Checklist (2016).

Hu-Di Xu, The State Key Laboratory Breeding Base of Basic Science of Stomatology (Hubei-MOST) and Key Laboratory of Oral Biomedicine Ministry of Education, Wuhan University, Wuhan 430079, Hubei Province, China

Richard J Miron, Department of Periodontology, College of Dental Medicine, Nova Southeastern University, Fort Lauderdale, FL 33314-7796, United States

Xiao-Xin Zhang, Yu-Feng Zhang, Department of Oral Implantology, School of Stomatology, Wuhan University, Wuhan 430079, Hubei Province, China

Corresponding author: Xiao-Xin Zhang, DDS, MD, PhD, Academic Research, Attending Doctor, Doctor, Surgeon, Teacher, Department of Oral Implantology, Wuhan University, 237 Luoyu Road, Wuhan 430079, Hubei Province, China. zhangxiaoxin@whu.edu.cn

Telephone: +86-27-87686600

Fax: +86-27-87686600

Abstract

BACKGROUND

The history of allogenic tooth transplantation can be traced back to the 16th century. Although there have been many successful cases, much needs to be better understood and researched prior to the technique being translated to everyday clinical practice.

CASE SUMMARY

In the present report, we describe a case of allogenic tooth transplantation between a mother and her daughter. The first left maxillary molar of the mother was diagnosed with residual root resorption and needed to be extracted. The 3rd molar of the daughter was used as a donor tooth. Prior to transplantation, a 3D printing system was introduced to fabricate an individualized reamer drill specifically designed utilizing the donor's tooth as a template. The specific design of our 3D printed bur allowed for the recipient site to better match the donor tooth. With the ability to 3D print in layers, even the protuberance of the root can be matched and 3D printed, thereby minimizing unnecessary bone loss.

CONCLUSION

Our study is a pioneering case combining 3D printing with allogenic tooth transplantation, which could be able to minimize unnecessary bone loss and improve the implant stability. This article aims to enhance our understanding of allogenic tooth transplantation and 3D printing, and may potentially lead to tooth transplantation being utilized more frequently - especially since transplantations are so commonly utilized in many other fields of medicine with high success

Open-Access: This article is an open-access article which was selected by an in-house editor and fully peer-reviewed by external reviewers. It is distributed in accordance with the Creative Commons Attribution Non Commercial (CC BY-NC 4.0) license, which permits others to distribute, remix, adapt, build upon this work non-commercially, and license their derivative works on different terms, provided the original work is properly cited and the use is non-commercial. See: <http://creativecommons.org/licenses/by-nc/4.0/>

Manuscript source: Unsolicited manuscript

Received: April 11, 2019

Peer-review started: April 12, 2019

First decision: May 31, 2019

Revised: June 25, 2019

Accepted: July 20, 2019

Article in press: July 20, 2019

Published online: September 6, 2019

P-Reviewer: Gonzalez F

S-Editor: Dou Y

L-Editor: Wang TQ

E-Editor: Xing YX



rates.

Key words: Transplantation; Allografts; Dental implants; 3D printing; Case report

©The Author(s) 2019. Published by Baishideng Publishing Group Inc. All rights reserved.

Core tip: The history of allogenic tooth transplantation can be traced back to the 16th century. Although there have been many successful cases, much needs to be better understood and researched prior to the technique being translated to everyday clinical practice. Our study is a pioneering case combining 3D printing with allogenic tooth transplantation, which could be able to minimize unnecessary bone loss and improve the implant stability. What's more, a review of the previous relevant research and the potential future avenues of research related to the novel introduction of 3D printing for tooth transplantation cases was performed.

Citation: Xu HD, Miron RJ, Zhang XX, Zhang YF. Allogenic tooth transplantation using 3D printing: A case report and review of the literature. *World J Clin Cases* 2019; 7(17): 2587-2596

URL: <https://www.wjgnet.com/2307-8960/full/v7/i17/2587.htm>

DOI: <https://dx.doi.org/10.12998/wjcc.v7.i17.2587>

INTRODUCTION

The history of allogenic tooth transplantation can be traced back to the 16th century, particularly during the last decades of the 20th century. While individual organs are often transplanted from one individual to the next, in the dental field, transplantation of teeth is much less frequently performed. Several innovations from basic and clinical translational research has improved patient matching tests and clinical techniques^[1,2]. Allogenic tooth transplantation refers to tooth grafting between two individuals of the same species whereas autogenic tooth transplantation indicates tooth grafting from one site to another in the same individual^[3]. Atkinson reported in the 1970s that an autograft can be orthotopic (when transplanted to the natural location) or heterotopic (when transplanted to a completely different site). Generally, allografts are rejected by immune cells, which may cause the most common histopathological symptoms including chronic inflammatory infiltration of the grafted tissue^[4,5]. However, a few cases of allogenic tooth transplantation have been reported^[6]. Little progress has been made owing to the high rate of potential immunological rejections and the increased use of titanium dental implants^[7]. Nevertheless, allografts can still function normally and often symptomless for many years^[8].

There are many successful cases of allo-transplantation. Ole Schwartz reported 73 allotransplanting cases which were carried out by three surgeons in humans from 1956 to 1980^[9]. The mean functional (without symptoms) time of the grafted teeth was 6.8 years (maximum 28.5 years, which is also the maximum observation period)^[4,6,9]. This study illustrates the potential long-term survival rates of allograft tooth transplants with rates influenced by a series of factors.

In previous cases, since differences in root shape and length exist, surgeons have had to reposition the donor tooth back to its original socket and remodel the recipient site with a round implant bur^[10]. The remodeling of the recipient site adds additional time to the surgical procedure with the possibility of surgically removing more bone than needed, which could totally be improved by the utilization of 3D printing. Today, 3D printing has been used widely in many fields of organ engineering^[11-17]. A typical 3D printing process involves data collection, model analysis, structure design, and final manufacture. Specifically, data initially can be collected by a variety of systems including computed tomography (CT), digital scanning, magnetic resonance imaging, and other image modality systems^[18]. Computer-aided design (CAD) software was followed by a precisely conducted 3D printing process controlled by a computer-aided manufacturing printer. The advantages of 3D printing include accurate control of material distribution, fast speed, scalability, and cost-effectiveness, which render this technology highly suitable and relevant in many areas of medicine including dentistry^[19,20]. One of the greatest advantages of 3D printing in tooth transplantation is that osteotomy drills can be customized to the three-dimensional

geometry of the tooth root of the individual donor^[21]. Such drills allow an optimal integration of transplanted tooth without unnecessary compression of tissues that may occur with standard burs, minimize unnecessary bone loss, and improve the implant stability^[22,23]. Furthermore, allogenic tooth transplantation could be an alternative solution for financially compromised patients that by-pass the need for additional costs including an implant, abutment, and final crown. This case report is the first published case combining 3D printing technology for tooth transplantation, which aims to inspire future research endeavors into this largely unstudied field.

CASE PRESENTATION

Chief complaints

A 47-year-old Chinese patient presented to the dental clinic at Wuhan University with a missing 1st molar for 2 mo. Her daughter (the donor) was a 21-year-old dental student with an impacted wisdom tooth.

History of present illness

The first left maxillary molar of the patient had been extracted in a private dental clinic 2 mo prior to the tooth transplantation. The root canal treatment for the 1st molar has failed, and tooth extraction was conducted after the roots fractured. The donor recently extracted two right third molars 2 wk prior to the donation (upper and lower).

History of past illness

No other health conditions are reported.

Medication history

The patient is allergic to penicillin.

Personal and family history

The mother has hypertension.

Physical examination upon admission

In the initial physical examination, the patient had a blood pressure of 128/84 mmHg with a pulse rate of 79 beats per minute (bpm). And the donor had a blood pressure of 92/62 mmHg with a pulse rate of 82 bpm. The extraction wound was well healed, and the anteroposterior gap of the defect was acceptable. The mandibular and maxillary distance had not been compromised, and the buccolingual width was about 7 mm. No obvious inclination of adjacent teeth was observed for the patient. The patient's oral hygiene was acceptable, with little microbial plaque accumulation or associated trauma (Figure 1).

Laboratory examinations

The patient has an O blood type. The donor presents with an A blood type. Routine blood count and coagulation profile for both the patient and donor were within normal limits.

Imaging examinations

Cone beam computed tomography (CBCT) of the donor revealed a tapered root shape different in morphology from the recipient's residual 1st maxillary molar root (3 roots), which eliminated the potential for an immediate transplantation. The lower 3rd mandibular molar (the donor tooth) was scanned, and the data of the morphology were collected and analyzed before an individualized implant drill was designed to match the contour of the donor tooth roots, with expectation that the shape of the recipient site could be identical to that of the original socket. A direct metal laser sintering 3D printing system was introduced to manufacture the drill (Figure 2).

FINAL DIAGNOSIS

Maxillary dentition defect.

TREATMENT

The individual drill was produced by Wuhan Tianyu Intelligent Manufacturing

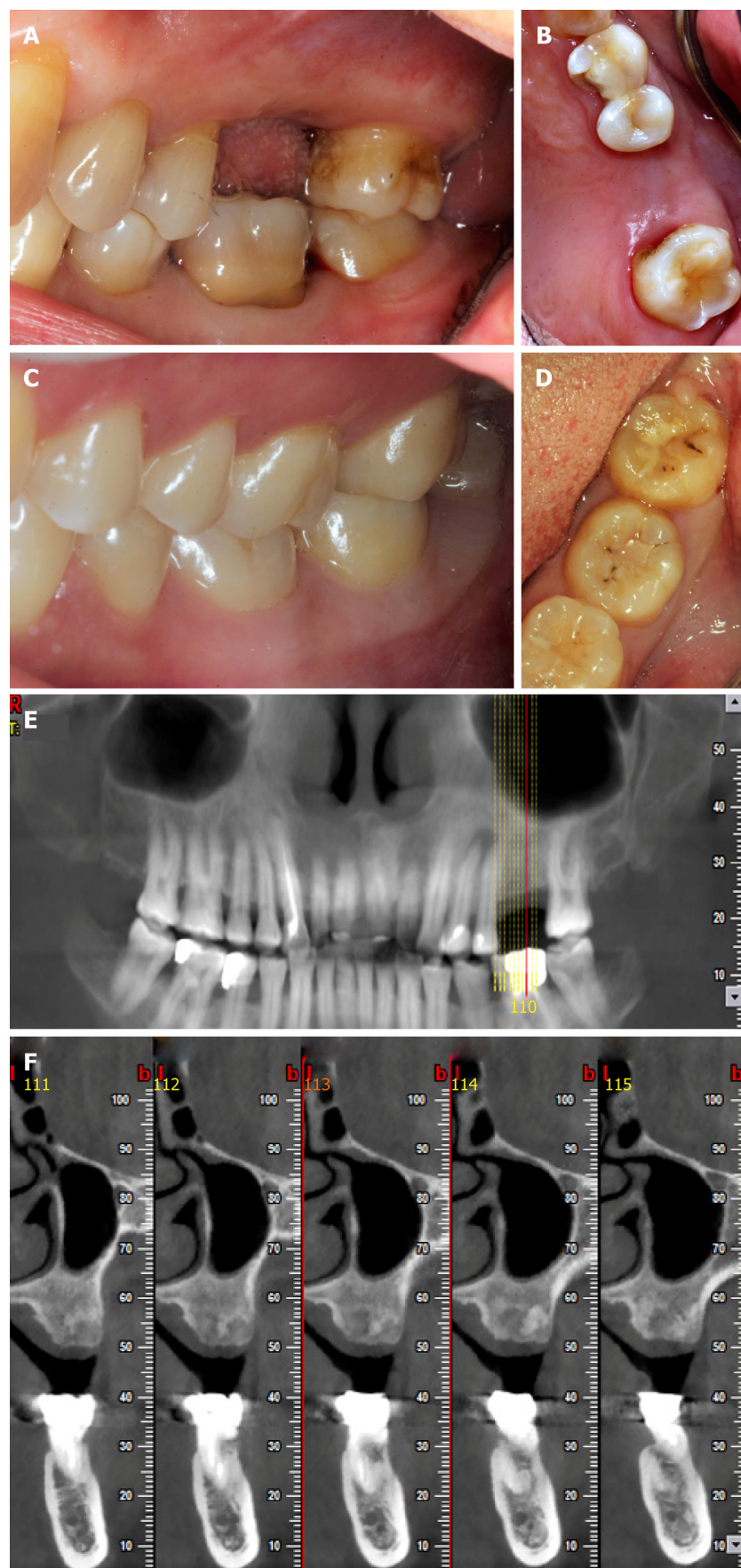


Figure 1 Preoperative photos and computed tomography scan of the donor and the recipient. A and B: Occlusal photos showing the recipient's missing #26; C and D: Occlusal photos showing the donor's #48; E: The recipient's orthopantomogram taken before the surgery; F: Computed tomography image showing the cross section of the bone at #26.

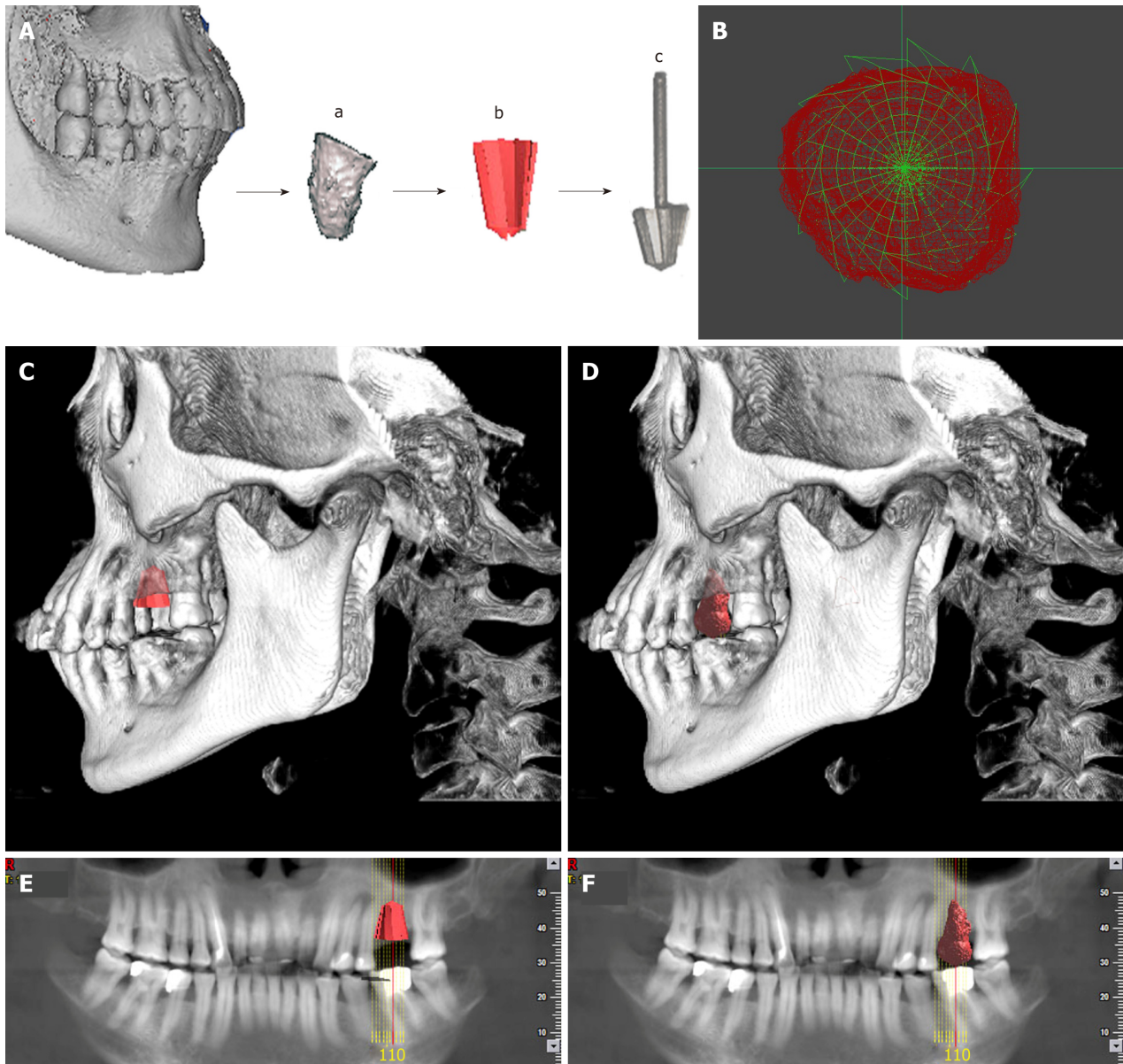


Figure 2 Individual drill compared with donor's tooth. A: The 3D image of the donor's tooth was extracted from the cone beam computed tomography, a computer-aided design model was built using measuring instrument to gather information for the shape and size, and an individual drill was manufactured by direct metal laser sintering; B: The cross section comparison of the individual drill and the donor's tooth; C and E: The model of the drill in the recipient's alveolar bone; D and F: The model of the donor's tooth in the recipient's alveolar bone.

Company using direct metal laser sintering as follows: (1) The 3d image of the donor's tooth was extracted from the CBCT; (2) The data of the donor's CBCT were imported into a STEP format CAD file using CAD software; (3) A CAD model was built using a measuring instrument to gather information regarding the shape and size of the tooth; (4) The shape of the drill was designed according to the donor's tooth, and the taper and the base of the drill were in accordance with the tooth's taper and the cervix, and then transferred into a CAD model; (5) The model was then sliced into discrete horizontal layers; and (6) A high-powered laser beam was focused onto a bed of powdered metal to fuse the model layer by layer. Each layer was printed followed by a subsequent layer of powder and printing to produce the next slice of the framework and fused with the first until all layers have been completely built. The laser was utilized to fuse the metal powder into metal solid particles and control their trajectory accurately.

In order to mitigate a potential immunological rejection, the tooth which was carefully extracted with minimal trauma was treated with solutions of 10 g/L cephalosporin, 75 g/L clindamycin hydrochloride, and 50 g/L aspirin in sequence. Then the pilot hole was expanded with progressively wider drills, and the preparation was completed using the 3D printed individual drill. The autogenous bone was collected during the entire drill preparation technique and utilized to fill the

compartment. After suture, the tooth was splinted with an acid-etch resin composite splint (Figure 3). The recipient was treated with antibiotics and a compound gargle solution of chlorhexidine gluconate was utilized for 2 wk. The follow-up radiographs and photos were taken after surgery (Figure 4).

OUTCOME AND FOLLOW-UP

Inflammation in the periodontal area was observed during healing 1 wk after transplantation. Resorption initiated after 2 wk, which was further increased after 4 and 8 wk. Replacement resorption on the external surface showed increasing appearance time, initiating at 4 wk. The periodontal ligament was no longer visible by X-ray after 4 wk. No pain or swelling was present; however, the height of the peri-implant papillae began to show some recession. The outcome was less than optimal or reported previously and further observations are needed. Other tooth treating methods such as sintering will be studied and carried out in the future.

DISCUSSION

The history of tooth transplantation

Allogenic tooth transplantation has been utilized for five decades with publications occurring in the literature at irregular intervals^[3]. While studies regarding the immunological aspects of tooth transplantation were not published until 1963^[24], more recently, a greater number of studies concerning these aspects have been performed, demonstrating that teeth can be antigenic and elicit an immune response from the host patient^[4]. Today, an overgrowing research development is placed on whole tooth regeneration, yet research in this field remains wishful. Advances in molecular biology, experimental embryology, developmental biology, and bioengineering may one day overcome present limitations^[25]. Nevertheless, tooth transplantation has received very little research in comparison owing largely to the developing field of dental implants. In general, the number of tooth transplantation cases have been decreasing and the utilization of new and modern bioengineering techniques and findings from immunological research have been seldom applied to transplantation research in the dental field. This makes this case report provide an insight into the potential development of future avenues of research and discovery in the field of tooth transplantation.

Complications

Root resorption is reported to be the most relevant complication in tooth transplantation and plays an important role in the long-term prognosis of allotransplanted teeth. However, it is also very common in the first few weeks following surgery. It has been suggested that the selection of autogenic tooth versus allogenic tooth is prominent to reduce the apoptosis of odontoblast-lineage cells, but this study also showed that the immunological rejection may have nothing to do with periodontal tissues^[26,27].

Root resorption usually happens as replacement resorption and inflammatory resorption^[28]. In previous cases, a surgeon had to remodel the recipient site to the according donor root sizes, which would definitely increase the surgical time required to transplant the tooth, and therefore worsen the prognosis as well as potentially lead to greater bone loss without the precise bur size created from the donor tooth^[10]. The replacement resorption is reported to be a response to the operative trauma, which can be lightened by the use of 3D printed burs. Alloimmune rejection also plays an important role during root resorption. Inflammatory resorption can be affected by the endodontic treatment and interestingly the age of recipient^[8].

There is also a potential for loss of marginal periodontal attachment which can be caused by pre/preoperative loss of bone and/or inflammation as a result of donor tooth root fracture^[8]. As a result, a number of cases end up being failed/lost. Accordingly, a previously study conducted by Schwartz *et al*^[6] found that after 10 years, 76% of allograft tooth transplants were lost and after 15 years, only six grafts (8.2%) were still in function. The findings further concluded that the cause of graft loss was root resorption in 38 cases, inflammatory resorption in 11, replacement resorption in 27, marginal periodontal complication in 2, apical periodontitis in 1, prosthetic failure in 1, and an unknown etiology in 3^[8].

In our case report, a similar failure caused by resorption is expected. Nevertheless, this case report is the first attempt at combining modern 3D imaging and printing with allogenic tooth transplantation, which demonstrated plenty of advantages such

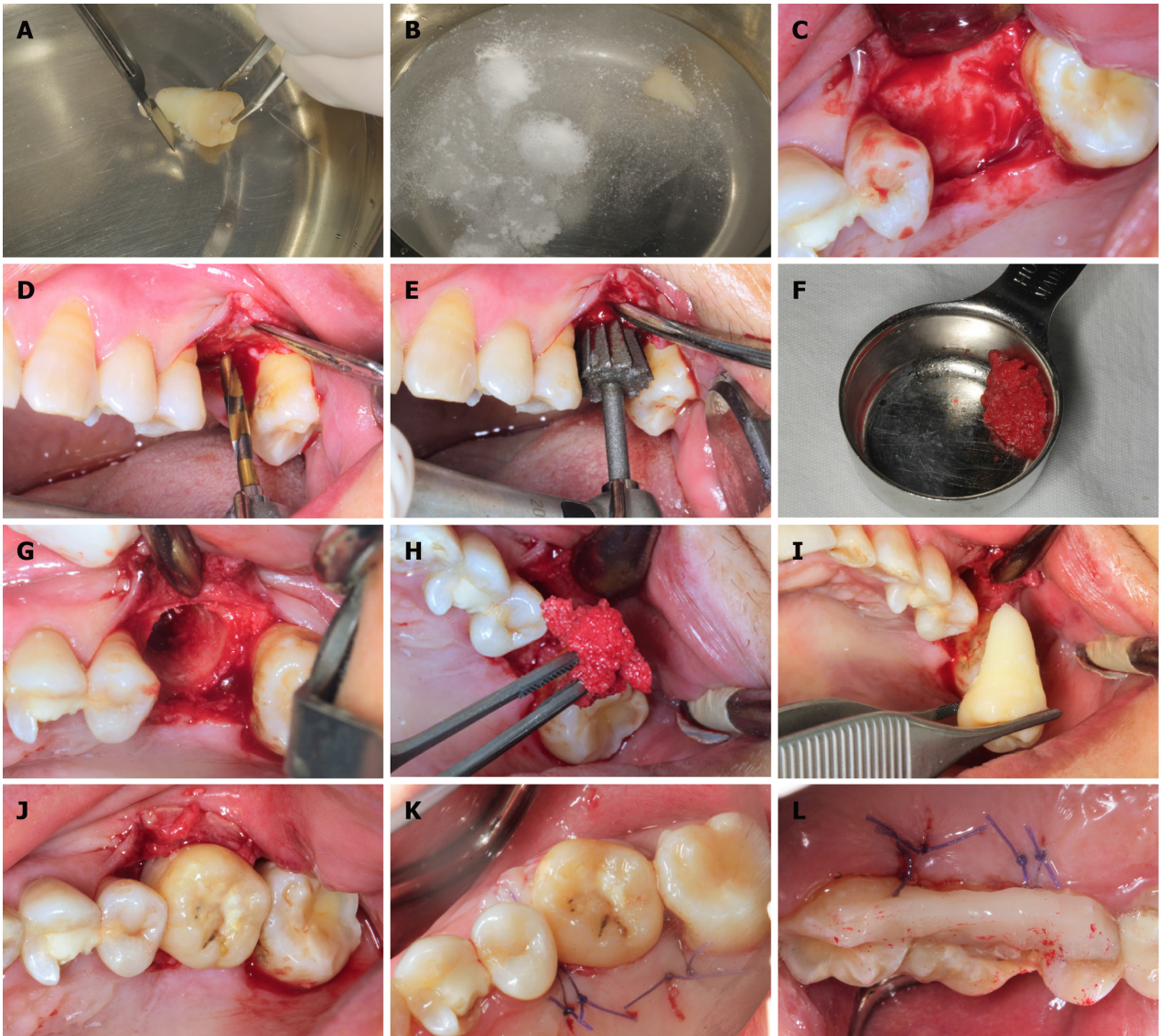


Figure 3 Surgical procedure. A: The donor's tooth was extracted, then the attached gingival was gently removed, but the periodontal ligament was kept; B: Treatment with solutions of 10 g/L cephalosporin, 75 g/L clindamycin hydrochloride, and 50 g/L aspirin in sequence; C: Soft tissue reflection; D: Expanding the pilot hole by using progressively wider drills; E: Finishing the preparation by using the individual drill; F: Collecting the autogenous bone during the hole preparation; G and H: Applying the autogenous bone to fill the compartment; I and J: Transplanting the tooth to the recipient's site; K: Suture; L: Splinting the tooth with an acid-etch resin composite splint.

as an accurate control of material distribution, lower surgical times required, better stability of the transplanted tooth owing to the 3D morphology of the bur, and cost-effectiveness^[19,20,29]. With the utilization of 3D printing during tooth transplantation, it is expected that surgical trauma will be minimized with better final tooth stability. Based on previous publications, the use of aspirin was utilized as a means to minimize alloimmune rejection^[30]. Aspirin has been shown to inhibit TNF- α and IFN- γ levels and reverse proinflammatory cytokines which may cause a higher immune response, leading to apoptosis of bone marrow mesenchymal stem cells^[31].

Prevention and treatment of late effects after allogenic tooth transplantation

To date there have been quite a few methods to inhibit alloimmune rejections, including donor and recipient's matching test, minimizing movement of the periodontal ligament of transplanted teeth, endodontic treatment prior to transplantation, repeated freezing treatment, irradiation of donor's teeth, and treatment with fluorinated fluid^[32,33]. For instance, although Schwartz *et al*^[34] used a monkey model to study the influence of endodontic treatment, and found that the teeth that were endodontically treated significantly decreased inflammatory resorption (almost totally eliminated, $P = 0.0003$), it had significantly increased replacement resorption ($P = 0.0004$)^[34]. Over 40 years ago, Robinson and Rowlands demonstrated that repeat freezing and thawing and incubation with collagenase and

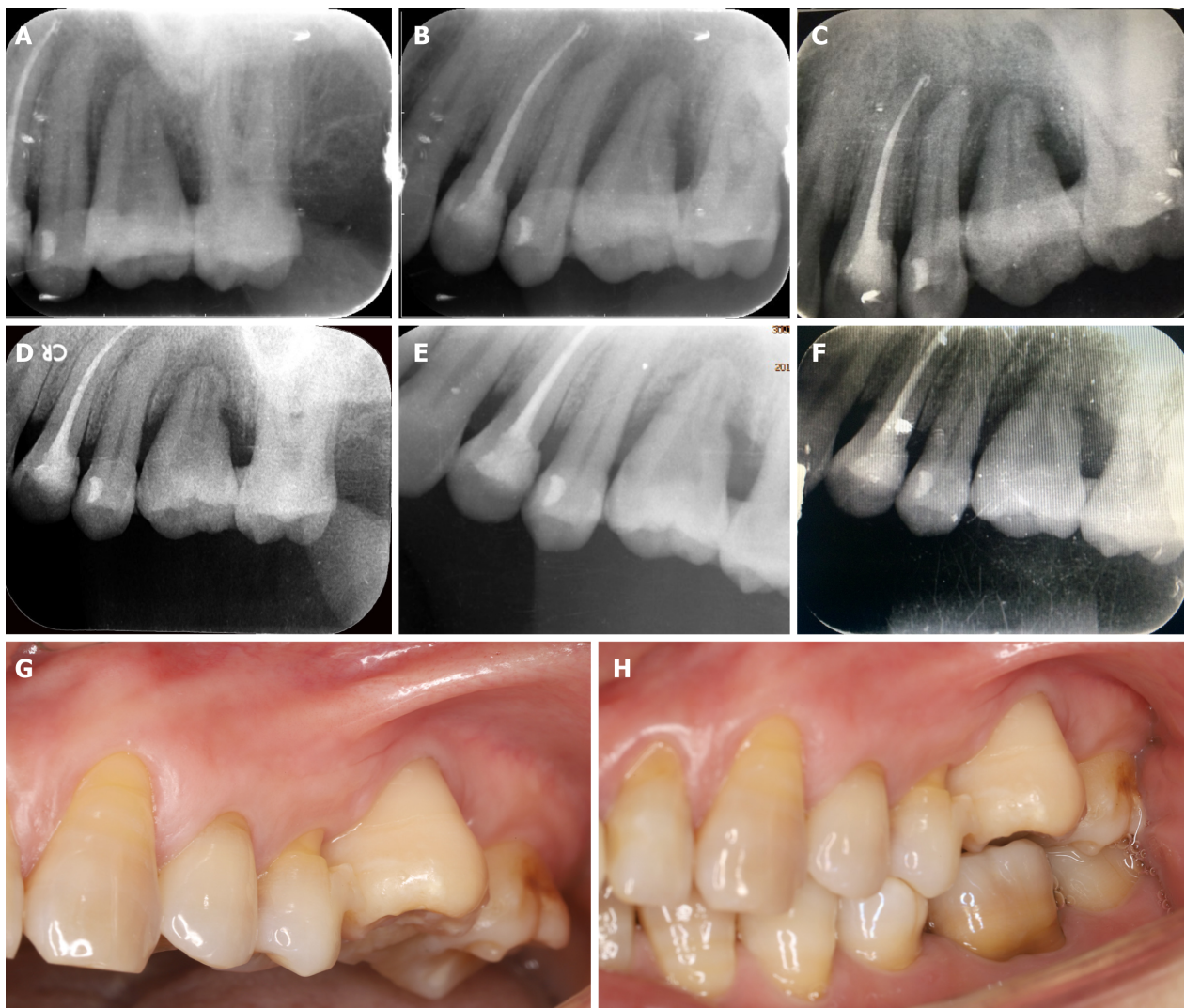


Figure 4 Periapical radiographs of the transplanted tooth after surgery. A: One day after transplantation; B: One week after transplantation; C: One month after transplantation, inflammatory resorption and replacement resorption were progressing; D: Two months after transplantation; E: Three months after transplantation; F: Four months after transplantation, inflammatory resorption and replacement resorption were stable, and there was no appearance of normal periodontal ligament up to this time; G and H: Photos showing the transplanted tooth four months after surgery.

hyaluronidase turned the tooth grafts non-immunogenic^[35]. These reports are quite old, yet no recent attempts have been made to further investigate if tooth transplantation can become a routine clinical procedure.

The manufacturing process of the individual drill: Direct metal laser sintering

3D printing and bioprinting are modalities of additive manufacturing. Compared to other techniques used in tissue engineering, 3D printing has the advantages of accurate precision, resolution, efficiency, and accuracy^[16,23]. Four main 3D printing techniques exist including inkjet, laser-assisted, extrusion, and stereolithography printing^[36-39]. Although autogenic and allogenic tooth transplantation has a long history of use, several limitations still exist. In previous cases, since differences in root shape and length exist, surgeons have had to reposition the donor tooth back to its original socket and remodel the recipient site with a round implant bur^[10]. The remodeling of the recipient site adds additional time to the surgical procedure with the possibility of surgically removing more bone than needed. In the present case report, the specific design of our 3D printed bur allowed for the recipient site to better match the donor tooth. With the ability to 3D print in layers, even the protuberance of the root can be matched and 3D printed, thereby minimizing unnecessary bone loss.

There are many factors that may affect the implanted tooth's primary stability including bone quality and quantity, surgical technique utilized, and the tooth geometry^[40]. Since the shape of the donor's and recipient's roots are generally mismatching, implant stability is hard to predict and therefore the advantages of 3D printing may provide a better solution to the current standards. The advantages of 3D

printing include accurate control of material distribution and sizing, fast production, scalability, and cost-effectiveness, which have made this technology successful in many areas of medicine with positive outcomes^[19,20]. It is therefore conceivable that since various allogenic transplantations are utilized in many areas of medicine including heart, lungs, kidneys, and other complex organs, the ability for dental clinicians to utilize this technique in the coming years should not be deemed unrealistic. With the advancements made in modern medicine and tissue engineering, future research endeavors should be geared towards utilizing this low-cost modality where 3D printing may help improve the predictability of such cases. In the present case, we report the first published attempt at utilizing 3D printing during a tooth transplantation procedure. Future research is necessary to further improve this technology, but this article offers a pioneering first attempt at such a therapy.

CONCLUSION

Our study presents a pioneering case combining 3D printing with allogenic tooth transplantation. A 3D printing system was introduced to print an individualized reamer drill for preparing the implant placement bed and the donor's tooth as a template for the drill. With the utilization of 3D printing, the surgical trauma was minimized and the tooth implant stability was more suitable. A detailed progress and prognosis of this cases were recorded, which makes the case very useful for reference purposes since it is the first study of its kind. Other tooth treating methods such as sintering will be studied and carried out in the future. This article hopes to enhance our understanding of allogenic tooth transplantation and 3D printing, and may potentially lead to tooth transplantation being utilized more frequently - especially since transplantations are so commonly utilized in many other fields of medicine with high success rates.

REFERENCES

1. **Andreasen JO**, Paulsen HU, Yu Z, Bayer T, Schwartz O. A long-term study of 370 autotransplanted premolars. Part II. Tooth survival and pulp healing subsequent to transplantation. *Eur J Orthod* 1990; **12**: 14-24 [PMID: 2318259 DOI: 10.1093/Ejo/12.1.14]
2. **Adell R**. Tissue integrated prostheses in clinical dentistry. *Int Dent J* 1985; **35**: 259-265 [PMID: 3912327 DOI: 10.1016/0022-3913(85)90460-3]
3. **Atkinson ME**. Histopathological and immunological aspects of tooth transplantation. *J Oral Pathol* 1978; **7**: 43-61 [PMID: 96235 DOI: 10.1111/j.1600-0714.1978.tb01579.x]
4. **Atkinson ME**. A histological study of tooth allografts transplanted to untreated and immunologically prepared mice. *J Oral Pathol* 1975; **4**: 167-179 [PMID: 811777 DOI: 10.1111/j.1600-0714.1975.tb01740.x]
5. **Atkinson ME**. A histological study of tooth grafts in an inbred strain of mice. *J Oral Pathol* 1972; **1**: 115-124 [PMID: 4269384 DOI: 10.1111/j.1600-0714.1972.tb01910.x]
6. **Revathy V**, Suryakanth M, Poornima P, Subba Reddy VV. Allotransplantation of tooth: a case report. *J Clin Pediatr Dent* 2012; **37**: 1-4 [PMID: 23342558 DOI: 10.17796/jcpd.37.1.10621349257g0228]
7. **Meffert RM**, Langer B, Fritz ME. Dental implants: a review. *J Periodontol* 1992; **63**: 859-870 [PMID: 1453301 DOI: 10.1902/jop.1992.63.11.859]
8. **Schwartz O**, Frederiksen K, Klausen B. Allotransplantation of human teeth. A retrospective study of 73 transplantations over a period of 28 years. *Int J Oral Maxillofac Surg* 1987; **16**: 285-301 [PMID: 3112258 DOI: 10.1016/S0901-5027(87)80149-2]
9. **Nordenram A**. Allogeneic tooth transplantation with an observation time of 16 years. Clinical report of 32 cases. *Swed Dent J* 1982; **6**: 149-156 [PMID: 6960499 DOI: 10.1097/00007890-196910000-00003]
10. **Herrera H**, Herrera H, Leonardo MR, de Paula e Silva FW, da Silva LA. Treatment of external inflammatory root resorption after autogenous tooth transplantation: case report. *Oral Surg Oral Med Oral Pathol Oral Radiol Endod* 2006; **102**: e51-e54 [PMID: 17138168 DOI: 10.1016/j.tripleo.2006.05.027]
11. **Xiang Gu G**, Su I, Sharma S, Voros JL, Qin Z, Buehler MJ. Three-Dimensional-Printing of Bio-Inspired Composites. *J Biomech Eng* 2016; **138**: 021006 [PMID: 26747791 DOI: 10.1115/1.4032423]
12. **Seunarine K**, Gadegaard N, Tormen M, Meredith DO, Riehle MO, Wilkinson CD. 3D polymer scaffolds for tissue engineering. *Nanomedicine (Lond)* 2006; **1**: 281-296 [PMID: 17716159 DOI: 10.2217/17435889.1.3.281]
13. **Rasperini G**, Pilipchuk SP, Flanagan CL, Park CH, Pagni G, Hollister SJ, Giannobile WV. 3D-printed Bioresorbable Scaffold for Periodontal Repair. *J Dent Res* 2015; **94**: 153S-157S [PMID: 26124215 DOI: 10.1177/0022034515588303]
14. **Wang X**, Ao Q, Tian X, Fan J, Wei Y, Hou W, Tong H, Bai S. 3D Bioprinting Technologies for Hard Tissue and Organ Engineering. *Materials (Basel)* 2016; **9** [PMID: 28773924 DOI: 10.3390/ma9100802]
15. **Murphy SV**, Atala A. 3D bioprinting of tissues and organs. *Nat Biotechnol* 2014; **32**: 773-785 [PMID: 25093879 DOI: 10.1038/nbt.2958]
16. **Mandrycky C**, Wang Z, Kim K, Kim DH. 3D bioprinting for engineering complex tissues. *Biotechnol Adv* 2016; **34**: 422-434 [PMID: 26724184 DOI: 10.1016/j.biotechadv.2015.12.011]
17. **Bajaj P**, Schweller RM, Khademosseini A, West JL, Bashir R. 3D biofabrication strategies for tissue engineering and regenerative medicine. *Annu Rev Biomed Eng* 2014; **16**: 247-276 [PMID: 24905875 DOI: 10.1146/annurev-bioeng-071813-105155]
18. **Boyle I**, Rong YM, Brown DC. A review and analysis of current computer-aided fixture design

- approaches. *Robot Cim-Int Manuf* 2011; **27**: 1-12 [DOI: [10.1016/j.rcim.2010.05.008](https://doi.org/10.1016/j.rcim.2010.05.008)]
- 19 **Legemate K**, Tarafder S, Jun Y, Lee CH. Engineering Human TMJ Discs with Protein-Releasing 3D-Printed Scaffolds. *J Dent Res* 2016; **95**: 800-807 [PMID: [27053116](https://pubmed.ncbi.nlm.nih.gov/27053116/) DOI: [10.1177/0022034516642404](https://doi.org/10.1177/0022034516642404)]
- 20 **Shao H**, Sun M, Zhang F, Liu A, He Y, Fu J, Yang X, Wang H, Gou Z. Custom Repair of Mandibular Bone Defects with 3D Printed Bioceramic Scaffolds. *J Dent Res* 2018; **97**: 68-76 [PMID: [29020507](https://pubmed.ncbi.nlm.nih.gov/29020507/) DOI: [10.1177/0022034517734846](https://doi.org/10.1177/0022034517734846)]
- 21 **Jung JW**, Lee JS, Cho DW. Computer-aided multiple-head 3D printing system for printing of heterogeneous organ/tissue constructs. *Sci Rep* 2016; **6**: 21685 [PMID: [26899876](https://pubmed.ncbi.nlm.nih.gov/26899876/) DOI: [10.1038/srep21685](https://doi.org/10.1038/srep21685)]
- 22 **Atsumi M**, Park SH, Wang HL. Methods used to assess implant stability: current status. *Int J Oral Maxillofac Implants* 2007; **22**: 743-754 [PMID: [17974108](https://pubmed.ncbi.nlm.nih.gov/17974108/) DOI: [10.4103/0972-4052.246706](https://doi.org/10.4103/0972-4052.246706)]
- 23 **Mesa F**, Muñoz R, Noguerol B, de Dios Luna J, Galindo P, O'Valle F. Multivariate study of factors influencing primary dental implant stability. *Clin Oral Implants Res* 2008; **19**: 196-200 [PMID: [18039335](https://pubmed.ncbi.nlm.nih.gov/18039335/) DOI: [10.1111/j.1600-0501.2007.01450.x](https://doi.org/10.1111/j.1600-0501.2007.01450.x)]
- 24 **Cserepfalvi M**. Clinical report of homotransplantation. *J Am Dent Assoc* 1963; **67**: 35-40 [PMID: [14024116](https://pubmed.ncbi.nlm.nih.gov/14024116/) DOI: [10.14219/jada.archive.1963.0221](https://doi.org/10.14219/jada.archive.1963.0221)]
- 25 **Chai Y**, Slavkin HC. Prospects for tooth regeneration in the 21st century: a perspective. *Microsc Res Tech* 2003; **60**: 469-479 [PMID: [12619122](https://pubmed.ncbi.nlm.nih.gov/12619122/) DOI: [10.1002/jemt.10287](https://doi.org/10.1002/jemt.10287)]
- 26 **Unno H**, Suzuki H, Nakakura-Ohshima K, Jung HS, Ohshima H. Pulpal regeneration following allogenic tooth transplantation into mouse maxilla. *Anat Rec (Hoboken)* 2009; **292**: 570-579 [PMID: [19226618](https://pubmed.ncbi.nlm.nih.gov/19226618/) DOI: [10.1002/ar.20831](https://doi.org/10.1002/ar.20831)]
- 27 **Saito K**, Nakatomi M, Kenmotsu S, Ohshima H. Allogenic tooth transplantation inhibits the maintenance of dental pulp stem/progenitor cells in mice. *Cell Tissue Res* 2014; **356**: 357-367 [PMID: [24671256](https://pubmed.ncbi.nlm.nih.gov/24671256/) DOI: [10.1007/s00441-014-1818-8](https://doi.org/10.1007/s00441-014-1818-8)]
- 28 **Lin S**, Ashkenazi M, Karawan M, Teich ST, Gutmacher Z. Management of Ankyrotic Root Resorption Following Dental Trauma: A Short Review and Proposal of a Treatment Protocol. *Oral Health Prev Dent* 2017; **15**: 467-474 [PMID: [28761940](https://pubmed.ncbi.nlm.nih.gov/28761940/) DOI: [10.3290/j.ohpd.a38736](https://doi.org/10.3290/j.ohpd.a38736)]
- 29 **Diment LE**, Thompson MS, Bergmann JHM. Clinical efficacy and effectiveness of 3D printing: a systematic review. *BMJ Open* 2017; **7**: e016891 [PMID: [29273650](https://pubmed.ncbi.nlm.nih.gov/29273650/) DOI: [10.1136/bmjopen-2017-016891](https://doi.org/10.1136/bmjopen-2017-016891)]
- 30 **Shi S**, Yamaza T, Akiyama K. Is aspirin treatment an appropriate intervention to osteoporosis? *Fut Rheumatol* 2008; **3**: 499-502 [PMID: [20428329](https://pubmed.ncbi.nlm.nih.gov/20428329/) DOI: [10.2217/17460816.3.6.499](https://doi.org/10.2217/17460816.3.6.499)]
- 31 **Liu Y**, Wang L, Kikuri T, Akiyama K, Chen C, Xu X, Yang R, Chen W, Wang S, Shi S. Mesenchymal stem cell-based tissue regeneration is governed by recipient T lymphocytes via IFN- γ and TNF- α . *Nat Med* 2011; **17**: 1594-1601 [PMID: [22101767](https://pubmed.ncbi.nlm.nih.gov/22101767/) DOI: [10.1038/nm.2542](https://doi.org/10.1038/nm.2542)]
- 32 **Li W**, Deng F, Wang Y, Ma C, Wang Y. Immune tolerance of mice allogenic tooth transplantation induced by immature dendritic cells. *Int J Clin Exp Med* 2015; **8**: 5254-5262 [PMID: [26131099](https://pubmed.ncbi.nlm.nih.gov/26131099/) DOI: [10.1097/01.tp.0000330573.13016.80](https://doi.org/10.1097/01.tp.0000330573.13016.80)]
- 33 **Mellberg JR**, Shulman L. Treatment of human teeth with fluoride for replantation and allotransplantation. *J Dent Res* 1974; **53**: 844-846 [PMID: [4526376](https://pubmed.ncbi.nlm.nih.gov/4526376/) DOI: [10.1177/00220345740530041401](https://doi.org/10.1177/00220345740530041401)]
- 34 **Schwartz O**, Andreasen JO. Allotransplantation and autotransplantation of mature teeth in monkeys: the influence of endodontic treatment. *J Oral Maxillofac Surg* 1988; **46**: 672-681 [PMID: [3165121](https://pubmed.ncbi.nlm.nih.gov/3165121/) DOI: [10.1016/0278-2391\(88\)90110-3](https://doi.org/10.1016/0278-2391(88)90110-3)]
- 35 **Robinson PJ**, Rowlands DT. Evidence of the alloimmunogenic potential of donor periodontal ligament. *Am J Pathol* 1974; **75**: 503-512 [PMID: [4600773](https://pubmed.ncbi.nlm.nih.gov/4600773/) DOI: [10.1016/0022-3913\(86\)90357-4](https://doi.org/10.1016/0022-3913(86)90357-4)]
- 36 **Bilgin MS**, Erdem A, Dilber E, Ersoy İ. Comparison of fracture resistance between cast, CAD/CAM milling, and direct metal laser sintering metal post systems. *J Prosthodont Res* 2016; **60**: 23-28 [PMID: [26347450](https://pubmed.ncbi.nlm.nih.gov/26347450/) DOI: [10.1016/j.jpor.2015.08.001](https://doi.org/10.1016/j.jpor.2015.08.001)]
- 37 **Mangano F**, Chambrone L, van Noort R, Miller C, Hatton P, Mangano C. Direct metal laser sintering titanium dental implants: a review of the current literature. *Int J Biomater* 2014; **2014**: 461534 [PMID: [25525434](https://pubmed.ncbi.nlm.nih.gov/25525434/) DOI: [10.1155/2014/461534](https://doi.org/10.1155/2014/461534)]
- 38 **Prabhu R**, Prabhu G, Baskaran E, Arumugam EM. Clinical acceptability of metal-ceramic fixed partial dental prosthesis fabricated with direct metal laser sintering technique-5 year follow-up. *J Indian Prosthodont Soc* 2016; **16**: 193-197 [PMID: [27141171](https://pubmed.ncbi.nlm.nih.gov/27141171/) DOI: [10.4103/0972-4052.176526](https://doi.org/10.4103/0972-4052.176526)]
- 39 **Venkatesh KV**, Nandini VV. Direct metal laser sintering: a digitised metal casting technology. *J Indian Prosthodont Soc* 2013; **13**: 389-392 [PMID: [24431766](https://pubmed.ncbi.nlm.nih.gov/24431766/) DOI: [10.1007/s13191-013-0256-8](https://doi.org/10.1007/s13191-013-0256-8)]
- 40 **Sennerby L**, Roos J. Surgical determinants of clinical success of osseointegrated oral implants: a review of the literature. *Int J Prosthodont* 1998; **11**: 408-420 [PMID: [9922733](https://pubmed.ncbi.nlm.nih.gov/9922733/) DOI: [10.1038/sj.dmf.4600382](https://doi.org/10.1038/sj.dmf.4600382)]



Published By Baishideng Publishing Group Inc
7041 Koll Center Parkway, Suite 160, Pleasanton, CA 94566, USA
Telephone: +1-925-2238242
Fax: +1-925-2238243
E-mail: bpgoffice@wjgnet.com
Help Desk: <https://www.f6publishing.com/helpdesk>
<https://www.wjgnet.com>

