

World Journal of *Clinical Cases*

World J Clin Cases 2019 September 26; 7(18): 2658-2915



**OPINION REVIEW**

- 2658** Effective use of the Japan Narrow Band Imaging Expert Team classification based on diagnostic performance and confidence level
Hirata D, Kashida H, Iwatate M, Tochio T, Teramoto A, Sano Y, Kudo M

MINIREVIEWS

- 2666** Low fermentable oligosaccharides, disaccharides, monosaccharides, and polyols diet in children
Fodor I, Man SC, Dumitrascu DL
- 2675** High-resolution colonic manometry and its clinical application in patients with colonic dysmotility: A review
Li YW, Yu YJ, Fei F, Zheng MY, Zhang SW

ORIGINAL ARTICLE**Retrospective Study**

- 2687** Predictors of rebleeding and in-hospital mortality in patients with nonvariceal upper digestive bleeding
Lazăr DC, Ursoniu S, Goldiș A
- 2704** Analgesic effect of parecoxib combined with ropivacaine in patients undergoing laparoscopic hepatectomy
Huang SS, Lv WW, Liu YF, Yang SZ
- 2712** Prognostic significance of 14v-lymph node dissection to D2 dissection for lower-third gastric cancer
Zheng C, Gao ZM, Sun AQ, Huang HB, Wang ZN, Li K, Gao S

Observational Study

- 2722** Wall shear stress can improve prediction accuracy for transient ischemic attack
Liu QY, Duan Q, Fu XH, Jiang M, Xia HW, Wan YL

Prospective Study

- 2734** Characterization of microbiota in systemic-onset juvenile idiopathic arthritis with different disease severities
Dong YQ, Wang W, Li J, Ma MS, Zhong LQ, Wei QJ, Song HM

SYSTEMATIC REVIEWS

- 2746** Sinusoidal obstruction syndrome: A systematic review of etiologies, clinical symptoms, and magnetic resonance imaging features
Zhang Y, Jiang HY, Wei Y, Song B

META-ANALYSIS

- 2760 Respiratory training interventions improve health status of heart failure patients: A systematic review and network meta-analysis of randomized controlled trials
Wang MH, Yeh ML

CASE REPORT

- 2776 *Mycobacterium chimaera* infections following cardiac surgery in Treviso Hospital, Italy, from 2016 to 2019: Cases report
Inojosa WO, Giobbia M, Muffato G, Minniti G, Baldasso F, Carniato A, Farina F, Forner G, Rossi MC, Formentini S, Rigoli R, Scotton PG
- 2787 Giant squamous cell carcinoma of the gallbladder: A case report
Junior MAR, Favaro MDL, Santin S, Silva CM, Iamarino APM
- 2794 Liver re-transplantation for donor-derived neuroendocrine tumor: A case report
Mrzljak A, Kocman B, Skrtic A, Furac I, Popic J, Franusic L, Zunec R, Mayer D, Mikulic D
- 2802 Calcifying fibrous tumor originating from the gastrohepatic ligament that mimicked a gastric submucosal tumor: A case report
Kwan BS, Cho DH
- 2808 Pancreatitis, panniculitis, and polyarthritis syndrome caused by pancreatic pseudocyst: A case report
Jo S, Song S
- 2815 Glomus tumor of uncertain malignant potential of the brachial plexus: A case report
Thanindrarn P, Chobpenthai T, Phorkhar T, Nelson SD
- 2823 Conservative pulp treatment for Oehlers type III dens invaginatus: A case report
Lee HN, Chen YK, Chen CH, Huang CY, Su YH, Huang YW, Chuang FH
- 2831 Propofol pump controls nonconvulsive status epilepticus in a hepatic encephalopathy patient: A case report
Hor S, Chen CY, Tsai ST
- 2838 Teriparatide as nonoperative treatment for femoral shaft atrophic nonunion: A case report
Tsai MH, Hu CC
- 2843 Successful repair of acute type A aortic dissection during pregnancy at 16th gestational week with maternal and fetal survival: A case report and review of the literature
Chen SW, Zhong YL, Ge YP, Qiao ZY, Li CN, Zhu JM, Sun LZ
- 2851 Inferior pancreaticoduodenal artery pseudoaneurysm in a patient with calculous cholecystitis: A case report
Xu QD, Gu SG, Liang JH, Zheng SD, Lin ZH, Zhang PD, Yan J

- 2857** ALK-positive anaplastic large cell lymphoma of the thoracic spine occurring in pregnancy: A case report
Yang S, Jiang WM, Yang HL
- 2864** Endoscopic mucosal resection of a bile duct polyp: A case report
Yang S, Yang L, Wang XY, Yang YM
- 2871** Multiple gastric adenocarcinoma of fundic gland type: A case report
Chen O, Shao ZY, Qiu X, Zhang GP
- 2879** Repair of the portal vein using a hepatic ligamentum teres patch for laparoscopic pancreatoduodenectomy: A case report
Wei Q, Chen QP, Guan QH, Zhu WT
- 2888** Drug coated balloon angioplasty for renal artery stenosis due to Takayasu arteritis: Report of five cases
Bi YH, Ren JZ, Yi MF, Li JD, Han XW
- 2894** Entrapment of the temporal horn secondary to postoperative gamma-knife radiosurgery in intraventricular meningioma: A case report
Liu J, Long SR, Li GY
- 2899** Pleomorphic lipoma in the anterior mediastinum: A case report
Mao YQ, Liu XY, Han Y
- 2905** Guillain-Barré syndrome in a patient with multiple myeloma after bortezomib therapy: A case report
Xu YL, Zhao WH, Tang ZY, Li ZQ, Long Y, Cheng P, Luo J
- 2910** Bowen's disease on the palm: A case report
Yu SR, Zhang JZ, Pu XM, Kang XJ

ABOUT COVER

Editorial Board Member of *World Journal of Clinical Cases*, Shao-Ping Yu, MD, Associate Professor, Chief Doctor, Department of Gastroenterology and Hepatology, Dongguan Kanghua Hospital, Dongguan 523080, Guangdong Province, China

AIMS AND SCOPE

The primary aim of *World Journal of Clinical Cases* (*WJCC*, *World J Clin Cases*) is to provide scholars and readers from various fields of clinical medicine with a platform to publish high-quality clinical research articles and communicate their research findings online.

WJCC mainly publishes case reports, case series, and articles reporting research results and findings obtained in the field of clinical medicine and covering a wide range of topics including diagnostic, therapeutic, and preventive modalities.

INDEXING/ABSTRACTING

The *WJCC* is now indexed in PubMed, PubMed Central, Science Citation Index Expanded (also known as SciSearch®), and Journal Citation Reports/Science Edition. The 2019 Edition of Journal Citation Reports cites the 2018 impact factor for *WJCC* as 1.153 (5-year impact factor: N/A), ranking *WJCC* as 99 among 160 journals in Medicine, General and Internal (quartile in category Q3).

RESPONSIBLE EDITORS FOR THIS ISSUE

Responsible Electronic Editor: Ji-Hong Liu

Proofing Production Department Director: Yun-Xiaoqian Wu

NAME OF JOURNAL

World Journal of Clinical Cases

ISSN

ISSN 2307-8960 (online)

LAUNCH DATE

April 16, 2013

FREQUENCY

Semimonthly

EDITORS-IN-CHIEF

Dennis A Bloomfield, Bao-Gan Peng, Sandro Vento

EDITORIAL BOARD MEMBERS

<https://www.wjgnet.com/2307-8960/editorialboard.htm>

EDITORIAL OFFICE

Jin-Lei Wang, Director

PUBLICATION DATE

September 26, 2019

COPYRIGHT

© 2019 Baishideng Publishing Group Inc

INSTRUCTIONS TO AUTHORS

<https://www.wjgnet.com/bpg/gerinfo/204>

GUIDELINES FOR ETHICS DOCUMENTS

<https://www.wjgnet.com/bpg/GerInfo/287>

GUIDELINES FOR NON-NATIVE SPEAKERS OF ENGLISH

<https://www.wjgnet.com/bpg/gerinfo/240>

PUBLICATION MISCONDUCT

<https://www.wjgnet.com/bpg/gerinfo/208>

ARTICLE PROCESSING CHARGE

<https://www.wjgnet.com/bpg/gerinfo/242>

STEPS FOR SUBMITTING MANUSCRIPTS

<https://www.wjgnet.com/bpg/GerInfo/239>

ONLINE SUBMISSION

<https://www.f6publishing.com>

Endoscopic mucosal resection of a bile duct polyp: A case report

Shu Yang, Li Yang, Xiang-Yang Wang, Yu-Ming Yang

ORCID number: Shu Yang (0000-0002-2423-7649); Li Yang (0000-0002-9721-7702); Xiang-Yang Wang (0000-0002-4442-6279); Yu-Ming Yang (0000-0003-1898-7723).

Author contributions: Yang S drafted the manuscript; Yang S, Yang L, and Wang XY collected the clinical data from the patient; Yang YM performed the surgical treatment, designed the case report, and revised the manuscript. All authors have read and approved the final manuscript.

Informed consent statement: Consent was obtained from the patient's son for the publication of this report, all accompanying images, and the video.

Conflict-of-interest statement: The authors declare that they have no conflict of interest.

CARE Checklist (2016) statement: The authors have read the CARE Checklist (2016), and the manuscript was prepared and revised according to the CARE Checklist (2016).

Open-Access: This article is an open-access article which was selected by an in-house editor and fully peer-reviewed by external reviewers. It is distributed in accordance with the Creative Commons Attribution Non Commercial (CC BY-NC 4.0) license, which permits others to distribute, remix, adapt, build upon this work non-commercially, and license their derivative works on different terms, provided the original work is properly cited and the use is non-commercial. See: <http://creativecommons.org/licenses/by-nc/4.0/>

Shu Yang, Department of Orthopaedics, The Second Xiangya Hospital, Central South University, Changsha 410011, Hunan Province, China

Li Yang, Xiang-Yang Wang, Yu-Ming Yang, Department of Gastroenterology, Hunan Provincial People's Hospital, Hunan Normal University, Changsha 410011, Hunan Province, China

Corresponding author: Yu-Ming Yang, MD, Professor, Department of Gastroenterology, Hunan Provincial People's Hospital, Hunan Normal University, 61 Jiefang West Road, Changsha 410011, Hunan Province, China. akm762mm@163.com

Telephone: +86-731-85295126

Fax: +86-731-85295126

Abstract

BACKGROUND

Bile duct polyps are difficult to diagnose and are usually excised by open abdominal surgery or snare polypectomy using choledochoscopy *via* the T-tube sinus tract. However, these two resection methods require the surgeon to open the abdomen and cut the bile duct to place the "T" tube. Moreover, simple snare polypectomy, without submucosal injection, can only remove pedunculated polyps and not flat polyps. Therefore, a new method is required for the excision of bile duct polyps, including flat polyps.

CASE SUMMARY

A 63-year-old woman was hospitalized following epigastric pain lasting a month. She had a 30-year history of cholelithiasis and had undergone cholecystectomy because of cholecystolithiasis, and had undergone cholangiolithotomy twice due to choledocholithiasis. Computed tomography (CT) and magnetic resonance imaging showed a communication between the bile duct and duodenal bulb. Inside the communication, CT showed a high-density shadow which was a hypointense lesion in T2 weighted image. The lesion showed no enhancement in T1 weighted image contrast enhanced. Gastroscopy revealed an incarcerated bile duct stone in the anterior wall of the duodenal bulb, which was removed with a basket under gastroscopy. Thereafter, a choledochoduodenal fistula was revealed. Finally, a flat polyp was detected in the lower part of the common bile duct and was removed by endoscopic mucosal resection (EMR) through the fistula. To our knowledge, this is the first reported case of the removal of a bile duct polyp using EMR.

CONCLUSION

EMR is a safe, effective, and low-cost method for the resection of all bile duct polyps.

Manuscript source: Unsolicited manuscript

Received: April 29, 2019

Peer-review started: May 9, 2019

Revised: July 12, 2019

Accepted: July 27, 2019

Article in press: July 27, 2019

Published online: September 26, 2019

P-Reviewer: Sugimoto M, Lee HC

S-Editor: Dou Y

L-Editor: Wang TQ

E-Editor: Zhou BX



Key words: Case report; Cholangiolithiasis; Bile duct polyp; Endoscopic mucosal resection

©The Author(s) 2019. Published by Baishideng Publishing Group Inc. All rights reserved.

Core tip: Bile duct polyps, including flat polyps, can be successfully resected by endoscopic mucosal resection (EMR). This method is safe, effective, and less invasive, with low pain, rapid rehabilitation, and low cost. Based on the literature search, this is the first reported case in the world on the resection of a bile duct polyp using EMR.

Citation: Yang S, Yang L, Wang XY, Yang YM. Endoscopic mucosal resection of a bile duct polyp: A case report. *World J Clin Casesol* 2019; 7(18): 2864-2870

URL: <https://www.wjgnet.com/2307-8960/full/v7/i18/2864.htm>

DOI: <https://dx.doi.org/10.12998/wjcc.v7.i18.2864>

INTRODUCTION

Bile duct polyps are difficult to diagnose by B-mode ultrasonography, computed tomography (CT), and magnetic resonance imaging (MRI); however, bile duct polyps can sometimes be detected during surgery of the biliary tract^[1-3]. However, the definitive diagnosis of bile duct polyps requires cholangioscopy or use of the SpyGlass system^[2,4-6]. Traditional open abdominal surgery and snare polypectomy by choledochoscopy *via* the T-tube sinus tract can be used to resect bile duct polyps^[2,7]. However, these two methods require the surgeon to open the abdomen and cut the bile duct to place the “T” tube; consequently, these techniques are associated with several limitations, including increased trauma, pain, and cost^[8]. Moreover, traditional snare polypectomy, without submucosal injection, can remove only pedunculated polyps of the bile duct, rather than flat polyps^[9-11]. Consequently, there is an urgent need to develop a new technique for the removal of bile duct polyps, including flat polyps.

CASE PRESENTATION

Chief complaints and history of illness

A 63-year-old woman was admitted into our hospital due to epigastric pain lasting one month. The pain radiated to the back and worsened after meals, but the patient did not present with fever, vomiting, or jaundice. In 1989, the patient was diagnosed with cholecystolithiasis following upper abdominal pain and underwent cholecystectomy. The patient was diagnosed with choledocholithiasis in 1991 and 2017, and underwent cholangiolithotomy twice.

Physical examination

Physical examination revealed multiple surgical scars and mild tenderness in the right upper abdomen, with no signs of rebound tenderness.

Laboratory examinations

Routine blood tests, liver function tests, blood amylase, and tumor markers were normal.

Imaging examination

A CT report from the other hospital that the patient previously visited described a communication between the bile duct and duodenal bulb, as well as a high-density shadow inside the communication. On MRI, axial T2 weighted image (Figure 1A) showed dilatation of the bile duct, as well as a fistula connecting the bile duct and duodenal bulb. Inside the fistula, there was a hypointense lesion. Axial T1 weighted image contrast enhanced (Figure 1B) showed no enhancement of the lesion.

Gastroscopic examination

Gastroscopy revealed the presence of a bile duct stone incarcerated in the anterior wall of the duodenal bulb (Figure 2A). After the stone was removed with an MWB-2 X4 Memory Basket (Wilson-Cook Medical Inc., Winston-Salem, North Carolina,

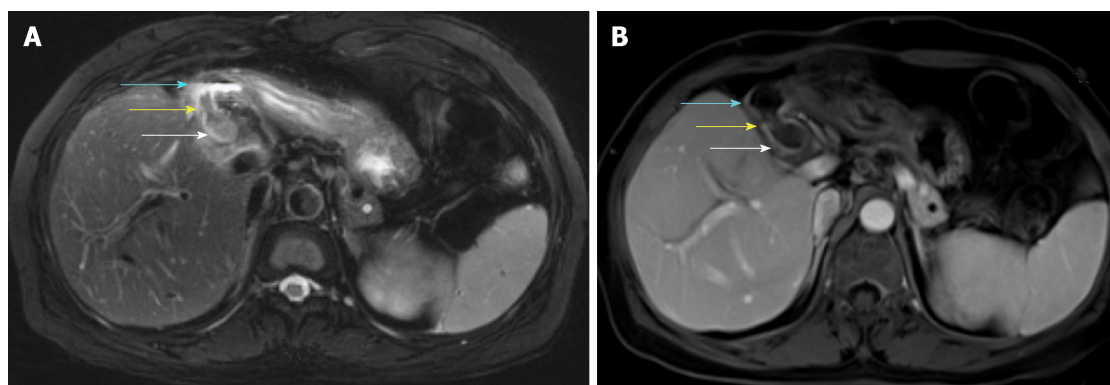


Figure 1 Magnetic resonance imaging. A: Axial T2 weighted image showing a fistula connecting the bile duct (white arrow) and the duodenal bulb (blue arrow) which had a gas-liquid plane inside. Inside the fistula, there was a hypointense lesion (yellow arrow); B: Axial T1 weighted image contrast enhanced showing no enhancement of the bile duct (white arrow), duodenal bulb (blue arrow), or lesion (yellow arrow).

United States), we observed a fistula with a proximal diameter of 1.2 cm (Figure 2B). The bile duct in the hilar area was observed when the gastroscope was inserted upwards through the fistula (Figure 3A), and the terminal part of the common bile duct was observed when the gastroscope was inserted downwards (Figure 3B). A 0.4-cm flat protruded lesion was seen in the lower portion of the common bile duct. The surface of the lesion appeared red under white light (Figure 4A) and brown under narrow band imaging (Figure 4B). The descending duodenum and duodenal papilla were normal. Pneumatosis and dilatation of the intrahepatic and extrahepatic bile ducts were noted in the intraoperative plain abdominal radiography. Contrast agent was injected via the gastroscope into the bile duct through the fistula, but the observation was severely interfered due to pneumatosis.

FINAL DIAGNOSIS

Finally, the patient was diagnosed with choledocholithiasis, a choledochoduodenal fistula (CDF), and a common bile duct polyp.

TREATMENT

The incarcerated stone in the duodenal bulb was removed using the Memory Basket under gastroscopy. Thereafter, the gastroscope was inserted into the lower part of the common bile duct through the fistula. An Olympus NM-2001-0425 endoscopic injection needle (Olympus Medical Systems Corp., Hachioji-shi, Tokyo, Japan) was used to inject 0.9% normal saline containing epinephrine at a concentration of 1/100000 into the submucosa next to the polyp. Elevation of the lesion (the positive lifting sign) was observed upon submucosal injection (Figure 5A, Video). The lesion was encircled and removed using the OLYMPUS SD-210U-25 Electrosurgical Snare (Olympus Medical Systems Corp., Hachioji-shi, Tokyo, Japan) (Figure 5B and Figure 5C, Video). Finally, the tissue sample was sent for pathological examination; subsequent pathological diagnosis confirmed that it was an inflammatory fibroid polyp (Figure 6).

OUTCOME AND FOLLOW-UP

The patient experienced moderate postoperative abdominal pain, which disappeared 48 h later. No complications, including bleeding, perforation, and pancreatitis, were observed during the hospitalization. The patient was followed for 12 wk without discomfort or complications.

DISCUSSION

Among many causes of CDF, the most common causes are cholelithiasis, duodenal ulcer, and tumors^[12,13]. In this case, the patient had a 28-year history of

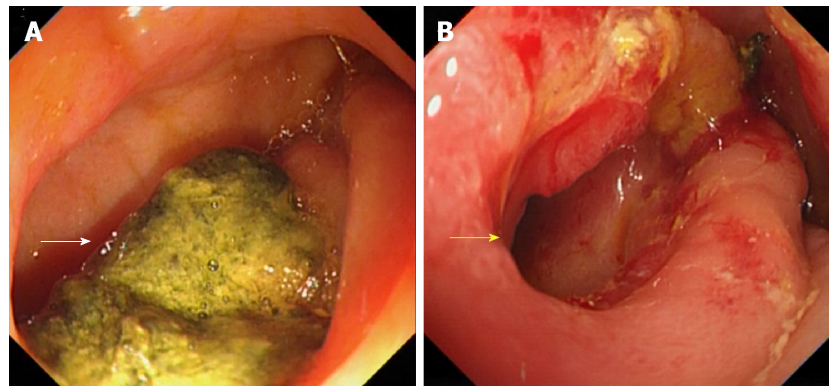


Figure 2 Gastroscopic images. A: An incarcerated stone (White arrow); B: A fistula (yellow arrow) was observed in the duodenal bulb after the stone was removed.

cholangiolithiasis, but showed no duodenal ulcer or gastrointestinal tumors. Therefore, the CDF in this patient was likely caused by the compression of stones on the bile duct wall and duodenal wall. This long-term compression could lead to necrosis and perforation of both bile duct wall and duodenal wall, resulting in CDF^[12,13]. Epigastric pain, fever, and jaundice are common symptoms of CDF, depending on its location, whereas vomiting and diarrhea are relatively rare symptoms^[12,13]. Pneumatosis of the bile duct on plain abdominal films and regurgitation of contrast on the upper gastrointestinal series can be observed in some patients^[13-15]. In addition, fistulas can be found by CT and MRI in some cases. The fistulous orifice can be observed directly by gastroscopy and the CDF can be further confirmed by cholangiography. Notably, CDF patients with no symptoms or mild symptoms do not require treatment, whereas surgery is needed for those who experience repeated pain, fever, and jaundice^[12,16].

Due to the low incidence rate and difficulty in diagnosis, bile duct polyps are rarely reported^[2,7,17-19]. The precise cause of bile duct polyps has yet to be elucidated, although it is generally believed that long-term stimulation by cholangiolithiasis and chronic cholangitis is associated with the formation of bile duct polyps^[20]. In this case, the patient had a 30-year history of cholelithiasis. Because most bile duct polyps exhibit neoplastic changes and can be cancerous, the early detection and resection of bile duct polyps can reduce the incidence of cholangiocarcinoma^[21,22].

Bile duct polyps are often asymptomatic^[2]. Bile duct polyps can lead to cholangiolithiasis, which can cause the bile duct to become obstructed; larger bile duct polyps can directly obstruct the bile duct^[7,22]. Bile duct obstruction presents with specific symptoms, such as abdominal pain, fever, and jaundice^[7]. However, B-mode ultrasound, CT, and MRI are limited in their ability to diagnose bile duct polyps, which are difficult to distinguish from cholangiocarcinomas^[4]. Yet, bile duct polyps are often found during biliary surgeries, *via* choledochoscopy or the SpyGlass system^[2-7].

The resection of bile duct polyps can be carried out by open abdominal surgery or snare polypectomy by choledochoscopy *via* the T-tube sinus tract^[2,7]. However, these two methods require the surgeon to open the abdomen, make a cut in the bile duct, and finally place the "T" tube to establish the bile duct sinus tract. This can cause severe trauma and significant pain, and is associated with slow recovery, significant costs, and many other complications^[8]. Moreover, simple snare polypectomy by choledochoscopy, without submucosal injection, can only resect pedunculated polyps, not flat polyps^[9-11]. Endoscopic mucosal resection (EMR) was initially used for the excision of flat polyps, benign tumors, and early malignant tumors in the stomach and intestine^[23]. However, resection of a proliferative lesion in the bile duct using EMR has not been attempted previously. In this case, we successfully resected the bile duct flat polyp through a CDF by gastroscopy with EMR. The patient recovered rapidly and had no postoperative complications. This indicated that this method is safe and effective, and has the advantages of limited trauma, reduced levels of pain, rapid recovery, and low cost. Moreover, to the best of our knowledge, this is the first ever reported case of a bile duct polyp being resected using EMR.

In future, with further miniaturization of the endoscopic needle and snare, we may also be able to use EMR in conjunction with the SpyGlass system to resect flat polyps in the bile duct, benign tumors of the bile duct, and early malignant tumors, thus opening up an exciting new avenue for the resection of proliferative lesions in the bile duct.

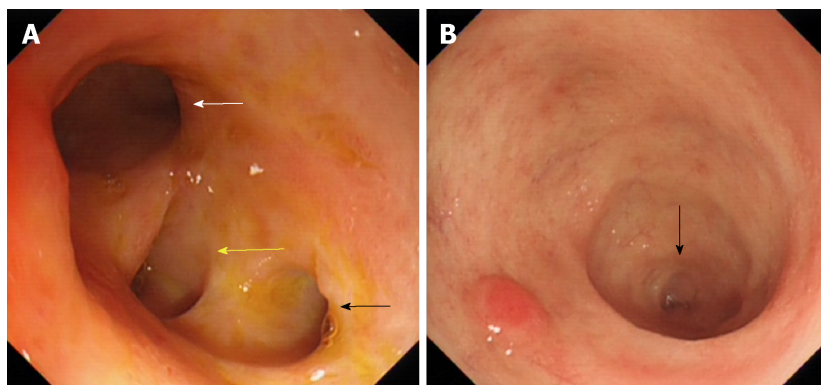


Figure 3 Gastroscopic images of the bile duct. A: The image of hilar bile duct showing the left hepatic duct (white arrow), right anterior hepatic duct (yellow Arrow), and right posterior hepatic duct (black arrow); B: The terminal part (black arrow) of the common bile duct.

CONCLUSION

We successfully resected a flat polyp of the bile duct through a CDF by EMR under gastroscopy without complications. This is the first ever reported case of a bile duct polyp being resected using EMR. Collectively, our experiences with our patient show that this treatment strategy is safe and effective for the resection of bile duct polyps and offers many advantages over existing techniques, such as reduced levels of trauma and pain, rapid recovery, and reduced costs.

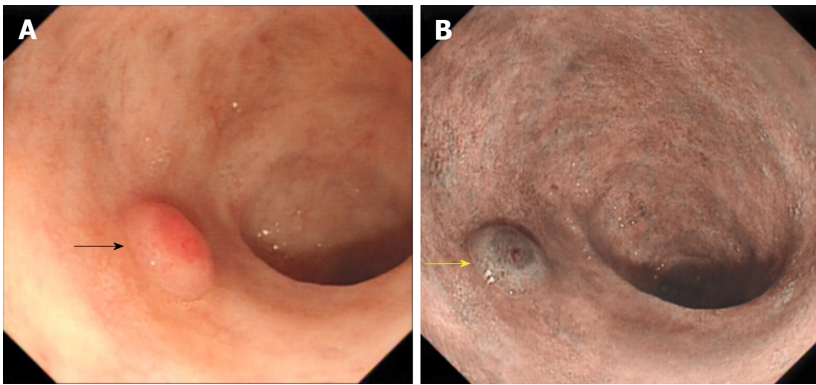


Figure 4 Gastroscopic images of the protruding lesion in the common bile duct. A: The lesion under white light (black arrow); B: The lesion under narrow band imaging (yellow arrow).

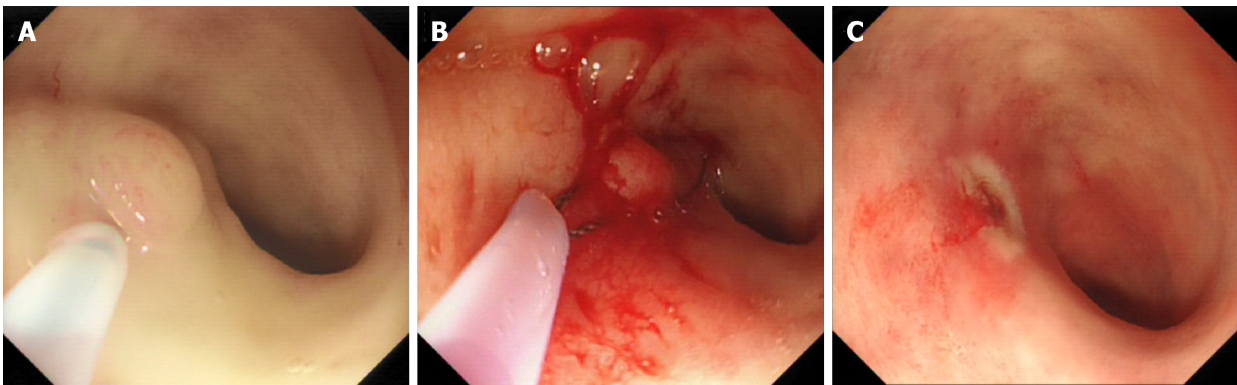


Figure 5 Endoscopic mucosal resection of the lesion in the common bile duct. A: The submucosal injection; B: The snare polypectomy of the polyp; C: Image collected after snare polypectomy.

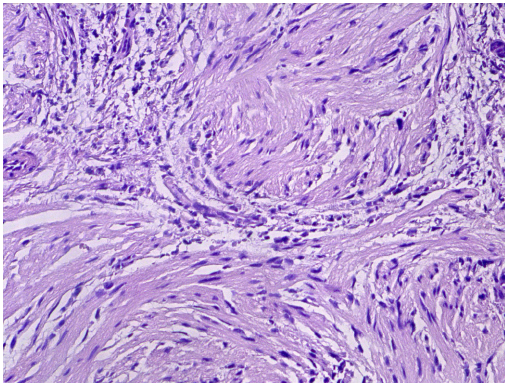


Figure 6 Histopathology. Histological section showing an inflammatory fibroid polyp (hematoxylin and eosin staining; magnification, 200×).

REFERENCES

- 1 **Dusunceli Atman E**, Erden A, Ustuner E, Uzun C, Bektas M. MRI Findings of Intrinsic and Extrinsic Duodenal Abnormalities and Variations. *Korean J Radiol* 2015; **16**: 1240-1252 [PMID: [26576112](#) DOI: [10.3348/kjr.2015.16.6.1240](#)]
- 2 **Tang R**, Zhao WP, Zhang YN, Tong X, Zeng JP. Cholesterol polyps in the distal common bile duct: a case report. *Medicine (Baltimore)* 2016; **95**: e5374 [PMID: [27828866](#) DOI: [10.1097/MD.0000000000005374](#)]
- 3 **Hamada Y**, Maeshiro K, Nakayama Y, Nitta T. Extrahepatic bile duct polyp mimicking biliary parasitic disease. *Endoscopy* 2012; **44** Suppl 2 UCTN: E315-E316 [PMID: [23011998](#) DOI: [10.1055/s-0032-1309760](#)]
- 4 **Derdeyn J**, Laleman W. Current role of endoscopic cholangioscopy. *Curr Opin Gastroenterol* 2018; **34**: 301-308 [PMID: [29901513](#) DOI: [10.1097/MOG.0000000000000457](#)]
- 5 **Voiosu T**, Ionita M, Voiosu A, Bengus A, Popp C, Mateescu B. Cholangioscopy using the SpyGlass

- system for a rare cause of obstruction: inflammatory polyp of the common bile duct. *J Gastrointest Liver Dis* 2017; **26**: 111 [PMID: [28617875](#) DOI: [10.15403/jgld.2014.1121.262.pyg](#)]
- 6 **D'Souza LS**, Korman A, Benias PC, Carr-Locke DL. A novel technique for biliary polypectomy. *Endoscopy* 2017; **49**: E244-E245 [PMID: [28759924](#) DOI: [10.1055/s-0043-114408](#)]
- 7 **Ezaki T**, Okamura T, Yoshida Y, Kitamura M, Furuta A, Haratake J, Shirakusa T. A small polypoid lesion in the lower common bile duct: a case study. *Endoscopy* 1994; **26**: 271 [PMID: [8026385](#) DOI: [10.1055/s-2007-1008964](#)]
- 8 **Parra-Membrives P**, Martínez-Baena D, Márquez-Muñoz M, Pino-Díaz V. Does laparoscopic approach impair T-tube-related sinus-tract formation? *Surg Laparosc Endosc Percutan Tech* 2013; **23**: 55-60 [PMID: [23386153](#) DOI: [10.1097/SLE.0b013e3182747b19](#)]
- 9 **Schwartz MP**. Clip-assisted EMR: a new resection technique for treating flat remnants of colonic polyp tissue during piecemeal EMR. *VideoGIE* 2018; **3**: 403-405 [PMID: [30506010](#) DOI: [10.1016/j.vgie.2018.08.008](#)]
- 10 **Sold M**, Kähler G. Improved Techniques for Endoscopic Mucosal Resection (EMR) in Colorectal Adenoma. *Viszeralmedizin* 2014; **30**: 33-38 [PMID: [26286120](#) DOI: [10.1159/000358243](#)]
- 11 **Wallace MB**. Endoscopic Removal of Polyps in the Gastrointestinal Tract. *Gastroenterol Hepatol (N Y)* 2017; **13**: 371-374 [PMID: [28690454](#)]
- 12 **Mallikarjunappa B**, Ashish SR. Choledochoduodenal fistula: A rare case report with review of literature. *JIMSA* 2013; **26**: 226
- 13 **Akaydin M**, Demiray O, Ferlenguez E, Erozyen F, Ersoy YE, Er M. Importance of Spontaneous Choledochoduodenal Fistulas Detected During ERCP Procedure. *Indian J Surg* 2018; **80**: 216-220 [PMID: [29973750](#) DOI: [10.1007/s12262-016-1569-8](#)]
- 14 **Dadzan E**, Akhondi H. Choledochoduodenal fistula presenting with pneumobilia in a patient with gallbladder cancer: a case report. *J Med Case Rep* 2012; **6**: 61 [PMID: [22333461](#) DOI: [10.1186/1752-1947-6-61](#)]
- 15 **Watanabe Y**, Toki A, Todani T. Bile duct cancer developed after cyst excision for choledochal cyst. *J Hepatobiliary Pancreat Surg* 1999; **6**: 207-212 [PMID: [10526053](#) DOI: [10.1007/s005340050108](#)]
- 16 **Karıncaoglu M**, Yildirim B, Kantarceken B, Aladag M, Hilmioglu F. Association of peripapillary fistula with common bile duct stones and cholangitis. *ANZ J Surg* 2003; **73**: 884-886 [PMID: [14616559](#) DOI: [10.1046/j.1445-2197.2003.02820.x](#)]
- 17 **Solakoglu T**, Akin E, Yavuz SH, Ersoy O. Endoscopic treatment of a solitary hamartomatous polyp in the intrahepatic biliary duct. *Endoscopy* 2013; **45** Suppl 2 UCTN: E356-E357 [PMID: [24285045](#) DOI: [10.1055/s-0033-1344417](#)]
- 18 **Levy AD**, Murakata LA, Abbott RM, Rohrmann CA. From the archives of the AFIP. Benign tumors and tumorlike lesions of the gallbladder and extrahepatic bile ducts: radiologic-pathologic correlation. Armed Forces Institute of Pathology. *Radiographics* 2002; **22**: 387-413 [PMID: [11896229](#) DOI: [10.1148/radiographics.22.2.g02mr08387](#)]
- 19 **Yang HL**, Sun YG, Wang Z. Polypoid lesions of the gallbladder: diagnosis and indications for surgery. *Br J Surg* 1992; **79**: 227-229 [PMID: [1555088](#) DOI: [10.1002/bjs.1800790312](#)]
- 20 **Zimmermann A**. Reactive bile duct alterations mimicking biliary cancer: inflammatory conditions. *Tumors and tumor-like lesions of the hepatobiliary tract*. Cham: Springer 2017; 1-17 [DOI: [10.1007/978-3-319-26956-6_142](#)]
- 21 **Kin Y**, Nimura Y, Kamiya J, Kondo S, Nagino M. Cholesterosis in bile duct carcinoma. *Gastrointest Endosc* 1994; **40**: 92-93 [PMID: [8163149](#) DOI: [10.1016/S0016-5107\(94\)70022-2](#)]
- 22 **Lee CC**, Wu CY, Chen GH. What is the impact of coexistence of hepatolithiasis on cholangiocarcinoma? *J Gastroenterol Hepatol* 2002; **17**: 1015-1020 [PMID: [12167124](#) DOI: [10.1046/j.1440-1746.2002.02779.x](#)]
- 23 **Larghi A**, Waxman I. Endoscopic mucosal resection: treatment of neoplasia. *Gastrointest Endosc Clin N Am* 2005; **15**: 431-454, viii [PMID: [15990050](#) DOI: [10.1016/j.giec.2005.04.003](#)]



Published By Baishideng Publishing Group Inc
7041 Koll Center Parkway, Suite 160, Pleasanton, CA 94566, USA
Telephone: +1-925-2238242
E-mail: bpgoffice@wjgnet.com
Help Desk: <https://www.f6publishing.com/helpdesk>
<https://www.wjgnet.com>

