

World Journal of *Cardiology*

World J Cardiol 2020 January 26; 12(1): 1-75





EDITORIAL

- 1 Is there a role for ischemia detection after an acute myocardial infarction?
Peteiro J, Bouzas-Mosquera A

REVIEW

- 7 Diagnosis and treatment of heart failure with preserved left ventricular ejection fraction
Henning RJ
- 26 Radial artery access site complications during cardiac procedures, clinical implications and potential solutions: The role of nitric oxide
Coghill EM, Johnson T, Morris RE, Megson IL, Leslie SJ

ORIGINAL ARTICLE

Observational Study

- 35 Impact of training specificity on exercise-induced cardiac troponin elevation in professional athletes: A pilot study
Wedin JO, Nyberg NS, Henriksson AE
- 44 Prognostic impact of body mass index on in-hospital bleeding complications after ST-segment elevation myocardial infarction
Ingremau D, Grall S, Valliet F, Desprets L, Prunier F, Furber A, Bière L

CASE REPORT

- 55 Phrenic nerve displacement by intrapericardial balloon inflation during epicardial ablation of ventricular tachycardia: Four case reports
Conti S, Bonomo V, Taormina A, Giordano U, Sgarito G
- 67 *Salmonella typhimurium* myopericarditis: A case report and review of literature
Jin D, Kao CY, Darby J, Palmer S

ABOUT COVER

Editorial Board of *World Journal of Cardiology*, Barakat Adeola Animasahun, FACC, MBBS, Chief Doctor, Occupational Physician, Reader (Associate Professor), Department of Paediatrics and Child Health, Lagos State University College of Medicine, Lagos +23401, Nigeria

AIMS AND SCOPE

The primary aim of *World Journal of Cardiology* (WJC, *World J Cardiol*) is to provide scholars and readers from various fields of cardiology with a platform to publish high-quality basic and clinical research articles and communicate their research findings online.

WJC mainly publishes articles reporting research results and findings obtained in the field of cardiology and covering a wide range of topics including acute coronary syndromes, aneurysm, angina, arrhythmias, atherosclerosis, atrial fibrillation, cardiomyopathy, congenital heart disease, coronary artery disease, heart failure, hypertension, imaging, infection, myocardial infarction, pathology, peripheral vessels, public health, Raynaud's syndrome, stroke, thrombosis, and valvular disease.

INDEXING/ABSTRACTING

The WJC is now abstracted and indexed in Emerging Sources Citation Index (Web of Science), PubMed, PubMed Central, Scopus, China National Knowledge Infrastructure (CNKI), China Science and Technology Journal Database (CSTJ), and Superstar Journals Database.

RESPONSIBLE EDITORS FOR THIS ISSUE

Responsible Electronic Editor: *Yan-Liang Zhang*

Proofing Production Department Director: *Xiang Li*

NAME OF JOURNAL

World Journal of Cardiology

ISSN

ISSN 1949-8462 (online)

LAUNCH DATE

December 31, 2009

FREQUENCY

Monthly

EDITORS-IN-CHIEF

Ramdas G. Pai MD, FACC, FRCP (Edin), Marco Matteo Ciccone, Dimitris Tousoulis

EDITORIAL BOARD MEMBERS

<https://www.wjgnet.com/1949-8462/editorialboard.htm>

EDITORIAL OFFICE

Ruo-Yu Ma, Director

PUBLICATION DATE

January 26, 2020

COPYRIGHT

© 2020 Baishideng Publishing Group Inc

INSTRUCTIONS TO AUTHORS

<https://www.wjgnet.com/bpg/gerinfo/204>

GUIDELINES FOR ETHICS DOCUMENTS

<https://www.wjgnet.com/bpg/GerInfo/287>

GUIDELINES FOR NON-NATIVE SPEAKERS OF ENGLISH

<https://www.wjgnet.com/bpg/gerinfo/240>

PUBLICATION MISCONDUCT

<https://www.wjgnet.com/bpg/gerinfo/208>

ARTICLE PROCESSING CHARGE

<https://www.wjgnet.com/bpg/gerinfo/242>

STEPS FOR SUBMITTING MANUSCRIPTS

<https://www.wjgnet.com/bpg/GerInfo/239>

ONLINE SUBMISSION

<https://www.f6publishing.com>



Is there a role for ischemia detection after an acute myocardial infarction?

Jesus Peteiro, Alberto Bouzas-Mosquera

ORCID number: Jesus Peteiro (0000-0002-8457-6351); Alberto Bouzas-Mosquera (0000-0002-2741-732X).

Author contributions: Peteiro J designed and wrote the paper; Bouzas-Mosquera A revised it critically and contributed to the design and discussion.

Conflict-of-interest statement:

There is no conflict of interest to declare.

Open-Access: This is an open-access article that was selected by an in-house editor and fully peer-reviewed by external reviewers. It is distributed in accordance with the Creative Commons Attribution Non Commercial (CC BY-NC 4.0) license, which permits others to distribute, remix, adapt, build upon this work non-commercially, and license their derivative works on different terms, provided the original work is properly cited and the use is non-commercial. See: <http://creativecommons.org/licenses/by-nc/4.0/>

Manuscript source: Unsolicited manuscript

Received: May 7, 2019

Peer-review started: May 10, 2019

First decision: August 16, 2019

Revised: August 27, 2019

Accepted: October 14, 2019

Article in press: October 15, 2019

Published online: January 26, 2020

P-Reviewer: Micheu MM, Sato A, Sicari R, Ueda H

S-Editor: Tang JZ

L-Editor: Filipodia

Jesus Peteiro, Alberto Bouzas-Mosquera, Unit of Echocardiography and Department of Cardiology, Complejo Hospitalario Universitario de A Coruña (CHUAC), CIVER-CV, University of A Coruña, A Coruña 15004, Spain

Corresponding author: Jesus Peteiro, DPhil, Doctor, Unit of Echocardiography and Department of Cardiology, Complejo Hospitalario Universitario de A Coruña (CHUAC), CIVER-CV, University of A Coruña, Xubias de Arriba 84, A Coruña 15008, Spain. pete@canalejo.org

Abstract

Coronary angiography and eventual revascularization have become the most common approaches for patients with acute coronary syndromes. Ischemia detection in this scenario is usually regarded as unnecessary for most of the patients. In fact, current guidelines recommend complete revascularization for patients with multivessel disease in the context of ST-elevation myocardial infarction, although it is in contrast with previous recommendations. However, some recent data suggested that ischemia could have a role for the decision of revascularization in these patients. The CROSS-AMI study randomized patients with ST-elevation myocardial infarction treated with primary angioplasty and who also had multivessel disease to a complete anatomic revascularization of the non-infarct related artery lesions *vs* subsequent revascularization of the non-infarct related artery lesions only if ischemia was demonstrated by stress echocardiography. The main findings were that only 30% of the patients in the ischemia arm needed a second revascularization and that the outcome was similar in both arms. Regarding non-ST-elevation acute coronary syndrome, coronary angiography is in general warranted for most of the patients. However, recent long-term published studies on patients randomized to an invasive or less aggressive approach based on ischemia detection have found no differences in outcome. The ultimate study in non-ST-elevation acute coronary syndrome comparing ischemia detection with an invasive approach is pending. Therefore, ischemia detection might have a role for stratifying these subjects. This is particularly true in the current era of imaging of high quality and sensitivity, last generation stents, radial access and modern antithrombotic therapy.

Key words: Ischemia; Acute myocardial infarction; Stress echocardiography; Coronary angiography; Stents

©The Author(s) 2020. Published by Baishideng Publishing Group Inc. All rights reserved.

Core tip: Coronary angiography and eventual revascularization have become the most

E-Editor: Zhang YL



common approaches for patients with acute coronary syndromes. Ischemia detection in this scenario is usually regarded as unnecessary for most of the patients. However, some recent data suggested that it could have a role in the decision-making process, particularly after ST-elevation acute myocardial infarction in the presence of multivessel disease but also after non-ST-elevation acute coronary syndrome.

Citation: Peteiro J, Bouzas-Mosquera A. Is there a role for ischemia detection after an acute myocardial infarction? *World J Cardiol* 2020; 12(1): 1-6

URL: <https://www.wjgnet.com/1949-8462/full/v12/i1/1.htm>

DOI: <https://dx.doi.org/10.4330/wjc.v12.i1.1>

INTRODUCTION

Coronary angiography and eventual revascularization have become the most common approaches for patients with acute coronary syndromes. Although ischemia detection is usually regarded as unnecessary for most of these patients, some recent data suggested that it could have a role in the decision-making process.

ST-elevation myocardial infarction (STEMI) with multivessel disease

The best treatment for STEMI is to rapidly open the infarct-related artery (IRA), which is better achieved by angioplasty^[1]. However, having done this, patients may still have significant coronary stenoses in up to 40% to 60% of the cases. These patients likely have higher atherosclerotic burden with increased risk, and it is not clear how to prevent their risk. Also, these patients may have worse left ventricular function.

In the last years several studies have dealt with the issue of multivessel disease (MVD) after STEMI treated with primary angioplasty, and these studies have been changing the guidelines ever since. Thus, guidelines in 2013 recommended exclusive treatment of the IRA^[2] reserving treatment of MVD just in cases of cardiogenic shock or persistent ischemia (indication IIa-class B), whereas the last guidelines recommend routine revascularization of MVD before hospital discharge (indication IIa-class A)^[3].

The PRAMI^[4] and CvLPRIT^[5] studies randomized patients with STEMI and MVD disease to an IRA-only strategy *vs* complete revascularization and reported better outcome with the complete revascularization strategy.

Further studies like the PRIMULTI^[6] and the ACUTE-COMPARE^[7] randomized STEMI and MVD disease patients to an IRA-only revascularization strategy *vs* a complete revascularization strategy based on ischemia, as detected by flow reserve-guided (FFR) < 0.80. Both studies demonstrated that the functional strategy was better than the mere revascularization of the IRA.

Recently, the CROSS-AMI study, using a completely different design, randomized patients with STEMI treated with primary angioplasty and who also had MVD to a complete anatomic revascularization of the non-infarct related artery (non-IRA) lesions *vs* subsequent revascularization of the non-IRA lesions only if ischemia was demonstrated by stress echocardiography^[8,9]. The main findings of this study were that only 30% of the patients in the ischemia arm needed a second revascularization and that the outcome was similar in both arms. In fact, there were 22 events in the complete revascularization arm and 21 in the ischemia-guided arm [14.3% *vs* 13.8%; hazard ratio (HR) = 1.06, 95% confidence interval (CI): 0.58-1.92, *P* = not significant]. **Figure 1** shows the Kaplan-Meier event-free survival curves for both arms and Video 1 to 3 are examples of two patients randomized to the stress-guided strategy. Of note, most of the stress echocardiography studies were performed using peak treadmill exercise, a very sensitive modality^[10,11]. This study therefore showed that ischemia detection has indeed a role for avoiding procedures and saving costs in this scenario.

These results are not completely surprising because revascularization based on ischemia has led to better prognosis than revascularization based on anatomy as reported in the FAME study, where ischemia was investigated by FFR^[12]. The investigators found that measurement of FFR in patients with multivessel coronary artery disease who were undergoing percutaneous coronary intervention with drug-eluting stents significantly reduced the rate of the composite end point of death, nonfatal myocardial infarction, and repeat revascularization. Also, Escaned *et al*^[13] recently reported similar results, such that the use of functional assessment based on FFR/iFR led to a 25% reduction in the use of stents.

Additional studies on this subject are ongoing. For instance, the FULL-REVASC

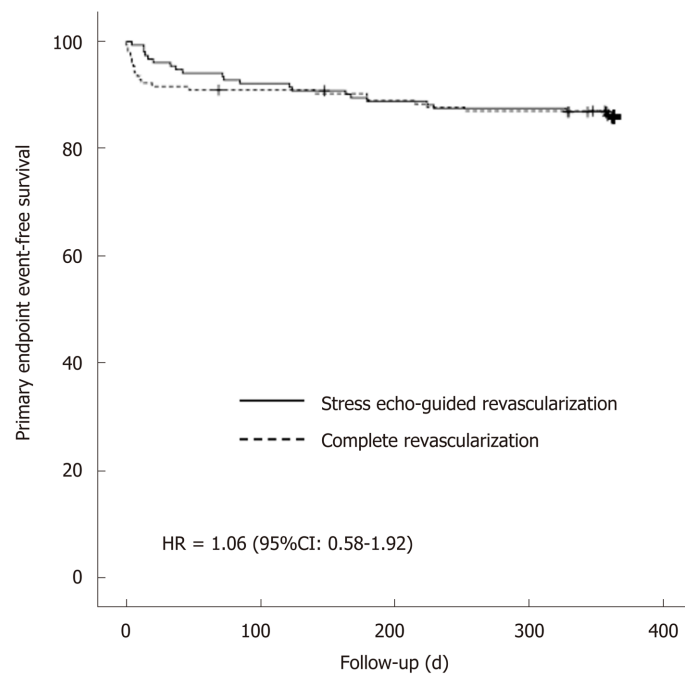


Figure 1 Kaplan-Meier event-free survival curves for patients with ST-elevation myocardial infarction treated with primary angioplasty and multivessel disease according to management with complete revascularization vs stress echo-guided revascularization (CROSS-AMI study). This figure is adapted from Calviño-Santos *et al*.^[8]. HR: Hazard ratio; CI: Confidence interval.

study will randomize patients with STEMI and MVD to an initial conservative management of non-IRA lesions *vs* FFR-guided revascularization of non-culprit lesions during hospitalization (<https://www.ucr.uu.se/fullrevasc/>).

However, as it is clear from above, the optimum study would be one with three arms comparing conservative management of non-IRA stenoses, complete anatomic revascularization and ischemia/FFR-guided revascularization. Meanwhile, it is worth stating that the current approach in our center for patients with STEMI and multivessel coronary artery disease is based on ischemia.

NON-ST-ELEVATION ACUTE CORONARY SYNDROME

In patients with non-ST-elevation acute coronary syndrome who do not have recurrence of chest pain, signs of heart failure or abnormalities in the initial or subsequent electrocardiography and increase in (preferably high-sensitivity) cardiac troponin level, a non-invasive stress test (preferably with imaging) for inducible ischemia is recommended before deciding on an invasive strategy. This recommendation has been clearly stated in the last guidelines on the issue^[14].

Therefore, when there is troponin elevation, a coronary angiography is currently warranted. However, in the last decades there has been a lot of discussion on this matter, and several studies have focused on the comparison between an invasive and functional strategy for patients with non-STEMI or unstable angina. A Cochrane review^[15] joining all studies published between 2001 and 2012 and including almost 9000 patients found that there was no significant differences in mortality [risk ratio (RR) = 0.87; CI: 0.64-1.18] or in the composite of mortality and non-fatal myocardial infarction (RR = 0.93; CI: 0.71-1.2). Less hard end-points like myocardial infarction (RR = 0.79; CI: 0.63-1), refractory angina (RR = 0.64; CI: 0.52-0.79) and rehospitalization (RR = 0.77; CI: 0.63-0.94) were lower with the invasive strategy. In contrast, complications of angiography or revascularization like bleeding or procedure-related myocardial infarction were higher in the invasive arms (RR = 1.73, CI: 1.2-2.31; and RR = 1.87, CI: 1.47-2.37). Therefore, the conclusion of this meta-analysis was that in patients with non-ST-elevation acute coronary syndrome, a conservative strategy based on clinical risk for recurrent events is the preferred management strategy. However, it is worth stating that the use of stents was lower (50% to 88% of the patients), and the use of coronary artery by-pass was higher (up to 10% to 41% of revascularizations). Also, antiplatelet therapy was less developed. On the other hand, functional testing consisted of just exercise electrocardiography for most of the

patients.

In this regard, the only old study that clearly observed a superiority of a functional approach in patients with non-STEMI was the VANQUISH trial^[16]. Unlike other conceptually similar studies, the conservative strategy of the VANQUISH was in fact a “conservative aggressive strategy” as almost half of the patients in this arm underwent coronary angiography. Another key point was that almost all patients in the conservative arm were studied by treadmill exercise with myocardial perfusion imaging, which is a very sensitive technique, or by dipyridamole myocardial perfusion imaging in case of the inability to exercise. Although the VANQUISH trial was a pre-stent study, these aspects may explain the superiority of the conservative strategy over the invasive strategy regarding both the primary end-point ($P = 0.007$) and all-cause death ($P = 0.004$).

Some of these studies comparing invasive and conservative approaches have long term follow-up. Fox *et al.*^[17] published the joint results of the fast revascularization during instability in coronary artery disease (FRISC-II), randomized intervention trial of unstable angina 3 (RITA-3) and invasive *vs* conservative treatment in unstable coronary syndromes (ICTUS) at 5 years, demonstrating superiority of an invasive strategy for the combination of cardiovascular death and myocardial infarction (HR = 0.8, CI: 0.71-0.93, $P = 0.002$), which was driven for myocardial infarction occurrence (HR = 0.77; CI: 0.65-0.90, $P = 0.001$); the difference in cardiovascular mortality did not reach statistical significance (HR = 0.83, CI: 0.68-1.01, $P = 0.068$). However, these differences were at expense of the results of the FRISC-II and RITA-3 studies, as in the ICTUS study there were no significant differences between arms.

We were curious what the differences between the ICTUS study and the other studies were. Crucial differences were that the percentage of angiographies in the conservative arm of ICTUS reached up to 53% of the patients, and all patients in the conservative arm were studied by a sensitive imaging technique (both characteristics similar to the older VANQUISH study). Table 1 depicts these differences between studies. In fact, the ICTUS trial at 10 years demonstrated an excess of the combined event (death or myocardial infarction) in the invasive arm as compared to the conservative arm (HR = 1.30, CI: 1.07-1.58, $P = 0.009$)^[18]. In addition, both the RITA-3 at 10 years and the FRISC-II at 15 years, which were studies that had shown better performance of an invasive strategy in the first years, found no significant differences in mortality between arms at longer-term follow-up^[19,20]. Therefore, given these results, it is not surprising that some experts have advocated for a fair study comparing the two strategies in a current era of imaging of high quality and sensitivity, last generation stents, radial access and modern antithrombotic therapy^[21].

The use of exercise electrocardiography testing in most of the conservative arms of the above-mentioned studies (if performed) should be considered as an important limitation. The superiority of modern techniques of imaging like stress echocardiography^[10,11], magnetic resonance or myocardial perfusion imaging would likely make a difference for stratification of these patients.

CONCLUSION

In patients with acute myocardial infarction and MVD, ischemia detection may be useful for clinical decisions. In non-ST elevation myocardial infarction or acute coronary syndrome, the ultimate role of ischemia detection for clinical decision making process in the current era of modern imaging and new drugs and stents is pending.

Table 1 Main differences between the invasive vs conservative treatment in unstable coronary syndromes, randomized intervention trial of unstable angina 3 and fast revascularization during instability in coronary artery disease studies

	FRISC-II	RITA-3	ICTUS
Year	1999	2002	2005
Inclusion criteria: Raised troponin	No	No	Yes
Functional imaging in the conservative arm	-	No (exercise ECG testing)	Yes (exercise with MIBI-SPECT)
Interventionism in the conservative arm	7%	16%	53%
Stents, invasive arm	61%	88%	88%

ICTUS: Invasive vs conservative treatment in unstable coronary syndromes; RITA-3: Randomized intervention trial of unstable angina 3; FRISC-II: Fast revascularization during instability in coronary artery disease; ECG: Electrocardiography.

REFERENCES

- 1 Neumann FJ, Sousa-Uva M, Ahlsson A, Alfonso F, Banning AP, Benedetto U, Byrne RA, Collet JP, Falk V, Head SJ, Juni P, Kastrati A, Koller A, Kristensen SD, Niebauer J, Richter DJ, Seferovic PM, Sibbing D, Stefanini GG, Windecker S, Yadav R, Zembala MO; ESC Scientific Document Group. 2018 ESC/EACTS Guidelines on myocardial revascularization. *Eur Heart J* 2019; **40**: 87-165 [PMID: [30165437](#) DOI: [10.1093/eurheartj/ehy394](#)]
- 2 Task Force on the management of ST-segment elevation acute myocardial infarction of the European Society of Cardiology (ESC); Steg PG, James SK, Atar D, Badano LP, Blömlund-Lundqvist C, Borger MA, Di Mario C, Dickstein K, Ducrocq G, Fernandez-Aviles F, Gershlick AH, Giannuzzi P, Halvorsen S, Huber K, Juni P, Kastrati A, Knuuti J, Lenzen MJ, Mahaffey KW, Valgimigli M, van't Hof A, Widimsky P, Zahger D. ESC Guidelines for the management of acute myocardial infarction in patients presenting with ST-segment elevation. *Eur Heart J* 2012; **33**: 2569-2619 [PMID: [22922416](#) DOI: [10.1093/eurheartj/ehs215](#)]
- 3 Ibanez B, James S, Agewall S, Antunes MJ, Bucciarelli-Ducci C, Bueno H, Caforio ALP, Crea F, Goudevinos JA, Halvorsen S, Hindricks G, Kastrati A, Lenzen MJ, Prescott E, Roffi M, Valgimigli M, Varenhorst C, Vranckx P, Widimský P; ESC Scientific Document Group. 2017 ESC Guidelines for the management of acute myocardial infarction in patients presenting with ST-segment elevation: The Task Force for the management of acute myocardial infarction in patients presenting with ST-segment elevation of the European Society of Cardiology (ESC). *Eur Heart J* 2018; **39**: 119-177 [PMID: [28886621](#) DOI: [10.1093/eurheartj/ehx393](#)]
- 4 Wald DS, Morris JK, Wald NJ, Chase AJ, Edwards RJ, Hughes LO, Berry C, Oldroyd KG; PRAMI Investigators. Randomized trial of preventive angioplasty in myocardial infarction. *N Engl J Med* 2013; **369**: 1115-1123 [PMID: [23991625](#) DOI: [10.1056/NEJMoa1305520](#)]
- 5 Gershlick AH, Khan JN, Kelly DJ, Greenwood JP, Sasikaran T, Curzen N, Blackman DJ, Dalby M, Fairbrother KL, Banya W, Wang D, Flather M, Hetherington SL, Kelion AD, Talwar S, Gunning M, Hall R, Swanton H, McCann GP. Randomized trial of complete vs lesion-only revascularization in patients undergoing primary percutaneous coronary intervention for STEMI and multivessel disease: the CvLPRIT trial. *J Am Coll Cardiol* 2015; **65**: 963-972 [PMID: [25766941](#) DOI: [10.1016/j.jacc.2014.12.038](#)]
- 6 Engström T, Kelbæk H, Helqvist S, Höfsten DE, Kløvgaard L, Holmvang L, Jørgensen E, Pedersen F, Saunamäki K, Clemmensen P, De Backer O, Ravkilde J, Tilsted HH, Villadsen AB, Aarøe J, Jensen SE, Raungaard B, Køber L; DANAMI-3—PRIMULTI Investigators. Complete revascularisation vs treatment of the culprit lesion only in patients with ST-segment elevation myocardial infarction and multivessel disease (DANAMI-3—PRIMULTI): an open-label, randomised controlled trial. *Lancet* 2015; **386**: 665-671 [PMID: [26347918](#) DOI: [10.1016/s0140-6736\(15\)60648-1](#)]
- 7 Smits PC, Abdel-Wahab M, Neumann FJ, Boxma-de Klerk BM, Lunde K, Schotborgh CE, Piroth Z, Horak D, Włodarczak A, Ong PJ, Hambrecht R, Angerås O, Richardt G, Omerovic E; Compare-Acute Investigators. Fractional Flow Reserve-Guided Multivessel Angioplasty in Myocardial Infarction. *N Engl J Med* 2017; **376**: 1234-1244 [PMID: [28317428](#) DOI: [10.1056/NEJMoa1701067](#)]
- 8 Calviño-Santos R, Estevez-Loureiro R, Bouzas-Mosquera A, Peteiro J, Salgado-Fernández J, Rodríguez-Vilela A, Franco-Gutiérrez R, Rodríguez-Fernández JA, Mesías-Prego A, González-Juanatey C, Aldama-López G, Piñón-Esteban P, Flores-Ríos X, Soler-Martín R, Seoane-Pillado T, Vázquez-González N, Muñoz J, Vázquez-Rodríguez JM. Complete revascularisation vs stress echocardiography-guided revascularisation in patients with ST-segment elevation myocardial infarction and multivessel disease (CROSS-AMI): a clinical trial. *Eur Heart J* 2017; **38**: 436 [DOI: [10.1093/eurheartj/ehx502.p2121](#)]
- 9 Calviño-Santos R, Estevez-Loureiro R, Peteiro J, Salgado-Fernández J, Rodríguez-Vilela A, Franco-Gutiérrez R, Bouzas-Mosquera A, Rodríguez-Fernández JA, Mesías-Prego A, González-Juanatey C, Aldama-López G, Piñón-Esteban P, Flores-Ríos X, Soler-Martín R, Seoane-Pillado T, Vázquez-González N, Muñoz J, Vázquez-Rodríguez JM. Angiographically-guided Complete revascularization vs selective stress echocardiography-guided revascularization in patients with ST-segment elevation myocardial infarction and multivessel disease: The CROSS-AMI Randomized Clinical Trial. *Circ Cardiovasc Interv* 2019; **12**: e007924 [PMID: [31554422](#) DOI: [10.1161/CIRCINTERVENTIONS.119.007924](#)]
- 10 Bouzas-Mosquera A, Peteiro J, Alvarez-García N, Broullón FJ, Mosquera VX, García-Bueno L, Ferro L, Castro-Beiras A. Prediction of mortality and major cardiac events by exercise echocardiography in patients with normal exercise electrocardiographic testing. *J Am Coll Cardiol* 2009; **53**: 1981-1990 [PMID: [19460612](#) DOI: [10.1016/j.jacc.2009.01.067](#)]
- 11 Peteiro J, Bouzas-Mosquera A, Broullón FJ, García-Campos A, Pazos P, Castro-Beiras A. Prognostic value of peak and post-exercise treadmill exercise echocardiography in patients with known or suspected coronary artery disease. *Eur Heart J* 2010; **31**: 187-195 [PMID: [19825812](#) DOI: [10.1093/eurheartj/ehp427](#)]

- 12 **Tonino PA**, De Bruyne B, Pijls NH, Siebert U, Ikeno F, van't Veer M, Klauss V, Manoharan G, Engström T, Oldroyd KG, Ver Lee PN, McCarthy PA, Fearon WF; FAME Study Investigators. Fractional flow reserve vs angiography for guiding percutaneous coronary intervention. *N Engl J Med* 2009; **360**: 213-224 [PMID: [19144937](#) DOI: [10.1056/NEJMoa0807611](#)]
- 13 **Escaned J**, Collet C, Ryan N, De Maria GL, Walsh S, Sabate M, Davies J, Lesiak M, Moreno R, Cruz-Gonzalez I, Hoole SP, Ej West N, Piek JJ, Zaman A, Fath-Ordoubadi F, Stables RH, Appleby C, van Mieghem N, van Geuns RJ, Uren N, Zueco J, Buszman P, Iñiguez A, Goicolea J, Hildick-Smith D, Ochala A, Dudek D, Hanratty C, Cavalcante R, Kappetein AP, Taggart DP, van Es GA, Morel MA, de Vries T, Onuma Y, Farooq V, Serruys PW, Banning AP. Clinical outcomes of state-of-the-art percutaneous coronary revascularization in patients with de novo three vessel disease: 1-year results of the SYNTAX II study. *Eur Heart J* 2017; **38**: 3124-3134 [PMID: [29020367](#) DOI: [10.1093/eurheartj/ehx512](#)]
- 14 **Roffi M**, Patrono C, Collet JP, Mueller C, Valgimigli M, Andreotti F, Bax JJ, Borger MA, Brotons C, Chew DP, Gencer B, Hasenfuss G, Kjeldsen S, Lancellotti P, Landmesser U, Mehilli J, Mukherjee D, Storey RF, Windecker S; ESC Scientific Document Group. 2015 ESC Guidelines for the management of acute coronary syndromes in patients presenting without persistent ST-segment elevation: Task Force for the Management of Acute Coronary Syndromes in Patients Presenting without Persistent ST-Segment Elevation of the European Society of Cardiology (ESC). *Eur Heart J* 2016; **37**: 267-315 [PMID: [26320110](#) DOI: [10.1093/eurheartj/ehv320](#)]
- 15 **Fanning JP**, Nyong J, Scott IA, Aroney CN, Walters DL. Routine invasive strategies vs selective invasive strategies for unstable angina and non-ST elevation myocardial infarction in the stent era. *Cochrane Database Syst Rev* 2016; CD004815 [PMID: [27226069](#) DOI: [10.1002/14651858.CD004815.pub4](#)]
- 16 **Boden WE**, O'Rourke RA, Crawford MH, Blaustein AS, Deedwania PC, Zoble RG, Wexler LF, Kleiger RE, Pepine CJ, Ferry DR, Chow BK, Lavori PW. Outcomes in patients with acute non-Q-wave myocardial infarction randomly assigned to an invasive as compared with a conservative management strategy. Veterans Affairs Non-Q-Wave Infarction Strategies in Hospital (VANQWISH) Trial Investigators. *N Engl J Med* 1998; **338**: 1785-1792 [PMID: [9632444](#) DOI: [10.1056/NEJM199806183382501](#)]
- 17 **Fox KA**, Clayton TC, Damman P, Pocock SJ, de Winter RJ, Tijssen JG, Lagerqvist B, Wallentin L; FIR Collaboration. Long-term outcome of a routine vs selective invasive strategy in patients with non-ST-segment elevation acute coronary syndrome a meta-analysis of individual patient data. *J Am Coll Cardiol* 2010; **55**: 2435-2445 [PMID: [20359842](#) DOI: [10.1016/j.jacc.2010.03.007](#)]
- 18 **Hoedemaker NPG**, Damman P, Woudstra P, Hirsch A, Windhausen F, Tijssen JGP, de Winter RJ; ICTUS Investigators. Early Invasive Vs Selective Strategy for Non-ST-Segment Elevation Acute Coronary Syndrome: The ICTUS Trial. *J Am Coll Cardiol* 2017; **69**: 1883-1893 [PMID: [28408018](#) DOI: [10.1016/j.jacc.2017.02.023](#)]
- 19 **Henderson RA**, Jarvis C, Clayton T, Pocock SJ, Fox KA. 10-Year Mortality Outcome of a Routine Invasive Strategy Vs a Selective Invasive Strategy in Non-ST-Segment Elevation Acute Coronary Syndrome: The British Heart Foundation RITA-3 Randomized Trial. *J Am Coll Cardiol* 2015; **66**: 511-520 [PMID: [26227188](#) DOI: [10.1016/j.jacc.2015.05.051](#)]
- 20 **Wallentin L**, Lindhagen L, Årnström E, Husted S, Janzon M, Johnsen SP, Kontny F, Kempf T, Levin LÅ, Lindahl B, Stridsberg M, Ståhle E, Venge P, Wollert KC, Swahn E, Lagerqvist B; FRISC-II study group. Early invasive vs non-invasive treatment in patients with non-ST-elevation acute coronary syndrome (FRISC-II): 15 year follow-up of a prospective, randomised, multicentre study. *Lancet* 2016; **388**: 1903-1911 [PMID: [27585757](#) DOI: [10.1016/S0140-6736\(16\)31276-4](#)]
- 21 **Hoedemaker NPG**, Damman P, de Winter RJ. Reply: Early Revascularization in NSTEMI-ACS: Insights From the ICTUS Long-Term Follow-Up. *J Am Coll Cardiol* 2017; **70**: 1424-1425 [PMID: [28882244](#) DOI: [10.1016/j.jacc.2017.06.067](#)]



Published By Baishideng Publishing Group Inc
7041 Koll Center Parkway, Suite 160, Pleasanton, CA 94566, USA
Telephone: +1-925-2238242
E-mail: bpgoffice@wjgnet.com
Help Desk: <https://www.f6publishing.com/helpdesk>
<https://www.wjgnet.com>

