



All Images Videos

翻译成中文

关闭取词

1,990,000 Results

Any time ▾

Intestinal anisakiasis can cause intussusception in adults ...

<https://www.ncbi.nlm.nih.gov/pmc/articles/PMC2852833>

Apr 14, 2010 · We report an **extremely rare case of adult intussusception caused by anisakiasis**. A 41-year-old man was admitted into our hospital for right lower abdominal colicky pain. Ultrasonography and computed tomography revealed the presence of **intussusception**. As ...

Cited by: 19

Author: Miura T, Iwaya A, Shimizu T, Tsuchiya J,...

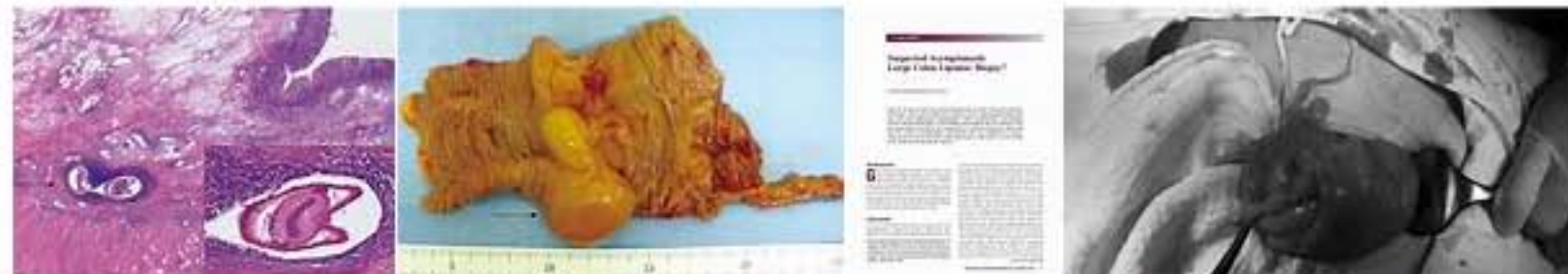Publish Year: 2010

Colonic Intussusception Caused by Anisakiasis: A Case ...

https://www.researchgate.net/publication/234133827_Colonic_Intussusception_Caused_by...

We report an **extremely rare case of adult intussusception caused by anisakiasis**. A 41-year-old man was admitted into our hospital for right lower abdominal colicky pain.

Images of adult intussusception caused by colonic anisakis a...

<bing.com/images>

See more images of adult intussusception caused by colonic anisakis an extremely rare case

Intestinal anisakiasis can cause intussusception in adults ...

https://www.researchgate.net/publication/43081269_Intestinal_anisakiasis_can_cause...

PDF | We report an **extremely rare case of adult intussusception caused by anisakiasis**. A 41-year-old man was admitted into our hospital for right lower abdominal colicky pain. Ultrasonography and ...

Adult intussusception caused by Meckel's ... - SpringerLink

<https://link.springer.com/article/10.1007/s12328-014-0502-6>

Jun 14, 2014 · We report an **extremely rare case of adult intussusception caused by Meckel's diverticulum complicated by anisakiasis** of the small intestine. A 48-year-old female was admitted to our hospital with vomiting and abdominal pain 3 days after eating ...

Cited by: 1

Author: Kenei Furukawa, Kazuhiko Yoshida, Taku...

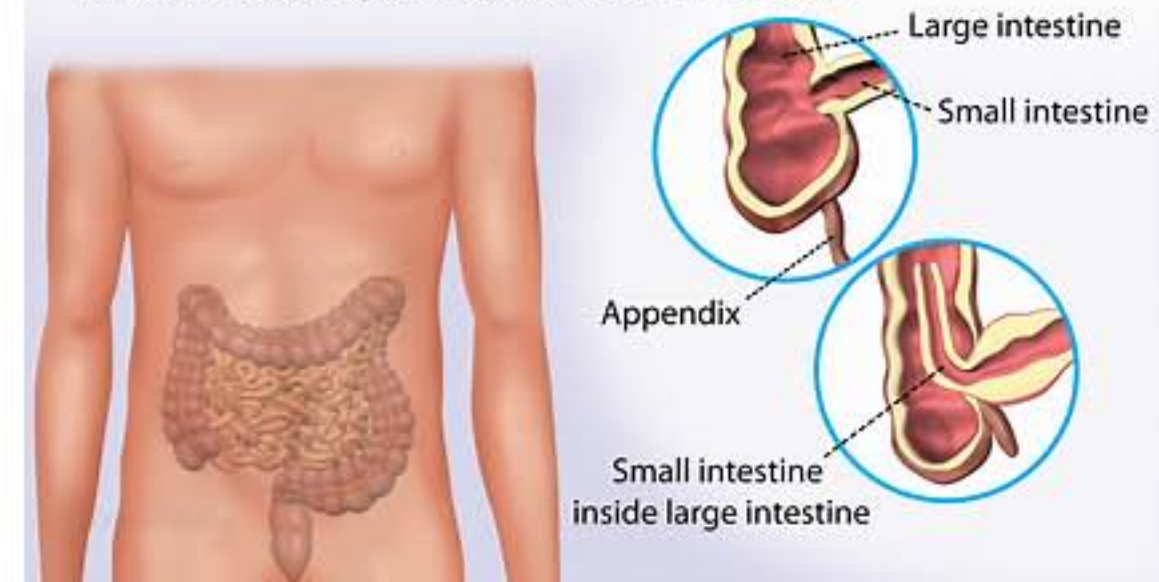
Publish Year: 2014

Location: Tokyo

Intussusception

Medical Condition

Intestinal obstruction in which one segment of intestine folds into the adjacent portion the intestine



Intestinal obstruction that results when a part of the intestine folds into a section next to it.

🏠 Rare (Fewer than 200,000 cases per year in US)

🔬 Diagnosis requires lab test or imaging

👨⚕️ Treatment from medical professional advised

🕒 Can last several weeks or months

More common in children, the cause is unknown. Sometimes, it could be a result of an abnormal growth in the intestines, e.g. a tumor. The symptoms include stool mixed with mucus, vomiting, diarrhea, fever, a lump in the abdomen. If diagnosed early, it can be treated through a minor procedure. In adults, surgery may be necessary.

Symptoms

The symptoms are as a result of intestinal obstruction. They include:

- Loud crying with their knees pulled up to chest due to abdominal pain, in infants
- Nausea and vomiting

Name of Journal: *World Journal of Clinical Cases*

Manuscript NO: 48970

Manuscript Type: CASE REPORT

Adult intussusception caused by colonic anisakis: A case report

Choi YI *et al.* Anisakis and adult intussusception

Youn I Choi, Dong Kyun Park, Hyun Yee Cho, Seung Joon Choi, Jun-Won Chung,
Kyung Oh Kim, Kwang An Kwon, Yoon Jae Kim

Abstract

BACKGROUND

Colo-colonic intussusception is an uncommon phenomenon in an adult. Adult

Match Overview

1	Crossref 33 words Kenei Furukawa, Kazuhiko Yoshida, Takuya Nojiri, Masaichi Ogawa, Shuzou Kohno, Katsuhiko Yanaga. "Adult intussu	2%
2	Crossref 14 words Yuto Shimamura, Niroshan Muwanwella, Sujievvann Chandran, Gabor Kandel, Norman Marcon. "Common Symptoms f	1%
3	Crossref 12 words Yasuhiro Murata, Katsuhiko Ando, Masanobu Usui, Hiromu Sugiyama et al. "A case of hepatic anisakiasis caused by ...	1%
4	Internet 10 words crawled on 26-Jun-2016 www.wjgnet.com	1%



国内版

国际版

Adult intussusception caused by colonic anisakis: A case report



All

Images

Videos

38,400 Results

Any time ▾

Intestinal anisakiasis can cause intussusception in adults ...

<https://www.ncbi.nlm.nih.gov/pmc/articles/PMC2852833>

Apr 14, 2010 · **Intestinal anisakiasis can cause intussusception in adults**: An extremely rare condition. Author contributions: Miura T, Tsuchiya J, Nakamura J, Yamada S, Miura T, Yanagi M and Takahashi T wrote the paper; Iwaya A and Shimizu T performed the operation; Usuda H and Emura I were involved in the pathological examination of the patient.

Cited by: 19**Author:** Miura T, Iwaya A, Shimizu T, Tsuchiya J, ...**Publish Year:** 2010

Colonic Intussusception Caused by Anisakiasis: A Case ...

https://www.jstage.jst.go.jp/article/internalmedicine/52/2/52_52.8629/_article

The patient noted that she had eaten raw fish one day before the **symptoms** developed. Although **colonic intussusception caused by anisakiasis** is extremely rare, **colonoscopy** should be performed in **colonic intussusception** patients suspected of having **anisakiasis** in order to **avoid invasive resection**.

Cited by: 21**Author:** Nobukazu Yorimitsu, Atsushi Hiraoka, Hi...**Publish Year:** 2013

Colonic Intussusception Caused by Anisakiasis: A Case ...

https://www.researchgate.net/publication/234133827_Colonic_Intussusception_Caused_by...

We report an extremely rare case of **adult intussusception caused by anisakiasis**. A **41-year-old man** was admitted into our hospital for right lower **abdominal colicky pain**.

Adult intussusception: case reports and review of ...

<https://pmj.bmj.com/content/81/953/174>

Mar 01, 2005 · **Adult intussusception occurs** infrequently and differs from childhood **intussusception** in its presentation, aetiology, and **treatment**. **Diagnosis** can be delayed because of its longstanding, intermittent, and non-specific **symptoms** and most **cases** are diagnosed at emergency laparotomy.


Cited by: 157**Author:** S Yalamarathi, R C Smith**Publish Year:** 2005

Adult intussusception caused by Meckel's - Springerlink

Intussusception

Medical Condition

Intestinal obstruction that results when a part of the intestine folds into a section next to it.

 Rare (Fewer than 200,000 cases per year in US) Diagnosis requires lab test or imaging Treatment from medical professional advised Can last several weeks or months

More common in children, the cause is unknown. Sometimes, it could be a result of an abnormal growth in the intestines, e.g. a tumor. The symptoms include stool mixed with mucus, vomiting, diarrhea, fever, a lump in the abdomen. If diagnosed early, it can be treated through a minor procedure. In adults, surgery may be necessary.

Symptoms

The symptoms are as a result of intestinal obstruction. They include:

- Loud crying with their knees pulled up to chest due to abdominal pain, in infants



All

Images

Videos

翻译成中文

开启取词

37,900 Results

Any time ▾

[PDF] Colonic Intussusception Caused by Anisakiasis: A Case ...https://www.jstage.jst.go.jp/article/internalmedicine/52/2/52_52.8629/_pdf-char/en

involve gastric anisakiasis, and colonic anisakiasis is extremely rare. Additionally, intussusception of the colon in adults is also rare and is primarily caused by colonic neoplasms(3). We herein report an extremely rare case of intussusception caused by colonic anisakiasis. Case Report A 67-year-old Japanese woman visited an emergency hos-

Colonic Intussusception Caused by Anisakiasis: A Case ...https://www.researchgate.net/publication/234133827_Colonic_Intussusception_Caused_by...

We report an extremely rare case of adult intussusception caused by anisakiasis. A 41-year-old man was admitted into our hospital for right lower abdominal colicky pain.

Colonic Intussusception Caused by Anisakiasis: A Case ...https://www.jstage.jst.go.jp/article/internalmedicine/52/2/52_52.8629/_article

Colonic Intussusception Caused by Anisakiasis: A Case Report and Review of the Literature. ... Although colonic intussusception caused by anisakiasis is extremely rare, colonoscopy should be performed in colonic intussusception patients suspected of having anisakiasis in order to avoid invasive resection.

Cited by: 21

Author: Nobukazu Yorimitsu, Atsushi Hiraoka, Hir...

Publish Year: 2013

Intestinal anisakiasis can cause intussusception in adults ...<https://www.ncbi.nlm.nih.gov/pmc/articles/PMC2852833>

Apr 14, 2010 · Intestinal anisakiasis can cause intussusception in adults: An extremely rare condition. Author contributions: Miura T, Tsuchiya J, Nakamura J, Yamada S, Miura T, Yanagi M and Takahashi T wrote the paper; Iwaya A and Shimizu T performed the operation; Usuda H and Emura I were involved in the pathological examination of the patient.

Cited by: 19

Author: Miura T, Iwaya A, Shimizu T, Tsuchiya J, ...

Publish Year: 2010

Adult intussusception caused by Meckel's ... - SpringerLink<https://link.springer.com/article/10.1007/s12328-014-0502-6>

Jun 14, 2014 · Adult intussusception represents 5 % of all cases of intussusception and accounts for only 1–5 % of intestinal obstructions in adults [1]. In adults, almost 90 % of the cases of intussusception are secondary to carcinoma, polyp, Meckel's diverticulum, colonic diverticulum...

Cited by: 1

Author: Kenei Furukawa, Kazuhiko Yoshida, Taku...

Publish Year: 2014 Location: Tokyo

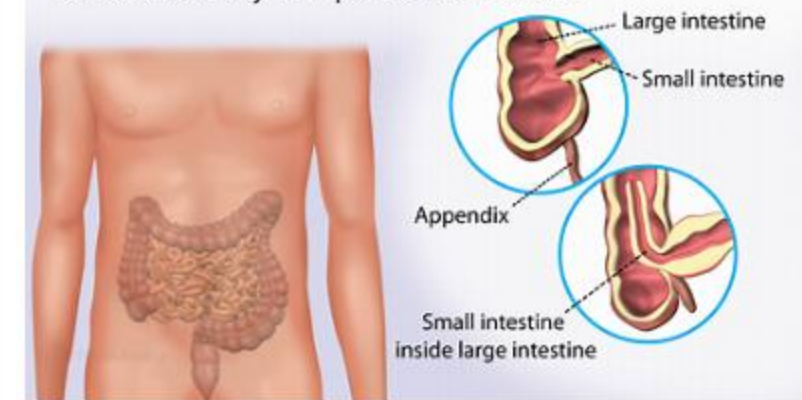
Colonic intussusception caused by a sigmoidal lipoma: A ...

<https://cn.bing.com/?FORM=Z9FD1> [cedirect.com/science/article/abs/pii/S221026128302116](https://pubmed.ncbi.nlm.nih.gov/2521026128302116)
adult intussusception is the cause of symptomatic bowel obstruction in 1% of cases and its colo

Intussusception

Medical Condition

Intestinal obstruction in which one segment of intestine folds into the adjacent portion the intestine



Intestinal obstruction that results when a part of the intestine folds into a section next to it.

Rare (Fewer than 200,000 cases per year in US)

Requires lab test or imaging

Treatment from medical professional advised

Can last several weeks or months

More common in children, the cause is unknown. Sometimes, it could be a result of an abnormal growth in the intestines, e.g. a tumor. The symptoms include stool mixed with mucus, vomiting, diarrhea, fever, a lump in the abdomen. If diagnosed early, it can be treated through a minor procedure. In adults, surgery may be necessary.

Symptoms

The symptoms are as a result of intestinal obstruction. They include:

- Loud crying with their knees pulled up to chest due to abdominal pain, in infants
- Nausea and vomiting
- Rectal bleeding
- Production of 'red currant jelly stool'
- Lethargy
- Sausage-shaped mass in the abdomen upon palpation

Treatments

This is a medical emergency. Avoid using over-the-counter medication to