

World Journal of *Clinical Cases*

World J Clin Cases 2019 October 26; 7(20): 3168-3383



**OPINION REVIEW**

- 3168** Clinical use of low-dose aspirin for elders and sensitive subjects
Zhang Y, Fang XM, Chen GX

ORIGINAL ARTICLE**Retrospective Study**

- 3175** Distribution and drug resistance of pathogenic bacteria in emergency patients
Huai W, Ma QB, Zheng JJ, Zhao Y, Zhai QR
- 3185** Comparative analysis of robotic *vs* laparoscopic radical hysterectomy for cervical cancer
Chen L, Liu LP, Wen N, Qiao X, Meng YG
- 3194** Feasibility of laparoscopic isolated caudate lobe resection for rare hepatic mesenchymal neoplasms
Li Y, Zeng KN, Ruan DY, Yao J, Yang Y, Chen GH, Wang GS
- 3202** Rh-incompatible hemolytic disease of the newborn in Hefei
Bi SH, Jiang LL, Dai LY, Zheng H, Zhang J, Wang LL, Wang C, Jiang Q, Liu Y, Zhang YL, Wang J, Zhu C, Liu GH, Teng RJ
- 3208** Soft tissue release combined with joint-sparing osteotomy for treatment of cavovarus foot deformity in older children: Analysis of 21 cases
Chen ZY, Wu ZY, An YH, Dong LF, He J, Chen R

Observational Study

- 3217** Clinical characteristics of sentinel polyps and their correlation with proximal colon cancer: A retrospective observational study
Wang M, Lu JJ, Kong WJ, Kang XJ, Gao F

Prospective Study

- 3226** Longitudinal observation of intraocular pressure variations with acute altitude changes
Xie Y, Sun YX, Han Y, Yang DY, Yang YQ, Cao K, Li SN, Li X, Lu XX, Wu SZ, Wang NL

Randomized Controlled Trial

- 3237** Combination of propofol and dezocine to improve safety and efficacy of anesthesia for gastroscopy and colonoscopy in adults: A randomized, double-blind, controlled trial
Li XT, Ma CQ, Qi SH, Zhang LM

META-ANALYSIS

- 3247** Prognostic significance of malignant ascites in gastric cancer patients with peritoneal metastasis: A systemic review and meta-analysis
Zheng LN, Wen F, Xu P, Zhang S

CASE REPORT

- 3259** Gonadotrophin-releasing hormone agonist-induced pituitary adenoma apoplexy and casual finding of a parathyroid carcinoma: A case report and review of literature
Triviño V, Fidalgo O, Juane A, Pombo J, Cordido F
- 3266** Constrictive pericarditis as a cause of refractory ascites after liver transplantation: A case report
Bezjak M, Kocman B, Jadrijević S, Gašparović H, Mrzljak A, Kanižaj TF, Vujanić D, Bubalo T, Mikulić D
- 3271** Endoluminal closure of an unrecognized penetrating stab wound of the duodenum with endoscopic band ligation: A case report
Kim DH, Choi H, Kim KB, Yun HY, Han JH
- 3276** Spontaneous superior mesenteric artery dissection following upper gastrointestinal panendoscopy: A case report and literature review
Ou Yang CM, Yen YT, Chua CH, Wu CC, Chu KE, Hung TI
- 3282** Hepatic amyloidosis leading to hepatic venular occlusive disease and Budd-Chiari syndrome: A case report
Li TT, Wu YF, Liu FQ, He FL
- 3289** Termination of a partial hydatidiform mole and coexisting fetus: A case report
Zhang RQ, Zhang JR, Li SD
- 3296** De Winter syndrome and ST-segment elevation myocardial infarction can evolve into one another: Report of two cases
Lin YY, Wen YD, Wu GL, Xu XD
- 3303** Next generation sequencing reveals co-existence of hereditary spherocytosis and Dubin-Johnson syndrome in a Chinese girl: A case report
Li Y, Li Y, Yang Y, Yang WR, Li JP, Peng GX, Song L, Fan HH, Ye L, Xiong YZ, Wu ZJ, Zhou K, Zhao X, Jing LP, Zhang FK, Zhang L
- 3310** Recognizable type of pituitary, heart, kidney and skeletal dysplasia mostly caused by SEMA3A mutation: A case report
Hu F, Sun L
- 3316** Dermatofibrosarcoma metastases to the pancreas: A case report
Cai HJ, Fang JH, Cao N, Wang W, Kong FL, Sun XX, Huang B

- 3322** Repeated lumps and infections: A case report on breast augmentation complications
Zhang MX, Li SY, Xu LL, Zhao BW, Cai XY, Wang GL
- 3329** Severe mental disorders following anti-retroviral treatment in a patient on peritoneal dialysis: A case report and literature review
He QE, Xia M, Ying GH, He XL, Chen JH, Yang Y
- 3335** Fish bone-induced myocardial injury leading to a misdiagnosis of acute myocardial infarction: A case report
Wang QQ, Hu Y, Zhu LF, Zhu WJ, Shen P
- 3341** Potentially fatal electrolyte imbalance caused by severe hydrofluoric acid burns combined with inhalation injury: A case report
Fang H, Wang GY, Wang X, He F, Su JD
- 3347** Ureter - an unusual site of breast cancer metastasis: A case report
Zhou ZH, Sun LJ, Zhang GM
- 3353** Alternative technique to save ischemic bowel segment in management of neonatal short bowel syndrome: A case report
Geng L, Zhou L, Ding GJ, Xu XL, Wu YM, Liu JJ, Fu TL
- 3358** Sister Mary Joseph's nodule in endometrial carcinoma: A case report
Li Y, Guo P, Wang B, Jia YT
- 3364** Synchronous quadruple primary malignancies of the cervix, endometrium, ovary, and stomach in a single patient: A case report and review of literature
Wang DD, Yang Q
- 3372** Ureteral Ewing's sarcoma in an elderly woman: A case report
Li XX, Bi JB
- 3377** Anaplastic lymphoma kinase-negative anaplastic large cell lymphoma masquerading as Behcet's disease: A case report and review of literature
Luo J, Jiang YH, Lei Z, Miao YL

ABOUT COVER

Editorial Board Member of *World Journal of Clinical Cases*, Faycal Lakhdar, MD, Professor, Department of Neurosurgery, University Hospital Center of Fes, University Sidi Mohammed Ben Abdellah, FES 10000, Morocco

AIMS AND SCOPE

The primary aim of *World Journal of Clinical Cases* (WJCC, *World J Clin Cases*) is to provide scholars and readers from various fields of clinical medicine with a platform to publish high-quality clinical research articles and communicate their research findings online.

WJCC mainly publishes articles reporting research results and findings obtained in the field of clinical medicine and covering a wide range of topics, including case control studies, retrospective cohort studies, retrospective studies, clinical trials studies, observational studies, prospective studies, randomized controlled trials, randomized clinical trials, systematic reviews, meta-analysis, and case reports.

INDEXING/ABSTRACTING

The WJCC is now indexed in PubMed, PubMed Central, Science Citation Index Expanded (also known as SciSearch®), and Journal Citation Reports/Science Edition. The 2019 Edition of Journal Citation Reports cites the 2018 impact factor for WJCC as 1.153 (5-year impact factor: N/A), ranking WJCC as 99 among 160 journals in Medicine, General and Internal (quartile in category Q3).

RESPONSIBLE EDITORS FOR THIS ISSUE

Responsible Electronic Editor: Ji-Hong Liu

Proofing Production Department Director: Yun-Xiaojuan Wu

NAME OF JOURNAL

World Journal of Clinical Cases

ISSN

ISSN 2307-8960 (online)

LAUNCH DATE

April 16, 2013

FREQUENCY

Semimonthly

EDITORS-IN-CHIEF

Dennis A Bloomfield, Bao-Gan Peng, Sandro Vento

EDITORIAL BOARD MEMBERS

<https://www.wjnet.com/2307-8960/editorialboard.htm>

EDITORIAL OFFICE

Jin-Lei Wang, Director

PUBLICATION DATE

October 26, 2019

COPYRIGHT

© 2019 Baishideng Publishing Group Inc

INSTRUCTIONS TO AUTHORS

<https://www.wjnet.com/bpg/gerinfo/204>

GUIDELINES FOR ETHICS DOCUMENTS

<https://www.wjnet.com/bpg/GerInfo/287>

GUIDELINES FOR NON-NATIVE SPEAKERS OF ENGLISH

<https://www.wjnet.com/bpg/gerinfo/240>

PUBLICATION MISCONDUCT

<https://www.wjnet.com/bpg/gerinfo/208>

ARTICLE PROCESSING CHARGE

<https://www.wjnet.com/bpg/gerinfo/242>

STEPS FOR SUBMITTING MANUSCRIPTS

<https://www.wjnet.com/bpg/GerInfo/239>

ONLINE SUBMISSION

<https://www.f6publishing.com>

Constrictive pericarditis as a cause of refractory ascites after liver transplantation: A case report

Miran Bezjak, Branislav Kocman, Stipislav Jadrijević, Hrvoje Gašparović, Anna Mrzljak, Tajana Filipec Kanižaj, Darko Vujanić, Tomislav Bubalo, Danko Mikulić

ORCID number: Miran Bezjak (0000-0001-6235-1162); Branislav Kocman (0000-0003-1497-6031); Stipislav Jadrijević (0000-0002-0565-0665); Hrvoje Gašparović (0000-0002-2492-3702); Anna Mrzljak (0000-0001-6270-2305); Tajana Filipec Kanižaj (0000-0002-9828-8916); Darko Vujanić (0000-0003-0585-5887); Tomislav Bubalo (0000-0003-1422-8439); Danko Mikulić (0000-0001-8103-6045).

Author contributions: Bezjak M wrote the manuscript. Mikulić D and Gašparović H were the patient's operators. Mikulić D reviewed the literature and contributed to manuscript drafting. Mrzljak A reviewed the literature and contributed to manuscript drafting. Mikulić D, Kocman B, Jadrijević S and Filipec Kanižaj T were responsible for the revision of the manuscript for important intellectual content. Vujanić D was responsible for cardiologic treatment and contributed to diagnosis. Bubalo T contributed to manuscript drafting. All authors issued final approval for the version to be submitted.

Informed consent statement: Informed written consent was obtained from the patient for publication of this report and any accompanying images.

Conflict-of-interest statement: The authors declare that they have no conflict of interest.

CARE Checklist (2016) statement: The authors have read the CARE

Miran Bezjak, Branislav Kocman, Stipislav Jadrijević, Tomislav Bubalo, Danko Mikulić, Division of Abdominal Surgery and Organ Transplantation, Department of Surgery, University Hospital Merkur, Zagreb 10000, Croatia

Hrvoje Gašparović, Division of Cardiology, Department of Internal Medicine, University Hospital Centre Zagreb, Zagreb 10000, Croatia

Anna Mrzljak, Tajana Filipec Kanižaj, Division of Gastroenterology, Department of Internal Medicine, University Hospital Merkur, Zagreb 10000, Croatia

Darko Vujanić, Division of Cardiology, Department of Internal Medicine, University Hospital Merkur, Zagreb 10000, Croatia

Corresponding author: Danko Mikulić, FEBS, MD, PhD, Attending Doctor, Surgeon, Division of Abdominal Surgery and Organ Transplantation, Department of Surgery, University Hospital Merkur, Zajčeva 19, Zagreb 10000, Croatia. danko.mikulic@zg.t-com.hr

Telephone: +385-1-2431390

Fax: +385-1-2431394

Abstract

BACKGROUND

Refractory ascites is a rare complication following orthotopic liver transplantation (OLT). The broad spectrum of differential diagnosis often leads to delay in diagnosis. Therapy depends on recognition and treatment of the underlying cause. Constrictive pericarditis is a condition characterized by clinical signs of right-sided heart failure. In the advanced stages of the disease, hepatic congestion leads to formation of ascites. In patients after OLT, cardiac etiology of ascites is easily overlooked and it requires a high degree of clinical suspicion.

CASE SUMMARY

We report a case of a 55-year-old man who presented with a refractory ascites three months after liver transplantation for alcoholic cirrhosis. Prior to transplantation the patient had a minimal amount of ascites. The transplant procedure and the early postoperative course were uneventful. Standard post-transplant work up failed to reveal any typical cause of refractory post-transplant ascites. The function of the graft was good. Apart from atrial fibrillation, cardiac status was normal. Eighteen months post transplantation the patient developed dyspnea and severe fatigue with peripheral edema. Ascites was still prominent. The presenting signs of right-sided heart failure were highly suggestive of cardiac etiology. Diagnostic paracentesis was suggestive of cardiac ascites, and

Checklist (2016), and the manuscript was prepared and revised according to the CARE Checklist (2016).

Open-Access: This article is an open-access article which was selected by an in-house editor and fully peer-reviewed by external reviewers. It is distributed in accordance with the Creative Commons Attribution Non Commercial (CC BY-NC 4.0) license, which permits others to distribute, remix, adapt, build upon this work non-commercially, and license their derivative works on different terms, provided the original work is properly cited and the use is non-commercial. See: <http://creativecommons.org/licenses/by-nc/4.0/>

Manuscript source: Invited manuscript

Received: May 28, 2019

Peer-review started: June 4, 2019

First decision: August 1, 2019

Revised: August 23, 2019

Accepted: October 5, 2019

Article in press: October 5, 2019

Published online: October 26, 2019

P-Reviewer: Ramsay MA, Bramhall S

S-Editor: Dou Y

L-Editor: A

E-Editor: Liu JH



further cardiac evaluation showed typical signs of constrictive pericarditis. Pericardiectomy was performed followed by complete resolution of ascites. On the follow-up the patient remained symptom-free with no signs of recurrent ascites and with normal function of the liver graft.

CONCLUSION

Refractory ascites following liver transplantation is a rare complication with many possible causes. Broad differential diagnosis needs to be considered.

Key words: Constrictive pericarditis; Liver transplantation; Refractory ascites; Case report

©The Author(s) 2019. Published by Baishideng Publishing Group Inc. All rights reserved.

Core tip: Refractory ascites following liver transplantation is a rare complication with many possible causes. Constrictive pericarditis is a disease characterized by clinical signs of right-sided heart failure which in the advanced stages can lead to hepatic congestion and formation of ascites. As a cause of refractory ascites it is easily overlooked and it requires a high degree of clinical suspicion. We present an uncommon case where refractory ascites occurred after successful liver transplantation for alcoholic cirrhosis and was caused by previously unknown constrictive pericarditis. Pericardiectomy led to complete resolution of the ascites, and the patient remained symptom free until today.

Citation: Bezjak M, Kocman B, Jadrijević S, Gašparović H, Mrzljak A, Kanižaj TF, Vujanić D, Bubalo T, Mikulić D. Constrictive pericarditis as a cause of refractory ascites after liver transplantation: A case report. *World J Clin Cases* 2019; 7(20): 3266-3270

URL: <https://www.wjgnet.com/2307-8960/full/v7/i20/3266.htm>

DOI: <https://dx.doi.org/10.12998/wjcc.v7.i20.3266>

INTRODUCTION

Refractory ascites is a rare complication following orthotopic liver transplantation (OLT). It is defined as persistent ascites present for more than four weeks after a successful transplantation. It occurs in about 5% of patients after OLT and it is associated with reduced 1-year survival. Etiology may be diverse with the most common underlying causes being bacterial peritonitis, obstruction of portal or hepatic veins, graft rejection, and renal or cardiac dysfunction. Therapy depends on recognition and treatment of the underlying cause^[1-4]. Constrictive pericarditis is a condition characterized by clinical signs of chronic right-sided heart failure, including peripheral edema and liver congestion. In the advanced stages of the disease, hepatic congestion leads to formation of ascites, as well as liver fibrosis and cirrhosis (cardiac cirrhosis). In patients after OLT, cardiac etiology of ascites is easily overlooked and it requires a high degree of clinical suspicion^[5-8].

The purpose of this case report is to summarize the cases of refractory ascites caused by constrictive pericarditis that have been published to date, to evaluate the results and analyze the approach in differential diagnosis. Also, we present an uncommon case where refractory ascites caused by constrictive pericarditis occurred in patient with a transplanted liver. A Pubmed literature search was performed for studies dealing with refractory ascites caused by constrictive pericarditis published between 2000 and 2018. Key words used were constrictive pericarditis, refractory ascites, recurrent ascites, liver transplantation, ascitic fluid, pericardiectomy. Only studies published in English were analyzed.

CASE PRESENTATION

Chief complaints

A 55-year-old caucasian man underwent OLT for alcoholic cirrhosis. Prior to transplantation the patient only had a minimal amount of ascites. Apart from atrial fibrillation he had no other comorbidities. The transplant procedure and the early postoperative course were uneventful. The patient was discharged home on the 9th

post-operative day with normal liver function tests and in good general condition. Three months post transplantation he presented with prominent ascites resistant to conventional diuretic treatment.

History of present illness

All of the typical causes of post-transplant ascites were initially excluded. There were no signs of bacterial peritonitis, and paracentesis revealed ascitic fluid to be transudate. Doppler ultrasound and computed tomography were normal, showing patent anastomoses and no other morphological or vascular abnormalities. Liver biopsy showed no signs of graft failure or rejection. Liver function tests and other laboratory values were within normal limits. Apart from atrial fibrillation, there were no abnormalities in the cardiac status. Heart ultrasound showed mild mitral insufficiency with a slightly elevated pressure in the right ventricle. The ascites was explained by poorly regulated atrial fibrillation aggravated by mild anemia which upon correction improved slightly.

History of past illness

Apart from atrial fibrillation the patient had no significant past medical history prior to transplantation.

Personal and family history

The patient had no significant personal or family history.

Physical examination upon admission

Eighteen months post transplantation he developed dyspnea with severe fatigue and peripheral edema with prominent ascites and a significant weight gain. The presenting signs of right-sided heart failure were highly suggestive of cardiac etiology.

Imaging examinations

Cardiac catheterisation revealed slightly elevated pressures in all four chambers and equalization of diastolic chamber pressures also known as the square root sign. This is the typical presentation of constrictive pericarditis and computed tomography showed excessive pericardial calcifications (Figures 1 and 2). The patient underwent an open pericardiectomy. The procedure was complicated by acute kidney injury which required intermittent hemodialysis. This was followed by improvement of the patient's general condition as well as of his renal function. There were no other complications related to the procedure. Following pericardiectomy, ascites improved dramatically with complete regression of all symptoms. On the follow-up the patient remained symptom-free with no signs of recurrent ascites and with normal function of the liver graft.

FINAL DIAGNOSIS

Constrictive pericarditis.

TREATMENT

Total pericardiectomy.

OUTCOME AND FOLLOW-UP

After total pericardiectomy ascites improved dramatically with complete regression of all symptoms. On the follow-up the patient remained symptom-free with no signs of recurrent ascites and with normal function of the liver graft.

DISCUSSION

Refractory ascites after OLT is a rare complication occurring in about 5% of patients and it is usually a complication of the transplant procedure. The difficulties in the differential diagnosis of refractory ascites have been described and a delay in diagnosis is common^[6-10]. Most common underlying causes are bacterial or fungal peritonitis, obstruction of the portal or hepatic veins and graft rejection. Patients with

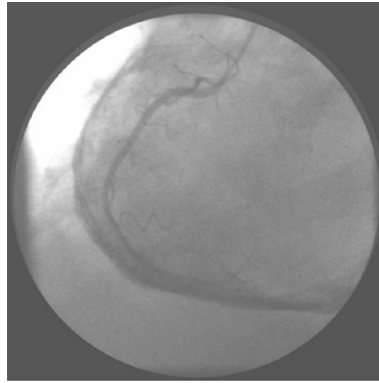


Figure 1 Heart catheterization with the view of the thickened pericardium.

refractory ascites after liver transplantation often have prolonged hospital stay and reduced 1-year survival. The treatment should be directed at the cause of ascites^[1,2]. In cases without an obvious cause of ascites, splenic artery embolization has been described as a good therapeutic measure improving intrahepatic hemodynamics after liver transplantation^[2]. Constrictive pericarditis is a rare cause of refractory ascites after liver transplantation. There are also several case reports describing constrictive pericarditis after renal transplantation leading both to graft dysfunction and liver disease^[11]. This disease of the pericardium was described as *concretio cordis* over 300 years ago and it is characterized by fibrosis and thickening of the pericardial wall and calcifications of the pericardium^[5]. Due to the heart constriction, diastolic filling is impaired. The myocardium is not affected and early diastolic filling of the ventricle is normal, however, at one point the thickened pericardium prevents the ventricle from further expansion and restricts the cardiac blood flow. Disturbance of the blood flow leads to equalization of pressures in the right and left ventricles and higher pressure exerted on the interventricular septum, thus increasing the pressure in the splanchnic system. This explains the common clinical phenomenon, Kussmaul's sign, inspiratory distention of jugular veins. The most common etiology of constrictive pericarditis includes heart surgery, radiation therapy and idiopathic pericarditis. Tuberculosis remains an important etiological factor in undeveloped countries. Clinical presentation of the illness is characterized by the signs of right-sided heart failure, peripheral edema and hepatic congestion. In advanced stages, hepatic congestion can progress into fibrosis and cirrhosis, also known as cardiac cirrhosis, manifesting with edema and jaundice. Severe muscle wasting and cachexia are also described^[5-7]. In some studies, ascites was present in 45% of patients with constrictive pericarditis^[5]. Differential diagnosis includes right-sided heart failure due to restrictive cardiomyopathy, inferior vena cava obstruction, tricuspid valve dysfunction, hepatic diseases, abdominal malignancies and some rare causes such as right atrial myxoma^[5,6]. Analysis of the ascites may be helpful, with a unique pattern associated with constrictive pericarditis. Relatively high serum-ascitic fluid albumin gradient (SAAG) above 1.1 g/dL and total protein concentration greater than 2.5 g/dL makes it an exudate with high SAAG. Such levels of total protein count are also typical of other postsinusoidal causes of ascites, in comparison with cirrhotic ascites which is usually a transudate with lower total protein count and high SAAG^[12,13]. Echocardiography is the initial imaging method. The criteria pointing to the diagnosis of constrictive pericarditis include thickened pericardium, inspiratory shift of interventricular septum to the left described as "septal bounce" due to pressure changes in the heart, non-collapsing inferior vena cava and reduced diastolic filling. Cardiac catheterization is considered the gold standard in the diagnosis of constrictive pericarditis. Simultaneous catheterization of both ventricles shows equalization of diastolic chamber pressures^[5-8]. Computed tomography and magnetic resonance imaging are useful non-invasive diagnostic tools with excellent sensitivity (88%) and specificity (100%). They allow for direct visualization of the pericardial thickening and calcifications^[7]. Pericardiectomy is the treatment of choice for symptomatic and severe constrictive pericarditis with surgical mortality of 6% and 7-year survival of about 88%^[14,15].

CONCLUSION

Refractory ascites is a rare complication occurring after liver transplantation. Etiology

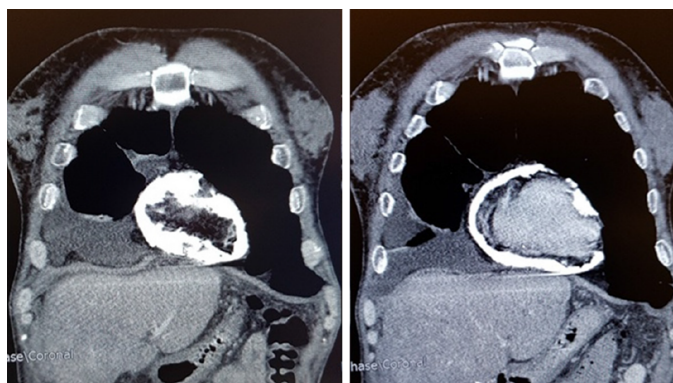


Figure 2 Computed tomography of the heart with excessive pericardial calcifications.

is diverse, and if typical causes related to the transplantation are excluded, more uncommon reasons need to be considered. Constrictive pericarditis is a common cause of refractory ascites, however, only rarely described after liver transplantation. Good outcome of total pericardiectomy in the presented case underlines the importance of a correct and timely diagnosis.

REFERENCES

- 1 **Gotthardt DN**, Weiss KH, Rathenberg V, Schemmer P, Stremmel W, Sauer P. Persistent ascites after liver transplantation: etiology, treatment and impact on survival. *Ann Transplant* 2013; **18**: 378-383 [PMID: [23881303](#) DOI: [10.12659/AOT.883982](#)]
- 2 **Runyon BA**; AASLD Practice Guidelines Committee. Management of adult patients with ascites due to cirrhosis: an update. *Hepatology* 2009; **49**: 2087-2107 [PMID: [19475696](#) DOI: [10.1002/hep.22853](#)]
- 3 **Quintini C**, D'Amico G, Brown C, Aucejo F, Hashimoto K, Kelly DM, Eghtesad B, Sands M, Fung JJ, Miller CM. Splenic artery embolization for the treatment of refractory ascites after liver transplantation. *Liver Transpl* 2011; **17**: 668-673 [PMID: [21618687](#) DOI: [10.1002/lt.22280](#)]
- 4 **Saad WE**, Darwish WM, Davies MG, Waldman DL. Transjugular intrahepatic portosystemic shunts in liver transplant recipients for management of refractory ascites: clinical outcome. *J Vasc Interv Radiol* 2010; **21**: 218-223 [PMID: [20123207](#) DOI: [10.1016/j.jvir.2009.10.025](#)]
- 5 **Bergman M**, Vitrai J, Salman H. Constrictive pericarditis: A reminder of a not so rare disease. *Eur J Intern Med* 2006; **17**: 457-464 [PMID: [17098587](#) DOI: [10.1016/j.ejim.2006.07.006](#)]
- 6 **Lominadze Z**, Kia L, Shah S, Parekh K, Levitsky J. Constrictive Pericarditis as a Cause of Refractory Ascites. *ACG Case Rep J* 2015; **2**: 175-177 [PMID: [26157955](#) DOI: [10.14309/crj.2015.46](#)]
- 7 **Howard JP**, Jones D, Mills P, Marley R, Wragg A. Recurrent ascites due to constrictive pericarditis. *Frontline Gastroenterol* 2012; **3**: 233-237 [PMID: [28839673](#) DOI: [10.1136/flgastro-2012-100173](#)]
- 8 **Van der Merwe S**, Dens J, Daenen W, Desmet V, Fevery J. Pericardial disease is often not recognised as a cause of chronic severe ascites. *J Hepatol* 2000; **32**: 164-169 [PMID: [10673082](#) DOI: [10.1016/S0168-8278\(00\)80204-4](#)]
- 9 **Kamio T**, Hiraoka E, Obunai K, Watanabe H. Constrictive Pericarditis as a Long-term Undetermined Etiology of Ascites and Edema. *Intern Med* 2018; **57**: 1487-1491 [PMID: [29321423](#) DOI: [10.2169/intermalmedicine.9455-17](#)]
- 10 **Domingos Nunes GF**, Fatela N, Ramalho F. Long-evolution ascites in a patient with constrictive pericarditis. *Rev Esp Enferm Dig* 2016; **108**: 368-371 [PMID: [26219528](#) DOI: [10.17235/reed.2015.3728/2015](#)]
- 11 **Celebi ZK**, Keven K, Sengul S, Sayin T, Yazicioglu L, Tuzuner A, Erturk S, Duman N, Erbay B. Constrictive pericarditis after renal transplantation: three case reports. *Transplant Proc* 2013; **45**: 953-955 [PMID: [23622596](#) DOI: [10.1016/j.transproceed.2013.02.060](#)]
- 12 **Christou L**, Economou M, Economou G, Kolettis TM, Tsianos EV. Characteristics of ascitic fluid in cardiac ascites. *Scand J Gastroenterol* 2007; **42**: 1102-1105 [PMID: [17710677](#) DOI: [10.1080/00365520701272433](#)]
- 13 **Giallourakis CC**, Rosenberg PM, Friedman LS. The liver in heart failure. *Clin Liver Dis* 2002; **6**: 947-967, viii-viix [PMID: [12516201](#) DOI: [10.1016/S1089-3261\(02\)00056-9](#)]
- 14 **Bertog SC**, Thambidorai SK, Parakh K, Schoenhagen P, Ozduran V, Houghtaling PL, Lytle BW, Blackstone EH, Lauer MS, Klein AL. Constrictive pericarditis: etiology and cause-specific survival after pericardiectomy. *J Am Coll Cardiol* 2004; **43**: 1445-1452 [PMID: [15093882](#) DOI: [10.1016/j.jacc.2003.11.048](#)]
- 15 **Chowdhury UK**, Subramaniam GK, Kumar AS, Airan B, Singh R, Talwar S, Seth S, Mishra PK, Pradeep KK, Sathia S, Venugopal P. Pericardiectomy for constrictive pericarditis: a clinical, echocardiographic, and hemodynamic evaluation of two surgical techniques. *Ann Thorac Surg* 2006; **81**: 522-529 [PMID: [16427843](#) DOI: [10.1016/j.athoracsur.2005.08.009](#)]



Published By Baishideng Publishing Group Inc
7041 Koll Center Parkway, Suite 160, Pleasanton, CA 94566, USA
Telephone: +1-925-2238242
E-mail: bpgoffice@wjgnet.com
Help Desk: <https://www.f6publishing.com/helpdesk>
<https://www.wjgnet.com>

