

# World Journal of *Cardiology*

*World J Cardiol* 2020 January 26; 12(1): 1-75





### EDITORIAL

- 1 Is there a role for ischemia detection after an acute myocardial infarction?  
*Peteiro J, Bouzas-Mosquera A*

### REVIEW

- 7 Diagnosis and treatment of heart failure with preserved left ventricular ejection fraction  
*Henning RJ*
- 26 Radial artery access site complications during cardiac procedures, clinical implications and potential solutions: The role of nitric oxide  
*Coghill EM, Johnson T, Morris RE, Megson IL, Leslie SJ*

### ORIGINAL ARTICLE

#### Observational Study

- 35 Impact of training specificity on exercise-induced cardiac troponin elevation in professional athletes: A pilot study  
*Wedin JO, Nyberg NS, Henriksson AE*
- 44 Prognostic impact of body mass index on in-hospital bleeding complications after ST-segment elevation myocardial infarction  
*Ingremau D, Grall S, Valliet F, Desprets L, Prunier F, Furber A, Bière L*

### CASE REPORT

- 55 Phrenic nerve displacement by intrapericardial balloon inflation during epicardial ablation of ventricular tachycardia: Four case reports  
*Conti S, Bonomo V, Taormina A, Giordano U, Sgarito G*
- 67 *Salmonella typhimurium* myopericarditis: A case report and review of literature  
*Jin D, Kao CY, Darby J, Palmer S*

**ABOUT COVER**

Editorial Board of *World Journal of Cardiology*, Barakat Adeola Animasahun, FACC, MBBS, Chief Doctor, Occupational Physician, Reader (Associate Professor), Department of Paediatrics and Child Health, Lagos State University College of Medicine, Lagos +23401, Nigeria

**AIMS AND SCOPE**

The primary aim of *World Journal of Cardiology* (WJC, *World J Cardiol*) is to provide scholars and readers from various fields of cardiology with a platform to publish high-quality basic and clinical research articles and communicate their research findings online.

WJC mainly publishes articles reporting research results and findings obtained in the field of cardiology and covering a wide range of topics including acute coronary syndromes, aneurysm, angina, arrhythmias, atherosclerosis, atrial fibrillation, cardiomyopathy, congenital heart disease, coronary artery disease, heart failure, hypertension, imaging, infection, myocardial infarction, pathology, peripheral vessels, public health, Raynaud's syndrome, stroke, thrombosis, and valvular disease.

**INDEXING/ABSTRACTING**

The WJC is now abstracted and indexed in Emerging Sources Citation Index (Web of Science), PubMed, PubMed Central, Scopus, China National Knowledge Infrastructure (CNKI), China Science and Technology Journal Database (CSTJ), and Superstar Journals Database.

**RESPONSIBLE EDITORS FOR THIS ISSUE**

Responsible Electronic Editor: *Yan-Liang Zhang*

Proofing Production Department Director: *Xiang Li*

**NAME OF JOURNAL**

*World Journal of Cardiology*

**ISSN**

ISSN 1949-8462 (online)

**LAUNCH DATE**

December 31, 2009

**FREQUENCY**

Monthly

**EDITORS-IN-CHIEF**

Ramdas G. Pai MD, FACC, FRCP (Edin), Marco Matteo Ciccone, Dimitris Tousoulis

**EDITORIAL BOARD MEMBERS**

<https://www.wjgnet.com/1949-8462/editorialboard.htm>

**EDITORIAL OFFICE**

Ruo-Yu Ma, Director

**PUBLICATION DATE**

January 26, 2020

**COPYRIGHT**

© 2020 Baishideng Publishing Group Inc

**INSTRUCTIONS TO AUTHORS**

<https://www.wjgnet.com/bpg/gerinfo/204>

**GUIDELINES FOR ETHICS DOCUMENTS**

<https://www.wjgnet.com/bpg/GerInfo/287>

**GUIDELINES FOR NON-NATIVE SPEAKERS OF ENGLISH**

<https://www.wjgnet.com/bpg/gerinfo/240>

**PUBLICATION MISCONDUCT**

<https://www.wjgnet.com/bpg/gerinfo/208>

**ARTICLE PROCESSING CHARGE**

<https://www.wjgnet.com/bpg/gerinfo/242>

**STEPS FOR SUBMITTING MANUSCRIPTS**

<https://www.wjgnet.com/bpg/GerInfo/239>

**ONLINE SUBMISSION**

<https://www.f6publishing.com>

## Salmonella typhimurium myopericarditis: A case report and review of literature

David Jin, Chien-Ying Kao, Jonathon Darby, Sonny Palmer

**ORCID number:** David Jin (0000-0002-7393-9540); Chien-Ying Kao (0000-0002-2307-9634); Jonathan Darby (0000-0001-5462-5215); Sonny Palmer (0000-0001-5305-1483).

**Author contributions:** Jin D, Darby J, and Palmer S designed the research; Jin D and Kao CY preformed the literature review; Darby J and Palmer S contributed to the writing of the discussion; Jin D and Kao CY wrote the paper.

**Informed consent statement:** All study participants or their legal guardian provided informed written consent about personal and medical data collection prior to study enrolment. Copy of this statement is available upon request.

**Conflict-of-interest statement:** David Jin is funded by a government commonwealth research scholarship. There are no declared conflicts of interest for any of the authors.

**CARE Checklist (2016) statement:** The authors have read the CARE Checklist (2016), and the manuscript was prepared and revised according to the CARE Checklist (2016).

**Open-Access:** This article is an open-access article which was selected by an in-house editor and fully peer-reviewed by external reviewers. It is distributed in accordance with the Creative Commons Attribution Non Commercial (CC BY-NC 4.0) license, which permits others to distribute, remix, adapt, build upon this work non-commercially,

**David Jin, Sonny Palmer,** Department of Medicine at St Vincent's Hospital, The University of Melbourne, Parkville 3052, Australia

**David Jin, Chien-Ying Kao, Sonny Palmer,** Department of Cardiology, St Vincent's Hospital Melbourne, Fitzroy 3065, Australia

**Jonathon Darby,** Department of Infectious Diseases, St Vincent's Hospital Melbourne, Fitzroy 3065, Australia

**Corresponding author:** David Jin, MD, Doctor, Department of Medicine at St Vincent's Hospital, The University of Melbourne, Parkville 3052, Australia. [d.jin2@unimelb.edu.au](mailto:d.jin2@unimelb.edu.au)

### Abstract

#### BACKGROUND

Non-typhoidal salmonella (NTS) is a rare, but well-established cause of myopericarditis. Presenting symptoms may be varied, however often revolve around the dual presentation of both myopericarditis and infectious diarrhoea. Given the rarity of NTS related myopericarditis, we conducted a systematic review of the literature, identifying 41 previously reported cases.

#### CASE SUMMARY

We present the case of an otherwise healthy 39-year old male, presenting with chest pain in the setting of documented *Salmonella typhimurium* infection. After further investigation with echocardiogram and laboratory blood tests, a diagnosis of NTS associated myopericarditis was made, and the patient received antibiotic treatment with an excellent clinical outcome. Overall, myopericarditis is rare in NTS. Although treatment for myopericarditis has not been well established, there are guidelines for the treatment of NTS infection. In our review, we found that the majority of NTS cases has been pericarditis (27/42, 64.3%), with an average age of 48.3 years, and 71.4% being male. The average mortality across all cases was 31%.

#### CONCLUSION

Myopericarditis is a rare, but potentially serious complication of NTS infection, associated with an increased morbidity and mortality.

**Key words:** *Salmonella typhimurium*; Pericarditis; Myocarditis; Myopericarditis; Non-typhoidal salmonella; Case report

©The Author(s) 2020. Published by Baishideng Publishing Group Inc. All rights reserved.



and license their derivative works on different terms, provided the original work is properly cited and the use is non-commercial. See: <http://creativecommons.org/licenses/by-nc/4.0/>

**Manuscript source:** Unsolicited manuscript

**Received:** June 21, 2019

**Peer-review started:** June 23, 2019

**First decision:** September 21, 2019

**Revised:** November 4, 2019

**Accepted:** November 20, 2019

**Article in press:** November 21, 2019

**Published online:** January 26, 2020

**P-Reviewer:** Kharlamov AN

**S-Editor:** Yan JP

**L-Editor:** A

**E-Editor:** Zhang YL



**Core tip:** Myopericarditis symptoms can be variable but generally presents with ischaemic sounding chest pain or pleuritic chest pain and cardiac biomarker elevation (troponin I and T). Non-typhoidal salmonella (NTS) generally presents as a non-bloody infectious diarrhoea. *Salmonella enterica* has multiple subtypes, with *Salmonella typhi* and *paratyphi* causing typhoid fever. However, there are a large number of NTS, which may include *Salmonella choleraesuis*, *enteritidis*, and *typhimurium*. Relevant investigations may consist of laboratory blood tests, electrocardiogram, echocardiography, coronary angiography, cardiac magnetic resonance imaging, cardiac biopsy, and faecal culture for *Salmonella*. *Salmonella* is a rare cause of myopericarditis; however, it should be considered when patients with symptoms of myocarditis or pericarditis present with a history of diarrhoea, abdominal pain and fever.

**Citation:** Jin D, Kao CY, Darby J, Palmer S. *Salmonella typhimurium* myopericarditis: A case report and review of literature. *World J Cardiol* 2020; 12(1): 67-75

**URL:** <https://www.wjnet.com/1949-8462/full/v12/i1/67.htm>

**DOI:** <https://dx.doi.org/10.4330/wjc.v12.i1.67>

## INTRODUCTION

Myocarditis is defined as an inflammatory disorder of the myocardium, formally diagnosed on clinical biopsy, however many cases are often diagnosed clinically<sup>[1]</sup>. Pericarditis, also inflammatory, is when the inflammation primarily involves the pericardial sac. Given their close anatomical relation, co-inflammation can occur as part of a syndrome known as myopericarditis, however, clinical manifestations are predominantly myocarditic or pericarditic<sup>[2]</sup>. The aetiology of myopericarditis is varied, ranging from infections (viral being the most common), autoinflammatory conditions, neoplasms, trauma, metabolic and idiopathic<sup>[3]</sup>. A rare, but potentially serious cause is as a sequelae of *Salmonella* infection.

Most cases of *Salmonella* myocarditis are associated with typhoid fever (*Salmonella typhi*/*paratyphi*), complicating up to 5% of all infections, and is well described in literature<sup>[4]</sup>. We conducted a systematic review of all case studies and case series published on nontyphoidal salmonella (NTS) associated pericarditis and/or myocarditis from January 1970 to March 2019. Both authors (Jin D and Kao CY) searched on PubMed and EMBASE using the search terms “*Salmonella* AND myocarditis” and “*Salmonella* AND pericarditis”. PubMed was further searched for the combined MeSH values of “Myocarditis” as well as “*Salmonella* (excluding typhi and paratyphi)”. Paediatric and non-human cases were excluded. References of articles were then further reviewed. We aim to discuss a case NTS myopericarditis, as well as reviewing the relevant literature.

## CASE PRESENTATION

### Chief complaints

We report a case of a 39-year old male, with no previous medical history, presenting with *Salmonella typhimurium* myopericarditis.

### Personal and family history

The patient initially presented to our emergency department (ED) with acute chest discomfort, on the background of a four-day history of persistent, watery diarrhoea, occurring three to four times per day. On Day 0 (four days prior to admission), he noticed diffused abdominal cramps, bloating, nausea without vomiting, and fever. There was no history of recent travel, however he had a seven-year-old daughter, who had a one-week history of the same symptoms which had resolved prior to the patient's presentation. There was no report of blood in the diarrhoea, which was beginning to decrease and form solid motions by Day 4.

However, it was during this stage (Day 4) that the patient noted central chest discomfort, described as a burning sensation, radiating to the axilla and neck, associated with diaphoresis and self-resolving shortness of breath. This was not exacerbated by exercise, however there was some relief with leaning forwards. He initially presented to his General Practitioner (GP), who organised for faecal cultures,

before referring onto ED.

### Laboratory examinations

At presentation to ED, his observations were within normal limits, with no documented fevers or tachycardia. Physical exam was unremarkable. Serial electrocardiogram (ECG, [Figure 1](#)) revealed prominent ST elevation ( $> 2$  mm in leads V2-V6,  $> 1$  mm in II/aVF), as well as ST depression in aVR. Investigations revealed a white cell count (WCC) of  $7.3 \times 10^9/L$ , C-reactive protein (CRP) of 84 mg/L, as well as a Troponin I (Abbott Architect) of 14,757 ng/L and a creatinine kinase of 594 units/L. Other blood tests such as electrolytes, creatinine and liver function tests were unremarkable.

### Imaging examinations

Chest X-ray showed mild cardiac enlargement, without signs of pulmonary oedema or pneumonia. Faeces microscopy and culture, along with blood cultures were taken, and the patient was admitted without specific antimicrobial treatment. An echocardiogram conducted the next day showed a trivial amount of pericardial fluid. There was no clinical or echocardiographic evidence of tamponade, ventricular dysfunction, or thrombus formation.

During Day 5, we were notified of a *Salmonella* species from the faecal culture organised by the GP. Treatment was commenced with 1 g of ceftriaxone daily. Later that night there was an associated, asymptomatic rise in the Troponin I from the previous nadir of 8,915 to 15,114 ng/L. Ceftriaxone was increased to 2 g daily, and the Infectious Diseases Unit were consulted. At this stage the repeat faecal culture also identified *Salmonella* species, with negative blood cultures at 48 h. Joint decision at this stage was made to change to azithromycin 500 mg daily for 5 d and to not initiate non-steroidal therapy, given that the initial presenting symptoms had fully resolved. There had been no clinical events of arterial or venous thrombus, combined with no significant echocardiography changes, therefore no anticoagulation was prescribed. After a further period of observation over 24 h, during which the troponin decreased to 11,327 ng/L, the patient was discharged home.

Post discharge, at Day 7, the initial presenting blood culture was positive for gram negative bacilli in one aerobic bottle, out of two sets, also identified as *Salmonella typhimurium*, however by this stage the patient was convalescing well at home.

---

## FINAL DIAGNOSIS

---

Myopericarditis in the setting of *Salmonella typhimurium* gastroenteritis and bacteraemia.

---

## TREATMENT

---

Two days of ceftriaxone 2 g IV daily followed by azithromycin 500 mg orally daily for 5 days.

---

## OUTCOME AND FOLLOW-UP

---

Clinical and biochemical resolution of myopericarditis and *Salmonella typhimurium* infection. Patient well with no further complaints at routine one-month follow-up.

---

## DISCUSSION

---

The presentation of NTS myopericarditis can be varied, but generally is divided into two categories, the symptoms of myopericarditis, and the diarrhoeal syndrome. Although the manifestations of myopericarditis are commonly a spectrum between myocarditis and pericarditis, there is often a predominance of one<sup>[2]</sup>. Myocarditis typically presents with chest pain, often of a varied nature, and can be impossible to differentiate on history from ischaemic chest pain. Otherwise heart failure symptoms, flu-like symptoms, fatigue, palpitations, syncope, or even sudden cardiac death may be the presenting symptom<sup>[5]</sup>. Pericarditis is associated with a pleuritic chest pain, often relieved by leaning forward, as well as fatigue, palpitations, dyspnoea, and potentially tamponade<sup>[5]</sup>. The classic exam finding is the pericardial friction rub, often described as a scratching sound best heard over the left sternal edge. Purulent

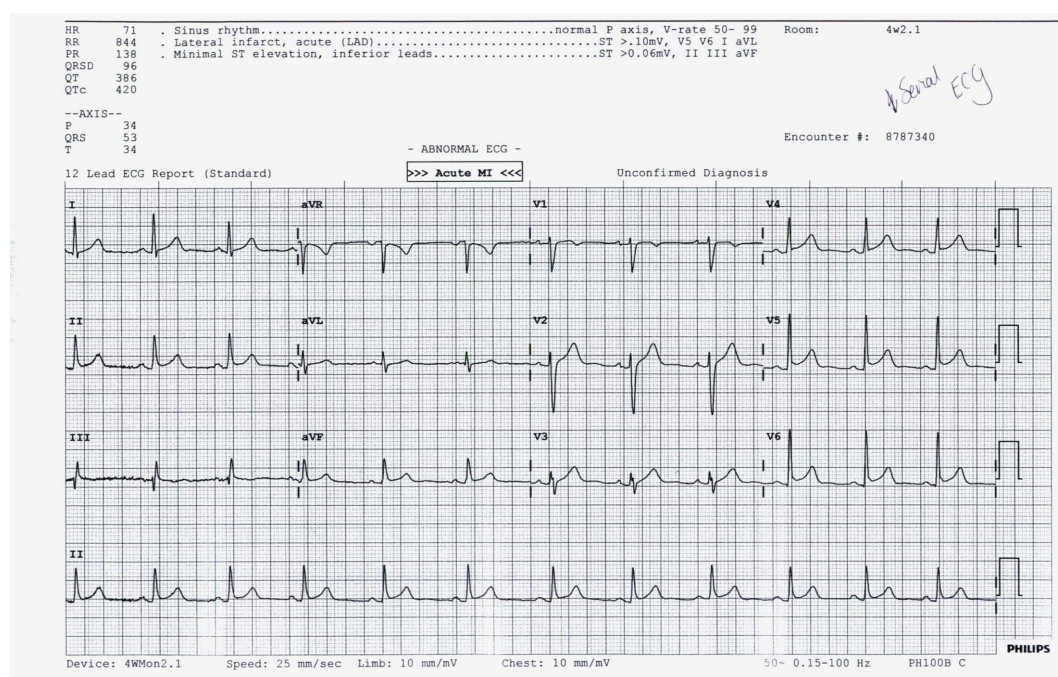


Figure 1 Electrocardiography from admission, showing diffuse ST elevation and mild ST depression in automatic voltage regulator.

pericarditis, a rare subset in the antibiotic era, should nevertheless be considered given its high morbidity and mortality. Presenting symptoms may include signs of pericarditis, especially if associated with sepsis or bacteraemia, with *Salmonella aureus* being the most commonly identified organism.

Investigations of relevance in myopericarditis include ECG, echocardiography, laboratory blood tests, biopsy, coronary angiography and cardiac magnetic resonance imaging. ECG changes are varied<sup>[6]</sup>, but typically involve diffuse ST elevation and PR depression, progressing to normalization of segments with subsequent T-wave inversion. However, given this can also manifest as focal ST elevation, combined with the fact that the pain can be ischaemic in nature, differentiation from acute coronary syndromes (ACS) is often required. This is most frequently done with interventional angiography, or more recently computed tomography coronary angiography. Aside from raised troponin, inflammatory markers such as WCC and CRP are often raised, however this has not been shown to help differentiate NTS as a cause<sup>[7]</sup>. Echocardiography is another critical area of investigation, as this can help identify ventricular dysfunction, valvular incompetence and thrombus in myocarditis<sup>[8]</sup>, as well as the extent of pericardial involvement, ranging from completely normal to cardiac tamponade in pericarditis<sup>[9]</sup>. Cardiac magnetic resonance imaging is another investigation that can be potentially used, as it can accurately assess inflammation in either the pericardium or myocardium, as well as help differentiate between ACS<sup>[10]</sup>. Definitive diagnosis of myocarditis requires endocardial biopsy, however indication revolves around whether a biopsy result would change patient management, and thus is rarely conducted in those with normal or only mildly impaired ventricular function<sup>[11]</sup>. Biopsy is most frequently performed in cases of fulminant heart failure, heart failure with rhythm disturbance, or when there is peripheral eosinophilia, suggestive of eosinophilic myocarditis.

The most recognised infection from *Salmonella* is typhoid fever, also known as enteric fever, caused by *Salmonella enterica* serotype Typhi (formerly *Salmonella typhi*), as well as *Salmonella paratyphi* (*Salmonella enterica* serotype *paratyphi*). Due to a nomenclature change, within *Salmonella* there are now two species; *bongori* and *enteric*<sup>[12]</sup>. *Salmonella enterica*, which causes the majority of infections, contains 6 subspecies, of which the most clinically relevant is *Salmonella enterica* subspecies *enterica*. These are then further divided into serovars, with the most common including: *Salmonella choleraesuis*, *Salmonella enteritidis*, and *Salmonella typhimurium*. These organisms make up the group known as NTS.

NTS often manifests within 72 h of exposure to the offending pathogen and is usually associated with faecal-oral contamination. The most common presenting symptoms by far is gastroenteritis<sup>[13]</sup>, associated with watery, non-bloody diarrhoea, abdominal cramps, nausea and vomiting, as well as fever.

In our review of the literature (Table 1), we found 42 reported cases of NTS (Table

2), with 9 myocarditis, 6 myopericarditis and 27 cases of pericarditis. Overall, we found that *Salmonella enteritidis* was the most common organism, representing 18 (42.9%) of all reported cases, with *Salmonella typhimurium* at 31.7%. Males consisted 71.4% of the cases, and the average age of patients was 48.3 years. In the case studies that we have identified, the overall mortality rate was 31%, and up to 77.8% in myocarditis cases, compared to 14.8% in pericarditis. Tamponade was the most commonly reported complication, especially in pericarditis, at 54.3%, whilst ventricular rupture was the most commonly reported complication of myocarditis. However, this is limited by both reporting and publication bias, and by the fact that most deaths and myocarditis cases occurred earlier in time, prior to modern diagnostic techniques and treatment.

The mainstay of therapy in treating the inflammation and pain associated with myopericarditis is non-steroidal anti-inflammatory drugs (NSAIDs)<sup>[6]</sup>. However when there is a predominant myocarditic component, NSAIDs are often reconsidered, as animal models show increased inflammation and mortality in viral myocarditis<sup>[14]</sup>. Corticosteroids are also potentially used, but should only be considered in cases of ongoing uncontrolled inflammation, as there is minimal data to recommend its routine use, and there is association with recurrent myocarditis<sup>[15]</sup>. Anticoagulation can be considered in specific patients, similar to the indications in non-ischaemic dilated cardiomyopathy<sup>[16]</sup>. These would be if there were new onset AF, clinical or radiographical evidence of arterial or venous thromboembolism, thrombus formation on the echocardiogram, or significant ventricular dysfunction. If treatment was indicated, evidence currently leans towards anticoagulation with warfarin or a Direct Oral Anti-Coagulant, as opposed to single-agent treatment with an antiplatelet<sup>[17]</sup>. If there are concurrent symptoms of heart failure, routine heart failure treatment should be initiated, including diuretics, angiotensin converting enzyme inhibition, and extended release beta blocker treatment. Invasive treatment is often limited to coronary angiography when differentiating from ACS, as well as pericardiocentesis in the setting of large pericardial effusions with features suggestive of developing or frank cardiac tamponade.

Lastly, it is also important to treat the underlying *Salmonella* infection, however guidelines vary secondary to local antimicrobial susceptibility patterns. After clinical rehydration, current Australian guidelines<sup>[18]</sup>, recommend treatment with intravenous therapy initially, such as ceftriaxone (2 g IV daily), or ciprofloxacin (400 mg twice-daily), before an oral tail of ciprofloxacin/azithromycin, determined by the severity of the infection.

At this stage, there is very limited high-quality data on long-term prognosis and complications in patients diagnosed with myopericarditis<sup>[3]</sup>. Nevertheless, it appears that survival rates in idiopathic and infectious myocarditis are overall quite favourable, especially the predominant pericarditis subtype<sup>[19]</sup>. The main complications are the development or non-resolution of heart failure, cardiomyopathy, arrhythmias, and sudden cardiac death, especially if there is significant myocardial scarring. Routine follow up in the acute phase with echocardiography is recommended, especially if there are clinical or radiological signs of heart failure.

## CONCLUSION

The presentation of NTS myopericarditis is varied, however it revolves around two main areas, the symptoms of myocarditis and pericarditis, as well as the infectious symptoms of diarrhoea accompanying *Salmonella* infection. Definitive diagnosis with biopsy is rarely undertaken, as this is usually a clinical diagnosis from the clinical history and examination, ECG, troponin and echocardiogram, as well as a stool culture for the NTS. There is a lack of consensus regarding the treatment of myopericarditis, however there are well established antibiotic guidelines for NTS. Although NTS is a rare cause of myopericarditis, given the severity of potential sequelae, remains a worthwhile consideration when patients present with symptoms of both infectious diarrhoea and myopericarditis.



**Table 1 Non-typhoidal salmonella pericarditis and myocarditis**

Author	Relevant medical history	Age and sex	Cardiac manifestation	Organism	Complications	Outcome
Bengtsson <i>et al</i> <sup>[20]</sup> , 1955	NA	50F	Myocarditis	<i>Salmonella typhimurium</i>	NA	Deceased
Bengtsson <i>et al</i> <sup>[20]</sup> , 1955	NA	51M	Myocarditis	<i>Salmonella typhimurium</i>	NA	Deceased
Sanders <i>et al</i> <sup>[21]</sup> , 1964	NA	62F	Myocarditis	<i>Salmonella choleraesuis</i>	Ventricular Rupture	Deceased
Shilkin <i>et al</i> <sup>[22]</sup> , 1969	SLE	61M	Myopericarditis	<i>Salmonella typhimurium</i>	Endocarditis	Deceased
Schatz <i>et al</i> <sup>[23]</sup> , 1973	NA	62M	Myopericarditis	<i>Salmonella typhimurium</i>	Tamponade	Deceased
Webster <i>et al</i> <sup>[24]</sup> , 1977	NA	19F	Myopericarditis	<i>Salmonella agona</i>	NA	Survived
Simonsen <i>et al</i> <sup>[25]</sup> , 1980	NA	24M	Myocarditis	<i>Salmonella typhimurium</i>	NA	Deceased
Götz <i>et al</i> <sup>[26]</sup> , 1983	NA	53M	Myocarditis	<i>Salmonella typhimurium</i>	NA	Deceased
Martínez-Martínez <i>et al</i> <sup>[27]</sup> , 1989	NA	60M	Myocarditis	<i>Salmonella enteritidis</i>	Mycotic aneurysms of aorta	Deceased
Burt <i>et al</i> <sup>[28]</sup> , 1990	NA	29M	Myocarditis	<i>Salmonella Heidelberg</i>	VF	Deceased
Dunbabin <i>et al</i> <sup>[29]</sup> , 1990	Chemotherapy	52F	Pericarditis	<i>Salmonella Dublin</i>	Tamponade	Deceased
Doig <i>et al</i> <sup>[30]</sup> , 1991	NA	36F	Pericarditis	<i>Salmonella enteritidis</i>	Tamponade	Survived
Clesham <i>et al</i> <sup>[31]</sup> , 1993	NA	45M	Pericarditis	<i>Salmonella enteritidis</i>	Tamponade	Survived
Li <i>et al</i> <sup>[32]</sup> , 1993	NA	22F	Pericarditis	<i>Salmonella enteritidis</i>	NA	Survived
Yang <i>et al</i> <sup>[33]</sup> , 1995	NA	54F	Pericarditis	<i>Salmonella typhimurium</i>	NA	Survived
Victor <i>et al</i> <sup>[34]</sup> , 1997	NA	71M	Pericarditis	<i>Salmonella enteritidis</i>	NA	Survived
Kiuchi <i>et al</i> <sup>[35]</sup> , 1998	ITP (prednisolone)	39M	Pericarditis	<i>Salmonella enteritidis</i>	Tamponade	Survived
Badawi <i>et al</i> <sup>[36]</sup> , 2002	NA	48M	Pericarditis	<i>Salmonella typhimurium</i>	NA	Survived
Pace <i>et al</i> <sup>[37]</sup> , 2002	NA	65M	Pericarditis	<i>Salmonella enteritidis</i>	Tamponade	Survived
Salavert <i>et al</i> <sup>[38]</sup> , 2002	NA	61M	Pericarditis	<i>Salmonella arizonae</i>	Tamponade	Survived
Candel <i>et al</i> <sup>[39]</sup> , 2003	HIV	37M	Pericarditis	<i>Salmonella Derby</i>	NA	Survived
Yoshioka <i>et al</i> <sup>[40]</sup> , 2003	NA	40M	Pericarditis	<i>Salmonella enteritidis</i>	NA	Survived
Arruvito <i>et al</i> <sup>[41]</sup> , 2004	Arthritis (steroids)	75M	Pericarditis	<i>Salmonella enterica</i>	Tamponade	Deceased
Can <i>et al</i> <sup>[42]</sup> , 2004	NA	42M	Pericarditis	<i>Salmonella typhimurium</i>	NA	Deceased
Fernández Guerrero <i>et al</i> <sup>[43]</sup> , 2004	SLE (prednisolone and azathioprine)	23F	Pericarditis	<i>Salmonella typhimurium</i>	Tamponade	Survived
Fernández Guerrero <i>et al</i> <sup>[43]</sup> , 2004	NA	66M	Myopericarditis	<i>Salmonella enteritidis</i>	NA	Survived
Hoag <i>et al</i> <sup>[44]</sup> , 2005	HIV	47F	Pericarditis	<i>Salmonella arizonae</i>	Tamponade	Survived
Górecki <i>et al</i> <sup>[45]</sup> , 2008	RA (steroids) ESRF (on HDx)	64M	Pericarditis	<i>Salmonella enteritidis</i>	Tamponade	Survived
Sahu <i>et al</i> <sup>[46]</sup> , 2008	Hodgkin's lymphoma	23M	Pericarditis	<i>Salmonella typhimurium</i>	NA	Survived
Takamiya <i>et al</i> <sup>[47]</sup> , 2008	CD4/CD8 depression (ratio = 0.81)	65M	Pericarditis	<i>Salmonella enteritidis</i>	NA	Survived
Hibbert <i>et al</i> <sup>[48]</sup> , 2010	NA	25M	Myopericarditis	<i>Salmonella enteritidis</i>	NA	Survived
Tseng <i>et al</i> <sup>[49]</sup> , 2010	ESRF	66M	Pericarditis	<i>Salmonella enterica</i>	Tamponade	Survived
Tseng <i>et al</i> <sup>[49]</sup> , 2010	ESRF	82M	Pericarditis	<i>Salmonella enteritidis</i>	Tamponade	Deceased

Ortiz et al <sup>[50]</sup> , 2014	SLE (prednisolone)	62M	Pericarditis	<i>Salmonella enteritidis</i>	Tamponade	Survived
Chand et al <sup>[51]</sup> , 2015	NA	67M	Pericarditis	<i>Salmonella enteritidis</i>	Tamponade	Survived
Zaman et al <sup>[52]</sup> , 2015	NA	67M	Myopericarditis	<i>Salmonella enteritidis</i>	Tamponade	Survived
Dawar et al <sup>[53]</sup> , 2017	NA	46F	Pericarditis	<i>Salmonella typhimurium</i>	NA	Survived
Kuo et al <sup>[54]</sup> , 2017	Adult onset Still's disease (methylprednisolone / prednisolone)	30F	Pericarditis	<i>Salmonella enteritidis</i>	Tamponade	Survived
Suzuki et al <sup>[55]</sup> , 2017	NA	31M	Pericarditis	<i>Salmonella arizonae</i>	Tamponade	Survived
Ezad et al <sup>[56]</sup> , 2018	NA	29F	Myocarditis	<i>Salmonella typhimurium</i>	NA	Survived
Sundbom et al <sup>[57]</sup> , 2018	NA	22M	Myocarditis	<i>Salmonella enteritidis</i>	NA	Survived
Saddler et al <sup>[58]</sup> , 2019	Crohn's disease (Infliximab)	57M	Pericarditis	<i>Salmonella enterica</i>	Tamponade	Survived

NA: Not applicable; SLE: Systemic lupus erythematosus; ESRF: End-stage renal failure; HIV: Human immunodeficiency virus; RA: Rheumatoid arthritis; ITP: Idiopathic thrombocytopenic purpura; M: Male; F: Female.

**Table 2 Summary of non-typhoidal salmonella ca**

Cardiac Manifestation (Cases)	Organisms (Number of cases)	Mortality
Myocarditis (9)	<i>Salmonella typhimurium</i> (5) <i>Salmonella enteritidis</i> (2) <i>Salmonella choleraesuis</i> (1) <i>Salmonella Heidelberg</i> (1)	77.8% (7/9)
Myopericarditis (6)	<i>Salmonella enteritidis</i> (3) <i>Salmonella typhimurium</i> (2) <i>Salmonella agona</i> (1)	33.3% (2/6)
Pericarditis (27)	<i>Salmonella enteritidis</i> (13) <i>Salmonella typhimurium</i> (6) <i>Salmonella arizonae</i> (3) <i>Salmonella enterica</i> (3) <i>Salmonella Derby</i> (1) <i>Salmonella Dublin</i> (1)	14.8% (4/27)
Total (42)	<i>Salmonella enteritidis</i> (18) <i>Salmonella typhimurium</i> (13) <i>Salmonella arizonae</i> (3) <i>Salmonella enterica</i> (3) <i>Salmonella agona</i> (1) <i>Salmonella choleraesuis</i> (1) <i>Salmonella Derby</i> (1) <i>Salmonella Dublin</i> (1) <i>Salmonella Heidelberg</i> (1)	31% (13/42)

## REFERENCES

- 1 **Caforio AL**, Pankuweit S, Arbustini E, Basso C, Gimeno-Blanes J, Felix SB, Fu M, Heliö T, Heymans S, Jahns R, Klingel K, Linhart A, Maisch B, McKenna W, Mogensen J, Pinto YM, Ristic A, Schultheiss HP, Seggewiss H, Tavazzi L, Thiene G, Yilmaz A, Charron P, Elliott PM; European Society of Cardiology Working Group on Myocardial and Pericardial Diseases. Current state of knowledge on aetiology, diagnosis, management, and therapy of myocarditis: a position statement of the European Society of Cardiology Working Group on Myocardial and Pericardial Diseases. *Eur Heart J* 2013; **34**: 2636-2648, 2648a-2648d [PMID: 23824828 DOI: 10.1093/eurheartj/ehd210]
- 2 **Imazio M**, Trinchero R. The spectrum of inflammatory myopericardial diseases. *Int J Cardiol* 2010; **144**: 134 [PMID: 19178962 DOI: 10.1016/j.ijcard.2008.12.118]
- 3 **Imazio M**, Trinchero R. Myopericarditis: Etiology, management, and prognosis. *Int J Cardiol* 2008; **127**: 17-26 [PMID: 18221804 DOI: 10.1016/j.ijcard.2007.10.053]

- 4 **Huang DB**, DuPont HL. Problem pathogens: extra-intestinal complications of *Salmonella enterica* serotype Typhi infection. *Lancet Infect Dis* 2005; **5**: 341-348 [PMID: [15919620](#) DOI: [10.1016/S1473-3099\(05\)70138-9](#)]
- 5 **Ammirati E**, Cipriani M, Moro C, Raineri C, Pini D, Sormani P, Mantovani R, Varrenti M, Pedrotti P, Conca C, Mafri A, Grosu A, Briguglia D, Guglielmetto S, Perego GB, Colombo S, Caico SI, Giannattasio C, Maestroni A, Carubelli V, Metra M, Lombardi C, Campodonico J, Agostoni P, Peretto G, Scelsi L, Turco A, Di Tano G, Campana C, Belloni A, Morandi F, Mortara A, Cirò A, Senni M, Gavazzi A, Frigerio M, Oliva F, Camici PG; Registro Lombardo delle Miocarditi. Clinical Presentation and Outcome in a Contemporary Cohort of Patients With Acute Myocarditis. *Circulation* 2018; **138**: 1088-1099 [PMID: [29764898](#) DOI: [10.1161/CIRCULATIONAHA.118.035319](#)]
- 6 **Imazio M**, Cecchi E, Demicheli B, Chinaglia A, Ierna S, Demarie D, Ghisio A, Pomari F, Belli R, Trincherò R. Myopericarditis versus viral or idiopathic acute pericarditis. *Heart* 2008; **94**: 498-501 [PMID: [17575329](#) DOI: [10.1136/hrt.2006.104067](#)]
- 7 **Satpathy S**, Bhuyan K, Nayak SR. *Salmonella* Myocarditis: Suspecting and Estimating the Associated Clinical Complications. *Clin Med Rev Cardiol* 2016 [DOI: [10.4137/CMRC.S38652](#)]
- 8 **Pinamonti B**, Alberti E, Cigalotto A, Dreas L, Salvi A, Silvestri F, Camerini F. Echocardiographic findings in myocarditis. *Am J Cardiol* 1988; **62**: 285-291 [PMID: [3400607](#) DOI: [10.1016/0002-9149\(88\)90226-3](#)]
- 9 **Chandraratna PA**. Echocardiography and Doppler ultrasound in the evaluation of pericardial disease. *Circulation* 1991; **84**: 1303-1310 [PMID: [1884500](#) DOI: [10.1002/ccd.1810240123](#)]
- 10 **Friedrich MG**, Sechtem U, Schulz-Menger J, Holmvang G, Alakija P, Cooper LT, White JA, Abdel-Aty H, Gutberlet M, Prasad S, Aletras A, Laissy JP, Paterson I, Filipchuk NG, Kumar A, Pauschinger M, Liu P; International Consensus Group on Cardiovascular Magnetic Resonance in Myocarditis. Cardiovascular magnetic resonance in myocarditis: A JACC White Paper. *J Am Coll Cardiol* 2009; **53**: 1475-1487 [PMID: [19389557](#) DOI: [10.1016/j.jacc.2009.02.007](#)]
- 11 **Yancy CW**, Jessup M, Bozkurt B, Butler J, Casey DE, Drazner MH, Fonarow GC, Geraci SA, Horwich T, Januzzi JL, Johnson MR, Kasper EK, Levy WC, Masoudi FA, McBride PE, McMurray JJ, Mitchell JE, Peterson PN, Riegel B, Sam F, Stevenson LW, Tang WH, Tsai EJ, Wilkoff BL. 2013 ACCF/AHA guideline for the management of heart failure: executive summary: a report of the American College of Cardiology Foundation/American Heart Association Task Force on practice guidelines. *Circulation* 2013; **128**: 1810-1852 [PMID: [23741057](#) DOI: [10.1161/CIR.0b013e31829e8807](#)]
- 12 **Tindall BJ**, Grimont PA, Garrity GM, Euzéby JP. Nomenclature and taxonomy of the genus *Salmonella*. *Int J Syst Evol Microbiol* 2005; **55**: 521-524 [PMID: [15653930](#) DOI: [10.1099/ijs.0.63580-0](#)]
- 13 **Saphra I**, WINTER JW. Clinical manifestations of salmonellosis in man; an evaluation of 7779 human infections identified at the New York Salmonella Center. *N Engl J Med* 1957; **256**: 1128-1134 [PMID: [13452006](#) DOI: [10.1056/NEJM195706132562402](#)]
- 14 **Costanzo-Nordin MR**, Reap EA, O'Connell JB, Robinson JA, Scanlon PJ. A nonsteroid anti-inflammatory drug exacerbates Cocksackie B3 murine myocarditis. *J Am Coll Cardiol* 1985; **6**: 1078-1082 [PMID: [2995470](#) DOI: [10.1016/S0735-1097\(85\)80312-0](#)]
- 15 **Chen HS**, Wang W, Wu SN, Liu JP. Corticosteroids for viral myocarditis. *Cochrane Database Syst Rev* 2013; CD004471 [PMID: [24136037](#) DOI: [10.1002/14651858.CD004471.pub3](#)]
- 16 **Schultz JC**, Hilliard AA, Cooper LT, Rihal CS. Diagnosis and treatment of viral myocarditis. *Mayo Clin Proc* 2009; **84**: 1001-1009 [PMID: [19880690](#) DOI: [10.1016/S0025-6196\(11\)60670-8](#)]
- 17 **Carazo M**, Berger JS, Reyentovich A, Katz SD. Role of Antiplatelet Therapy and Anticoagulation in Nonischemic Cardiomyopathy. *Cardiol Rev* 2016; **24**: 211-217 [PMID: [26501990](#) DOI: [10.1097/CRD.0000000000000094](#)]
- 18 **Acute infectious diarrhoea**. Therapeutic Guidelines Ltd [Internet]. 2019 [cited April 29, 2019]. Available from: <https://tgldcdp.tg.org.au/searchAction?appendedInputButtons=Acute%20infectious%20diarrhoea>
- 19 **Imazio M**, Brucato A, Barbieri A, Ferroni F, Maestroni S, Ligabue G, Chinaglia A, Cumetti D, Della Casa G, Bonomi F, Mantovani F, Di Corato P, Lugli R, Faletti R, Leuzzi S, Bonamini R, Modena MG, Belli R. Good prognosis for pericarditis with and without myocardial involvement: results from a multicenter, prospective cohort study. *Circulation* 2013; **128**: 42-49 [PMID: [23709669](#) DOI: [10.1161/CIRCULATIONAHA.113.001531](#)]
- 20 **Bengtsson E**, Hedlund P, Nisell A, Nordenstam H. An epidemic due to *Salmonella typhimurium* (Breslau) occurring in Sweden in 1953; with special reference to clinical complications, bacteriology, serology, antibiotic treatment, and morbid anatomy. *Acta Med Scand* 1955; **153**: 1-20 [PMID: [13292172](#)]
- 21 **Sanders V**, Misanik LF. *Salmonella* myocarditis. report of a case with ventricular rupture. *Am Heart J* 1964; **68**: 682-685 [PMID: [14222407](#) DOI: [10.1016/0002-8703\(64\)90278-9](#)]
- 22 **Shilkin KB**. *Salmonella typhimurium* pancarditis. *Postgrad Med J* 1969; **45**: 40-43 [PMID: [4892937](#) DOI: [10.1136/pgmj.45.519.40](#)]
- 23 **Schatz JW**, Wiener L, Gallagher HS, Eberly RJ. *Salmonella* pericarditis: an unusual complication of myocardial infarction. *Chest* 1973; **64**: 267-269 [PMID: [4579706](#) DOI: [10.1378/chest.64.2.267](#)]
- 24 **Webster J**, Petersen J, Edward N. Cardiac tamponade and acute renal failure following *Salmonella agona* pericarditis. *Postgrad Med J* 1977; **53**: 265-266 [PMID: [876935](#) DOI: [10.1136/pgmj.53.619.265](#)]
- 25 **Simonsen J**, Falk E. A case of sudden cardiac death in connection with *Salmonella typhimurium* infection. *Forensic Sci Int* 1980; **16**: 283-287 [PMID: [7009351](#) DOI: [10.1016/0379-0738\(80\)90214-5](#)]
- 26 **Götz M**, Juchems R. [Myocarditis caused by *Salmonella typhimurium*]. *Klin Wochenschr* 1983; **61**: 1153-1157 [PMID: [6228687](#) DOI: [10.1007/BF01530844](#)]
- 27 **Martínez-Martínez L**, Mesa E, Rodríguez JE, Sánchez MP, Ugarte J, Algorta Weber A, Dámaso D, Daza RM, Mendaza P. [Bacteremia associated with mycotic aneurysm of the transversal aortic arch and myocarditis caused by *Salmonella enteritidis*]. *Enferm Infecc Microbiol Clin* 1989; **7**: 97-99 [PMID: [2490676](#)]
- 28 **Burt CR**, Proudfoot JC, Roberts M, Horowitz RH. Fatal myocarditis secondary to *Salmonella* septicemia in a young adult. *J Emerg Med* 1990; **8**: 295-297 [PMID: [2373838](#) DOI: [10.1016/0736-4679\(90\)90009-K](#)]
- 29 **Dunbabin DW**. Pericarditis due to *Salmonella dublin*. *Postgrad Med J* 1990; **66**: 252-253 [PMID: [2362900](#) DOI: [10.1136/pgmj.66.773.252-a](#)]
- 30 **Doig JC**, Hilton CJ, Reid DS. *Salmonella*: a rare cause of subacute effusive-constrictive pericarditis. *Br Heart J* 1991; **65**: 296-297 [PMID: [2039677](#) DOI: [10.1136/hrt.65.5.296](#)]
- 31 **Clesham GJ**, Davies GJ. Bacterial pericarditis caused by *Salmonella enteritidis* phage type 1. *Int J Cardiol* 1993; **41**: 241-243 [PMID: [8288415](#) DOI: [10.1016/0167-5273\(93\)90122-W](#)]

- 32 **Li EK**, Cohen MG, Ho AK, Cheng AF. Salmonella bacteraemia occurring concurrently with the first presentation of systemic lupus erythematosus. *Br J Rheumatol* 1993; **32**: 66-67 [PMID: [8422563](#) DOI: [10.1093/rheumatology/32.1.66](#)]
- 33 **Yang CH**, Chen KJ, Tseng HH, Yang CJ, Liu JD. Salmonella pericarditis and empyema: a case report. *Zhonghua Yi Xue Za Zhi (Taipei)* 1995; **56**: 199-204 [PMID: [8854443](#)]
- 34 **Victor F**, Gras D, Le Breton H, Gras S, Amelot J, Pony JC. [Salmonella enteritidis pericarditis. Apropos of a case and review of the literature]. *Arch Mal Coeur Vaiss* 1997; **90**: 301-303 [PMID: [9181041](#)]
- 35 **Kiuchi K**, Endo T, Nejima J, Okamatsu K, Takayama M, Takano T, Hayakawa H. Purulent pericarditis with tamponade caused by Salmonella enteritidis. *Jpn Circ J* 1998; **62**: 139-141 [PMID: [9559435](#) DOI: [10.1253/jcj.62.139](#)]
- 36 **Badawi R**, Nageh T, Walker D, Wray R. Nontyphoidal salmonella pericarditis: a case of Salmonella typhimurium phage type 2 pericarditis. *Int J Cardiol* 2002; **82**: 187-189 [PMID: [11853909](#) DOI: [10.1016/S0167-5273\(01\)00617-9](#)]
- 37 **Pace F**, Fanfarillo F, Giorgino F, Baratta L. Salmonella enteritidis pericarditis: case report and review of the literature. *Ann Ital Med Int* 2002; **17**: 189-192 [PMID: [12402668](#)]
- 38 **Salavert M**, Navarro V, Roig P. [Purulent pericarditis due to Salmonella enterica subsp. arizonae]. *Enferm Infecc Microbiol Clin* 2002; **20**: 47-49 [PMID: [11820989](#) DOI: [10.1016/S0213-005X\(02\)72738-9](#)]
- 39 **Candel FJ**, Roca-Arbonés V, Núñez MJ, Arroyo C, Valdivia A, Téllez MJ, Picazo JJ. A rare cause of pericarditis. *Clin Microbiol Infect* 2003; **9**: 1261-1263 [PMID: [14687001](#) DOI: [10.1111/j.1469-0691.2003.00802.x](#)]
- 40 **Yoshioka H**, Shigemitsu K, Takeuchi M, Mori S, Imaizumi M, Ueda Y. Salmonella pericarditis in a patient with primary idiopathic chylopericardium. *Jpn J Thorac Cardiovasc Surg* 2003; **51**: 16-17 [PMID: [12645149](#) DOI: [10.1007/s11748-003-0059-7](#)]
- 41 **Arruvito L**, Ber MG, Martínez Martínez JA. Purulent pericarditis with pericardial tamponade caused by Streptococcus agalactiae and Salmonella enterica no typhi. *Medicina (B Aires)* 2004; **64**: 340-342 [PMID: [15338978](#)]
- 42 **Can F**, Demirbilek M, Erdem B, Ciftci U, Tunaoglu M, Laleli Y. A purulent pericarditis caused by Salmonella typhimurium. *J Med Microbiol* 2004; **53**: 1051-1052 [PMID: [15358830](#) DOI: [10.1099/jmm.0.05449-0](#)]
- 43 **Fernández Guerrero ML**, Aguado JM, Arribas A, Lumbreras C, de Gorgolas M. The spectrum of cardiovascular infections due to Salmonella enterica: a review of clinical features and factors determining outcome. *Medicine (Baltimore)* 2004; **83**: 123-138 [PMID: [15028966](#) DOI: [10.1097/01.md.0000125652.75260.cf](#)]
- 44 **Hoag JB**, Sessler CN. A comprehensive review of disseminated Salmonella arizona infection with an illustrative case presentation. *South Med J* 2005; **98**: 1123-1129 [PMID: [16351033](#) DOI: [10.1097/01.smj.0000177346.07719.00](#)]
- 45 **Górecki B**, Flasiński J, Górski J. [Patient with purulent pericarditis caused by Salmonella enteritidis complicated by tamponade]. *Kardiologia* 2008; **66**: 664-7; discussion 667-8 [PMID: [18626836](#)]
- 46 **Sahu M**, Sujatha S, Dr C, Parija SC. Pericardial effusion - an unusual manifestation of salmonellosis: a case report. *Cases J* 2008; **1**: 375 [PMID: [19061513](#) DOI: [10.1186/1757-1626-1-375](#)]
- 47 **Takamiya Y**, Shirai K, Fujino M, Miller N, Tsuchiya Y, Okabe M, Saku K. Purulent pericarditis with Salmonella enteritidis in a patient with CD4/CD8 depression. *J Cardiol* 2008; **51**: 201-204 [PMID: [18522796](#) DOI: [10.1016/j.jjcc.2007.12.004](#)]
- 48 **Hibbert B**, Costiniuk C, Hibbert R, Joseph P, Alanazi H, Simard T, Dennie C, Angel JB, O'Brien ER. Cardiovascular complications of Salmonella enteritidis infection. *Can J Cardiol* 2010; **26**: 323-325 [PMID: [20931102](#) DOI: [10.1016/S0828-282X\(10\)70444-X](#)]
- 49 **Tseng JR**, Lee MJ, Lin JL, Yen TH. Definite and probable septic pericarditis in hemodialysis. *Ren Fail* 2010; **32**: 1177-1182 [PMID: [20954978](#) DOI: [10.3109/0886022X.2010.516858](#)]
- 50 **Ortiz D**, Siegal EM, Kramer C, Khandheria BK, Brauer E. Nontyphoidal cardiac salmonellosis: two case reports and a review of the literature. *Tex Heart Inst J* 2014; **41**: 401-406 [PMID: [25120393](#) DOI: [10.14503/THIJ-13-3722](#)]
- 51 **Chand G**, Jhaj R, Sanam K, Sinha P, Alexander P. Pericardial salmonella with cardiac tamponade and ventricular wall rupture: A case report. *Ann Med Surg (Lond)* 2016; **7**: 83-86 [PMID: [27141304](#) DOI: [10.1016/j.amsu.2016.03.024](#)]
- 52 **Zaman T**, Vinayak A, Sonti R. Salmonella Enteritidis Myopericarditis Progressing to Cardiac Tamponade. *Chest* 2015; **148**: 266A [DOI: [10.1378/chest.2243595](#)]
- 53 **Dawar R**, Ganjoo A, Imdadi F, Bhandari V. Multidrug Resistant Invasive Nontyphoidal Salmonella Isolated from and Masquerading Healed Tubercular Constrictive Pericarditis and Study of Virulence Markers. *Cureus* 2017; **9**: e1198 [PMID: [28560124](#) DOI: [10.7759/cureus.1198](#)]
- 54 **Kuo CC**, Yu WL, Lee CH, Wu NC. Purulent constrictive pericarditis caused by Salmonella enteritidis in a patient with adult-onset Still's disease: A case report. *Medicine (Baltimore)* 2017; **96**: e8949 [PMID: [29390286](#) DOI: [10.1097/MD.00000000000008949](#)]
- 55 **Suzuki A**, Tanaka T, Ohba K, Ito N, Sakai Y, Kaneko A, Machii M, Nonaka D, Goto Y, Takase H. Purulent Pericarditis with Salmonella enterica Subspecies arizona in a Patient with Type 2 Diabetes Mellitus. *Intern Med* 2017; **56**: 2171-2174 [PMID: [28781305](#) DOI: [10.2169/internalmedicine.8293-16](#)]
- 56 **Ezad S**, McGee M, Murch S. A Case of Salmonella typhimurium Myocarditis Confirmed on Cardiac Magnetic Resonance Imaging. *Heart Lung Circ* 2018; **27**: S207 [DOI: [10.1016/j.hlc.2018.06.371](#)]
- 57 **Sundbom P**, Suutari AM, Abdulhadi K, Broda W, Csegedi M. Salmonella enteritidis causing myocarditis in a previously healthy 22-year-old male. *Oxf Med Case Reports* 2018; **2018**: omy106 [PMID: [30487991](#) DOI: [10.1093/omcr/omy106](#)]
- 58 **Saddler K**, Castro-Lainez MT, Deliz-Aguirre R, Muñoz J, Aguilar Espinal JA, Sierra-Hoffman M, Chandna H, Howel A, Midturi J, Winn R. Nontyphoidal Salmonella purulent pericarditis presenting with pericardial tamponade in a patient on infliximab therapy. *IDCases* 2019; **15**: e00500 [PMID: [30788216](#) DOI: [10.1016/j.idcr.2019.e00500](#)]





Published By Baishideng Publishing Group Inc  
7041 Koll Center Parkway, Suite 160, Pleasanton, CA 94566, USA  
Telephone: +1-925-2238242  
E-mail: [bpgoffice@wjgnet.com](mailto:bpgoffice@wjgnet.com)  
Help Desk: <https://www.f6publishing.com/helpdesk>  
<https://www.wjgnet.com>

