



All

Images

Videos

翻译成中文

关闭取词

15,400 Results

Any time ▾

Coexistence of Neurofibromatosis Type-1 and Primary ...

https://www.researchgate.net/publication/284486619_Coexistence_of_Neurofibromatosis...

PDF | On Dec 19, 2014, Yang Liang Boo and others published Coexistence of Neurofibromatosis Type-1 and Primary Pulmonary Sarcoma: A Case Report and Review of the Literature

[PDF] Neurofibroma of Spindle Cell Origin, a Diagnostic ...

www.iosrjournals.org/iosr-jdms/papers/Vol13-issue10/Version-1/G0131012729.pdf

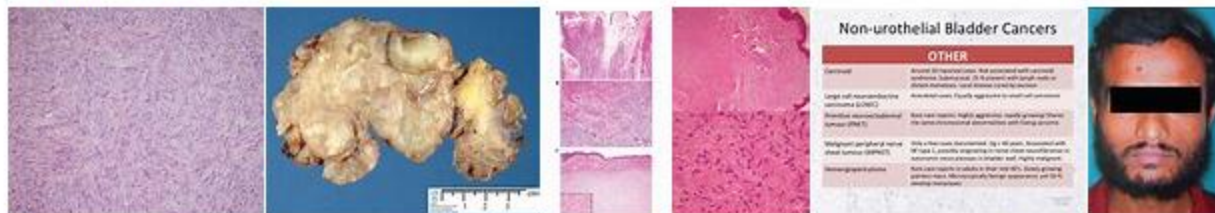
Neurofibroma of Spindle Cell Origin, a Diagnostic Dilemma to General Dentist. ... Key Words: Neurofibroma, Spindle cell, Tumor I. Introduction Case presentation: The patient reported a slow growing lesion in lower left mandibular region extending from canine to 2nd molar region. A 22-year-old man presented to the department of the Oral and ...

Published in: IOSR Journal of Dental and Medical Sciences - 2014

Authors: Swapnil Moghe · Moni Gupta · Mrinal Sathpathy · Ajay Pillai · Saksham Nahar

Images of I-type neurofibromatosis with spindle cell sarcom...

bing.com/images



See more images of I-type neurofibromatosis with spindle cell sarcoma : a case report

[PDF] SPINDLE-CELL SARCOMA OF THE THIGH: A CASE REPORT

cancerres.aacrjournals.org/content/amjcancer/16/2/419.full.pdf

SPINDLE-CELL SARCOMA OF THE THIGH: A CASE REPORT SAMUEL W. VERNICK, M.D. Assistant Visiting Physician, City Hospital, New York AND JAMES R. LISA, M.D. Pathologist, City Hospital, New York The following case of highly malignant, large spindle-cell

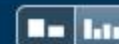Published in: American Journal of Cancer - 1932

Authors: Samuel W Vernick · James R Lisa

(PDF) Synovial Cell Sarcoma of the Kidney: A Case Report ...

https://www.researchgate.net/publication/321443772_Synovial_Cell_Sarcoma_of_the_Kidney...

Match Overview



1	Crossref 71 words Ahmed Abdel Khalek Abdel Razek. "MR imaging of neoplastic and non-neoplastic lesions of the brain and spine in ne	3%
2	Crossref 45 words Márcia Gaiger Oliveira. "NF1 diagnosis criteria and associated sarcomatous tumor review of the literature and case re	2%
3	Crossref 29 words Ahmed Abdel Khalek Abdel Razek, Germeen Albair Ashmalia. "Assessment of paraspinal neurogenic tumors with di	1%
4	Internet 20 words crawled on 08-Jul-2019 www.wjgnet.com	1%
5	Crossref 18 words Esra Kalkan, Steven G. Waguespack. "Endocrine Tumors Associated with Neurofibromatosis Type 1, Peutz-Jeghers	1%
6	Crossref 15 words Afşar, Çiğdem Usul, İsmail Oğuz Kara, Banu Kara Kozat, Haluk Demiryürek, Bema Bozkurt Duman, and Figen Doran.	1%

Type I neurofibromatosis with spindle cell sarcoma: A case report

Yu Zhang, Jiao-Jiao Chao, Xiu-Feng Liu, Shu-Kui Qing

Abstract

BACKGROUND

Neurofibromatosis type I is the most frequent subtype of neurofibromatosis. It is ¹related tumor-suppressor syndromes characterized by a predisposition to multiple tumor types and other disorder presentations, what's more, its incidence of tumors is much higher than normal people. However, the reports on it are very few at home and abroad, then we present a case of Neurofibromatosis type I with spindle cell sarcoma.

CASE SUMMARY

A 50-year-old male was found a right axillary mass for 20 years. Specialist examination: coffee milk spots can be seen in many parts of the skin, rounded nodules in the skin; bulge in the right armpit, touching a lump (10 cm × 6 cm), hard, unclear boundary, poor mobility, local tenderness; right The anterior side of the thigh feels weakened on the opposite side; the right groin can touch a swollen lymph node, hard, clear border, good mobility, local tenderness. According to the results of PET/CT, Puncture pathology and immunohistochemistry, Genetic testing, Neurofibromatosis type I with spindle cell sarcoma was confirmed. According to the Genetic testing result, the patient was given a targeted treatment with crizotinib.

CONCLUSION

Surgery, chemotherapy and radiotherapy are the main treatment methods of Neurofibromatosis type I. However, with the continuous progress of molecular biology research, molecular targeted therapy may bring benefits for patients.

Type I neurofibromatosis with spindle cell sarcoma: A case report



All

Images

Videos

翻译成中文

关闭取词

Add Bi

66,800 Results

Any time ▾

Neurofibromatosis type I (von Recklinghausen's disease): A ...

<https://www.ncbi.nlm.nih.gov/pmc/articles/PMC3491339>

The term **neurofibromatosis** (NF) is used for a group of genetic disorders that primarily affect the cell growth of neural tissues. **Neurofibromatosis type 1** (NF1), also known as von Recklinghausen's disease, is the most common **type** of NF, and accounts for about 90% of all cases.

Spindle Cell Sarcoma of Thyroid: A Case Report

<https://www.ncbi.nlm.nih.gov/pmc/articles/PMC4354824>

Spindle cell sarcoma of thyroid represents a rare entity that may arise primarily from thyroid gland as a variant of thyroid cancer or as metastatic. We **report a case** of 60 year old man who presented with 2 months history of rapidly growing thyroid enlargement with no obstructive features and ...

Cited by: 2

Author: A. K. Abdul Siyad, Praveen Gopi, N. P. J...

Publish Year: 2014

Metaplastic spindle cell carcinoma of the breast in a ...

<https://onlinelibrary.wiley.com/doi/full/10.1111/tbj.12957>

We **report a unique case** of a 67-year-old woman with **neurofibromatosis type 1**, who was also diagnosed with **metaplastic** spindle cell carcinoma of the left breast. She had many **neurofibromatosis** lesions on her body, as well as the mass in the left breast.

Cited by: 2

Author: Han Shin Lee, Eun Jung Jung, Ju Yeon Ki...

Publish Year: 2018

Left atrial spindle cell sarcoma: a case report | European ...

<https://academic.oup.com/ehjcr/article/3/1/ytz005/5308399> ▾

Feb 06, 2019 · This **case report** describes a case of cardiac **spindle cell sarcoma** diagnosed after surgery, where the initial diagnostic possibilities included an intramural thrombus and a cardiac myxoma. A 57-year-old woman was referred to our hospital for evaluation of ...

Author: Natalia J Braams, Selma E Kaffka Ge...

Publish Year: 2019

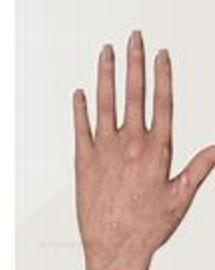Images of type I Neurofibromatosis with Spindle Cell Sarcom...

<bing.com/images>

Neurofibr

Medical Condition

Genetic disorder of the



A disorder of the
development of ne

Rare (Fewer
year in US)

Requires lab

Treatments c
no known cu

Can last sev

Tumors can form
system including
nerves. It is caus
that are either inh
spontaneously. D
symptoms includ
freckles on the ar
loss, loss of visio
It cannot be cured
control it and mal

Symptoms