

# World Journal of *Radiology*

*World J Radiol* 2019 August 28; 11(8): 110-115



**CASE REPORT**

- 110** Duodenal variceal bleeding with large SPSS treated with transjugular intrahepatic portosystemic shunt and embolization: A case report

*Anand R, Ali SE, Raissi D, Frandah WM*

**ABOUT COVER**

Editorial Board Member of *World Journal of Radiology*, Giovanni Storto, MD, Chief Doctor, Research Scientist, Teacher, Department Nuclear Medicine, IRCCS CROB, Regional Cancer Hospital, Rionero 85028, Italy

**AIMS AND SCOPE**

The primary aim of *World Journal of Radiology* (*WJR*, *World J Radiol*) is to provide scholars and readers from various fields of radiology with a platform to publish high-quality basic and clinical research articles and communicate their research findings online.

*WJR* mainly publishes articles reporting research results and findings obtained in the field of radiology and covering a wide range of topics including state of the art information on cardiopulmonary imaging, gastrointestinal imaging, genitourinary imaging, musculoskeletal imaging, neuroradiology/head and neck imaging, nuclear medicine and molecular imaging, pediatric imaging, vascular and interventional radiology, and women's imaging.

**INDEXING/ABSTRACTING**

The *WJR* is now abstracted and indexed in Emerging Sources Citation Index (Web of Science), PubMed, PubMed Central, China National Knowledge Infrastructure (CNKI), China Science and Technology Journal Database (CSTJ), and Superstar Journals Database.

**RESPONSIBLE EDITORS FOR THIS ISSUE**

Responsible Electronic Editor: *Bao-Xia Zhou*

Proofing Production Department Director: *Yun-Xiao Jian Wu*

**NAME OF JOURNAL**

*World Journal of Radiology*

**ISSN**

ISSN 1949-8470 (online)

**LAUNCH DATE**

January 31, 2009

**FREQUENCY**

Monthly

**EDITORS-IN-CHIEF**

Venkatesh Mani

**EDITORIAL BOARD MEMBERS**

<https://www.wjgnet.com/1949-8470/editorialboard.htm>

**EDITORIAL OFFICE**

Ruo-Yu Ma, Director

**PUBLICATION DATE**

August 28, 2019

**COPYRIGHT**

© 2019 Baishideng Publishing Group Inc

**INSTRUCTIONS TO AUTHORS**

<https://www.wjgnet.com/bpg/gerinfo/204>

**GUIDELINES FOR ETHICS DOCUMENTS**

<https://www.wjgnet.com/bpg/GerInfo/287>

**GUIDELINES FOR NON-NATIVE SPEAKERS OF ENGLISH**

<https://www.wjgnet.com/bpg/gerinfo/240>

**PUBLICATION MISCONDUCT**

<https://www.wjgnet.com/bpg/gerinfo/208>

**ARTICLE PROCESSING CHARGE**

<https://www.wjgnet.com/bpg/gerinfo/242>

**STEPS FOR SUBMITTING MANUSCRIPTS**

<https://www.wjgnet.com/bpg/GerInfo/239>

**ONLINE SUBMISSION**

<https://www.f6publishing.com>

## Duodenal variceal bleeding with large SPSS treated with transjugular intrahepatic portosystemic shunt and embolization: A case report

Rohit Anand, Saad Emhmed Ali, Driss Raissi, Wesam M Frandah

**ORCID number:** Rohit Anand (0000-0002-6587-2825); Saad Emhmed Ali (0000-0002-3481-0365); Driss Raissi (0000-0002-6751-2997); Wesam M Frandah (0000-0001-8068-7030).

**Author contributions:** Emhmed Ali S, Anand R, Raissi D and Frandah WM designed the paper. Emhmed Ali S, Anand R, Raissi D and Frandah WM wrote the paper. All authors contributed equally to this paper. An author may list more than one contribution, and more than one author may have contributed to the same aspect.

**Informed consent statement:** Informed consent was obtained from the patient.

**Conflict-of-interest statement:** No conflict of interest declared.

**CARE Checklist (2016) statement:** The authors have read the CARE Checklist (2016), and the manuscript was revised according to the CARE Checklist (2016).

**Open-Access:** This article is an open-access article which was selected by an in-house editor and fully peer-reviewed by external reviewers. It is distributed in accordance with the Creative Commons Attribution Non Commercial (CC BY-NC 4.0) license, which permits others to distribute, remix, adapt, build upon this work non-commercially, and license their derivative works on different terms, provided the original work is properly cited and the use is non-commercial. See: <http://creativecommons.org/licenses/by-nc/4.0/>

**Rohit Anand, Saad Emhmed Ali,** Department of Internal Medicine, University of Kentucky, Lexington, KY 40536, United States

**Driss Raissi, Wesam M Frandah,** Department of Interventional Radiology, University of Kentucky, Lexington, KY 40536, United States

**Corresponding author:** Saad Emhmed Ali, FACP, MD, Assistant Professor, Department of Internal Medicine, University of Kentucky, 800 Rose St, Lexington, KY 40536, United States. [saad.ali@uky.edu](mailto:saad.ali@uky.edu)

**Telephone:** +1-859-2184991

**Fax:** +1-859-2283352

### Abstract

#### BACKGROUND

Duodenal variceal bleeding is a rare cause of gastrointestinal bleeding. The most common site is the duodenal bulb. It is usually detected endoscopically but it can be very challenging to diagnose if it is located distal to the second part of duodenum. The pre- transjugular intrahepatic portosystemic shunt (TIPS) presence of SPSS was found to be associated with an increased risk of early morbidity and mortality after TIPS placement.

#### CASE SUMMARY

A 43-year-old cirrhotic male presented with melena for three days. Upper endoscopy was performed and showed active blood oozing from the distal duodenum concerning for ectopic duodenal varix. A computed tomography (CT) angiogram was performed and showed an enlarged cluster of venous collaterals around the distal duodenum. He underwent TIPS placement. He had another episode of melena three days later. Push enteroscopy with injection sclerotherapy into the duodenal varices was performed with no success. A repeat CT angiogram showed occluded TIPS shunt. Therefore, a TIPS revision was performed and there was an extensive portal venous thrombosis with a large shunt between the inferior mesenteric vein and left renal vein *via* the left gonadal vein. Thrombectomy and TIPS shunt balloon angioplasty was performed, followed by embolization of the portosystemic. The melena was resolved, and patient was discharged with arranged hepatology follow up.

#### CONCLUSION

It important to look and embolize the SPSS shunts in patients with early TIPS dysfunction and recurrent duodenal variceal bleeding.

**Manuscript source:** Unsolicited manuscript

**Received:** July 13, 2019

**Peer-review started:** July 26, 2019

**First decision:** August 2, 2019

**Revised:** August 14, 2019

**Accepted:** August 18, 2019

**Article in press:** August 19, 2019

**Published online:** August 28, 2019

**P-Reviewer:** Garbuzenko DV, Tarantino G

**S-Editor:** Ma RY

**L-Editor:** A

**E-Editor:** Zhou BX



**Key words:** Portosystemic shunt; Gastrointestinal hemorrhage; Liver cirrhosis; Duodenum; Endoscopy; Angioplasty; Case report

©The Author(s) 2019. Published by Baishideng Publishing Group Inc. All rights reserved.

**Core tip:** Portal hypertension leads to the formation of varices, which can be present at the gastroesophageal region or ectopic locations. Bleeding ectopic varices are challenging to manage, and in many cases, transjugular intrahepatic portosystemic shunt (TIPS) is a safe and effective therapy. The pre-TIPS presence of SPSS was found to be associated with an increased risk of early morbidity and mortality after TIPS placement. We have successfully treated a patient with duodenal variceal bleeding with TIPS and embolization of SPSS after he failed TIPS monotherapy.

**Citation:** Anand R, Ali SE, Raissi D, Frandah WM. Duodenal variceal bleeding with large SPSS treated with transjugular intrahepatic portosystemic shunt and embolization: A case report. *World J Radiol* 2019; 11(8): 110-115

**URL:** <https://www.wjgnet.com/1949-8470/full/v11/i8/110.htm>

**DOI:** <https://dx.doi.org/10.4329/wjr.v11.i8.110>

## INTRODUCTION

Duodenal variceal bleeding is a rare cause of gastrointestinal bleeding. It can be life-threatening with a mortality rate of up to 40%<sup>[1]</sup>. Portal hypertension due to liver cirrhosis is the most common cause of portosystemic shunts and duodenal varices<sup>[2]</sup>. The most common site is at the duodenal bulb, and it is usually detected endoscopically<sup>[3]</sup>. However, it can be difficult to diagnose if it is located distal to the second part of duodenum. The pre-transjugular intrahepatic portosystemic shunt (TIPS) presence of SPSS was found to be associated with an increased risk of early morbidity and mortality after TIPS placement<sup>[4]</sup>. We have successfully treated a patient with duodenal variceal bleeding with TIPS and embolization of SPSS after he failed TIPS monotherapy.

## CASE PRESENTATION

### Chief complaints

A 43-year-old male presented to the emergency department complaining of melena for three days.

### History of present illness

He had two loose bowel movements with black tarry stool every day for the last three days with lightheadedness.

### History of past illness

He denies any hematemesis, abdominal pain, or similar episodes in the past.

### Personal and family history

Past medical history was remarkable for liver cirrhosis due to untreated hepatitis C and alcohol abuse. Family history was unremarkable.

### Physical examination upon admission

On presentation, vitals revealed a blood pressure of 100/60 mmHg; pulse rate of 110 per minute, temperature of 98.5 Fahrenheit, and respiratory rate of 18 per minute. Physical exam revealed an ill-looking patient with mild confusion, pale conjunctiva, non-icterus sclera, mildly distended abdomen with no tenderness, and trace pitting edema in both legs.

### Laboratory examinations

Laboratory findings displayed hemoglobin of 6.8 g/dL, leukocytes 10000/mm<sup>3</sup>, and platelet 105000/mm<sup>3</sup>. Serum biochemistry revealed creatinine 0.6 mg/dL, blood urea nitrogen 16 mg/dL, albumin 2.4 g/dL, total protein 4.8 g/dL, aspartate

aminotransferase 34 IU/L, alanine aminotransferase 60 IU/L, alkaline phosphatase 95 IU/L, international normalized ratio 1.1 and total bilirubin 1.5 mg/dL.

## FINAL DIAGNOSIS

Duodenal variceal bleeding with large SPSS.

## TREATMENT

Emergency esophagogastroduodenoscopy (EGD) was performed on the day of admission and showed grade B esophagitis and small esophageal varices with no active bleeding.

## OUTCOME AND FOLLOW-UP

He continued to have melena, and drop in hemoglobin concentration over the next 48 h. So, repeat EGD was performed and showed oozing of fresh blood in the distal duodenum, concerning for a bleeding ectopic duodenal varix. A computed tomography (CT) angiogram was performed and showed an enlarged cluster of venous collaterals around the distal duodenum. He underwent TIPS *via* using VIATORR® 10 mm × 6 cm stent-graft, which decreased the portosystemic gradient from 21 mmHg to 5 mmHg with complete decompression of the intestinal varices (Figure 1).

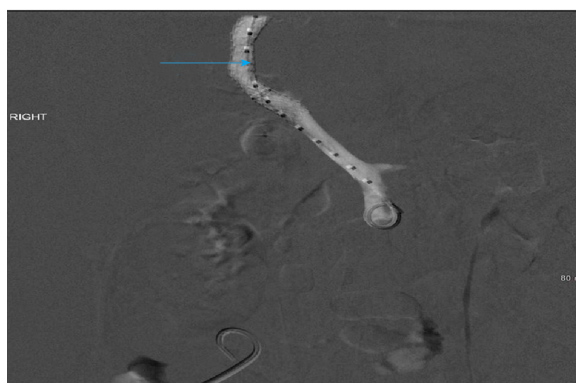Seventy-two hours later, the patient had a recurrence of melena with worsening anemia. A push enteroscopy was performed and showed fresh blood oozing from ectopic varix in the fourth portion of the duodenum (Figure 2). One ml of glue (n-Butyl Cyanoacrylate) was injected into varix. Despite all of that, he continued to have gastrointestinal bleeding that requires a blood transfusion. A repeat CT angiogram showed a nearly occluded TIPS shunt. Therefore, a TIPS revision was preceded, and TIPS was occluded with extensive portal venous thrombosis (Figure 3).

Interestingly, there was a large, competing, non-physiological shunt between the inferior mesenteric vein and left renal vein *via* the left gonadal vein (Figure 4). Maceration thrombectomy and TIPS shunt balloon angioplasty was performed, followed by embolization of the portosystemic (Figure 5). The patient remained stable for the rest of the hospital course with no signs of recurrent bleeding. He was discharged with arranged hepatology follow up.

## DISCUSSION

Patients with portal hypertension develop SPSS with hepatofugal flow that serve as non-physiologic communications between branches of the systemic and portal venous systems which allow excess flow to bypass the liver. One of these SPSS is the splenorenal shunt (SRS), which is associated with boosted occurrence of hepatocellular carcinoma in an obese patient<sup>[5]</sup>. SPSS when dilating form varices, which can be present at numerous regions of the body. Since duodenal varices were initially defined by Alberti<sup>[6]</sup> in 1931 and envisioned *via* the scope by Kunisaki *et al*<sup>[7]</sup> in 1973, there have been hundreds of cases published. In a study reviewing 169 cases of bleeding ectopic varices, 17% were in the duodenum<sup>[1]</sup>. Bleeding ectopic varices account for up to 5% of all variceal bleeding noted in cirrhotic patients. They can be very challenging to diagnose and manage, and as a result, in some cases, can have mortality rates as high as 40%<sup>[1,8,9]</sup>. Currently, there are no set guidelines for the treatment of ectopic variceal bleeding. Management varies based on the location and size of these ectopic varices. Endoscopic band ligation (EBL) and endoscopic injection sclerotherapy (EIS) has been tried in multiple studies for bleeding ectopic varices with some degree of success<sup>[10-15]</sup>. However, as in our case, EBL or EIS can fail to control the bleeding, and TIPS can be used as second-line therapy<sup>[16,17]</sup>. A combined therapeutic technique such as a balloon-occluded retrograde transvenous obliteration (BRTO) with embolization or sclerotherapy has been investigated by Copelan *et al*<sup>[18]</sup> and showed a bleeding control rate of 90% and it suggested to be a safe treatment option when TIPS is contraindicated.

TIPS reduce the hepatic venous pressure gradient (HVPG), which results in portal venous decompression and variceal bleeding control. Studies have shown that bleeding risk from varices decreases significantly once the HVPG falls below 12



**Figure 1** Portal vein angiography image showing hepatopetal flow through transjugular intrahepatic portosystemic shunt (blue arrow) with no filling of varices.

mmHg<sup>[19,20]</sup>. TIPS dysfunction is a complication with TIPS placement. It is defined as a loss of portal vein system decompression, due to thrombosis or stenosis (> 50%) of the TIPS. The pre-TIPS presence of SPSS was found to be associated with an increased risk of early morbidity and mortality after TIPS placement<sup>[4]</sup>.

Our patient had an infrequent and unusual cause for TIPS thrombosis. He was noted to have a large non-physiological SPSS between the inferior mesenteric vein and left renal vein *via* the left gonadal vein. The shunt promoted hepatofugal flow that was competing with the TIPS. As a result, it decreased the flow across the shunt and led to early thrombosis and TIPS dysfunction, which led to recurrent variceal bleeding. Once the shunt was embolized, TIPS revision was successful, and the patient's variceal bleeding resolved.

## CONCLUSION

This case illustrates the importance to look for these competing shunts in patients with early TIPS dysfunction and recurrent bleeding when other causes have been ruled out. Also, as noted in our case, portosystemic pressure gradient measurements are unreliable in patients with large competing SPSS. Embolization of these shunts is crucial to control the duodenal variceal bleeding and prevent early thrombosis of TIPS.

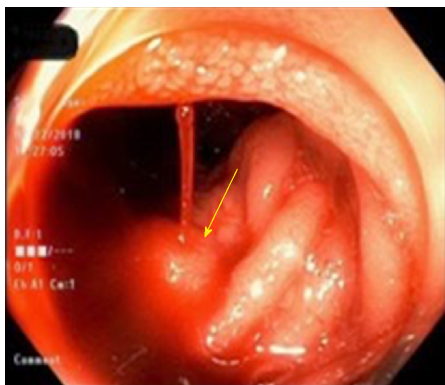


Figure 2 Endoscopic image showing active oozing of fresh blood (yellow arrow) from the ectopic varix in the fourth portion of the duodenum.

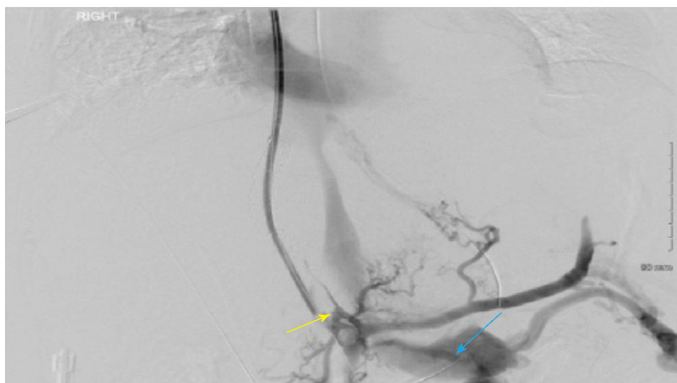


Figure 3 Angiographic image showing filling defect in the transjugular intrahepatic portosystemic shunt and the portal vein (yellow arrow) with portosystemic shunting to left renal vein (blue arrow).

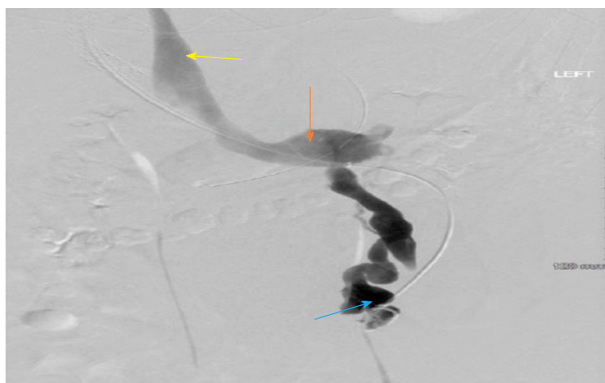


Figure 4 Angiographic image showing a large mesenterico-gonadal venous shunt (blue arrow) draining into the inferior vena cava (yellow arrow) via the left renal vein (orange arrow).

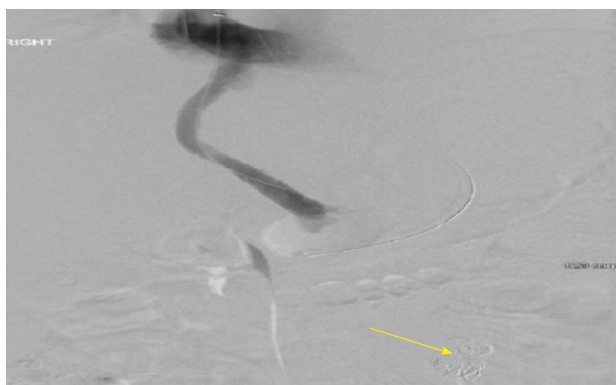


Figure 5 Angiographic image of the portal vein showing the restoration of hepatopetal flow through the transjugular intrahepatic portosystemic shunt after the portosystemic shunt was embolized (yellow arrow).

## REFERENCES

- 1 Norton ID, Andrews JC, Kamath PS. Management of ectopic varices. *Hepatology* 1998; **28**: 1154-1158 [PMID: 9755256 DOI: 10.1002/hep.510280434]
- 2 Kotfila R, Trudeau W. Extraesophageal varices. *Dig Dis* 1998; **16**: 232-241 [PMID: 9732183 DOI: 10.1159/000016871]
- 3 Christidou A, Tzathas C, Khuffash O, Triantaphyllou G. Upper gastrointestinal bleeding due to ectopic varices in a patient with alcoholic cirrhosis. *Ann Gastroenterol* 2003; **16**: 179-182
- 4 Borentain P, Soussan J, Resseguier N, Botta-Fridlund D, Dufour JC, G  rolami R, Vidal V. The presence of SPSS increases the risk of complications after transjugular intrahepatic portosystemic shunt (TIPS) placement. *Diagn Interv Imaging* 2016; **97**: 643-650 [PMID: 26947721 DOI: 10.1016/j.diii.2016.02.004]
- 5 Tarantino G, Citro V, Conca P, Riccio A, Tarantino M, Capone D, Cirillo M, Lobello R, Iaccarino V. What are the implications of the spontaneous spleno-renal shunts in liver cirrhosis? *BMC Gastroenterol* 2009; **9**: 89 [PMID: 19930687 DOI: 10.1186/1471-230X-9-89]
- 6 Alberti W. Ueberden roentgenologischen nachweis von varizen in buolbus duodeni. *Fortschro Geb Koentgenstr* 1931; **43**: 60-65
- 7 Kunisaki T, Someya N, Shimokawa Y. Varices in the distal duodenum seen with a fiberduodenoscope. *Endoscopy* 1973; **5**: 101-104 [DOI: 10.1055/s-0028-1098222]
- 8 Graham DY, Smith JL. The course of patients after variceal hemorrhage. *Gastroenterology* 1981; **80**: 800-809 [PMID: 6970703 DOI: 10.1016/0016-5085(81)90144-X]
- 9 Sarin SK, Kumar CKN. Ectopic varices. *Clin Liver Dis (Hoboken)* 2012; **1**: 167-172 [PMID: 31186880 DOI: 10.1002/clid.95]
- 10 Akhter NM, Haskal ZJ. Diagnosis and management of ectopic varices. *Gastrointest Intervention* 2012; **1**: 3-10 [DOI: 10.1016/j.gii.2012.08.001]
- 11 Akazawa Y, Murata I, Yamao T, Yamakawa M, Kawano Y, Nomura N, Isomoto H, Mizuta Y, Murase K, Kohno S. Successful management of bleeding duodenal varices by endoscopic variceal ligation and balloon-occluded retrograde transvenous obliteration. *Gastrointest Endosc* 2003; **58**: 794-797 [PMID: 14595327 DOI: 10.1016/S0016-5107(03)02008-X]
- 12 Yoshida Y, Imai Y, Nishikawa M, Nakatukasa M, Kurokawa M, Shibata K, Shimomukai H, Shimano T, Tokunaga K, Yonezawa T. Successful endoscopic injection sclerotherapy with N-butyl-2-cyanoacrylate following the recurrence of bleeding soon after endoscopic ligation for ruptured duodenal varices. *Am J Gastroenterol* 1997; **92**: 1227-1229 [PMID: 9219810]
- 13 Hekmat H, Al-toma A, Mallant MP, Mulder CJ, Jacobs MA. Endoscopic N-butyl-2-cyanoacrylate (Histoacryl) obliteration of jejunal varices by using the double balloon enteroscope. *Gastrointest Endosc* 2007; **65**: 350-352 [PMID: 17259003 DOI: 10.1016/j.gie.2006.07.001]
- 14 Chen WC, Hou MC, Lin HC, Chang FY, Lee SD. An endoscopic injection with N-butyl-2-cyanoacrylate used for colonic variceal bleeding: a case report and review of the literature. *Am J Gastroenterol* 2000; **95**: 540-542 [PMID: 10685765 DOI: 10.1016/S0002-9270(99)00841-2]
- 15 Ota K, Shirai Z, Masuzaki T, Tanaka K, Higashihara H, Okazaki M, Arakawa M. Endoscopic injection sclerotherapy with n-butyl-2-cyanoacrylate for ruptured duodenal varices. *J Gastroenterol* 1998; **33**: 550-555 [PMID: 9719241 DOI: 10.1007/s005350050131]
- 16 Sel  uk H, Boyvat F, Eren S, Korkmaz M, G  r G, Yilmaz U, Boyacio  lu S. Duodenal varices as an unusual cause of gastrointestinal bleeding due to portal hypertension: a case report. *Turk J Gastroenterol* 2004; **15**: 104-107 [PMID: 15334321]
- 17 Jonnalagadda SS, Quiason S, Smith OJ. Successful therapy of bleeding duodenal varices by TIPS after failure of sclerotherapy. *Am J Gastroenterol* 1998; **93**: 272-274 [PMID: 9468260 DOI: 10.1111/j.1572-0241.1998.270\_3.x]
- 18 Copelan A, Chehab M, Dixit P, Cappell MS. Safety and efficacy of angiographic occlusion of duodenal varices as an alternative to TIPS: review of 32 cases. *Ann Hepatol* 2015; **14**: 369-379 [PMID: 25864218 DOI: 10.1016/S1665-2681(19)31277-3]
- 19 Vangeli M, Patch D, Terreni N, Tibballs J, Watkinson A, Davies N, Burroughs AK. Bleeding ectopic varices--treatment with transjugular intrahepatic porto-systemic shunt (TIPS) and embolisation. *J Hepatol* 2004; **41**: 560-566 [PMID: 15464235 DOI: 10.1016/j.jhep.2004.06.024]
- 20 Boyer TD, Haskal ZJ; American Association for the Study of Liver Diseases. The role of transjugular intrahepatic portosystemic shunt in the management of portal hypertension. *Hepatology* 2005; **41**: 386-400 [PMID: 15660434 DOI: 10.1002/hep.20559]



Published By Baishideng Publishing Group Inc  
7041 Koll Center Parkway, Suite 160, Pleasanton, CA 94566, USA  
Telephone: +1-925-2238242  
E-mail: [bpgoffice@wjgnet.com](mailto:bpgoffice@wjgnet.com)  
Help Desk: <https://www.f6publishing.com/helpdesk>  
<https://www.wjgnet.com>

