



All

Images

Videos

翻译成中文

关闭取词

27,200 Results

Any time ▾

(PDF) Giant gastroduodenal trichobezoar: An endoscopic ...

https://www.researchgate.net/publication/327316235_Giant_gastroduodenal_trichobezoar...

Endoscopy images showing giant gastroduodenal trichobezoar [(a) Gastroesophageal junction, (b) Body and antrum, and (c) Entering the duodenum through the pyloric canal] ... We report the case of a ...

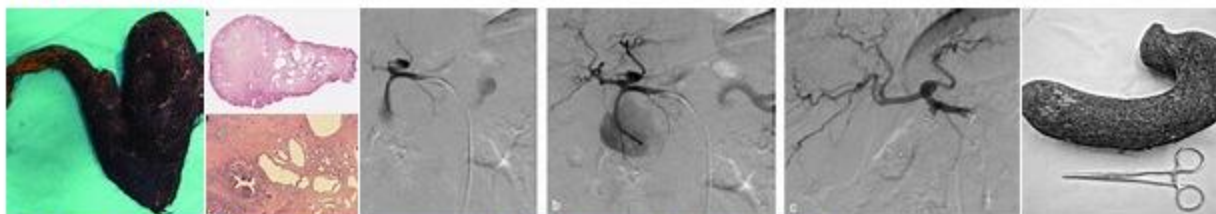
[PDF] Giant gastric trichobezoar: a case report and literature ...

www.scielo.br/pdf/rb/v43n1/en_15.pdf

Giant gastric trichobezoar: a case report Radiol Bras. 2010 Jan/Fev;43(1):63–65 nonspecific dyspeptic symptoms such as post-prandial abdominal pain, nausea and emesis, halitosis, gastrointestinal bleeding, anemia and malnutrition(2,5). Upper digestive endoscopy is the technique of ...

Images of Giant Gastroduodenal Trichobezoar: a case report

bing.com/images



See more images of Giant Gastroduodenal Trichobezoar: a case report

Unusual cause of gastric outlet obstruction: giant gastric ...

<https://casesjournal.biomedcentral.com/articles/10.1186/1757-1626-1-399> ▾

Dec 16, 2008 · Trichobezoars are caused by hair ingestion. The usual presentation of a trichobezoar is with early satiety and malnutrition. Obstructive symptoms and manifestations of gastric outlet obstruction may occur. The diagnosis may be suspected in young females with malnutrition, who have a history of trichophagia. We report a case of 12-year-old female admitted to the emergency room for abdominal ...

Cited by: 7

Author: Ibrahim Yetim, Orhan Veli Ozkan, Ersan ...

Publish Year: 2008

[PDF] Surgical extraction of a giant trichobezoar: A rare ...

www.ijcasereportsandimages.com/archive/2018-pdfs/...

The aim of this study is to report a case of giant trichobezoar presenting as a abdominal mass and underwent surgical extraction. Case Report: A 14-year-old girl with anorexia, epigastric pain and loss of

Name of Journal: *World Journal of Clinical Cases*

Manuscript NO: 50502

Manuscript Type: CASE REPORT

Giant gastroduodenal trichobezoar: A case report

Dong ZH *et al.* Giant gastroduodenal trichobezoar

Zhi-Hui Dong, Feng Yin, Shi-Lin Du, Zhe-Heng Mo

Abstract

BACKGROUND

We report a case of giant gastroduodenal trichobezoar, an extremely rare upper gastrointestinal bezoar due to trichotillomania and trichophagia.

Match Overview

1	Internet 15 words crawled on 28-Jun-2019 www.sap.org.ar	1%
2	Internet 15 words crawled on 13-Apr-2016 www.indianpediatrics.net	1%
3	Crossref 11 words Catherine Western. "Rapunzel Syndrome: A Case Report and Review", <i>Journal of Gastrointestinal Surgery</i> , 09/2008	1%
4	Internet 11 words crawled on 28-Apr-2016 www.najms.net	1%
5	Crossref 10 words M.M. Hennessy, I. Ivanovski, C.B. Ó Súilleabháin. "Gastric ulceration and perforation secondary to large trichobezoar –	1%



All

Images

Videos

关闭取词

27,800 Results

Any time ▾

(PDF) Giant gastroduodenal trichobezoar: An endoscopic ...

https://www.researchgate.net/publication/327316235_Giant_gastroduodenal_trichobezoar...

Endoscopy images showing giant gastroduodenal trichobezoar [(a) Gastroesophageal junction, (b) Body and antrum, and (c) Entering the duodenum through the pyloric canal] ... The case report is ...

Unusual cause of gastric outlet obstruction: giant gastric ...

<https://casesjournal.biomedcentral.com/articles/10.1186/1757-1626-1-399> ▾

Dec 16, 2008 - Trichobezoars are caused by hair ingestion. The usual presentation of a trichobezoar is with early satiety and malnutrition. Obstructive symptoms and manifestations of gastric outlet obstruction may occur. The diagnosis may be suspected in young females with malnutrition, who have a history of trichophagia. We report a case of 12-year-old female admitted to the emergency room for abdominal ...

Cited by: 7

Author: Ibrahim Yetim, Orhan Veli Ozkan, Ersan ...

Publish Year: 2008

Closed-perforation of gastric fundus and gastric outlet ...

<https://docksci.com/closed-perforation-of-gastric-fundus-and-gastric-outlet...> ▾

Closed-perforation of gastric fundus and gastric outlet obstruction caused by a giant gastric trichobezoar: A case report. A bezoar is a mass formed because of the accumulation of indigestible material in the stomach and/or small intestine. Bezoars are rare but occasionally...

[PDF] Surgical extraction of a giant trichobezoar: A rare ...

www.ijcasereportsandimages.com/archive/2018-pdfs/...

The aim of this study is to report a case of giant trichobezoar presenting as a abdominal mass and underwent surgical extraction. Case Report: A 14-year-old girl with anorexia, epigastric pain and loss of weight for three month duration. The patient reported history of early satiety and constipation. Abdominal

Cited by: 1

Author: Ayad Ahmad Mohammed, Sardar Hassan...

Publish Year: 2018

Surgical extraction of a giant trichobezoar: A rare ...

www.ijcasereportsandimages.com/archive/2018... ▾

Introduction: Trichobezoar occurs when a trichotillomaniac patient eats his or her hair after extraction leading to surgical emergency. The aim of this study is to report a case of giant trichobezoar presenting as a abdominal mass and underwent surgical extraction. Case Report: A 14-year-old girl with anorexia, epigastric pain and loss of weight for three month duration.



国内版

国际版

Giant gastroduodenal trichobezoar: A case report



All

Images

Videos

关闭取词

52,700 Results

Any time ▼

(PDF) Giant gastroduodenal trichobezoar: An endoscopic ...

https://www.researchgate.net/publication/327316235_Giant_gastroduodenal_trichobezoar...

We report herein a third case of a trichobezoar that was successfully retrieved after endoscopic fragmentation with snare polypectomy and argon plasma coagulation in a six-year-old female patient.

(PDF) Giant Gastroduodenal Trichobezoar: Rapunzel Syndrome

https://www.researchgate.net/publication/38066042_Giant_Gastroduodenal_Trichobezoar...

Giant Gastroduodenal Trichobezoar: Rapunzel Syndrome. ... We report here the unusual case of a case of a 16 years old girl presented with severe abdominal pain and vomiting. ... A diagnostic of ...

Giant Trichobezoar of Duodenojejunal Flexure: A Rare Entity

<https://www.ncbi.nlm.nih.gov/pmc/articles/PMC3003208>

Giant Trichobezoar of Duodenojejunal Flexure: A Rare Entity ... Hereby we report a case of duodenojejunal bezoar in a 27-year-old woman presenting with intestinal occlusion which was treated with bowel resection. We want to attract the attention of clinicians to the diagnostic difficulties in this regard. ... A normal oeso-gastroduodenal ...

Cited by: 4

Author: Mehdi Soufi, Said Benamr, Mehdi Belhas...

Publish Year: 2010

(PDF) Giant gastroduodenal trichobezoar: Rapunzel ...

<https://www.academia.edu/14449131/Giant...>

Giant gastroduodenal trichobezoar: Rapunzel syndrome. The American journal of gastroenterology, 2009. ... 2864 Letters to the Editor Giant Gastroduodenal ing into the small bowel and sometimes severe hypoalbuminemia (1.7 g/dl). A even to the colon (1,2). ... [Rapunzel syndrome: case report and literature review]. Rev Gastroenterol Peru the ...

[PDF] CASE REPORT GIANT TRICHOBEZOAR ... - ...

<https://jamc.ayubmed.edu.pk/index.php/jamc/article/download/2514/1153>

number of case reports and small case series has been reported in the literature. This is the first ever rare case report of giant trichobezoar reported from our public sector university hospital. CASE REPORT A 40 years old thin built, married woman is admitted in the department of surgery with epigastric pain and lump

Cited by: 1

Author: Syed Asad Ali, Abdul Ghani Soomro, Mu...

Publish Year: 2011