

# World Journal of *Clinical Cases*

*World J Clin Cases* 2019 December 26; 7(24): 4172-4425



**REVIEW**

- 4172** Polyunsaturated fatty acids and DNA methylation in colorectal cancer  
*Moradi Sarabi M, Mohammadrezaei Khorramabadi R, Zare Z, Eftekhari E*

**ORIGINAL ARTICLE****Retrospective Study**

- 4186** Impact of resection margins on long-term survival after pancreaticoduodenectomy for pancreatic head carcinoma  
*Li CG, Zhou ZP, Tan XL, Gao YX, Wang ZZ, Liu Q, Zhao ZM*
- 4196** Arthroscopy combined with unicompartmental knee arthroplasty for treatment of isolated unicompartmental knee arthritis: A long-term comparison  
*Wang HR, Li ZL, Li J, Wang YX, Zhao ZD, Li W*
- 4208** Intact, pie-crusting and repairing the posterior cruciate ligament in posterior cruciate ligament-retaining total knee arthroplasty: A 5-year follow-up  
*Ma DS, Wen L, Wang ZW, Zhang B, Ren SX, Lin Y*
- 4218** Community-acquired pneumonia complicated by rhabdomyolysis: A clinical analysis of 11 cases  
*Zhao B, Zheng R*

**Clinical Trials Study**

- 4226** Dissection and ligation of the lateral circumflex femoral artery is not necessary when using the direct anterior approach for total hip arthroplasty  
*Zhao GY, Wang YJ, Xu NW, Liu F*

**Observational Study**

- 4234** Expression of interleukin-32 in bone marrow of patients with myeloma and its prognostic significance  
*Wang G, Ning FY, Wang JH, Yan HM, Kong HW, Zhang YT, Shen Q*

**Randomized Controlled Trial**

- 4245** Effect of different types of laryngeal mask airway placement on the right internal jugular vein: A prospective randomized controlled trial  
*Zhang JJ, Qu ZY, Hua Z, Zuo MZ, Zhang HY*

**SYSTEMATIC REVIEW**

- 4254** Chronic pain, posttraumatic stress disorder, and opioid intake: A systematic review  
*López-Martínez AE, Reyes-Pérez Á, Serrano-Ibáñez ER, Esteve R, Ramírez-Maestre C*

## CASE REPORT

- 4270 Acute appendicitis in a patient after a uterus transplant: A case report  
*Kristek J, Kudla M, Chlupac J, Novotny R, Mirejovsky T, Janousek L, Fronek J*
- 4277 Pneumococcal infection transmission between family members with congenital asplenia: A case report  
*Shibata J, Hiramatsu K, Kenzaka T, Kato T*
- 4285 Successful treatment of warfarin-induced skin necrosis using oral rivaroxaban: A case report  
*Kamada M, Kenzaka T*
- 4292 Simultaneous *Paragonimus* infection involving the breast and lung: A case report  
*Oh MY, Chu A, Park JH, Lee JY, Roh EY, Chai YJ, Hwang KT*
- 4299 Isolated peritoneal lymphomatosis defined as post-transplant lymphoproliferative disorder after a liver transplant: A case report  
*Kim HB, Hong R, Na YS, Choi WY, Park SG, Lee HJ*
- 4307 Three-dimensional image simulation of primary diaphragmatic hemangioma: A case report  
*Chu PY, Lin KH, Kao HL, Peng YJ, Huang TW*
- 4314 Natural orifice specimen extraction with laparoscopic radical gastrectomy for distal gastric cancer: A case report  
*Sun P, Wang XS, Liu Q, Luan YS, Tian YT*
- 4321 Huge brown tumor of the rib in an unlocatable hyperparathyroidism patient with “self-recovered” serum calcium and parathyroid hormone: A case report  
*Wang WD, Zhang N, Qu Q, He XD*
- 4327 Percutaneous management of atrium and lung perforation: A case report  
*Zhou X, Ze F, Li D, Li XB*
- 4334 Epstein-Barr virus-positive post-transplant lymphoproliferative disorder presenting as hematochezia and enterobrosis in renal transplant recipients in China: A report of two cases  
*Sun ZJ, Hu XP, Fan BH, Wang W*
- 4342 Postoperative multidrug-resistant *Acinetobacter baumannii* meningitis successfully treated with intravenous doxycycline and intraventricular gentamicin: A case report  
*Wu X, Wang L, Ye YZ, Yu H*
- 4349 Reconstruction of massive skin avulsion of the scrota and penis by combined application of dermal regeneration template (Pelnac) and split-thickness skin graft with vacuum-assisted closure: A case report  
*Fang JJ, Li PF, Wu JJ, Zhou HY, Xie LP, Lu H*

- 4355** Multisystem smooth muscle dysfunction syndrome in a Chinese girl: A case report and review of the literature  
*Chen SN, Wang YQ, Hao CL, Lu YH, Jiang WJ, Gao CY, Wu M*
- 4366** Kidney inflammatory myofibroblastic tumor masquerading as metastatic malignancy: A case report and literature review  
*Zhang GH, Guo XY, Liang GZ, Wang Q*
- 4377** Hydroxychloroquine-induced renal phospholipidosis resembling Fabry disease in undifferentiated connective tissue disease: A case report  
*Wu SZ, Liang X, Geng J, Zhang MB, Xie N, Su XY*
- 4384** Spontaneous ovarian hyperstimulation syndrome: Report of two cases  
*Gui J, Zhang J, Xu WM, Ming L*
- 4391** Castleman disease in the hepatic-gastric space: A case report  
*Xu XY, Liu XQ, Du HW, Liu JH*
- 4398** KIT and platelet-derived growth factor receptor  $\alpha$  wild-type gastrointestinal stromal tumor associated with neurofibromatosis type 1: Two case reports  
*Kou YW, Zhang Y, Fu YP, Wang Z*
- 4414** Isolated elevated aspartate aminotransferase in an asymptomatic woman due to macro-aspartate aminotransferase: A case report  
*Zhan MR, Liu X, Zhang MY, Niu JQ*
- 4420** Rehabilitation of anterior pituitary dysfunction combined with extrapontine myelinolysis: A case report  
*Yang MX, Chen XN*

**ABOUT COVER**

Editorial Board Member of *World Journal of Clinical Cases*, Ashu Seith Bhalla, MD, Professor, Department of Radiodiagnosis, All India Institute of Medical Sciences, New Delhi 110029, India

**AIMS AND SCOPE**

The primary aim of *World Journal of Clinical Cases* (WJCC, *World J Clin Cases*) is to provide scholars and readers from various fields of clinical medicine with a platform to publish high-quality clinical research articles and communicate their research findings online.

WJCC mainly publishes articles reporting research results and findings obtained in the field of clinical medicine and covering a wide range of topics, including case control studies, retrospective cohort studies, retrospective studies, clinical trials studies, observational studies, prospective studies, randomized controlled trials, randomized clinical trials, systematic reviews, meta-analysis, and case reports.

**INDEXING/ABSTRACTING**

The WJCC is now indexed in PubMed, PubMed Central, Science Citation Index Expanded (also known as SciSearch®), and Journal Citation Reports/Science Edition. The 2019 Edition of Journal Citation Reports cites the 2018 impact factor for WJCC as 1.153 (5-year impact factor: N/A), ranking WJCC as 99 among 160 journals in Medicine, General and Internal (quartile in category Q3).

**RESPONSIBLE EDITORS FOR THIS ISSUE**

Responsible Electronic Editor: Ji-Hong Liu

Proofing Production Department Director: Yun-Xiaojuan Wu

**NAME OF JOURNAL**

*World Journal of Clinical Cases*

**ISSN**

ISSN 2307-8960 (online)

**LAUNCH DATE**

April 16, 2013

**FREQUENCY**

Semimonthly

**EDITORS-IN-CHIEF**

Dennis A Bloomfield, Bao-Gan Peng, Sandro Vento

**EDITORIAL BOARD MEMBERS**

<https://www.wjnet.com/2307-8960/editorialboard.htm>

**EDITORIAL OFFICE**

Jin-Lei Wang, Director

**PUBLICATION DATE**

December 26, 2019

**COPYRIGHT**

© 2019 Baishideng Publishing Group Inc

**INSTRUCTIONS TO AUTHORS**

<https://www.wjnet.com/bpg/gerinfo/204>

**GUIDELINES FOR ETHICS DOCUMENTS**

<https://www.wjnet.com/bpg/GerInfo/287>

**GUIDELINES FOR NON-NATIVE SPEAKERS OF ENGLISH**

<https://www.wjnet.com/bpg/gerinfo/240>

**PUBLICATION MISCONDUCT**

<https://www.wjnet.com/bpg/gerinfo/208>

**ARTICLE PROCESSING CHARGE**

<https://www.wjnet.com/bpg/gerinfo/242>

**STEPS FOR SUBMITTING MANUSCRIPTS**

<https://www.wjnet.com/bpg/GerInfo/239>

**ONLINE SUBMISSION**

<https://www.f6publishing.com>



## Acute appendicitis in a patient after a uterus transplant: A case report

Jakub Kristek, Michal Kudla, Jaroslav Chlupac, Robert Novotny, Tomas Mirejovsky, Libor Janousek, Jiri Fronek

**ORCID number:** Jakub Kristek (0000-0002-3758-2273); Michal Kudla (0000-0001-9018-1738); Jaroslav Chlupac (0000-0003-1482-6105); Robert Novotny (0000-0002-5876-2951); Tomas Mirejovsky (0000-0002-4616-4321); Libor Janousek (0000-0001-7572-8416); Jiri Fronek (0000-0003-2379-3886).

**Author contributions:** Kristek J wrote the manuscript and analyzed the data. Kudla M operated on the patient. Chlupac J and Novotny R co-analyzed the data and provided consultations regarding the risk of thrombosis. Mirejovsky T provided the histological image. Janousek L and Fronek J designed and ran the uterus transplantation trial and provided consultations regarding this case.

**Conflict-of-interest statement:** The authors declare that they have no conflict of interest.

**CARE Checklist (2016) statement:** The manuscript was prepared and revised according to the CARE Checklist (2016).

**Open-Access:** This article is an open-access article which was selected by an in-house editor and fully peer-reviewed by external reviewers. It is distributed in accordance with the Creative Commons Attribution Non Commercial (CC BY-NC 4.0) license, which permits others to distribute, remix, adapt, build upon this work non-commercially, and license their derivative works on different terms, provided the original work is properly cited and

**Jakub Kristek, Michal Kudla, Jaroslav Chlupac, Robert Novotny, Libor Janousek, Jiri Fronek,** Department of Transplant Surgery, Institute for Clinical and Experimental Medicine, Prague 140 21, Czech Republic

**Jakub Kristek, Jaroslav Chlupac, Jiri Fronek,** Department of Anatomy, Second Faculty of Medicine, Charles University, Prague 150 06, Czech Republic

**Tomas Mirejovsky,** Department of Clinical and Transplant Pathology, Institute for Clinical and Experimental Medicine, Prague 140 21, Czech Republic

**Libor Janousek,** First Faculty of Medicine, Charles University, Prague 121 08, Czech Republic

**Corresponding author:** Jakub Kristek, MD, Department of Anatomy, Second Faculty of Medicine, Charles University, V Uvalu 84, Prague 150 06, Czech Republic. [krsj@ikem.cz](mailto:krsj@ikem.cz)  
**Telephone:** +420-23-6054105  
**Fax:** +420-23-6052822

### Abstract

#### BACKGROUND

Acute appendicitis in a solid organ transplant recipient is a rare occurrence, and experience remains limited. Appendicitis in uterine transplant recipients has never been reported. Immunocompromised patients with acute abdomen often present late and with attenuated symptoms. The differential diagnosis in a transplanted patient is broad and challenging due to possible existing complications associated with the graft, effects of immunosuppression, and altered anatomical relations.

#### CASE SUMMARY

A 26-year-old woman suffering from absolute uterine factor infertility received a uterus transplant. In the post-transplant period, she suffered from leukopenia and recurrent acute cellular rejection. Her compliance was suboptimal. She travelled to an exotic destination despite the physician's recommendation not to do so. Following her vacation, she presented with abdominal discomfort, nausea and diarrhoea. There was no sign of acute abdomen; the abdominal ultrasound was negative on day 0. *Clostridium difficile* colitis was verified and treated with perorally administered vancomycin. On day 4, the discomfort changed to pain; the ultrasound scan revealed a finding suggestive of appendicitis. Surgical exploration revealed perforated appendicitis, and appendectomy was performed. From a surgical point of view, the patient's follow-up was uneventful. The patient underwent a successful embryo transfer 6 months after the appendectomy. The patient gave birth to a healthy boy at the 35<sup>th</sup> week of

the use is non-commercial. See:  
<http://creativecommons.org/licenses/by-nc/4.0/>

**Manuscript source:** Unsolicited manuscript

**Received:** September 20, 2019

**Peer-review started:** September 20, 2019

**First decision:** October 20, 2019

**Revised:** November 7, 2019

**Accepted:** November 15, 2019

**Article in press:** November 15, 2019

**Published online:** December 26, 2019

**P-Reviewer:** Hefny AF

**S-Editor:** Zhang L

**L-Editor:** A

**E-Editor:** Qi LL



gestation.

## CONCLUSION

A high index of suspicion of an atypical course and symptomatology of acute abdomen should be maintained in immunosuppressed patients.

**Key words:** Uterus; Organ transplantation; Noncompliance; Acute abdomen; Colitis; Differential diagnosis; Case report

©The Author(s) 2019. Published by Baishideng Publishing Group Inc. All rights reserved.

**Core tip:** Herein, we present a unique report of a woman with a viable transplanted uterus graft who was suffering from concurrent *Clostridium difficile* colitis and acute appendicitis. The differential diagnosis in an immunosuppressed patient may be complex, and a high index of suspicion of an atypical course of acute abdomen should be maintained in immunosuppressed patients. Sometimes, more than one synchronous pathological condition may be present. This case highlights the ultimate importance of focusing on the achievement of successful embryo transfer in the uterus transplantation recipients as soon as possible since they are vulnerable to a multitude of possible complications.

**Citation:** Kristek J, Kudla M, Chlupac J, Novotny R, Mirejovsky T, Janousek L, Fronek J. Acute appendicitis in a patient after a uterus transplant: A case report. *World J Clin Cases* 2019; 7(24): 4270-4276

**URL:** <https://www.wjgnet.com/2307-8960/full/v7/i24/4270.htm>

**DOI:** <https://dx.doi.org/10.12998/wjcc.v7.i24.4270>

## INTRODUCTION

Uterus transplantation (UTx) is an experimental treatment method for women with uterine factor infertility (UFI). It is a novel, challenging procedure performed in only a few centres around the world; hence, experience with acute abdomen in UTx recipients is rare. The lifetime risk of acute appendicitis (AA) in a normal population has been estimated to be 8.6% and 6.7% for males and females, respectively<sup>[1]</sup>. AA in solid organ transplant recipients is rare, yet a few small case series have been reported<sup>[2,3]</sup>. This article presents the first case of a woman with a history of UTx who suffered from AA.

## CASE PRESENTATION

### History of past illness

A 26-year-old Caucasian woman suffering from congenital absolute UFI underwent a deceased donor UTx. In the first year of the post-transplant period, 4 episodes of mild acute cellular rejection were diagnosed by cervical biopsy. They were treated with pulses of glucocorticoids and the addition of azathioprine to a maintenance immunosuppressive regimen of tacrolimus. In the further course, the patient developed secondary neutropenia, which was addressed by withdrawal of azathioprine and administration of several pulses of granulocyte colony-stimulating factor.

### Personal and family history

Apart from congenital uterine agenesis which was treated with UTx, the patient was healthy with no history of further operations. Family history was negative for inherent diseases.

### History of present illness

Five months after the UTx, the patient's compliance was suboptimal. She decided to go on vacation to Egypt despite clear physician recommendation not to do so considering the high risk of acquisition of infectious gastroenteritis.

### Chief complaints

After her return from Egypt, the patient presented with nausea, abdominal discomfort, and diarrhoea. She was hospitalized to receive rehydration therapy and to run necessary tests.

### Physical examination upon admission

Upon admission, there were no signs of acute abdomen. The abdomen was mildly tender in all quadrants; there were no signs of peritoneal inflammation.

### Imaging examinations

Upon admission, her abdominal ultrasound (US) was normal, although the appendix was not differentiated on baseline US. There was no suspicion of acute abdomen, and thrombosis of the uterine graft was excluded using Doppler ultrasound (Figure 1).

### Laboratory examinations

C-reactive protein was 27 mg/L on day 0; the level of leukocytes was within the normal range. However, tests proved to be positive for *Clostridium difficile* colitis. Due to lack of signs of acute abdomen and verified colitis, we felt it was not necessary to run computed tomography (CT) of the abdomen. A therapy of perorally administered vancomycin 125 mg 4 times a day was started. Viral and parasitic colitis were excluded. Additionally, cytomegalovirus (CMV) polymerase chain reaction was negative. In the course of the next few days, there was a steady progressive elevation of the level of C-reactive protein up to 83 mg/L on day 4. Although the differential blood count showed a normal level of leukocytes, it was considered pathologic because the patient had been leukopenic chronically and there was a new finding of neutrophilia. On day 4, the abdominal discomfort changed to pain and became localized to the right hypogastrium.

---

## FINAL DIAGNOSIS

A subsequent US scan revealed a nonhomogeneous tubular structure located behind the uterus, *i.e.*, a finding suggestive of AA (Figure 2A and B). The final diagnosis of the presented case is concurrent *Clostridium difficile* colitis and acute perforated appendicitis.

---

## TREATMENT

The patient underwent an uncomplicated conversion lap-to-open appendectomy. A gangrenous perforated appendix with localized peritonitis was found dorsal to the uterus (Figures 3 and 4). The patient was treated with metronidazole and amoxicillin with clavulanic acid; the tacrolimus immunosuppressive regimen was not discontinued because she was not septic. Subsequently, the tacrolimus levels increased to toxic levels, probably due to diarrhoea and consequently impaired resorption. The medication was changed, and probiotics were administered.

---

## OUTCOME AND FOLLOW-UP

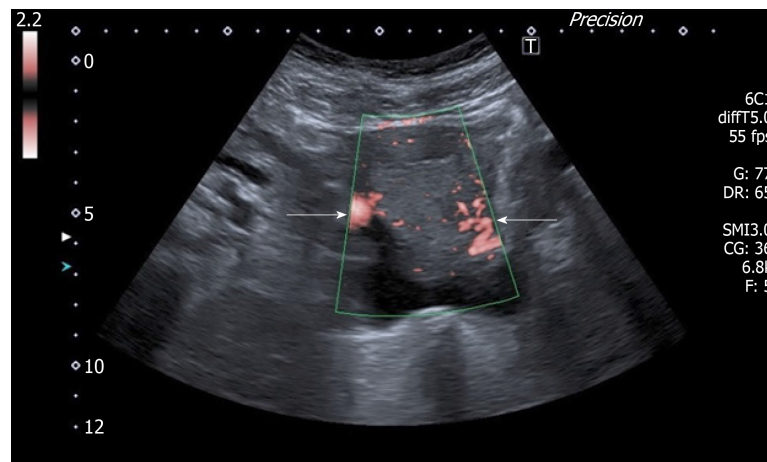
Apart from long-lasting diarrhoea and pancytopenia of complex aetiology, the patient's follow-up was uneventful. The interval between transplant and appendectomy was 502 days. The patient underwent a successful embryo transfer 6 months after the appendectomy. Apart from pregnancy-induced diabetes, the pregnancy was uneventful. The patient gave birth to a healthy boy at week 35 of gestation.

---

## DISCUSSION

Although AA has been rarely observed and described in recipients of solid organ transplants, this is the first reported case of AA in a uterus transplant recipient. According to the official transplant terminology, uterus transplant is not considered a solid organ transplant but a vascularized composite allograft, as are other non-vital transplantable organs, including the face, extremities, abdominal wall, and larynx<sup>[4]</sup>. The prevalence of AA is reported as 0.35%, 0.49%, and 0.21% in kidney transplant recipients ( $n = 2880$ ), liver transplant recipients ( $n = 817$ ), and liver, heart, kidney,





**Figure 1** Doppler ultrasound scan of the uterine graft showing perfusion present on both sides of the graft. Uterine arteries (white arrows).

pancreas-kidney and heart-kidney transplant recipients ( $n = 8000$ ), respectively<sup>[2,3,5]</sup>.

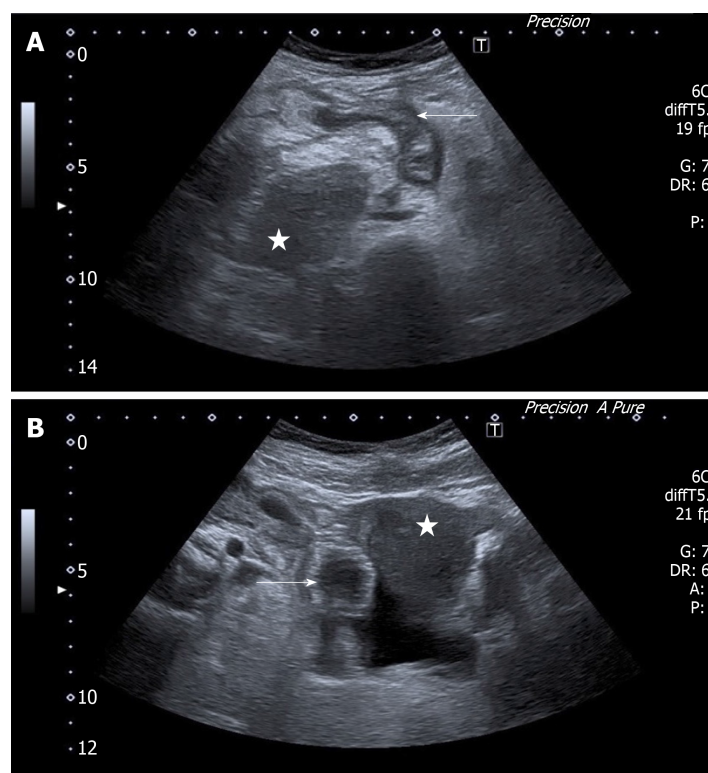
Generally, immunocompromised patients tend to present late and with minimal symptoms; the symptoms of acute abdomen tend to be weakened by the attenuated immune response. Classic signs of peritonitis, *e.g.*, rebound tenderness and fever, may be feeble or even absent in immunocompromised hosts. Furthermore, nonspecific signs such as tachycardia, hypotension, and confusion may present the only warning of existing abdominal catastrophe<sup>[6]</sup>. Savar *et al*<sup>[2]</sup> came to slightly different conclusions, at least with regard to AA. In their cohort of 15 transplant recipients suffering from AA, the physical findings were similar to the findings in the non-transplant population, *i.e.*, abdominal/right hypogastrium pain (present in 94% of cases) and nausea and vomiting (present in 88% of cases)<sup>[2]</sup>. Generally, after solid organ transplants that are typically placed in the right iliac fossa/retroperitoneum (kidney or pancreas), AA may be misdiagnosed as a graft-related complication, *e.g.*, infection, acute urine outflow obstruction, or acute rejection of the graft. In UTx recipients, thrombosis of the graft remains the most feared complication. Thrombosis of the vascular pedicles of the uterine graft has been repeatedly presented as a cause of loss of the graft in both animal as well as human studies<sup>[7,8]</sup>. Since diarrhoea may lead to dehydration and the association between dehydration and a higher risk of venous thrombosis is presumed, graft thrombosis was immediately suspected and subsequently excluded using Doppler US in our case<sup>[9]</sup>. A possible cause of AA after kidney transplantation is CMV infection. Invasive CMV infection must always be excluded by definitive histopathological evaluation. If the test for CMV is positive, effective antiviral treatment must be instituted<sup>[10]</sup>.

The risk of perforation of an inflamed appendix escalates over time. Perforation is present in approximately 10% of patients by 24 h and in up to 50% of patients by 48 h in the non-transplanted paediatric population<sup>[11]</sup>. Although the diagnosis of AA is often based on clinical and laboratory findings, the use of either US or CT is recommended if AA is suspected; the sensitivity and specificity of CT are up to 98.5% and up to 98%, respectively<sup>[12]</sup>. According to a meta-analysis, the rate of a negative appendectomy was 8.7% with the use of preoperative abdominal CT compared to 16.7% based on clinical evaluation alone<sup>[13]</sup>. However, US may be almost as sensitive as CT in diagnosing AA when performed by well-trained radiologists, with the advantage of no radiation exposure<sup>[14]</sup>.

In our case, if CT was used upon admission, it may have led to timely diagnosis and appendectomy of inflamed yet non-perforated appendix. However, we have suspicion that *Clostridium difficile* colitis may have been the very cause of the appendicitis. In other words, it may be a case of *Clostridium difficile* colitis and subsequent acute appendicitis.

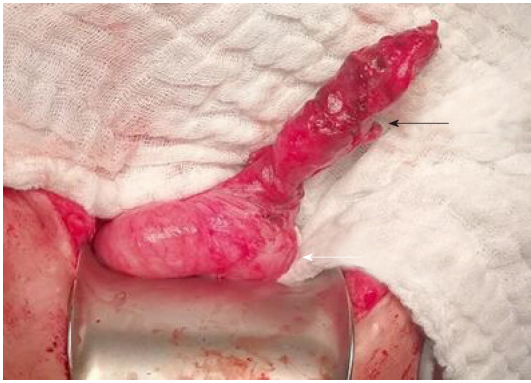UTx is primarily considered a temporary transplant. It cannot be emphasized enough that UTx recipients should preferentially focus on achieving successful embryo transfer. Since UTx recipients are prone to a variety of complications and the side effects of immunosuppression, it is advisable to obviate any risky activities that might compromise achieving the primary aim.

## CONCLUSION

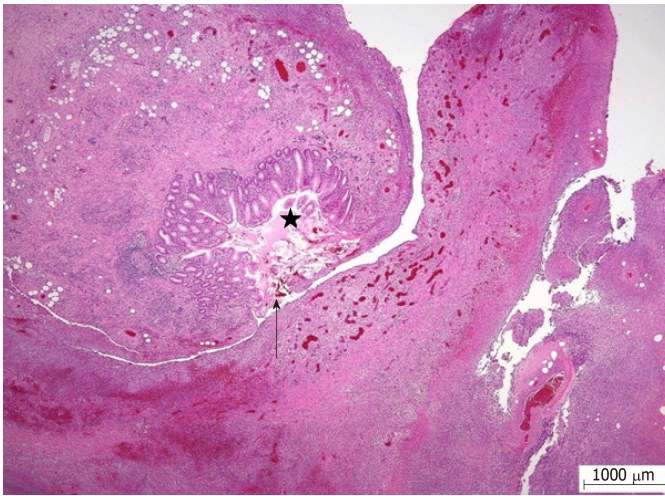


**Figure 2** Ultrasound scan. A: A suspected inflamed appendix next to the uterine graft. Suspected inflamed appendix in a longitudinal view (arrow); the uterine graft (star); B: A suspected inflamed appendix next to the uterine graft. Suspected appendicitis in a transversal view (arrow); the uterine graft (star).

In this paper, we present a unique report of a woman with a viable transplanted uterus graft suffering from *Clostridium difficile* colitis and AA. The differential diagnosis in an immunosuppressed patient may be complex, and a high index of suspicion of atypical course and indefinite symptomatology of acute abdomen should be maintained in immunosuppressed patients. Sometimes, more than one synchronous pathological condition may be present. In transplanted patients, thrombosis of the vascular pedicles must always be excluded if pain or alteration to the graft's function occurs. UTx recipients should preferentially focus on achieving successful embryo transfer because they are prone to a variety of complications.



**Figure 3** A photo of the appendix. A perforation of the appendix (black arrow); the base of the caecum (white arrow).



**Figure 4** A histological section of the appendix; acute gangrenous appendicitis with perforation of its wall, purulent fibrinous periappendicitis. (Hematoxylin eosin, magnitude 20 ×). A perforation of the appendix (arrow); the lumen of the appendix (star).

## ACKNOWLEDGEMENTS

The author would like to thank Dr. Kornelia Chrapkova, PG Dip, for her invaluable help with review of the literature.

## REFERENCES

- 1 Addiss DG, Shaffer N, Fowler BS, Tauxe RV. The epidemiology of appendicitis and appendectomy in the United States. *Am J Epidemiol* 1990; **132**: 910-925 [PMID: [2239906](#) DOI: [10.1093/oxfordjournals.aje.a115734](#)]
- 2 Savar A, Hiatt JR, Busuttill RW. Acute appendicitis after solid organ transplantation. *Clin Transplant* 2006; **20**: 78-80 [PMID: [16556158](#) DOI: [10.1111/j.1399-0012.2005.00444.x](#)]
- 3 Kwon SH, Park SH, Lee HY, Ko EJ, Ban TH, Chung BH, Yang CW. Clinical Characteristics of Acute Appendicitis in Kidney Transplant Recipients. *Ann Transplant* 2019; **24**: 168-173 [PMID: [30910996](#) DOI: [10.12659/AOT.914134](#)]
- 4 Samuel U. Regulatory aspects of VCA in Eurotransplant. *Transpl Int* 2016; **29**: 686-693 [PMID: [26824440](#) DOI: [10.1111/tri.12753](#)]
- 5 Wu L, Zhang J, Guo Z, Tai Q, He X, Ju W, Wang D, Zhu X. Diagnosis and treatment of acute appendicitis after orthotopic liver transplant in adults. *Exp Clin Transplant* 2011; **9**: 113-117 [PMID: [21453228](#)]
- 6 Scott-Conner CE, Fabrega AJ. Gastrointestinal problems in the immunocompromised host. A review for surgeons. *Surg Endosc* 1996; **10**: 959-964 [PMID: [8864085](#) DOI: [10.1007/s004649900214](#)]
- 7 Brännström M, Wranning CA, Altchek A. Experimental uterus transplantation. *Hum Reprod Update* 2010; **16**: 329-345 [PMID: [19897849](#) DOI: [10.1093/humupd/dmp049](#)]
- 8 Fageeh W, Raffa H, Jabbar H, Marzouki A. Transplantation of the human uterus. *Int J Gynaecol Obstet* 2002; **76**: 245-251 [PMID: [11880127](#) DOI: [10.1016/s0020-7292\(01\)00597-5](#)]
- 9 Verhaeghe R, Vermeylen J, Verstraete M. Thrombosis in particular organ veins. *Herz* 1989; **14**: 298-307 [PMID: [2680853](#)]
- 10 Posen A, Renckens I, Sagaert X, Kuypers D. Subacute cytomegalovirus appendicitis in a renal transplant recipient. *Transpl Infect Dis* 2013; **15**: 96-97 [PMID: [23075276](#) DOI: [10.1111/tid.12021](#)]

- 11 **Chan MK**, Wilcox DT, Trompeter RS. Acute appendicitis in children after renal transplantation. *Arch Dis Child* 1999; **81**: 372 [PMID: [10577360](#) DOI: [10.1136/adc.81.4.e372](#)]
- 12 **Pickhardt PJ**, Lawrence EM, Pooler BD, Bruce RJ. Diagnostic performance of multidetector computed tomography for suspected acute appendicitis. *Ann Intern Med* 2011; **154**: 789-796, W-291 [PMID: [21690593](#) DOI: [10.7326/0003-4819-154-12-201106210-00006](#)]
- 13 **Krajewski S**, Brown J, Phang PT, Raval M, Brown CJ. Impact of computed tomography of the abdomen on clinical outcomes in patients with acute right lower quadrant pain: a meta-analysis. *Can J Surg* 2011; **54**: 43-53 [PMID: [21251432](#) DOI: [10.1503/cjs.023509](#)]
- 14 **Doria AS**, Moineddin R, Kellenberger CJ, Epelman M, Beyene J, Schuh S, Babyn PS, Dick PT. US or CT for Diagnosis of Appendicitis in Children and Adults? A Meta-Analysis. *Radiology* 2006; **241**: 83-94 [PMID: [16928974](#) DOI: [10.1148/radiol.2411050913](#)]



Published By Baishideng Publishing Group Inc  
7041 Koll Center Parkway, Suite 160, Pleasanton, CA 94566, USA  
Telephone: +1-925-2238242  
E-mail: [bpgoffice@wjgnet.com](mailto:bpgoffice@wjgnet.com)  
Help Desk: <https://www.f6publishing.com/helpdesk>  
<https://www.wjgnet.com>

