

World Journal of *Clinical Cases*

World J Clin Cases 2019 December 26; 7(24): 4172-4425



**REVIEW**

- 4172** Polyunsaturated fatty acids and DNA methylation in colorectal cancer
Moradi Sarabi M, Mohammadrezaei Khorramabadi R, Zare Z, Eftekhari E

ORIGINAL ARTICLE**Retrospective Study**

- 4186** Impact of resection margins on long-term survival after pancreaticoduodenectomy for pancreatic head carcinoma
Li CG, Zhou ZP, Tan XL, Gao YX, Wang ZZ, Liu Q, Zhao ZM
- 4196** Arthroscopy combined with unicompartmental knee arthroplasty for treatment of isolated unicompartmental knee arthritis: A long-term comparison
Wang HR, Li ZL, Li J, Wang YX, Zhao ZD, Li W
- 4208** Intact, pie-crusting and repairing the posterior cruciate ligament in posterior cruciate ligament-retaining total knee arthroplasty: A 5-year follow-up
Ma DS, Wen L, Wang ZW, Zhang B, Ren SX, Lin Y
- 4218** Community-acquired pneumonia complicated by rhabdomyolysis: A clinical analysis of 11 cases
Zhao B, Zheng R

Clinical Trials Study

- 4226** Dissection and ligation of the lateral circumflex femoral artery is not necessary when using the direct anterior approach for total hip arthroplasty
Zhao GY, Wang YJ, Xu NW, Liu F

Observational Study

- 4234** Expression of interleukin-32 in bone marrow of patients with myeloma and its prognostic significance
Wang G, Ning FY, Wang JH, Yan HM, Kong HW, Zhang YT, Shen Q

Randomized Controlled Trial

- 4245** Effect of different types of laryngeal mask airway placement on the right internal jugular vein: A prospective randomized controlled trial
Zhang JJ, Qu ZY, Hua Z, Zuo MZ, Zhang HY

SYSTEMATIC REVIEW

- 4254** Chronic pain, posttraumatic stress disorder, and opioid intake: A systematic review
López-Martínez AE, Reyes-Pérez Á, Serrano-Ibáñez ER, Esteve R, Ramírez-Maestre C

CASE REPORT

- 4270 Acute appendicitis in a patient after a uterus transplant: A case report
Kristek J, Kudla M, Chlupac J, Novotny R, Mirejovsky T, Janousek L, Fronek J
- 4277 Pneumococcal infection transmission between family members with congenital asplenia: A case report
Shibata J, Hiramatsu K, Kenzaka T, Kato T
- 4285 Successful treatment of warfarin-induced skin necrosis using oral rivaroxaban: A case report
Kamada M, Kenzaka T
- 4292 Simultaneous *Paragonimus* infection involving the breast and lung: A case report
Oh MY, Chu A, Park JH, Lee JY, Roh EY, Chai YJ, Hwang KT
- 4299 Isolated peritoneal lymphomatosis defined as post-transplant lymphoproliferative disorder after a liver transplant: A case report
Kim HB, Hong R, Na YS, Choi WY, Park SG, Lee HJ
- 4307 Three-dimensional image simulation of primary diaphragmatic hemangioma: A case report
Chu PY, Lin KH, Kao HL, Peng YJ, Huang TW
- 4314 Natural orifice specimen extraction with laparoscopic radical gastrectomy for distal gastric cancer: A case report
Sun P, Wang XS, Liu Q, Luan YS, Tian YT
- 4321 Huge brown tumor of the rib in an unlocatable hyperparathyroidism patient with “self-recovered” serum calcium and parathyroid hormone: A case report
Wang WD, Zhang N, Qu Q, He XD
- 4327 Percutaneous management of atrium and lung perforation: A case report
Zhou X, Ze F, Li D, Li XB
- 4334 Epstein-Barr virus-positive post-transplant lymphoproliferative disorder presenting as hematochezia and enterobrosis in renal transplant recipients in China: A report of two cases
Sun ZJ, Hu XP, Fan BH, Wang W
- 4342 Postoperative multidrug-resistant *Acinetobacter baumannii* meningitis successfully treated with intravenous doxycycline and intraventricular gentamicin: A case report
Wu X, Wang L, Ye YZ, Yu H
- 4349 Reconstruction of massive skin avulsion of the scrota and penis by combined application of dermal regeneration template (Pelnac) and split-thickness skin graft with vacuum-assisted closure: A case report
Fang JJ, Li PF, Wu JJ, Zhou HY, Xie LP, Lu H

- 4355** Multisystem smooth muscle dysfunction syndrome in a Chinese girl: A case report and review of the literature
Chen SN, Wang YQ, Hao CL, Lu YH, Jiang WJ, Gao CY, Wu M
- 4366** Kidney inflammatory myofibroblastic tumor masquerading as metastatic malignancy: A case report and literature review
Zhang GH, Guo XY, Liang GZ, Wang Q
- 4377** Hydroxychloroquine-induced renal phospholipidosis resembling Fabry disease in undifferentiated connective tissue disease: A case report
Wu SZ, Liang X, Geng J, Zhang MB, Xie N, Su XY
- 4384** Spontaneous ovarian hyperstimulation syndrome: Report of two cases
Gui J, Zhang J, Xu WM, Ming L
- 4391** Castleman disease in the hepatic-gastric space: A case report
Xu XY, Liu XQ, Du HW, Liu JH
- 4398** KIT and platelet-derived growth factor receptor α wild-type gastrointestinal stromal tumor associated with neurofibromatosis type 1: Two case reports
Kou YW, Zhang Y, Fu YP, Wang Z
- 4407** Treatment of severe upper gastrointestinal bleeding caused by Mallory-Weiss syndrome after primary coronary intervention for acute inferior wall myocardial infarction: A case report
Du BB, Wang XT, Li XD, Li PP, Chen WW, Li SM, Yang P
- 4414** Isolated elevated aspartate aminotransferase in an asymptomatic woman due to macro-aspartate aminotransferase: A case report
Zhan MR, Liu X, Zhang MY, Niu JQ
- 4420** Rehabilitation of anterior pituitary dysfunction combined with extrapontine myelinolysis: A case report
Yang MX, Chen XN

ABOUT COVER

Editorial Board Member of *World Journal of Clinical Cases*, Ashu Seith Bhalla, MD, Professor, Department of Radiodiagnosis, All India Institute of Medical Sciences, New Delhi 110029, India

AIMS AND SCOPE

The primary aim of *World Journal of Clinical Cases* (WJCC, *World J Clin Cases*) is to provide scholars and readers from various fields of clinical medicine with a platform to publish high-quality clinical research articles and communicate their research findings online.

WJCC mainly publishes articles reporting research results and findings obtained in the field of clinical medicine and covering a wide range of topics, including case control studies, retrospective cohort studies, retrospective studies, clinical trials studies, observational studies, prospective studies, randomized controlled trials, randomized clinical trials, systematic reviews, meta-analysis, and case reports.

INDEXING/ABSTRACTING

The WJCC is now indexed in PubMed, PubMed Central, Science Citation Index Expanded (also known as SciSearch®), and Journal Citation Reports/Science Edition. The 2019 Edition of Journal Citation Reports cites the 2018 impact factor for WJCC as 1.153 (5-year impact factor: N/A), ranking WJCC as 99 among 160 journals in Medicine, General and Internal (quartile in category Q3).

RESPONSIBLE EDITORS FOR THIS ISSUE

Responsible Electronic Editor: Ji-Hong Liu

Proofing Production Department Director: Yun-Xiaojuan Wu

NAME OF JOURNAL

World Journal of Clinical Cases

ISSN

ISSN 2307-8960 (online)

LAUNCH DATE

April 16, 2013

FREQUENCY

Semimonthly

EDITORS-IN-CHIEF

Dennis A Bloomfield, Bao-Gan Peng, Sandro Vento

EDITORIAL BOARD MEMBERS

<https://www.wjnet.com/2307-8960/editorialboard.htm>

EDITORIAL OFFICE

Jin-Lei Wang, Director

PUBLICATION DATE

December 26, 2019

COPYRIGHT

© 2019 Baishideng Publishing Group Inc

INSTRUCTIONS TO AUTHORS

<https://www.wjnet.com/bpg/gerinfo/204>

GUIDELINES FOR ETHICS DOCUMENTS

<https://www.wjnet.com/bpg/GerInfo/287>

GUIDELINES FOR NON-NATIVE SPEAKERS OF ENGLISH

<https://www.wjnet.com/bpg/gerinfo/240>

PUBLICATION MISCONDUCT

<https://www.wjnet.com/bpg/gerinfo/208>

ARTICLE PROCESSING CHARGE

<https://www.wjnet.com/bpg/gerinfo/242>

STEPS FOR SUBMITTING MANUSCRIPTS

<https://www.wjnet.com/bpg/GerInfo/239>

ONLINE SUBMISSION

<https://www.f6publishing.com>

Isolated elevated aspartate aminotransferase in an asymptomatic woman due to macro-aspartate aminotransferase: A case report

Meng-Ru Zhan, Xu Liu, Ming-Yuan Zhang, Jun-Qi Niu

ORCID number: Meng-Ru Zhan (0000-0002-2419-6859); Xu Liu (0000-0001-5312-0987); Ming-Yuan Zhang (0000-0003-0744-5945); Jun-Qi Niu (0000-0002-9857-6520).

Author contributions: Zhan MR contributed to the manuscript drafting and reviewed the literature; Liu X was responsible for the revision of the manuscript; Zhan MR and Zhang MY collected the patient's clinical data; Niu JQ designed the report and revised the manuscript; All authors issued final approval for the version to be submitted.

Informed consent statement: The study was reviewed and approved by the First Hospital of Jilin University Institutional Review Board. The patient and his family were offered written explanations prior to the start of treatment, and they provided consent.

Conflict-of-interest statement: The authors declare that they have no conflicts of interest.

CARE Checklist (2016) statement: The authors have read the CARE Checklist (2016), and the manuscript was prepared and revised according to the CARE Checklist (2016).

Open-Access: This article is an open-access article which was selected by an in-house editor and fully peer-reviewed by external reviewers. It is distributed in accordance with the Creative Commons Attribution Non Commercial (CC BY-NC 4.0) license, which permits others to distribute, remix, adapt, build

Meng-Ru Zhan, Xu Liu, Ming-Yuan Zhang, Jun-Qi Niu, Department of Hepatology, The First Hospital of Jilin University, Changchun 130021, Jilin Province, China

Corresponding author: Jun-Qi Niu, MD, PhD, Doctor, Professor, Research Scientist, Department of Hepatology, The First Hospital of Jilin University, No. 71, Xinmin Street, Changchun 130021, Jilin Province, China. junqiniu@aliyun.com
Telephone: +86-13756661205
Fax: +86-0431-88786006

Abstract

BACKGROUND

Macro-aspartate aminotransferase (AST), a macroenzyme, is a high-molecular mass complex formed by self-polymerization or association with other serum components that are difficult for the kidney to clear, leading to the isolated elevation of serum AST activity. Cases of macro-AST formation are rare, with only 3 published in the English language literature up to September 2019 in China. In this paper, we present a case in which an asymptomatic woman with persistent isolated elevated AST was confirmed as having macro-AST by the polyethylene glycol precipitation method.

CASE SUMMARY

A 34-year-old woman was referred to our clinic for elevated AST levels with normal levels of other liver-associated enzymes on November 12, 2018. Her AST level of liver function test had been abnormal for 7 mo before she came to the clinic. The patient was asymptomatic with a normal physical examination. There was no relevant family history and no alcohol consumption or smoking. She had a several-month history of traditional Chinese medical taking and had stopped it 1 year prior. The laboratory tests in our clinic showed only the elevation of AST (89.5 U/L) with no other significant abnormalities. We performed the precipitation technique with polyethylene glycol to confirm the presence of macro-AST. Then for almost a year, her AST level still fluctuated in the abnormal range.

CONCLUSION

This case highlights that clinical physicians should be familiar with this rare condition of persistent isolated AST elevation due to the presence of macro-AST to avoid unnecessary investigation and patient anxiety.

Key words: Aspartate aminotransferase; Macroenzymes; Macro-aspartate aminotransferase; Polyethylene glycol precipitation method; China; Case report

upon this work non-commercially, and license their derivative works on different terms, provided the original work is properly cited and the use is non-commercial. See: <http://creativecommons.org/licenses/by-nc/4.0/>

Manuscript source: Unsolicited manuscript

Received: September 24, 2019

Peer-review started: September 24, 2019

First decision: November 11, 2019

Revised: November 26, 2019

Accepted: November 30, 2019

Article in press: November 30, 2019

Published online: December 26, 2019

P-Reviewer: Sirin G, Tajiri K

S-Editor: Zhang L

L-Editor: Filipodia

E-Editor: Liu JH



©The Author(s) 2019. Published by Baishideng Publishing Group Inc. All rights reserved.

Core tip: Here, we present a case in which an asymptomatic woman with persistent isolated elevated aspartate aminotransferase was diagnosed as having macro-aspartate aminotransferase, which was confirmed by the polyethylene glycol method; only 3 such cases have been published in the English language literature up to September 2019 in China. It is necessary for physicians to be sufficiently familiar with this condition to avoid repeated unnecessary check-ups.

Citation: Zhan MR, Liu X, Zhang MY, Niu JQ. Isolated elevated aspartate aminotransferase in an asymptomatic woman due to macro-aspartate aminotransferase: A case report. *World J Clin Cases* 2019; 7(24): 4414-4419

URL: <https://www.wjgnet.com/2307-8960/full/v7/i24/4414.htm>

DOI: <https://dx.doi.org/10.12998/wjcc.v7.i24.4414>

INTRODUCTION

The elevation of liver enzymes is usually associated with liver injury, and both elevated aspartate aminotransferase (AST) and alanine aminotransferase are observed in most situations. However, the isolated elevation of AST with an unexplained cause can be found in some rare instances. At such cases time, the presence of macro-AST should be the one of suspected diagnoses. Macro-AST is a high molecular mass complex formed by AST with immunoglobulin or other plasma components^[1]. As a benign etiology of isolated AST elevation, it is often ignored in clinical practice, leading to costly, unnecessary, or even invasive tests before diagnosis. Macro-AST can be detected by gel filtration chromatography, ultracentrifugation and precipitation with polyethylene glycol (PEG) or simply storage at 4 °C^[2]. Here, we report a woman in China with persistent isolated elevated AST due to the presence of macro-AST.

CASE PRESENTATION

Chief complaints

A 34-year-old previously healthy woman was referred to our clinic with isolated elevated AST but had no symptoms on November 12, 2018.

History of present illness

The patient was an infertile woman who found her liver function abnormal after a health examination for *in vitro* fertilization 7 mo before she came to our clinic. The liver function indicated that the only abnormal result was isolated elevated AST ranging from 76.2 to 170 U/L (reference range 13-35 U/L) with other liver-associated enzymes at normal levels during the past 7 mo. She had taken liver protection drugs intermittently but they had no effect.

History of past illness

The patient had no significant medical history.

Personal and family history

She had a history of taking traditional Chinese medical for her infertility but had stopped 1 year prior. There was no relevant family history or alcohol consumption.

Physical examination upon admission

The physical examination of the patient showed no significant abnormality.

Laboratory examinations

The laboratory tests showed only the elevation of AST (89.5 U/L), with normal levels of the other liver function tests and enzymes: Alanine aminotransferase: 16.1 U/L (7.0-40.0), alkaline phosphatase 47.6 U/L (35.0-100.0), γ-glutamyl transpeptidase 12.6 U/L (7.0-45.0), bilirubin 9.4 μmol/L (6.8-30.0), and total protein 74.9 g/L (65.0-85.0). Serologic testing for viruses was negative and just anti-hepatitis B surface antibody was positive, with a titer of 1300.973 IU/L (the patient had been vaccinated against hepatitis B 3 years prior). Regarding the autoimmune aspect, we did not find

significant changes. Her ceruloplasmin, iron concentrations, and thyroid function test were also normal. The details and other laboratory data are shown in [Table 1](#).

Imaging examinations

The abdominal ultrasonography showed mild cholecystitis.

Further diagnostic work-up

We told the patient to stop taking so-called “liver protectors” and undergo regular reexaminations. During the following 7 mo, there was still a persistent elevation of AST ([Figure 1](#)), with normal values for the other liver function tests. Because of the lack of symptoms and lack of evidence of underlying causes such as liver, muscle, or cardiac disease, we suspected the diagnosis of macro-AST formation.

Hence, we decided to confirm the presence of macro-AST in our hospital laboratory by measuring whether AST activity decreased in the sample after PEG precipitation. For the study, we requested a new sample from the patient and used two serum samples from other patients with elevated AST as controls. We conducted the precipitation with PEG following a previously described method^[3,4]. The activity of AST dropped sharply to 1.4 U/L after the process ([Table 2](#)). After 2 mo, the patient had a reexamination of her liver function, which showed that the AST was still abnormal.

FINAL DIAGNOSIS

According to these results, we concluded that the isolated elevation of AST was most likely due to the presence of macro-AST.

TREATMENT

There is no specific treatment for the patient because macro-AST is generally a benign condition.

OUTCOME AND FOLLOW-UP

The patient remained healthy without any abnormalities, except for the isolated elevated AST.

DISCUSSION

Macroenzymes are serum high molecular weight compounds formed by complexes of enzymes and their polymerization products. The enzymes are usually linked to immunoglobulins (mainly Ig G and Ig M) or other plasma components, which make their clearance slower and more difficult *via* urine, and ultimately lead to higher levels of their activity^[3,5]. Macro-AST is one type of macroenzyme, which was first reported by Konttinen in 1978 in two healthy women^[6]. This gradually led to the recognition that macro-AST may be one of the causes of elevated serum AST levels.

Macro-AST is rare, and the exact prevalence rate in the general population is unknown. There have been reports that the prevalence rate of macro-AST was 0.014% in 7273 patients who visited one hospital, while the prevalence was 9.09% in patients with isolated increased AST activity without liver abnormalities^[4]. In addition, macro-AST seems to be more common in female patients < 60-years-old^[7,8], which is also a high-risk group for autoimmune diseases. As described in the previous literature, the mechanism of the immune complex formation may be due to autoimmunity. The immune reaction or the dysregulation of immune tolerance seems to be associated with immune complex formation^[9].

To the best of our knowledge, there are very few reports on macro-AST in China. Our patient is a female of child-bearing age who belongs to a high-risk group^[8]. The increased serum activities of AST usually result from liver, heart, skeletal muscle, and erythrocyte injury. Our patient had no evidence of hepatic disease, skeletal muscle disorders, myocardial disease, or hemolysis according to the evaluations with abdominal imaging studies and laboratory examinations. Therefore, after a literature review, the presence of benign macroenzymes became suspected in the absence of organ-specific disease. Ultimately, we performed an experiment with PEG that clearly demonstrated the presence of macro-AST. Prior to being referred to our clinic, our

Table 1 Laboratory data in the clinic

Parameter	Result (normal range)	Parameter	Result (normal range)
AST in U/L	89.5 (13.0-35.0)	WBC as $\times 10^9/L$	4.49 (3.5-9.5)
ALT in U/L	16.1 (7.0-40.0)	RBC as $\times 10^9/L$	4.22 (3.8-5.10)
GGT in IU/L	12.6 (7.0-45.0)	Hemoglobin in g/L	123 (115-150)
ALP in IU/L	47.6 (35.0-100.0)	Platelets as $\times 10^9/L$	187 (125-350)
ACHE in IU/L	7194 (4300-12000)	Neutrophils as $\times 10^9/L$	2.69 (1.80-6.30)
TP in g/L	74.9 (65.0-85.0)	Lymphocytes as $\times 10^9/L$	1.41 (1.10-3.20)
ALB in g/L	44.9 (40.0-55.0)	Monocytes as $\times 10^9/L$	0.32 (0.10-0.60)
GLB in g/L	30.0 (20.0-40.0)		
TBIL in $\mu\text{mol/L}$	9.4 (6.8-30.0)	CHOL in mmol/L	4.39 (2.6-6.0)
DBIL in $\mu\text{mol/L}$	2.8 (0.0-8.6)	TG in mmol/L	0.62 (0.28-1.80)
IBIL in $\mu\text{mol/L}$	6.6 (5.1-21.4)		
Enzyme parameter		Virology test	
CK in U/L	67 (40-200)	Anti-HAV-IgM	- (-)
CKMB in U/L	7.2 (0.0-25)	Anti-HEV-IgM	- (-)
LDH in U/L	161 (120-250)	HBsAg	- (-)
α -HBDH in U/L	116 (78.0-182.0)	Anti-HBsAb	+ (-)
MAO in U/L	3.4 (0.0-12.0)	HBeAg	- (-)
AFU in U/L	21 (3.0-40.0)	Anti-HBeAb	- (-)
AMY in U/L	90 (1-135)	Anti-HBcAb	- (-)
LPS in U/L	46 (5.6-51.3)	Anti-HBcAb	- (-)
		Anti-HCV	- (-)
Immunological test		Anti-HIV	- (-)
Anti-dsDNA	- (-)	Anti-TP	- (-)
Anti-M2	- (-)		
Anti-gp210	- (-)	Liver metabolism test	
Anti-SP100	- (-)	CER in g/L	0.28 (0.2-0.6)
Anti-SSA-52/Ro52	- (-)	SI in $\mu\text{mol/L}$	15.6 (7.8-32.2)
Anti-Sm	- (-)	SF in $\mu\text{mol/L}$	43.5 (10-120.0)
Anti-nRNP/Sm	- (-)	TIBC in $\mu\text{g/L}$	62.0 (50.0-70.0)
Anti-LKM	- (-)		
Immunoglobulin A in g/L	2.60 (0.7-4.0)		
Immunoglobulin G in g/L	15.1 (7.0-16.0)		
Immunoglobulin M in g/L	0.90 (0.4-2.3)		
Complement C3 in g/L	1.31 (0.9-1.8)		

AST: Aspartate aminotransferase; ALT: Alanine aminotransferase; GGT: γ -glutamyltransferase; ALP: Alkaline phosphatase; ACHE: Acetylcholinesterase; TP: Total protein; ALB: Albumin; GLB: Globulin; TBIL: Total bilirubin; DBIL: Direct bilirubin; IBIL: Indirect bilirubin; CK: Creatine kinase; CKMB: Creatine kinase isoenzymes; LDH: Lactate dehydrogenase; α -HBDH: α -Hydroxybutyrate Dehydrogenase; MAO: Monoamine oxidase; AFU: α -L-Fucosidase; AMY: Amylase; LPS: Lipase; Anti-dsDNA: Anti-double strand DNA antibody; Anti-M2: Antimitochondrial antibody 2; Anti-Sm: Anti-smooth muscle antibody; WBC: White blood cells; Anti-LKM: Anti liver and kidney microsomes antibody; WBC: White blood cell; RBC: Red blood cells; CHOL: Cholesterol; TG: Triglyceride; anti-HCV: Anti-hepatitis C virus antibody; anti-HIV: Anti-human immunodeficiency virus antibody; Anti-TP: Anti-Treponema pallidum; CER: Ceruloplasmin; SI: Serum iron; SF: Serum ferritin; TIBC: Total iron binding capacity.

patient underwent many repeated check-ups and was even advised to undergo a liver biopsy because elevated AST was observed. Moreover, she had been treated with various liver protective drugs that had no effect on her. She experienced significant psychological stress.

To date, whether macro-AST is related to disease is unsure and has attracted much attention. Although it has been reported that macroenzymes have been associated with various conditions, such as rheumatoid arthritis or other autoimmune conditions, allergen injection immunotherapy, monoclonal gammopathy, and chronic hepatitis C or possibly resolved acute hepatitis C^[10], the majority of reported cases are asymptomatic. There is a report that the AST activity of a young woman with macro-AST for 12 years fluctuated between 163 and 500 U/L but she still remained healthy^[8]. In addition, there have been 3 cases of macro-AST patients reported in China who remained healthy after 2-7 years of follow-up^[11]. Two studies in children with macro-

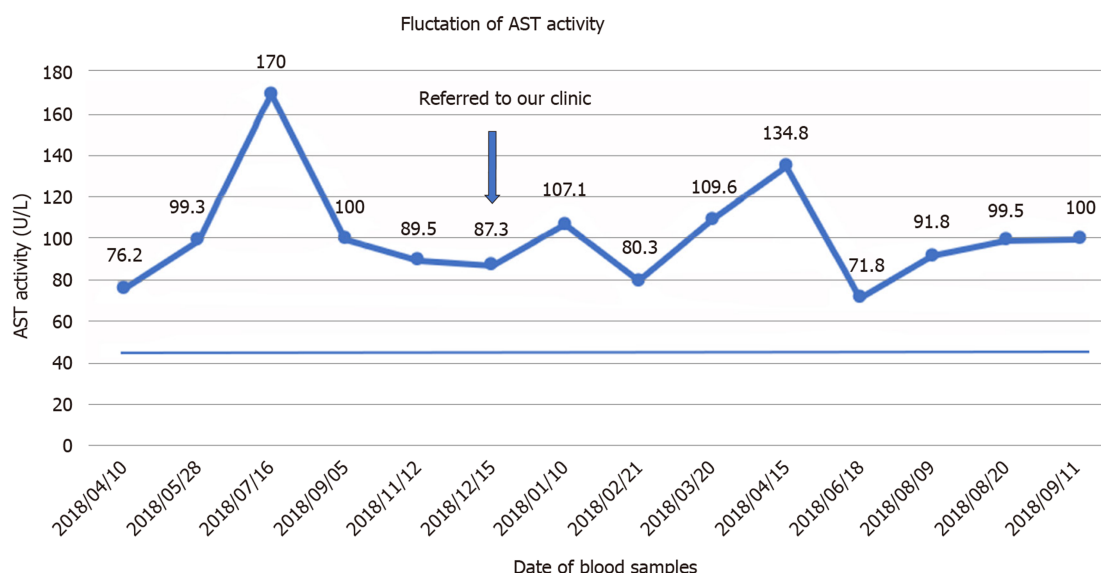


Figure 1 Changes in the patient's aspartate aminotransferase activity over a 17-mo period. The horizontal bar represents the upper limit of normal of aspartate aminotransferase (AST).

AST showed that all children remained healthy during long-term follow-up^[12], and these studies have shown that macro-AST is a benign condition that needs no further work-up. In addition, a study showed that familial isolated elevated AST may be associated with a heterozygous mutation in glutamate oxaloacetate transaminase 1^[13].

Macro-AST can be detected by multiple methods; the most common are precipitating the complexes of macroenzymes with PEG or simply storing the sample at 4 °C, which is convenient and economical, although two cases reported by Chtioui *et al*^[14] in 2010 and Maan *et al*^[15] in 2017 showed no significant decrease in AST levels after 1 wk of being stored at 4 °C. Ultracentrifugation and gel filtration chromatography, which constitute the standard reference method, require highly specialized chromatography, are complex and relatively expensive and are not available in most clinical laboratories. In the samples from our patient, we performed a precipitation technique with PEG to confirm the presence of macro-AST. After the patient's serum was treated with PEG, immunoglobulins precipitated out, revealing the lower free AST concentration. PEG precipitation confirmed the presence of macro-AST with 96.4% polyethylene glycol precipitable activity, which was significantly greater than in the controls.

CONCLUSION

In conclusion, although macro-AST is rare, clinicians and laboratories should consider macro-AST as a cause of unexplained isolated AST elevations if the patients are asymptomatic and other diseases causing an increase in AST have been excluded. A high index of suspicion may help reduce costs and patient anxiety before performing additional tests.

Table 2 Precipitation with polyethylene glycol

	AST origin	AST DIL1/2	AST PEG	PPA (%)	AST recovery (%)
Patient	71.8	38.9	1.4	96.4	3.60
Control 1	229	121.7	49.8	59.1	40.9
Control 2	68	31	17.7	42.9	57.1

Polyethylene glycol precipitation (PEG): 25% PEG centrifuged at 3000 rpm of two control serum samples and samples from the patient with macro-aspartate aminotransferase (AST). AST origin: AST value of the original serum; AST diluted 1/2 (DIL1/2): AST value of serum DIL1/2 with phosphate-buffered saline; AST PEG: AST value after PEG precipitation. PEG-precipitable activity (PPA) = $100 \times [(AST \text{ DIL1/2} - AST \text{ PEG}) / AST \text{ DIL1/2}]$; AST recovery = $100 \times (AST \text{ PEG} / AST \text{ DIL1/2})$.

REFERENCES

- Briani C, Zaninotto M, Forni M, Burra P. Macroenzymes: too often overlooked. *J Hepatol* 2003; **38**: 119 [PMID: 12480570 DOI: 10.1016/s0168-8278(02)00333-1]
- Davidson DF, Watson DJ. Macroenzyme detection by polyethylene glycol precipitation. *Ann Clin Biochem* 2003; **40**: 514-520 [PMID: 14503988 DOI: 10.1258/000456303322326425]
- González Raya A, Coca Zúñiga R, Martín Salido E. Isolated elevation of aspartate aminotransferase (AST) in an asymptomatic patient due to macro-AST. *J Clin Lab Anal* 2019; **33**: e22690 [PMID: 30320474 DOI: 10.1002/jcla.22690]
- Patteet L, Simoens M, Piqueur M, Wauters A. Laboratory detection of macro-aspartate aminotransferase: case report and evaluation of the PEG-precipitation method. *Clin Biochem* 2012; **45**: 691-693 [PMID: 22429521 DOI: 10.1016/j.clinbiochem.2012.03.004]
- Luk KHK, Hui YT, Lam JTW, Lai KY. Macro-aspartate aminotransferase is a possible cause of persistent isolated elevated aspartate aminotransferase level. *Hong Kong Med J* 2019; **25**: 337-338 [PMID: 31416998 DOI: 10.12809/hkmj187566]
- Kontinen A, Murros J, Ojala K, Salaspuro M, Somer H, Räsänen J. A new cause of increased serum aspartate aminotransferase activity. *Clin Chim Acta* 1978; **84**: 145-147 [PMID: 639298 DOI: 10.1016/0009-8981(78)90487-4]
- Mrosewski I, Bredlau B, Öztürk Y, Switkowski R. Persistent Isolated Elevation of Aspartate Aminotransferase in an Asymptomatic Female Patient: a Case Report and Review of Current Literature. *Clin Lab* 2019; **65** [PMID: 31414761 DOI: 10.7754/Clin.Lab.2019.190205]
- Orlando R, Carbone A, Lirussi F. Macro-aspartate aminotransferase (macro-AST). A 12-year follow-up study in a young female. *Eur J Gastroenterol Hepatol* 2003; **15**: 1371-1373 [PMID: 14624163 DOI: 10.1097/00042737-200312000-00018]
- Triester SL, Douglas DD. Development of macro-aspartate aminotransferase in a patient undergoing specific allergen injection immunotherapy. *Am J Gastroenterol* 2005; **100**: 243-245 [PMID: 15654805 DOI: 10.1111/j.1572-0241.2005.41284.x]
- Lee M, Vajro P, Keffe EB. Isolated aspartate aminotransferase elevation: think macro-AST. *Dig Dis Sci* 2011; **56**: 311-313 [PMID: 21246276 DOI: 10.1007/s10620-011-1575-4]
- Yu Z, Wang Y, Feng L, Jia J. Macro-aspartate aminotransferase: two-year follow-up of three patients in China. *Dig Dis Sci* 2014; **59**: 224-226 [PMID: 24026404 DOI: 10.1007/s10620-013-2856-x]
- Caropreso M, Fortunato G, Lenta S, Palmieri D, Esposito M, Vitale DF, Iorio R, Vajro P. Prevalence and long-term course of macro-aspartate aminotransferase in children. *J Pediatr* 2009; **154**: 744-748 [PMID: 19111320 DOI: 10.1016/j.jpeds.2008.11.010]
- Kulecka M, Wierzbicka A, Paziewska A, Mikula M, Habior A, Janczyk W, Dabrowska M, Karczmarski J, Lazniewski M, Ginalski K, Czlonkowska A, Socha P, Ostrowski J. A heterozygous mutation in GOT1 is associated with familial macro-aspartate aminotransferase. *J Hepatol* 2017; **67**: 1026-1030 [PMID: 28716744 DOI: 10.1016/j.jhep.2017.07.003]
- Chtioui H, Mauerhofer O, Günther B, Dufour JF. Macro-AST in an asymptomatic young patient. *Ann Hepatol* 2010; **9**: 93-95 [PMID: 20308729]
- Maan W, Warsi AQ, Rashed A, Karjoo M. Unexplained High Activity of Aspartate Aminotransferase in an Asymptomatic Pediatric Patient. *Int J Pediatr* 2017; **5**: 5805-5808 [DOI: 10.22038/ijp.2017.25420.2162]



Published By Baishideng Publishing Group Inc
7041 Koll Center Parkway, Suite 160, Pleasanton, CA 94566, USA
Telephone: +1-925-2238242
E-mail: bpgoffice@wjgnet.com
Help Desk: <https://www.f6publishing.com/helpdesk>
<https://www.wjgnet.com>

