

World Journal of *Clinical Cases*

World J Clin Cases 2020 July 26; 8(14): 2893-3135



Contents

Semimonthly Volume 8 Number 14 July 26, 2020

EXPERT RECOMMENDATIONS

- 2893 Recommendations for perinatal and neonatal surgical management during the COVID-19 pandemic
Ma LS, Zhao YL, Wei YD, Liu C

MINIREVIEWS

- 2902 Clinical applicability of gastroscopy with narrow-band imaging for the diagnosis of *Helicobacter pylori* gastritis, precancerous gastric lesion, and neoplasia
Cho JH, Jeon SR, Jin SY

ORIGINAL ARTICLE

Clinical and Translational Research

- 2917 Identification of APEX2 as an oncogene in liver cancer
Zheng R, Zhu HL, Hu BR, Ruan XJ, Cai HJ

Retrospective Cohort Study

- 2930 Restenosis after recanalization for Budd-Chiari syndrome: Management and long-term results of 60 patients
Zhang W, Tian YL, Wang QZ, Chen XW, Li QY, Han JH, Chen XD, Xu K

Retrospective Study

- 2942 Comparison of microendoscopic discectomy and open discectomy for single-segment lumbar disc herniation
Pang JY, Tan F, Chen WW, Li CH, Dou SP, Guo JR, Zhao LY
- 2950 Clinical characteristics of patients with COVID-19 presenting with gastrointestinal symptoms as initial symptoms: Retrospective case series
Yang TY, Li YC, Wang SC, Dai QQ, Jiang XS, Zuo S, Jia L, Zheng JB, Wang HL

Observational Study

- 2959 Effects of policies and containment measures on control of COVID-19 epidemic in Chongqing
Liang XH, Tang X, Luo YT, Zhang M, Feng ZP
- 2977 Role of shear wave elastography in the evaluation of the treatment and prognosis of supraspinatus tendinitis
Zhou J, Yang DB, Wang J, Li HZ, Wang YC
- 2988 Endoscopic retrograde cholangiopancreatography in elderly patients: Difficult cannulation and adverse events
Tabak F, Wang HS, Li QP, Ge XX, Wang F, Ji GZ, Miao L

- 3000** Diagnostic value of orbicularis oculi muscle electromyography in functional epiphora

Lu H, Liu PD, Yao X, Wang ZF, Gao LF, Wang SP

META-ANALYSIS

- 3006** Diagnostic value of liquid-based cytology and smear cytology in pancreatic endoscopic ultrasound-guided fine needle aspiration: A meta-analysis

Pan HH, Zhou XX, Zhao F, Chen HY, Zhang Y

SCIENTOMETRICS

- 3021** Bibliometric analysis of randomized controlled trials of colorectal cancer over the last decade

Wang CY, Zhou SC, Li XW, Li BH, Zhang JJ, Ge Z, Zhang Q, Hu JH

CASE REPORT

- 3031** Spontaneous pneumothorax in a single lung transplant recipient-a blessing in disguise: A case report

Deshwal H, Ghosh S, Hogan K, Akindipe O, Lane CR, Mehta AC

- 3039** Endoscopic third ventriculostomy in obstructive hydrocephalus: A case report and analysis of operative technique

Munda M, Spazzapan P, Bosnjak R, Velnar T

- 3050** Underwater endoscopic mucosal resection for neoplasms in the pyloric ring of the stomach: Four case reports

Kim DH, Park SY, Park CH, Kim HS, Choi SK

- 3057** Successful treatment of basaloid squamous cell carcinoma in the rectosigmoid colon: A case report and review of literature

Lee TG, Yoon SM, Kim MJ

- 3064** Synchronous sporadic bilateral multiple chromophobe renal cell carcinoma accompanied by a clear cell carcinoma and a cyst: A case report

Yang F, Zhao ZC, Hu AJ, Sun PF, Zhang B, Yu MC, Wang J

- 3074** Intra-abdominal hemorrhage during pregnancy: Four case reports

Yang L, Liu N, Long Y

- 3082** Pulmonary benign metastasizing leiomyoma: A case report and review of the literature

Dai HY, Guo SL, Shen J, Yang L

- 3090** Mucoepidermoid carcinoma in the infratemporal fossa: A case report

Zhang HY, Yang HY

- 3097** Intra-abdominal inflammatory pseudotumor-like follicular dendritic cell sarcoma associated with paraneoplastic pemphigus: A case report and review of the literature

Zhuang JY, Zhang FF, Li QW, Chen YF

- 3108** Multiple recurrent cystic echinococcosis with abdominal aortic involvement: A case report
Taxifulati N, Yang XA, Zhang XF, Aini A, Abulizi A, Ma X, Abulati A, Wang F, Xu K, Aji T, Shao YM, Ahan A
- 3114** Dental focal infection-induced ventricular and spinal canal empyema: A case report
Xue H, Wang XH, Shi L, Wei Q, Zhang YM, Yang HF
- 3122** Effect of chidamide on treating hepatosplenic T-cell lymphoma: A case report
Wang XT, Guo W, Sun M, Han W, Du ZH, Wang XX, Du BB, Bai O
- 3130** Acute esophageal obstruction caused by reverse migration of gastric bezoars: A case report
Zhang FH, Ding XP, Zhang JH, Miao LS, Bai LY, Ge HL, Zhou YN

ABOUT COVER

Editorial Board Member of *World Journal of Clinical Cases*, Dr. Iva Brčić finished medical studies at the Medical University of Graz and received her MD degree in 2003. She received her doctoral degree in 2006 at the same institution. In 2007, she enrolled in the pathology residency program at the University Hospital Center Zagreb. In 2012, she passed her board exam and, until 2015, worked as a staff pathologist at the University Hospital Center Zagreb. From 2015, she is working as the University Assistant at the Medical University of Graz. At the end of 2017, she joined the bone and soft tissue team and spent 4-mo observership at the University of Miami, FL, USA. Her ongoing research interests include bone and soft tissue neoplasms.

AIMS AND SCOPE

The primary aim of *World Journal of Clinical Cases* (*WJCC*, *World J Clin Cases*) is to provide scholars and readers from various fields of clinical medicine with a platform to publish high-quality clinical research articles and communicate their research findings online.

WJCC mainly publishes articles reporting research results and findings obtained in the field of clinical medicine and covering a wide range of topics, including case control studies, retrospective cohort studies, retrospective studies, clinical trials studies, observational studies, prospective studies, randomized controlled trials, randomized clinical trials, systematic reviews, meta-analysis, and case reports.

INDEXING/ABSTRACTING

The *WJCC* is now indexed in Science Citation Index Expanded (also known as SciSearch®), Journal Citation Reports/Science Edition, PubMed, and PubMed Central. The 2020 Edition of Journal Citation Reports® cites the 2019 impact factor (IF) for *WJCC* as 1.013; IF without journal self cites: 0.991; Ranking: 120 among 165 journals in medicine, general and internal; and Quartile category: Q3.

RESPONSIBLE EDITORS FOR THIS ISSUE

Electronic Editor: Ji-Hong Liu, Production Department Director: Xiang Li, Editorial Office Director: Jin-Lai Wang.

NAME OF JOURNAL

World Journal of Clinical Cases

ISSN

ISSN 2307-8960 (online)

LAUNCH DATE

April 16, 2013

FREQUENCY

Semimonthly

EDITORS-IN-CHIEF

Dennis A Bloomfield, Sandro Vento, Bao-Gan Peng

EDITORIAL BOARD MEMBERS

<https://www.wjgnet.com/2307-8960/editorialboard.htm>

PUBLICATION DATE

July 26, 2020

COPYRIGHT

© 2020 Baishideng Publishing Group Inc

INSTRUCTIONS TO AUTHORS

<https://www.wjgnet.com/bpg/gerinfo/204>

GUIDELINES FOR ETHICS DOCUMENTS

<https://www.wjgnet.com/bpg/GerInfo/287>

GUIDELINES FOR NON-NATIVE SPEAKERS OF ENGLISH

<https://www.wjgnet.com/bpg/gerinfo/240>

PUBLICATION ETHICS

<https://www.wjgnet.com/bpg/GerInfo/288>

PUBLICATION MISCONDUCT

<https://www.wjgnet.com/bpg/gerinfo/208>

ARTICLE PROCESSING CHARGE

<https://www.wjgnet.com/bpg/gerinfo/242>

STEPS FOR SUBMITTING MANUSCRIPTS

<https://www.wjgnet.com/bpg/GerInfo/239>

ONLINE SUBMISSION

<https://www.f6publishing.com>



Observational Study

Diagnostic value of orbicularis oculi muscle electromyography in functional epiphora

Hui Lu, Pei-Dong Liu, Xue Yao, Zuo-Fen Wang, Li-Fen Gao, Shao-Peng Wang

ORCID number: Hui Lu 0000-0002-4379-2525; Pei-Dong Liu 0000-0002-7111-3374; Xue Yao 0000-0002-8406-3644; Zuo-Fen Wang 0000-0002-6670-4890; Li-Fen Gao 0000-0003-0572-668x; Shao-Peng Wang 0000-0003-0043-2463.

Author contributions: Lu H wrote the manuscript; Liu PD and Yao X were the patient's operators; Wang ZF and Gao LF reviewed the literature and contributed to manuscript drafting; Wang SP was responsible for revision of the manuscript for important intellectual content and contributed to diagnosis; all authors issued final approval for the version to be submitted.

Institutional review board

statement: This study was reviewed and approved by the Science and Research Office of Zibo Central Hospital.

Informed consent statement:

Informed written consent was obtained from the patients for publication of this report and any accompanying images.

Conflict-of-interest statement:

There are no conflicts of interest to report.

Data sharing statement: No

additional data are available.

Hui Lu, Xue Yao, Zuo-Fen Wang, Li-Fen Gao, Shao-Peng Wang, Department of Ophthalmology, Zibo Central Hospital, Zibo 255000, Shandong Province, China

Pei-Dong Liu, Department of Electromyography, Zibo Central Hospital, Zibo 255000, Shandong Province, China

Corresponding author: Shao-Peng Wang, MD, Doctor, Department of Ophthalmology, Zibo Central Hospital, No. 54, Gongqingtuanxi Road, Zhangdian District, Zibo 255000, Shandong Province, China. 904268100@qq.com

Abstract

BACKGROUND

Functional epiphora is a clinical condition which is not due to an anatomic defect. Most studies agree that it involves the action of the orbicularis oculi muscle, particularly its deeper segment (Horner's muscle), but the exact mechanism is not clear.

AIM

To evaluate the orbicularis oculi muscle in functional epiphora patients using electromyography (EMG).

METHODS

A total of 8 Chinese patients (16 eyes) with functional epiphora were enrolled in this study, and ten volunteers (10 eyes) were included as normal controls. Five epiphora patients (five eyes) with facial palsy served as positive controls. Quantitative EMG was performed in the deeper segment of orbicularis oculi muscle. The average duration of each EMG waveform was measured.

RESULTS

The average duration of EMG waveforms in the normal control group, the functional epiphora group, and the facial palsy group were 6.39 ± 0.73 ms, 9.39 ± 1.32 ms and 11.2 ± 1.42 ms, respectively. The duration of EMG waveforms was significantly longer in the functional epiphora group than in the normal control group ($P < 0.05$), and shorter than that in the facial palsy group ($P < 0.05$).

CONCLUSION

These data indicate the presence of neurogenic orbicularis oculi muscle damage in

STROBE statement: The authors have read the STROBE Statement checklist of items, and the manuscript was prepared and revised according to the STROBE Statement checklist of items.

Open-Access: This article is an open-access article that was selected by an in-house editor and fully peer-reviewed by external reviewers. It is distributed in accordance with the Creative Commons Attribution NonCommercial (CC BY-NC 4.0) license, which permits others to distribute, remix, adapt, build upon this work non-commercially, and license their derivative works on different terms, provided the original work is properly cited and the use is non-commercial. See: <http://creativecommons.org/licenses/by-nc/4.0/>

Manuscript source: Invited manuscript

Received: November 21, 2019

Peer-review started: February 25, 2019

First decision: April 8, 2020

Revised: May 12, 2020

Accepted: June 20, 2020

Article in press: June 20, 2020

Published online: July 26, 2020

P-Reviewer: Vaudo G

S-Editor: Liu M

L-Editor: Webster JR

E-Editor: Liu JH



epiphora patients, which may be the cause of functional epiphora. The etiology of neurogenic damage in the orbicularis oculi muscle requires further investigation.

Key words: Functional epiphora; Electromyography; Orbicularis oculi muscle; Neurological damage; Etiology; Treatment

©The Author(s) 2020. Published by Baishideng Publishing Group Inc. All rights reserved.

Core tip: Functional epiphora is a clinical condition which is not due to an anatomic defect, and the cause of functional epiphora is not very clear. In this study, we used electromyography as a valuable tool to evaluate the orbicularis oculi muscle, and the results suggest neurogenic muscle motor neuron disease in functional epiphora patients. This study reveals a possible new approach for the treatment of functional epiphora.

Citation: Lu H, Liu PD, Yao X, Wang ZF, Gao LF, Wang SP. Diagnostic value of orbicularis oculi muscle electromyography in functional epiphora. *World J Clin Cases* 2020; 8(14): 3000-3005

URL: <https://www.wjgnet.com/2307-8960/full/v8/i14/3000.htm>

DOI: <https://dx.doi.org/10.12998/wjcc.v8.i14.3000>

INTRODUCTION

Epiphora is a bothersome clinical condition, which may require extensive diagnostic efforts. The patient's history and/or clinical signs, which may include lacrimal hypersecretion, canalicular (presac) obstruction or stenosis, nasolacrimal (postsac) obstruction or stenosis, or even a functional (nonanatomic) defect, which might be due to "lacrimal pump" failure, can provide critical information in identifying this disorder^[1]. Functional epiphora is a clinical condition which is not due to an anatomic defect, and the cause of functional epiphora is not very clear^[2,3]. Although some controversy exists concerning the exact mechanism of functional epiphora, most studies agree that it involves the action of the orbicularis oculi muscle, particularly its deeper segment (Horner's muscle), which inserts on the lacrimal sac.

Electromyography (EMG) is a supplement to clinical examination, which can distinguish myopathic from neurogenic muscle wasting and weakness. To determine the etiology of muscle weakness in functional epiphora, we used EMG to evaluate the orbicularis oculi muscle, in order to provide an approach for the diagnosis of functional epiphora.

MATERIALS AND METHODS

Subjects

A total 8 Chinese patients (16 eyes) with functional epiphora were included in this study, 3 males and 5 females aged between 48-68 years, with a mean age of 62.5 years. Five epiphora patients (five eyes) with facial palsy served as positive controls, including 2 males and 3 females aged between 50-70 years, with a mean age of 59.0 years. Patients with chronic lacrimal canaliculitis, previous lacrimal canalicular laceration, congenital absence of lacrimal puncta and canaliculi, or canalicular mass were excluded from the study. Ten volunteers (10 eyes), with a mean age of 62.2 years, without any eye diseases or epiphora symptoms were included in this study as normal controls (Table 1). This study complied with the Declaration of Helsinki and was approved by the Ethics Committee of the Zibo Central Hospital. All subjects gave written informed consent.

Methods

The patency and caliber of the lacrimal puncta was assessed by slit lamp biomicroscopy. Drainage to the ipsilateral nasal cavity was assessed by probing the canalicular system. Quantitative EMG of the orbicularis oculi muscle was performed. EMG response was recorded by a disposable concentric facial EMG needle electrode^[4]

Table 1 Clinical characteristics of the study patients

	Normal control group	Functional epiphora group	Facial palsy group
Age, yr	62.2 ± 7.8	62.5 ± 8	59.0 ± 6.5
Male/female	4/6	3/5	2/3
Subjects (eyes)	10 (10)	8 (16)	5 (5)
Duration of EMG (ms)	6.39 ± 0.73	9.14 ± 1.32	11.0 ± 1.41

EMG: Electromyography.

(25 mm × 0.33 mm, 30G, Alpine Biomed), which was inserted into Horner's muscle (**Figure 1**), while the muscle was maintained under slight voluntary contraction. The parameters of the motor unit potential were measured by isolating the discharge of single motor units as achieved by triggering and delaying their display^[5-7]. The duration of motor unit potentials was measured. Filter settings were set from 1000 Hz–10000 Hz.

Statistical analysis

For each eye, the mean duration of the EMG waveform was used in the calculations, and measurements were available from left and right sides. A one-way ANOVA was used to compare the average duration of the EMG waveform in the normal control group, functional epiphora group and the facial palsy group. A *P* value ≤ 0.05 was considered statistically significant.

RESULTS

EMG waveforms in the normal control group, the functional epiphora group and the facial palsy group are shown in **Figure 2**. The average duration of each EMG waveform was measured. The average duration of each action potential was calculated from 7–10 different action potentials. Our data showed that the average duration of the EMG waveform was 6.39 ± 0.73 ms, 9.39 ± 1.32 ms and 11.2 ± 1.42 ms in the control group, the functional epiphora group and the facial palsy group, respectively. The duration of EMG waveforms in the functional epiphora group and facial palsy group were significantly longer than those in the normal control group (*P* < 0.05), indicating the presence of neurological damage in functional epiphora patients (**Figure 3**).

DISCUSSION

Epiphora may present as a watery (usually due to punctual or canalicular causes) or mucous (the so called “sticky eye”) condition^[8,9]. Watery epiphora can significantly affect the patient's quality of life and may be more difficult to treat than mucopurulent discharge^[2]. However, the exact reasons underlying epiphora remain unclear. According to Jone's theory, contraction of Horner's muscle may cause expansion of the sac and creation of a negative pressure resulting in tear suction^[8-10]. Alternatively, the Rosengren Doane theory postulates that the elastic expansion of the lacrimal papillae that occurs upon eyelid opening aspirates tears into the sac and the subsequent contraction of the orbicularis oculi creates a positive pressure gradient that may drive tears along the nasolacrimal duct into the nose^[8-10].

The causes of muscle wasting and weakness can be divided into myopathic and neurogenic mechanisms, which can be distinguished by EMG. EMG represents an obligatory tool for assessing myopathic from neurogenic muscle motor neuron disease to demonstrate the widespread denervation and fasciculation required for a comprehensive diagnosis. EMG can detect abnormalities such as chronic denervation or fasciculation, which may not be apparent in clinically normal muscle. Isolating the discharge of single motor units as achieved by triggering and delaying their display, enables parameters of the motor unit potential to be measured. Amplitude and duration were measured, and these motor unit parameters varied with the muscle examined. Chronic re-innervation was associated with long duration motor unit potentials with a normal number of phases. Generally, the amplitude of motor unit

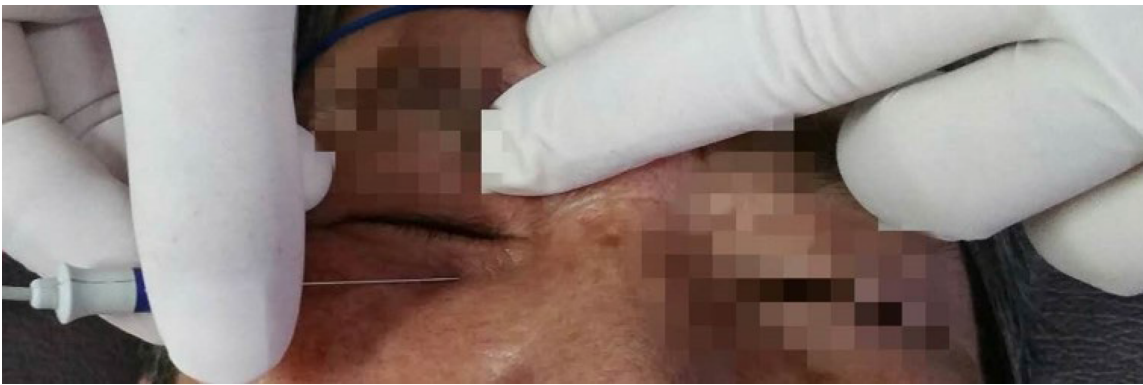

Figure 1 Electromyography of the orbicularis oculi muscle: A disposable concentric facial electromyography needle electrode was inserted into Horner's muscle.

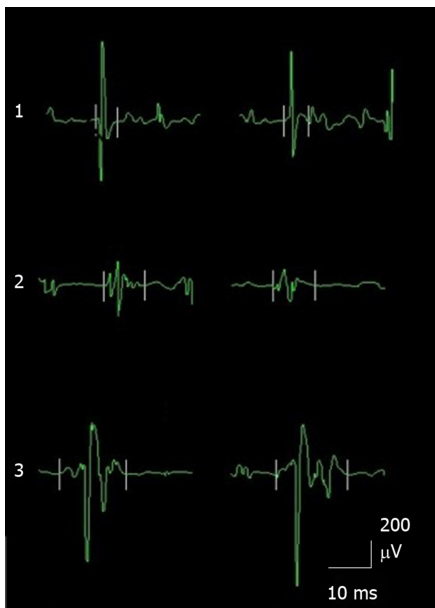

Figure 2 The electromyography waveforms in the subjects. The time between the two vertical white bars is the duration of the electromyography waveform. 1: The normal control group; 2: The functional epiphora group; 3: The facial palsy group. The bar represents 10 ms.

potentials was less than 2 mV, and the durations were 10–5 ms with 3–4 phases. Intramuscular sprouting and re-innervation can occur in chronic partial denervation, and the amplitudes might be 10–20 mV and durations might increase to 20–30 ms. In primary muscle disease, only slight motor unit amplitude potentials of short duration were observed; typical amplitude and duration values would be 0.5 mV and 5–10 ms, respectively^[11].

A recent study revealed that EMG of the orbicularis oculi muscle is very sensitive in patients with ptosis^[12]. In this study, we used EMG to evaluate Horner's muscle and its relation to functional epiphora. Amplitude and duration were measured, and these motor unit parameters varied with the muscle examined. In general, high amplitude and long duration motor unit potentials with a normal number of phases in EMG suggest chronic re-innervation. Facial palsy is definitely a neurogenic muscle motor neuron disease; therefore, we included facial palsy patients as positive controls in this study. The results demonstrated that the duration of the EMG waveform in the facial palsy patients was significantly longer than that in the normal controls. Consistent with the data from the functional epiphora patients, the duration of the EMG waveform was significantly longer than that in the normal controls, which suggested that chronic denervation in the orbicularis oculi muscle, particularly in the lower segment (Horner's muscle) may contribute to this condition. It is noteworthy that the extent of increase in the duration of the EMG waveform in the facial palsy patients was more significant as compared to that in the functional epiphora patients, and this may be due to a different degree of neurogenic muscle motor neuron disease.

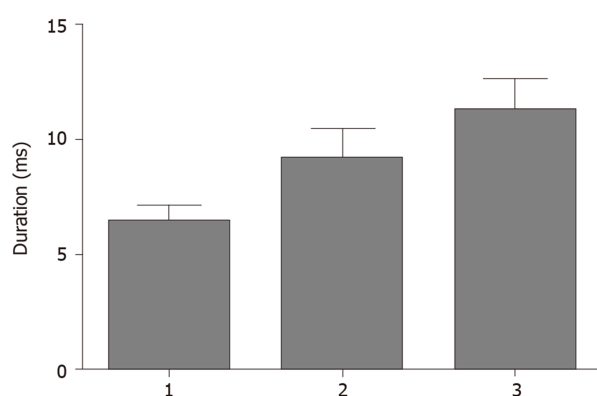


Figure 3 The duration of the electromyography waveform in the different groups. The durations in group 2 and group 3 were significantly longer than that in group 1 ($P < 0.05$). 1: The normal control group; 2: The functional epiphora group; 3: The facial palsy group.

Thus, longer duration might mean chronic partial denervation, which suggests neurogenic muscle motor neuron disease in the functional epiphora patients, which might help us to treat functional epiphora in another way.

According to previous studies, lacrimal scintigraphy, can identify treatment strategies for functionally acquired epiphora^[13,14]. For example, a horizontal shortening of the lower eyelid may be present which can then augment the action of the lacrimal “pump” (as lower eyelid laxity has been associated with decreased lacrimal pump function^[13]). However, if the cause of functional epiphora is chronic denervation in the orbicularis oculi muscle, lacrimal scintigraphy may not be good enough to identify treatment strategies for this disease.

In addition, the cross-sectional study method used should be taken into account, the small number of patients included in the study and the lack of a control group for analysis of treatment decision specificity, require further investigation. Our results revealed that EMG of the orbicularis oculi muscle is a valuable tool for identifying treatment approaches for functional epiphora. The etiology of neurogenic damage in the orbicularis oculi muscle requires further investigation.

ARTICLE HIGHLIGHTS

Research background

Functional epiphora is a clinical condition which is not due to an anatomic defect, and the exact causes of epiphora remain unclear. In this study, we used electromyography (EMG) to evaluate the orbicularis oculi muscle, and the results suggested neurogenic muscle motor neuron disease in functional epiphora patients.

Research motivation

Most studies agree that functional epiphora involves the action of the orbicularis oculi muscle, particularly its deeper segment (Horner’s muscle), but the exact mechanism is not clear. In this study, we used EMG to evaluate Horner’s muscle and its relation to functional epiphora, which may provide a new way to evaluate orbicularis oculi muscle-related disease.

Research objectives

The objective of this study was to evaluate the orbicularis oculi muscle in functional epiphora patients using EMG. The data indicated the presence of neurogenic orbicularis oculi muscle damage in epiphora patients, which might be the cause of functional epiphora.

Research methods

Three groups were included in this study: Functional epiphora, normal controls and facial palsy patients who served as positive controls. Quantitative EMG was performed in the deeper segment of the orbicularis oculi muscle. The average duration of each EMG waveform was measured. A one-way ANOVA was used to compare the average duration of the EMG waveform in the three groups. A P value ≤ 0.05 was

considered statistically significant.

Research results

The duration of EMG waveforms in the functional epiphora group and facial palsy group were significantly longer than those in the normal control group ($P < 0.05$), indicating the presence of neurological damage in functional epiphora patients. The small number of patients included in the study and the lack of a control group for analysis of treatment decision specificity, require further investigation.

Research conclusions

The cause of functional epiphora is not clear; however, orbicularis oculi muscle weakness might be related to functional epiphora. To determine the etiology of muscle weakness in functional epiphora, we used EMG to evaluate the orbicularis oculi muscle, in order to provide an approach for the diagnosis of functional epiphora. EMG was a valuable tool in evaluating the orbicularis oculi muscle, and the results suggest the presence of neurogenic muscle motor neuron disease in functional epiphora patients, which might help us to treat functional epiphora in another way.

Research perspectives

EMG of the orbicularis oculi muscle is a valuable tool for identifying treatment approaches for functional epiphora. The etiology of neurogenic damage in the orbicularis oculi muscle requires further investigation.

ACKNOWLEDGEMENTS

The authors would like to thank the members of the Department of Ophthalmology, Zibo Central Hospital.

REFERENCES

- 1 Amrith S, Goh PS, Wang SC. Tear flow dynamics in the human nasolacrimal ducts--a pilot study using dynamic magnetic resonance imaging. *Graefes Arch Clin Exp Ophthalmol* 2005; **243**: 127-131 [PMID: 15742210 DOI: 10.1007/s00417-004-1045-1]
- 2 Detorakis ET, Drakonaki E, Papadaki E, Pallikaris IG, Tsilimbaris MK. Watery eye following patent external DCR: an MR dacryocystography study. *Orbit* 2010; **29**: 239-243 [PMID: 20812828 DOI: 10.3109/01676831003660697]
- 3 O'Donnell B, Shah R. Dacryocystorhinostomy for epiphora in the presence of a patent lacrimal system. *Clin Exp Ophthalmol* 2001; **29**: 27-29 [PMID: 11272781 DOI: 10.1046/j.1442-9071.2001.00366.x]
- 4 Stålberg EV, Sanders DB. Jitter recordings with concentric needle electrodes. *Muscle Nerve* 2009; **40**: 331-339 [PMID: 19705424 DOI: 10.1002/mus.21424]
- 5 Sanders DB, Stålberg EV. AAEM minimonograph #25: single-fiber electromyography. *Muscle Nerve* 1996; **19**: 1069-1083 [PMID: 8761262 DOI: 10.1002/(SICI)1097-4598(199609)19:9<1069::AID-MUS1>3.0.CO;2-Y]
- 6 Kouyoumdjian JA, Stålberg EV. Reference jitter values for concentric needle electrodes in voluntarily activated extensor digitorum communis and orbicularis oculi muscles. *Muscle Nerve* 2008; **37**: 694-699 [PMID: 18506720 DOI: 10.1002/mus.21043]
- 7 Sarriani PG, Kennett RP, Read S, Farrugia ME. Single-fiber EMG with a concentric needle electrode: validation in myasthenia gravis. *Muscle Nerve* 2006; **33**: 61-65 [PMID: 16175626 DOI: 10.1002/mus.20435]
- 8 Wesley RE. Lacrimal disease. *Curr Opin Ophthalmol* 1994; **5**: 78-83 [PMID: 10150821]
- 9 Hurwitz JJ, Cooper PR, McRae DL, Chenoweth DR. The investigation of epiphora. *Can J Ophthalmol* 1977; **12**: 196-198 [PMID: 890589]
- 10 Nesi FA, Waltz KL, Vega J. Basic principles of ophthalmic plastic surgery. In: Nesi FA, Lisman RD, Levine MR, editor. *Smith's Ophthalmic Plastic and Reconstructive Surgery*. Nesi FA, Lisman RD, Levine MR. St. Louis: Mosby, 1998: 81-98
- 11 Mills KR. The basics of electromyography. *J Neurol Neurosurg Psychiatry* 2005; **76** Suppl 2: ii32-ii35 [PMID: 15961866 DOI: 10.1136/jnnp.2005.069211]
- 12 Giannoccaro MP, Di Stasi V, Zanesini C, Donadio V, Avoni P, Liguori R. Sensitivity and specificity of single-fibre EMG in the diagnosis of ocular myasthenia varies accordingly to clinical presentation. *J Neurol* 2020; **267**: 739-745 [PMID: 31734908 DOI: 10.1007/s00415-019-09631-3]
- 13 Guzek JP, Ching AS, Hoang TA, Dure-Smith P, Llaurado JG, Yau DC, Stephenson CB, Stephenson CM, Elam DA. Clinical and radiologic lacrimal testing in patients with epiphora. *Ophthalmology* 1997; **104**: 1875-1881 [PMID: 9373120 DOI: 10.1016/s0161-6420(97)30013-x]
- 14 Maliborski A, Różycki R. Diagnostic imaging of the nasolacrimal drainage system. Part I. Radiological anatomy of lacrimal pathways. Physiology of tear secretion and tear outflow. *Med Sci Monit* 2014; **20**: 628-638 [PMID: 24743297 DOI: 10.12659/MSM.890098]



Published by **Baishideng Publishing Group Inc**
7041 Koll Center Parkway, Suite 160, Pleasanton, CA 94566, USA

Telephone: +1-925-3991568

E-mail: bpgoffice@wjgnet.com

Help Desk: <https://www.f6publishing.com/helpdesk>

<https://www.wjgnet.com>

