

World Journal of *Clinical Cases*

World J Clin Cases 2020 April 26; 8(8): 1343-1560





GUIDELINES

- 1343** Prevention program for the COVID-19 in a children's digestive endoscopy center
Ma XP, Wang H, Bai DM, Zou Y, Zhou SM, Wen FQ, Dai DL

REVIEW

- 1350** Predictive factors for central lymph node metastases in papillary thyroid microcarcinoma
Wu X, Li BL, Zheng CJ, He XD
- 1361** Probiotic mixture VSL#3: An overview of basic and clinical studies in chronic diseases
Cheng FS, Pan D, Chang B, Jiang M, Sang LX

MINIREVIEWS

- 1385** Hypertransaminasemia in the course of infection with SARS-CoV-2: Incidence and pathogenetic hypothesis
Zippi M, Fiorino S, Occhigrossi G, Hong W
- 1391** Stability and infectivity of coronaviruses in inanimate environments
Ren SY, Wang WB, Hao YG, Zhang HR, Wang ZC, Chen YL, Gao RD
- 1400** Status, challenges, and future prospects of stem cell therapy in pelvic floor disorders
Cheng J, Zhao ZW, Wen JR, Wang L, Huang LW, Yang YL, Zhao FN, Xiao JY, Fang F, Wu J, Miao YL

ORIGINAL ARTICLE

Retrospective Study

- 1414** Bedside score predicting retained common bile duct stone in acute biliary pancreatitis
Khoury T, Kadah A, Mahamid M, Mari A, Sbeit W

Observational Study

- 1424** Clinicopathological differences and correlations between right and left colon cancer
Kalantzis I, Nonni A, Pavlakis K, Delicha EM, Miltiadou K, Kosmas C, Ziras N, Gkoumas K, Gakiopoulou H
- 1444** Hemodynamic characteristics in preeclampsia women during cesarean delivery after spinal anesthesia with ropivacaine
Zhao N, Xu J, Li XG, Walline JH, Li YC, Wang L, Zhao GS, Xu MJ

CASE REPORT

- 1454** Mucosa-associated lymphoid tissue lymphoma simulating Crohn's disease: A case report
Stundiene I, Maksimaityte V, Liakina V, Valantinas J

- 1463** Suicide attempt using potassium tablets for congenital chloride diarrhea: A case report
Iijima S
- 1471** Embolization of pancreatic arteriovenous malformation: A case report
Yoon SY, Jeon GS, Lee SJ, Kim DJ, Kwon CI, Park MH
- 1477** Novel frameshift mutation in the SACS gene causing spastic ataxia of charlevoix-saguenay in a consanguineous family from the Arabian Peninsula: A case report and review of literature
Al-Ajmi A, Shamsah S, Janicijevic A, Williams M, Al-Mulla F
- 1489** Duodenal mature teratoma causing partial intestinal obstruction: A first case report in an adult
Chansoon T, Angkathunyakul N, Aroonroch R, Jirasiritham J
- 1495** Rare anaplastic sarcoma of the kidney: A case report
Kao JL, Tsung SH, Shiao CC
- 1502** Unusual association of Axenfeld-Rieger syndrome and wandering spleen: A case report
Chang YL, Lin J, Li YH, Tsao LC
- 1507** Primary cutaneous mantle cell lymphoma: Report of a rare case
Zheng XD, Zhang YL, Xie JL, Zhou XG
- 1515** Typical ulcerative colitis treated by herbs-partitioned moxibustion: A case report
Lin YY, Zhao JM, Ji YJ, Ma Z, Zheng HD, Huang Y, Cui YH, Lu Y, Wu HG
- 1525** Bronchogenic cyst of the stomach: A case report
He WT, Deng JY, Liang H, Xiao JY, Cao FL
- 1532** Laparoscopic umbilical trocar port site endometriosis: A case report
Ao X, Xiong W, Tan SQ
- 1538** Unusual presentation of congenital radioulnar synostosis with osteoporosis, fragility fracture and nonunion: A case report and review of literature
Yang ZY, Ni JD, Long Z, Kuang LT, Tao SB
- 1547** Hydatidiform mole in a scar on the uterus: A case report
Jiang HR, Shi WW, Liang X, Zhang H, Tan Y
- 1554** Pulmonary contusion mimicking COVID-19: A case report
Chen LR, Chen ZX, Liu YC, Peng L, Zhang Y, Xu Q, Lin Q, Tao YM, Wu H, Yin S, Hu YJ

ABOUT COVER

Editorial Board Member of *World Journal of Clinical Cases*, Steven M Schwarz, MD, Professor, Department of Pediatrics, SUNY-Downstate Medical Center, Brooklyn, NY 11203, United States

AIMS AND SCOPE

The primary aim of *World Journal of Clinical Cases* (WJCC, *World J Clin Cases*) is to provide scholars and readers from various fields of clinical medicine with a platform to publish high-quality clinical research articles and communicate their research findings online.

WJCC mainly publishes articles reporting research results and findings obtained in the field of clinical medicine and covering a wide range of topics, including case control studies, retrospective cohort studies, retrospective studies, clinical trials studies, observational studies, prospective studies, randomized controlled trials, randomized clinical trials, systematic reviews, meta-analysis, and case reports.

INDEXING/ABSTRACTING

The WJCC is now indexed in PubMed, PubMed Central, Science Citation Index Expanded (also known as SciSearch®), and Journal Citation Reports/Science Edition. The 2019 Edition of Journal Citation Reports cites the 2018 impact factor for WJCC as 1.153 (5-year impact factor: N/A), ranking WJCC as 99 among 160 journals in Medicine, General and Internal (quartile in category Q3).

RESPONSIBLE EDITORS FOR THIS ISSUE

Responsible Electronic Editor: Ji-Hong Liu

Proofing Production Department Director: Xiang Li

Responsible Editorial Office Director: Jin-Lai Wang

NAME OF JOURNAL

World Journal of Clinical Cases

ISSN

ISSN 2307-8960 (online)

LAUNCH DATE

April 16, 2013

FREQUENCY

Semimonthly

EDITORS-IN-CHIEF

Dennis A Bloomfield, Bao-Gan Peng, Sandro Vento

EDITORIAL BOARD MEMBERS

<https://www.wjgnet.com/2307-8960/editorialboard.htm>

PUBLICATION DATE

April 26, 2020

COPYRIGHT

© 2020 Baishideng Publishing Group Inc

INSTRUCTIONS TO AUTHORS

<https://www.wjgnet.com/bpg/gerinfo/204>

GUIDELINES FOR ETHICS DOCUMENTS

<https://www.wjgnet.com/bpg/GerInfo/287>

GUIDELINES FOR NON-NATIVE SPEAKERS OF ENGLISH

<https://www.wjgnet.com/bpg/gerinfo/240>

PUBLICATION ETHICS

<https://www.wjgnet.com/bpg/GerInfo/288>

PUBLICATION MISCONDUCT

<https://www.wjgnet.com/bpg/gerinfo/208>

ARTICLE PROCESSING CHARGE

<https://www.wjgnet.com/bpg/gerinfo/242>

STEPS FOR SUBMITTING MANUSCRIPTS

<https://www.wjgnet.com/bpg/GerInfo/239>

ONLINE SUBMISSION

<https://www.f6publishing.com>

Laparoscopic umbilical trocar port site endometriosis: A case report

Xue Ao, Wei Xiong, Shi-Qiao Tan

ORCID number: Xue Ao (0000-0002-7883-8116); Wei Xiong (0000-0002-9258-2196); Shi-Qiao Tan (0000-0002-7292-6158).

Author contributions: Ao X was responsible for the data collection and drafting of the manuscript; Xiong W and Tan SQ were responsible for critical revision of the manuscript; all authors read and approved the final manuscript.

Informed consent statement: Informed consent to publish this paper was obtained from the patient.

Conflict-of-interest statement: The authors declare no conflicts of interest.

CARE Checklist (2016) statement: The authors have read the CARE Checklist (2016), and the manuscript was prepared and revised according to the CARE Checklist (2016).

Open-Access: This article is an open-access article that was selected by an in-house editor and fully peer-reviewed by external reviewers. It is distributed in accordance with the Creative Commons Attribution NonCommercial (CC BY-NC 4.0) license, which permits others to distribute, remix, adapt, build upon this work non-commercially, and license their derivative works on different terms, provided the original work is properly cited and the use is non-commercial. See: <http://creativecommons.org/licenses/by-nc/4.0/>

Manuscript source: Unsolicited manuscript

Received: January 19, 2020

Xue Ao, Wei Xiong, Shi-Qiao Tan, Department of Obstetrics and Gynecology, West China Second University Hospital, Key Laboratory of Birth Defects and Related Diseases of Women and Children (Sichuan University), Ministry of Education, Chengdu 610041, Sichuan Province, China

Corresponding author: Wei Xiong, MD, PhD, Associate Chief Physician, Department of Obstetrics and Gynecology, West China Second University Hospital, Key Laboratory of Birth Defects and Related Diseases of Women and Children (Sichuan University), Ministry of Education, No. 20, Section 3, South Renmin Road, Wuhou District, Chengdu 610041, Sichuan Province, China. axsj1113@163.com

Abstract

BACKGROUND

Abdominal wall endometriosis can occur secondary to gynecological and obstetric pelvic laparotomy; however, this is a rare clinical event. There are few cases of endometriosis involving the incision site of a laparoscopic surgery, especially for those of the endometrial nodule at the umbilical trocar port site where the camera is placed.

CASE SUMMARY

We describe the case of a 37-year-old woman who presented with a 2-year history of a tough swelling below the umbilicus, which presented periodical pain during menstruation. The patient had undergone laparoscopic ovarian cystectomy 4 years prior, and we theorized that the umbilical nodule was a complication of that laparoscopic surgery. Histological analysis confirmed the diagnosis of abdominal umbilical scar endometriosis secondary to previous laparoscopic surgery. Surgical removal of the nodule followed by three cycles of leuporelin was curative.

CONCLUSION

Abdominal mass and pain in women of childbearing age with a previous history of pelvic surgery should support consideration of endometriosis at the surgical site.

Key words: Endometriosis; Laparoscopy; Abdominal wall; Scar endometriosis; Ovarian cystectomy; Case report

©The Author(s) 2020. Published by Baishideng Publishing Group Inc. All rights reserved.

Core tip: Incisional endometriosis after laparoscopy is very rare, and if occurring, it is often seen in the cannula incision of that collected specimen. In our patient, incisional endometriosis occurred in the umbilical cannula incision, which was not the cannula

Peer-review started: January 19, 2020

First decision: February 26, 2020

Revised: March 9, 2020

Accepted: April 10, 2020

Article in press: April 10, 2020

Published online: April 26, 2020

P-Reviewer: Daniilidis A,
Richardson WS, Ulker K

S-Editor: Dou Y

L-Editor: Wang TQ

E-Editor: Xing YX



incision from which the specimen was taken out of. We also review the published literature and summarize the characteristics, differential diagnosis, and treatment of umbilical endometriosis.

Citation: Ao X, Xiong W, Tan SQ. Laparoscopic umbilical trocar port site endometriosis: A case report. *World J Clin Cases* 2020; 8(8): 1532-1537

URL: <https://www.wjnet.com/2307-8960/full/v8/i8/1532.htm>

DOI: <https://dx.doi.org/10.12998/wjcc.v8.i8.1532>

INTRODUCTION

Endometriosis occurs mostly in pelvic organs and is rarely detected in extrapelvic locations, such as the abdominal wall, central nervous system, lungs, kidneys, ureters, limbs, gallbladder, nasal cavity, brain, and distant skin^[1,2]. Abdominal wall endometriosis (AWE) is the most common site of extrapelvic endometriosis. AWE can be spontaneous, but it can also occur after gynecological and obstetric pelvic surgery, with approximately 57% of cases developing secondary to cesarean section^[3]. In addition, AWE can also be detected in the abdominal wall incision after ovarian cyst removal, appendectomy, and tubal ligation, being clinically defined as scar endometriosis or incision endometriosis.

Herein, we report a case of AWE detected in the umbilicus, which served as the trocar port site where the laparoscope body and camera were placed during previous laparoscopic surgery.

CASE PRESENTATION

Chief complaints

A 37-year-old woman found a slow-growing nodule under the skin of the surgical scar on the umbilicus which caused periodic pain and presented to the Dermatology Department of West China Hospital, Sichuan University (Chengdu, China) on March 29, 2019 for treatment. Histological analysis of a fine needle aspiration biopsy of the nodule suggested endometriosis.

History of present illness

Umbilical nodules appeared at the incision site of the original laparoscopic cannula at the lower edge of the umbilicus about 4 years prior, which had gradually increased from 0.5 cm to approximately 1.5 cm in diameter and were accompanied by pain during menstruation.

History of past illness

The patient had undergone laparoscopic ovarian cyst removal and bilateral salpingoplasty at the Department of Reproductive Endocrinology of our hospital 6 years prior. After cyst removal, pathological examination had led to the diagnosis of endometrial cyst.

Physical examination

The patient's vital signs were normal. Abdominal examination revealed no tenderness or rebound tenderness. At the incision of the original laparoscopic cannula at the lower edge of the umbilicus, three brown hard nodules of different sizes were detected, with the maximum diameter of about 1.5 cm. No redness or ulceration was found on the surface of the nodules (Figure 1). The boundary between the nodules and surrounding tissues was clear.

Laboratory testing

Fine needle biopsy of the umbilical nodule confirmed the diagnosis of umbilical endometriosis. Positive expression of the immunohistochemical markers' estrogen receptor, progesterone receptor, and p63 was found in the infiltrated glands of the dermis; in addition, progesterone receptor and cluster of differentiation 10 were expressed in the periglandular interstitial space. Ki67 was about 10% positive in the gland and interstitium. Serum level of tumor marker carbohydrate antigen 19-9 was 39.1 U/mL and that of carbohydrate antigen 12-5 was 19.7 U/mL.




Figure 1 Endometriosis at the laparoscopic umbilical trocar port site (orange arrow).

Imaging examination

No superficial ultrasound examination of the abdominal wall was performed because the nodules could be seen clearly by the naked eye. Transvaginal Doppler showed that the endometrial echo was uneven, with a slightly strong echo (endometrial polyp could not be excluded). A cyst about 1.5 to 2.9 cm in diameter was present on both ovaries (chocolate cyst of the ovary is likely).

FINAL DIAGNOSIS

Abdominal umbilical scar endometriosis secondary to previous laparoscopic surgery.

TREATMENT

The nodule was surgically removed, and leuprorelin was administered for three cycles.

OUTCOME AND FOLLOW-UP

Postoperative anatomy showed the cut surface of the mass to be gray-white, gray-yellow, and solid. Both intraoperative and postoperative histological analyses confirmed umbilical endometriosis (Figure 2), and the wound recovered well after operation, without any recurrence to date.

DISCUSSION

This is a case report of an AWE that appeared in the abdominal wall incision after minimally invasive laparoscopic surgery. With the extensive development of laparoscopic surgery, there have been few reports of endometriosis at the cannula incision. Laparoscopic incision endometriosis was first reported by Denton *et al*^[4] in 1990, as umbilical endometriosis after laparoscopic sterilization in a 37-year-old woman. According to Akbarzadeh-Jahromi *et al*^[5], there have been 17 cases reported in the English literature. However, according to our literature review, the total number of cases reported in either English or Chinese is 71 to date, including 32 cases in English and 39 cases in Chinese. Overall, prospective studies are required to increase the quality of the existing literature. Most scholars agree that the etiology of scar endometriosis is endometrial cell planting during surgical treatment^[1,5]. Endometriosis of the abdominal wall most commonly involves tissues around incisions following surgery, such as from cesarean section, abdominal wall incision after hysterectomy, and laparoscopic cannula incision for specimen collection. When taking out the tissue containing endometrial cells, the abdominal incision is most likely to contact endometrial cells. In our case, incision endometriosis occurred in the umbilical cannula incision. This incision is only used to place the laparoscopic camera, so the chance of contact with endometrial cells is small. We suspect that gloves or instruments contaminated with endometrial cells were responsible for the endometrial cells or debris present at the abdominal incision closed (by suture).

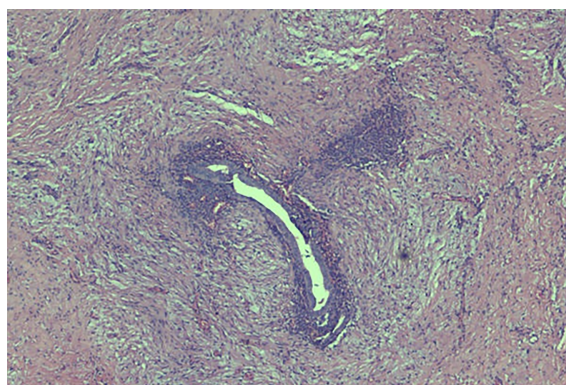


Figure 2 Histopathology of the umbilical nodules: Endometrial tissue (×400).

Abdominal wall mass (82%-96%) and pain (41%-87%) are the most common symptoms of AWE^[6,7]. Only 57% of patients report periodic symptoms^[7], and 3.08% (2/65) are asymptomatic^[8]. Therefore, the periodicity of lump pain related to menstruation is not a necessary condition to diagnose AWE. In a study by Horton *et al*^[7] that reviewed 29 articles, the average age of patients was 31.4 years (95% confidence interval: 29.1-33.8 years) and the average time of symptom onset was 3.6 years (95% confidence interval: 2.5-4.8 years)^[7]. Anand *et al*^[9] described the appearance of ectopic umbilical scar nodules being usually above the incision, with brown skin changes on the surface of the nodules, consistent with the appearance in our case (Figure 1).

AWE should be differentiated from incisional hernia, granulation tissue, hematoma, abscess, sediment, desmoid fibromatosis, lipoma, infection, soft tissue sarcoma, and metastatic malignant tumors^[7,10]. Gupta *et al*^[11] described cases of sporadic desmoid fibromatosis in the umbilical cord 8 mo after laparoscopic cholecystectomy. Desmoid fibromatosis is a rare benign soft tissue tumor originating from muscle-aponeurosis, without malignant potential; however, it can be locally invasive and is similar to AWE. It has been reported that many cases are misdiagnosed as hernia^[5,12], and one case was misdiagnosed as umbilical granuloma^[13].

Most AWEs have typical clinical symptoms, including palpable masses and pain without compression, combined with abdominal surgery history, which indicates a preliminary diagnosis of AWE. Nevertheless, there is no gold standard for preoperative diagnosis. Nodules on ultrasound (a modality characterized by low cost, safety, and noninvasiveness) are usually pear-shaped, with a solid hypoechoic or cystic appearance. Ultrasound, magnetic resonance imaging, or computed tomography can assist in determining the extent of lesions. Ultrasound-guided fine needle puncture can confirm the diagnosis and exclude the diagnosis of malignancies before operation. Surgical resection not only treats patients but can also confirm the diagnosis.

It is widely accepted that surgical excision is the most appropriate approach, and surgical excision of normal tissue 5-10 mm away from the edge of the lesion is required to prevent recurrence, according to the literature^[3,5]. In the case of extensive lesions, computed tomography or magnetic resonance imaging can assess the location and size of AWE more accurately than ultrasound; moreover, they can prevail for the determination of whether to accumulate fascia and rectus abdominis muscles and if preoperative surgical evaluation is needed for reticular repair of the abdominal wall^[3]. Large lesion area and rectus muscle involvement often indicate a higher recurrence rate. Apart from surgical excision, therapeutic percutaneous cryoablation can reduce the volume of lesions, as shown by preliminary studies but not yet confirmed by high-quality literature. Due to the histological characteristics of scars, it is difficult to achieve therapeutic effects around the lesion by oral medication alone. Oral contraceptives and progesterone can attenuate symptoms only slightly but cannot eliminate the lesion^[3]. However, in a study conducted by Alborzi *et al*^[14], who performed laparoscopic exploration after resection of abdominal wall mass in 30 AWE patients, it was found that 28 (93.3%) patients had pelvic endometriosis. Our case report is likely to support this conclusion. Therefore, after surgical resection of AWE, we believe that the postoperative treatment should be supplemented with medication.

A Japanese group, Tsuruga *et al*^[15], previously reported the case of a 49-year-old woman with mixed endometrioid and clear cell carcinoma caused by endometriosis in the laparoscopic cannula during laparoscopic oophorectomy. Nevertheless,

malignant transformation of peritoneal endometriosis is extremely rare. Clear cell carcinoma of abdominal incision is the most common histological type, followed by endometrioid carcinoma^[16]. Other types include mixed adenocarcinoma, serous carcinoma, clear cell carcinoma, and carcinosarcoma. There is no authoritative consensus or guideline on the treatment of AWE malignancies. Despite the lack of direct evidence to support the benefit of chemotherapy at present, adjuvant chemotherapy or radiotherapy is typically administered after extensive surgical operation. The malignant transformation of AWE emphasizes the importance of surgical excision and pathological biopsy.

In consideration of the etiology of AWE iatrogenic implantation, prevention is the fundamental precaution to eliminate AWE. Clinically, the dissemination of endometrial cells should be avoided as much as possible in the first pelvic surgery for patients with ovarian function. In addition, preventive measures can be taken, such as using specimen bags to collect specimens. Saline irrigation should be carefully used when closing abdominal wall incisions, and potentially contaminated cannula incisions should also be flushed out. In addition, instruments contacting the specimens should be rinsed, hands and stitches should be flushed, or the stitches should be replaced. Laparoscopic surgery should not be performed during the menstrual period, and the postoperative complications should be reduced as much as possible for patients.

CONCLUSION

In summary, incisional endometriosis after laparoscopic surgery is rare, and the biological characteristics of the endometriosis are the appearance, growth, infiltration, and formation of nodules and masses in tissues outside the endometrium. Hence, abdominal mass and pain in women of childbearing age with a previous history of pelvic surgery should support consideration of AWE.

REFERENCES

- 1 Uysal A, Mun S, Taner CE. Endometrioma in abdominal scars: case reports of four cases and review of the literature. *Arch Gynecol Obstet* 2012; **286**: 805-808 [PMID: 22476380 DOI: 10.1007/s00404-012-2320-8]
- 2 Emre A, Akbulut S, Yilmaz M, Bozdog Z. Laparoscopic trocar port site endometriosis: a case report and brief literature review. *Int Surg* 2012; **97**: 135-139 [PMID: 23102079 DOI: 10.9738/CC124.1]
- 3 Rindos NB, Mansuria S. Diagnosis and Management of Abdominal Wall Endometriosis: A Systematic Review and Clinical Recommendations. *Obstet Gynecol Surv* 2017; **72**: 116-122 [PMID: 28218772 DOI: 10.1097/OGX.0000000000000399]
- 4 Denton GW, Schofield JB, Gallagher P. Uncommon complications of laparoscopic sterilisation. *Ann R Coll Surg Engl* 1990; **72**: 210-211 [PMID: 2141462]
- 5 Akbarzadeh-Jahromi M, Motavas M, Fazelzadeh A. Recurrent abdominal wall endometriosis at the trocar site of laparoscopy: A rare case. *Int J Reprod Biomed (Yazd)* 2018; **16**: 653-656 [PMID: 30643859]
- 6 Vellido-Cotelo R, Muñoz-González JL, Oliver-Pérez MR, de la Hera-Lázaro C, Almansa-González C, Pérez-Sagasetta C, Jiménez-López JS. Endometriosis node in gynaecologic scars: a study of 17 patients and the diagnostic considerations in clinical experience in tertiary care center. *BMC Womens Health* 2015; **15**: 13 [PMID: 25783643 DOI: 10.1186/s12905-015-0170-9]
- 7 Horton JD, Dezee KJ, Ahnfeldt EP, Wagner M. Abdominal wall endometriosis: a surgeon's perspective and review of 445 cases. *Am J Surg* 2008; **196**: 207-212 [PMID: 18513698 DOI: 10.1016/j.amjsurg.2007.07.035]
- 8 Ecker AM, Donnellan NM, Shepherd JP, Lee TT. Abdominal wall endometriosis: 12 years of experience at a large academic institution. *Am J Obstet Gynecol* 2014; **211**: 363.e1-363.e5 [PMID: 24732005 DOI: 10.1016/j.ajog.2014.04.011]
- 9 Anand M, Deshmukh SD. Massive abdominal wall endometriosis masquerading as desmoid tumour. *J Cutan Aesthet Surg* 2011; **4**: 141-143 [PMID: 21976909 DOI: 10.4103/0974-2077.85043]
- 10 Siddiqui ZA, Husain F, Siddiqui Z, Siddiqui M. Port site endometrioma: a rare cause of abdominal wall pain following laparoscopic surgery. *BMJ Case Rep* 2017; **2017** [PMID: 28630240 DOI: 10.1136/bcr-2017-219291]
- 11 Gupta R, Andley M, Talwar N, Kumar A. Sporadic Desmoid-Type Fibromatosis Occurring at Laparoscopic Trocar Site: An Unusual Entity. *Indian J Surg* 2018; **80**: 275-277 [PMID: 29973760 DOI: 10.1007/s12262-017-1717-9]
- 12 Tatli F, Gozeneli O, Uyanikoglu H, Uzunkoy A, Yalcin HC, Ozgonul A, Bardakci O, Incebiyik A, Guldur ME. The clinical characteristics and surgical approach of scar endometriosis: A case series of 14 women. *Bosn J Basic Med Sci* 2018; **18**: 275-278 [PMID: 29285999 DOI: 10.17305/bjbm.2018.2659]
- 13 Efremidou EI, Kouklakis G, Mitrakas A, Liratzopoulos N, Polychronidis ACh. Primary umbilical endometrioma: a rare case of spontaneous abdominal wall endometriosis. *Int J Gen Med* 2012; **5**: 999-1002 [PMID: 23271917 DOI: 10.2147/IJGM.S37302]
- 14 Alborzi S, Hamed B, Abbasi S, Parsanejad ME. Association Rate between Incisional and Pelvic Endometriosis. *J Endometriosis* 2011; **3**: 183-187 [DOI: 10.5301/JE.2012.9087]
- 15 Tsuruga T, Hirata T, Akiyama I, Matsumoto Y, Oda K, Fujii T, Osuga Y. Mixed endometrioid and clear cell carcinoma arising from laparoscopic trocar site endometriosis. *J Obstet Gynaecol Res* 2019; **45**: 1613-1618 [PMID: 31183953 DOI: 10.1111/jog.14014]
- 16 Taburiaux L, Pluchino N, Petignat P, Wenger JM. Endometriosis-Associated Abdominal Wall Cancer: A

Poor Prognosis? *Int J Gynecol Cancer* 2015; **25**: 1633-1638 [PMID: 26448542 DOI: 10.1097/IGC.0000000000000556]



Published By Baishideng Publishing Group Inc
7041 Koll Center Parkway, Suite 160, Pleasanton, CA 94566, USA
Telephone: +1-925-3991568
E-mail: bpgoffice@wjgnet.com
Help Desk: <https://www.f6publishing.com/helpdesk>
<https://www.wjgnet.com>

