

World Journal of *Gastroenterology*

World J Gastroenterol 2020 March 7; 26(9): 883-994



**REVIEW**

- 883** Role of alcohol in pathogenesis of hepatitis B virus infection
Ganesan M, Eikenberry A, Poluektova LY, Kharbanda KK, Osna NA

ORIGINAL ARTICLE**Basic Study**

- 904** Magnetic resonance imaging biomarkers for pulsed focused ultrasound treatment of pancreatic ductal adenocarcinoma
Maloney E, Wang YN, Vohra R, Son H, Whang S, Khokhlova T, Park J, Gravelle K, Totten S, Hwang JH, Lee D
- 918** Kynurenine plays an immunosuppressive role in 2,4,6-trinitrobenzene sulfate-induced colitis in mice
Tashita C, Hoshi M, Hirata A, Nakamoto K, Ando T, Hattori T, Yamamoto Y, Tezuka H, Tomita H, Hara A, Saito K

Case Control Study

- 933** Exosomal miR-182 regulates the effect of RECK on gallbladder cancer
Zheng H, Wang JJ, Zhao LJ, Yang XR, Yu YL

Retrospective Study

- 947** Clinical utility of treatment method conversion during single-session endoscopic ultrasound-guided biliary drainage
Minaga K, Takenaka M, Yamao K, Kamata K, Omoto S, Nakai A, Yamazaki T, Okamoto A, Ishikawa R, Yoshikawa T, Chiba Y, Watanabe T, Kudo M
- 960** Differentiation of atypical hepatic hemangioma from liver metastases: Diagnostic performance of a novel type of color contrast enhanced ultrasound
Wu XF, Bai XM, Yang W, Sun Y, Wang H, Wu W, Chen MH, Yan K
- 973** Effect and safety of mark-guided *vs* standard peroral endoscopic myotomy: A retrospective case control study
Li DF, Xiong F, Yu ZC, Zhang HY, Liu TT, Tian YH, Shi RY, Lai MG, Song Y, Xu ZL, Zhang DG, Yao J, Wang LS

CASE REPORT

- 984** Two case reports of novel syndrome of bizarre performance of gastrointestinal endoscopy due to toxic encephalopathy of endoscopists among 181767 endoscopies in a 13-year-university hospital review: Endoscopists, first do no harm!
Cappell MS

LETTER TO THE EDITOR

- 992** Results of meta-analysis should be treated critically
Liu RQ, Shao Y

ABOUT COVER

Associate Editor of *World Journal of Gastroenterology*, Seung Up Kim, MD, PhD, Associate Professor, Department of Internal Medicine, Yonsei University College of Medicine, Severance Hospital, Seoul 03722, South Korea

AIMS AND SCOPE

The primary aim of *World Journal of Gastroenterology* (WJG, *World J Gastroenterol*) is to provide scholars and readers from various fields of gastroenterology and hepatology with a platform to publish high-quality basic and clinical research articles and communicate their research findings online.

WJG mainly publishes articles reporting research results and findings obtained in the field of gastroenterology and hepatology and covering a wide range of topics including gastroenterology, hepatology, gastrointestinal endoscopy, gastrointestinal surgery, gastrointestinal oncology, and pediatric gastroenterology.

INDEXING/ABSTRACTING

The WJG is now indexed in Current Contents®/Clinical Medicine, Science Citation Index Expanded (also known as SciSearch®), Journal Citation Reports®, Index Medicus, MEDLINE, PubMed, PubMed Central, and Scopus. The 2019 edition of Journal Citation Report® cites the 2018 impact factor for WJG as 3.411 (5-year impact factor: 3.579), ranking WJG as 35th among 84 journals in gastroenterology and hepatology (quartile in category Q2). CiteScore (2018): 3.43.

RESPONSIBLE EDITORS FOR THIS ISSUE

Responsible Electronic Editor: *Yu-Jie Ma*
Proofing Production Department Director: *Xiang Li*

NAME OF JOURNAL

World Journal of Gastroenterology

ISSN

ISSN 1007-9327 (print) ISSN 2219-2840 (online)

LAUNCH DATE

October 1, 1995

FREQUENCY

Weekly

EDITORS-IN-CHIEF

Subrata Ghosh, Andrzej S Tarnawski

EDITORIAL BOARD MEMBERS

<http://www.wjgnet.com/1007-9327/editorialboard.htm>

EDITORIAL OFFICE

Ze-Mao Gong, Director

PUBLICATION DATE

March 7, 2020

COPYRIGHT

© 2020 Baishideng Publishing Group Inc

INSTRUCTIONS TO AUTHORS

<https://www.wjgnet.com/bpg/gerinfo/204>

GUIDELINES FOR ETHICS DOCUMENTS

<https://www.wjgnet.com/bpg/GerInfo/287>

GUIDELINES FOR NON-NATIVE SPEAKERS OF ENGLISH

<https://www.wjgnet.com/bpg/gerinfo/240>

PUBLICATION MISCONDUCT

<https://www.wjgnet.com/bpg/gerinfo/208>

ARTICLE PROCESSING CHARGE

<https://www.wjgnet.com/bpg/gerinfo/242>

STEPS FOR SUBMITTING MANUSCRIPTS

<https://www.wjgnet.com/bpg/GerInfo/239>

ONLINE SUBMISSION

<https://www.f6publishing.com>



Retrospective Study

Effect and safety of mark-guided vs standard peroral endoscopic myotomy: A retrospective case control study

De-Feng Li, Feng Xiong, Zhi-Chao Yu, Hai-Yang Zhang, Ting-Ting Liu, Yan-Hui Tian, Rui-Yue Shi, Ming-Guang Lai, Yang Song, Zheng-Lei Xu, Ding-Guo Zhang, Jun Yao, Li-Sheng Wang

ORCID number: De-Feng Li (0000-0003-3118-6840); Feng Xiong (0000-0002-4021-0817); Zhi-Chao Yu (0000-0001-5123-9191); Hai-Yang Zhang (0000-0002-0899-827X); Ting-Ting Liu (0000-0002-1533-5220); Yan-Hui Tian (0000-0003-4671-2938); Rui-Yue Shi (0000-0001-9123-2103); Ming-Guang Lai (0000-0001-5432-0921); Yang Song (0000-0003-4124-9286); Zheng-Lei Xu (0000-0002-5413-7390); Ding-Guo Zhang (0000-0001-7728-9672); Jun Yao (0000-0002-3472-1602); Li-Sheng Wang (0000-0002-7418-6114).

Author contributions: Wang LS and Yao J were responsible for design of the study and reviewed the manuscript. Li DF and Xiong F drafted the manuscript. Li DF, Xiong F and Yu ZC abstracted data. Liu TT, Tian YH, Shi RY, Lai MG, Song Y, Xu ZL and Zhang DG performed the POEM. Yao J and Wang LS were responsible for revising manuscript. All authors have read and approved the final manuscript.

Supported by Natural Science Foundation of Guangdong Province, No. 2018A0303100024; Shenzhen Health Planning Commission, No. SZXJ2017030.

Institutional review board statement: The research was reviewed and approved by the Institutional review board of Shenzhen Municipal People's Hospital.

Informed consent statement: Patients were not required to give informed consent to the study

De-Feng Li, Feng Xiong, Zhi-Chao Yu, Hai-Yang Zhang, Ting-Ting Liu, Yan-Hui Tian, Rui-Yue Shi, Ming-Guang Lai, Yang Song, Zheng-Lei Xu, Ding-Guo Zhang, Jun Yao, Li-Sheng Wang, Department of Gastroenterology, the Second Clinical Medicine College (Shenzhen People's Hospital) of Jinan University, Shenzhen 518020, Guangdong Province, China

Corresponding author: Li-Sheng Wang, MD, Doctor, Department of Gastroenterology, the Second Clinical Medicine College (Shenzhen People's Hospital) of Jinan University, 1017 East Gate Road, Shenzhen 518020, Guangdong Province, China. wanglsszrmmy@163.com

Abstract

BACKGROUND

Peroral endoscopic myotomy (POEM) is a promising therapeutic modality for esophageal achalasia worldwide. However, clinical failure and adverse events of POEM have still been concerned.

AIM

To compare the efficacy and safety of a novel mark-guided POEM with standard POEM.

METHODS

A total of 133 patients with esophageal achalasia who underwent POEM from May 2013 to May 2019 were enrolled in this retrospective study. Of the 133 patients, there were 64 patients in the mark-guided POEM group and 69 patients in the standard POEM group. The clinical success, procedural duration and adverse events were compared between the two groups at 3 mo, 12 mo and 24 mo postoperatively.

RESULTS

Characteristic baseline was similar in the mark-guided POEM group and standard POEM group. The clinical success was comparable between the two groups, ranging from 92% to 98%, at 3 mo, 12 mo and 24 mo postoperatively (all $P > 0.5$). Eckart score, Gastroesophageal Reflux Disease Questionnaire score and SF-36 score were not different between the two groups after treatment (all $P > 0.05$). No severe adverse events occurred in the two groups. However, mark-guided POEM required shorter procedural duration, and less use of proton pump inhibitors and lower incidence of reflux symptoms than the standard POEM (all $P < 0.001$).

CONCLUSION

because the analysis used anonymous data that were obtained after each patient agreed to treatment by written consent.

Conflict-of-interest statement: The authors of this manuscript have no conflicts of interest to disclose.

Data sharing statement: No additional data are available.

Open-Access: This article is an open-access article that was selected by an in-house editor and fully peer-reviewed by external reviewers. It is distributed in accordance with the Creative Commons Attribution NonCommercial (CC BY-NC 4.0) license, which permits others to distribute, remix, adapt, build upon this work non-commercially, and license their derivative works on different terms, provided the original work is properly cited and the use is non-commercial. See: <http://creativecommons.org/licenses/by-nc/4.0/>

Manuscript source: Unsolicited manuscript

Received: October 30, 2019

Peer-review started: October 30, 2019

First decision: December 12, 2019

Revised: January 9, 2020

Accepted: January 19, 2020

Article in press: January 19, 2020

Published online: March 7, 2020

P-Reviewer: Abdelfatah MM, Eleftheriadis N

S-Editor: Dou Y

L-Editor: MedE-Ma JY

E-Editor: Zhang YL



Mark-guided POEM and standard POEM were both effective and safe for the treatment of esophageal achalasia. However, the mark-guided POEM was characterized by shorter procedural duration, less use of proton pump inhibitors and lower incidence of reflux symptoms.

Key words: Mark-guided peroral endoscopic myotomy; Standard peroral endoscopic myotomy; Achalasia; Endoscopy; Efficacy; Adverse event

©The Author(s) 2020. Published by Baishideng Publishing Group Inc. All rights reserved.

Core tip: Mark-guided Peroral endoscopic myotomy (POEM) can create full and large separation through sufficient sub-mucosal injection, which can improve the operative field, decrease the incidence of bleeding, perforation and intra-procedural mucosal injury, and enhance the clinical success. By mark-guided POEM, it was not necessary to repeatedly pull out the tunnel to check the direction, thus saving the procedural time. Moreover, mark-guided POEM required less use of proton pump inhibitors and showed a lower incidence of reflux symptoms after the procedure.

Citation: Li DF, Xiong F, Yu ZC, Zhang HY, Liu TT, Tian YH, Shi RY, Lai MG, Song Y, Xu ZL, Zhang DG, Yao J, Wang LS. Effect and safety of mark-guided vs standard peroral endoscopic myotomy: A retrospective case control study. *World J Gastroenterol* 2020; 26(9): 973-983

URL: <https://www.wjgnet.com/1007-9327/full/v26/i9/973.htm>

DOI: <https://dx.doi.org/10.3748/wjg.v26.i9.973>

INTRODUCTION

As a rare esophageal motility disorder, esophageal achalasia is characterized by a failure of peristalsis in the esophageal body, leading to impaired lower esophageal sphincter relax and esophageal emptying^[1,2]. The hampered passage of food from the esophagus to the stomach contributes to symptoms of dysphagia, regurgitation, chest pain and weight loss, as well as pulmonary complications^[3,4].

Peroral endoscopic myotomy (POEM) was first described by Inoue *et al*^[5] for achalasia treatment in 2010. Subsequently, it was demonstrated that POEM was effective and safe and has become the standard procedure for achalasia treatment worldwide^[6-8]. Although several prospective studies have shown that POEM was superior in controlling symptoms of achalasia, POEM-associated clinical failure and adverse events have still been concerned^[9-11]. The clinical success rate of POEM was reported to be more than 90%, however, reflux esophagitis which was the main adverse event developed in more than 40% of the patients after POEM treatment^[12].

Several factors are associated with the efficacy and safety of POEM, such as mucosal injury, direction loss in the tunnel and oblique muscle damage^[12,13]. Therefore, we here described a novel POEM procedure named mark-guided POEM, which may solve above-mentioned problems. We retrospectively compared the novel mark-guided POEM and standard POEM described by Inoue *et al*^[5] in terms of clinical success, technical success and adverse events in our clinical center.

MATERIALS AND METHODS

From May 2013 to May 2019, patients diagnosed with achalasia based on Eckardt score, barium esophagography and high-resolution manometry (HRM) were retrospectively collected at the Department of Gastroenterology of the Second Clinical Medicine College (Shenzhen People's Hospital) of Jinan University (Guangdong, China). The patients who were lost to follow-up were excluded. Demographic and clinical data included patient's age, gender, disease duration, follow-up, procedural duration, clinical success, technical success, pre-operative and post-operative Eckardt score, post-operative length of stay, recurrence and adverse events (bleeding, perforation and reflux symptoms). A total of 133 patients who underwent POEM were included in this study. Of these patients, there were 64 patients in the mark-guided POEM group treated from September 2018 to May 2019 and 69 patients in the

standard POEM group treated from May 2013 to September 2018. The initial follow-up barium esophagography was conducted at 3 mo post-operatively. Subsequently, Eckardt score, Medical Outcomes Study 36-Item Short-Form Health Survey (SF-36), reflux symptoms and proton pump inhibitor (PPI) use were assessed *via* telephone at 3, 12 and 24 mo post-operatively (Figure 1). The study protocol was approved by Shenzhen People's Hospital Ethics Committee.

Definitions

Achalasia is divided into three distinct subtypes (type I, II and III) according to the pattern of esophageal contractility observed during high-resolution manometry (HRM) according to the Chicago Classification system^[3]. Eckardt scores in 4-item questionnaire including dysphagia, regurgitation and chest pain ranging from 0 to 3 (0, none; 1, occasionally; 2, daily; 3, with every meal), and weight loss (0, no weight loss; 1, < 5 kg; 2, 5-10 kg; 3, > 10 kg) were used to evaluate the severity of achalasia, which were rated from the lowest severity (0 score) to the highest severity (12 scores)^[14]. Clinical success was assessed using the Eckardt scores (≤ 3 scores), and failure of treatment was defined as Eckardt scores of more than 3 after treatment. The Gastroesophageal Reflux Disease Questionnaire (GERDQ) was used to assess reflux symptoms, including heartburn, regurgitation, epigastric pain, nausea, sleep disorder and use of over-the-counter drugs, and each of them was rated from 0 to 3 scores. Therefore, the total scores ranged from 0 to 18 points, and > 8 points was regarded as GERD^[15]. SF-36 scoring system was composed of physical and mental components ranging from 0 to 100 scores, and higher scores indicated better quality of life^[16]. Severe adverse events consisted of perforation and bleeding (defined as need of blood transfusion or endoscopy, radiologic and surgical intervention).

POEM procedure

Patients were fasted for 24 h before the procedure. POEM was performed under general anesthesia with endotracheal intubation and CO₂ insufflation. All participating endoscopists were experts, and standard POEM procedure in this study was in accordance with Inoue *et al.*^[3]. The steps of standard POEM were briefly described as follows. (1) At the middle of esophagus, a submucosal bleb was created by injecting saline containing 0.3% indigo carmine. Subsequently, a 2-cm longitudinal mucosal incision was made by Dual Knife (Olympus, Japan) to create submucosal tunnel using Endocut mode (30 W, effect 3) (ERBE, Germany); (2) A tunnel passing gastroesophageal junction (GEJ) 2-3 cm into proximal stomach was created by Dual Knife on the plane of dissection of submucosal layer; (3) Circular muscle bundle dissection was extended from 3 cm below the mucosal entry onto the proximal gastric cardia using Triangle Knife; and (4) Clips were placed close to the mucosal entry site (Anrei, China) (Video 1 standard peroral endoscopic myotomy procedure) through endoscopy. In the first step of mark-guided POEM, the middle of esophagus to gastric cardia at esophageal mucosal surface was marked using Dual Knife. Then, submucosal injection was administered through the mark with saline containing 0.3% indigo carmine. Next, submucosal layer dissection, circular muscle bundle dissection and closure of mucosal entry site were the same as standard POEM (Video 2 mark-guided peroral endoscopic myotomy procedure).

Postoperative management

All patients were given antibiotics (Ceftriaxone and Metronidazole) and a double-dose PPI (Omeprazole) intravenously at the day of the procedure and kept nothing by mouth (NPO) at the night of the procedure. The next day, a gastrografin esophagram was performed to rule out leakage and perforation. All patients with no evidence of adverse events were discharged, and they were advised to take soft food for 2 wk and PPI (Omeprazole, 20 mg, once a day) was prescribed for 2 wk.

Follow-up

All patients were followed up with barium esophagography at 3 mo post-operatively, and Eckardt score, GERDQ score, SF-36 score, reflux symptoms and PPI use were also assessed *via* telephone at 12 mo and 24 mo post-operatively.

Outcomes

The primary outcome was clinical success, and the second outcome included procedure duration, severe adverse events, Eckardt score, GERDQ score, SF-36 score, reflux symptoms and PPI use.

Statistical analysis

All analyses were performed using the SPSS 23.0 software package (SPSS Company, Chicago, IL, United States). All categorical variables were expressed as the frequency

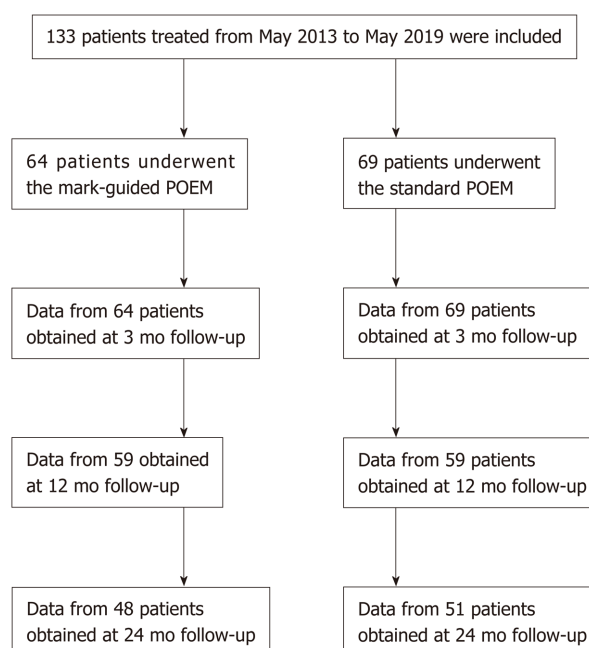


Figure 1 Flow chart.

with respective percentages. Continuous data were presented as mean \pm SD or median (interquartile range) according to distribution. χ^2 test or Fisher's exact test was used to assess categorical variables, and unpaired *t*-test or Mann-Whitney test was used to assess continuous data. *P* values < 0.05 were considered statistically significant.

RESULTS

Patient characteristics

A total of 133 consecutive patients were included in this retrospective study. Of these patients, there were 64 patients in the mark-guided POEM group and 69 patients in the standard POEM group. There was no significant difference between the two groups in terms of sex, age, type of achalasia, disease duration, Eckardt score, esophageal height, esophageal diameter, HRM, GERDQ score and SF-36 score (Table 1).

Comparison of procedure-related parameters

Both groups successfully underwent POEM without any severe adverse events (perforation and bleeding) (*P* = 1). In addition, the hospital stay was not significantly different between the two groups (*P* = 0.56). However, the procedure duration was significantly shorter in the mark-guided POEM group compared with the standard POEM group (*P* < 0.001) (Table 1).

Primary outcome and second outcome at 3-mo follow-up

There were 64 and 69 patients in the mark-guided POEM group and standard POEM group at 3-mo follow-up, respectively. No significant difference was observed in the clinical success between the two groups (98.4% *vs* 98.6%, *P* = 0.3). Figure 2 shows that the pre-operative HRM and Eckart scores were significantly decreased compared with the post-operative values in both groups (Figure 2A-2D, all *P* < 0.001). Furthermore, the pre-operative SF-36 score was significantly improved compared with the postoperative value in both groups (Figure 2E, 2F, all *P* < 0.001). However, there was no significant difference between the two groups (Table 2). The post-operative height and diameter of barium esophagography were significantly decreased in both groups (Figure 3A-3D, all *P* < 0.001), whereas there was no significant difference between the two groups (Table 2). Moreover, the pre-operative GERDQ score was significantly decreased compared with its post-operative value in the standard POEM group (*P* = 0.01, Figure 3E), while such significant difference was not observed in the mark-guided POEM group (*P* = 0.09, Figure 3F). However, the incidence of reflux symptoms and PPI use were significantly different between mark-guided POEM and

Table 1 Baseline characteristics and comparison of procedure-related parameters

Characteristics	Mark-guided POEM (n = 64)	Standard POEM (n = 69)	P value
Sex			
Male (n)	33 (51.6%)	36 (52.2%)	0.94
Female (n)	31 (48.4%)	33 (47.8%)	
Age (yr)	33.5 (28-48.75)	40 (30-47.75)	0.22
Achalasia Type			
I	21 (32.8%)	23 (33.3%)	0.98
II	36 (56.3%)	38 (55.1%)	
III	7 (10.9%)	8 (11.6%)	
Disease duration (mo)	32.5 (23-49.50)	33 (22.5-49.50)	0.95
Eckardt score	9.0 (8-9.75)	8.0 (7-9)	0.32
Barium esophagography			
Height (cm)	8 (8-9)	8 (7-9)	0.55
Diameter (cm)	5 (4-6)	5 (5-6)	0.29
HRM (mmHg)	38 (28-41)	38 (28-41.5)	0.64
GERDQ score	7 (6-9)	7 (6-8.5)	0.74
SF-36 score	47.22 ± 7.25	46.81 ± 7.60	0.75
Procedure duration (min)	40 (38-43)	49 (47-51)	< 0.001
Technical success (n)	64 (100%)	69 (100%)	1
Postoperative stay (d)	1 (1-2)	1 (1-2)	0.56
Perforation (n)	0	0	1
Bleeding (n)	0	0	1

POEM: Peroral endoscopic myotomy; HRM: High-resolution manometry; GERDQ: Gastroesophageal reflux disease questionnaire; SF-36: 36-Item Short-Form Health Survey.

standard POEM groups (10.9% *vs* 24.6%, $P = 0.04$; and 12.7% *vs* 27.5%, $P = 0.03$, respectively) (Table 2).

Primary outcome and second outcome at 12-mo follow-up

Table 3 shows that there were 59 patients in each group at 12-mo follow-up, and the clinical success was 93.5% (55/59) and 91.5% (54/59) in the mark-guided POEM group and standard POEM group, respectively, with no significant difference between the two groups ($P = 0.73$). Moreover, there was no significant difference between the two groups in terms of Eckart score, GERDQ score and SF-36 score ($P = 0.9$, $P = 0.67$ and $P = 0.94$, respectively). However, the incidence of reflux symptoms and PPI use was 16.9% and 18.6% in the mark-guided POEM group and 37.3% and 40.7% in the standard POEM group, respectively ($P = 0.01$ and $P = 0.009$).

Primary outcome and second outcome at 24-mo follow-up

There were 48 patients in the mark-guided POEM group and 51 patients in the standard POEM group at 24-mo follow-up. The results showed that there was no significant difference in clinical success between the mark-guided POEM group and standard POEM group (92.7% *vs* 92.2%, $P = 0.93$). Furthermore, there was no significant difference between the two groups in terms of Eckart score, GERDQ score and SF-36 score ($P = 0.92$, $P = 0.74$ and $P = 0.73$, respectively), whereas the incidence of reflux symptoms and PPI use were significantly lower in the mark-guided POEM group compared with the standard POEM group (27.1% *vs* 47.1%, $P = 0.04$ and 29.2% *vs* 51%, $P = 0.02$) (Table 4).

Unsuccessful treatment analysis

Nine and 10 patients with unsuccessful treatment in the mark-guided POEM group and standard POEM group, respectively, were all symptomatic (Eckart score > 3). Of the nine patients in the mark-guided POEM group, five patients required re-treatment and recovered uneventfully, whereas the other four patients refused additional treatments because of symptom improvement. Of the 10 patients in the standard POEM group, six patients successfully underwent re-treatment of POEM, while the other four patients refused additional re-treatment.

Table 2 Primary and secondary outcomes in patients at 3 mo follow-up

	Mark-guided POEM (n = 64)	Standard POEM (n = 69)	P value
Overall clinical success (n)	63 (98.4%)	68 (98.6%)	0.3
Eckart score	1 (1-2)	1 (1-2)	0.78
GERDQ score	6 (5-9)	6 (5-7)	0.35
SF-36 score	78 (76-80)	78 (75-80.5)	0.87
Barium esophagography			
Height (cm)	3 (2-4)	3 (2-4)	0.94
Diameter (cm)	2 (2-2.5)	2 (2-2.75)	0.86
HRM (mmHg)	12.2 ± 2.37	12.06 ± 1.93	0.7
Reflux symptom (n)			
Yes	7 (10.9%)	17 (24.6%)	0.04
No	57 (89.1%)	52 (75.4%)	
PPI use (n)			
Yes	8 (12.7%)	19 (27.5%)	0.03
No	56 (87.3%)	60 (72.5%)	

POEM: Peroral endoscopic myotomy; HRM: High-resolution manometry; GERDQ: Gastroesophageal reflux disease questionnaire; SF-36: 36-Item Short-Form Health Survey; PPI: Proton pump inhibitor.

DISCUSSION

In this retrospective study, we compared the mark-guided POEM with standard POEM in terms of the clinical success, procedure duration, adverse events, reflux symptoms and PPI use at 3-mo, 12-mo and 24-mo follow-up. The results showed that the overall clinical success, hospital stay and severe adverse events were not significantly different between the two groups. However, the procedural duration, and incidence of reflux symptoms and PPI use were significantly lower in the mark-guided POEM group compared with the standard POEM group.

In the present study, we found that the clinical success ranged from 92.7% to 98.4% and 92.2% to 98.6% at 3-mo follow-up and 24-mo follow-up, respectively, in the mark-guided POEM group and standard POEM group, which was similar to a previous meta-analysis^[17]. Moreover, there was no severe adverse event (perforation and bleeding) in the patients in this study. However, a previous study has shown that the overall rate of adverse events is 7.5%, and severe adverse events only occur in 90 cases of 1800 POEM procedures^[18]. Our results indicated that the clinical success could be decreased with time in both groups, which was consistent with previous data that the recurrence rate after POEM can be increased with time^[19,20]. However, POEM re-treatment was also effective for the recurrent patients, and some of them refused additional treatment because of symptom improvement. Therefore, both the mark-guided and standard POEM was effective for achalasia. Interestingly, we found that the mark-guided POEM showed a lower incidence of reflux symptoms and less PPI use compared with standard POEM, which was markedly lower compared with the previous study as well^[6]. Ponds *et al*^[10] have demonstrated that the reflux esophagitis rate is 49%, and 8% are severe cases on endoscopy examination at 1-year follow-up after POEM treatment, which is markedly higher compared with the mark-guided POEM in the present study. Furthermore, Shiwaku *et al*^[21] have found that the erosive esophagitis (Los Angeles grade A-D) and severe erosive esophagitis (Los Angeles grade C-D) account for 63% and 6.2%, respectively, whereas, symptomatic GERD is only observed in 14.8% of 1300 patients at 6-mo follow-up after POEM. Therefore, the erosive esophagitis might be more in this study. Fortunately, many studies including our current study have shown that reflux symptoms respond to treatment with a PPI^[10,21].

To the best of our knowledge, we, for the first time, compared the mark-guided POEM with standard POEM. In addition to less procedure duration, and lower incidence of reflux symptoms and PPI use in the mark-guided POEM, there was no significant difference between the two groups. We considered that the mark-guided POEM had the following advantages: First, it could create full and large separation through sufficient sub-mucosal injection, which could improve operative filed, decrease the incidence of bleeding, perforation and intra-procedural mucosal injury, and increase the clinical success. Liu *et al*^[22] have shown that intra-procedural mucosal injury is a risk factor for clinical failure. Second, it was not necessary to repeatedly

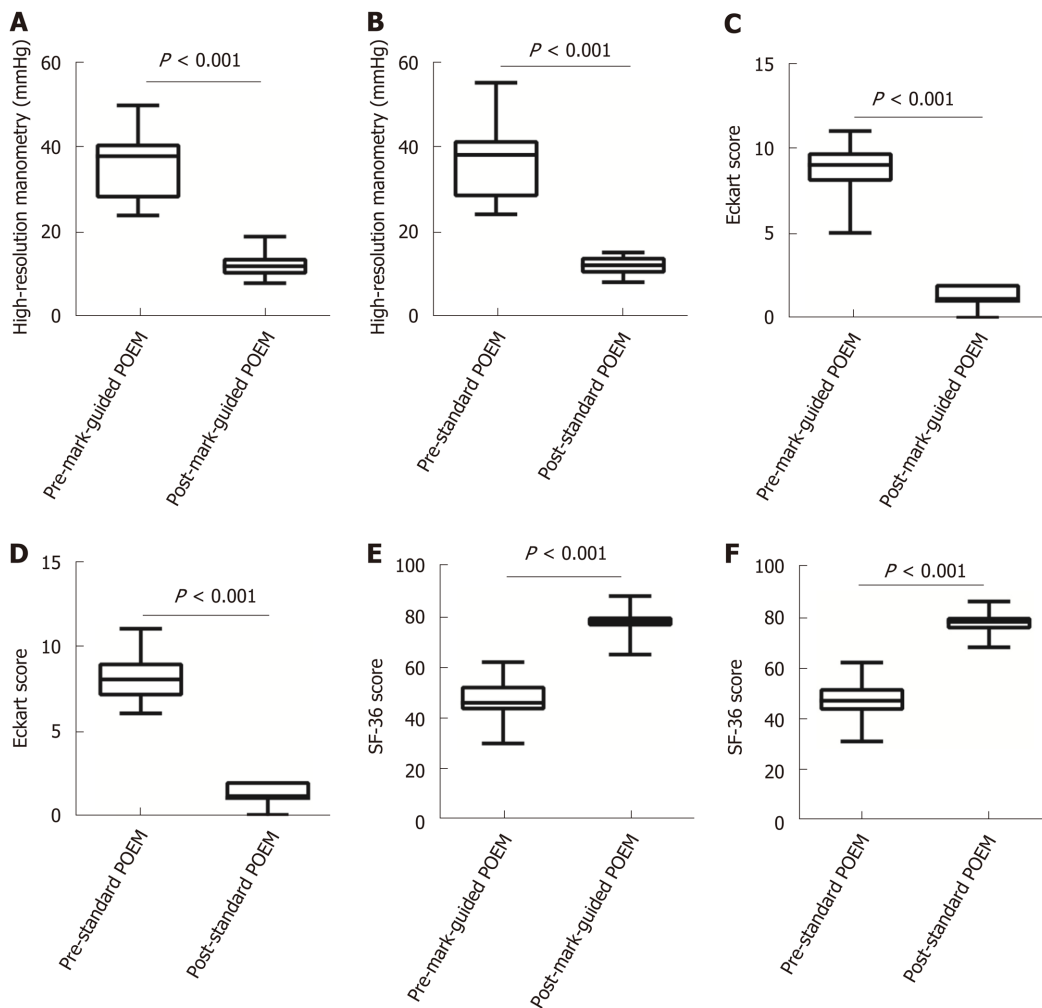


Figure 2 High-resolution manometry, Eckart score and 36-Item Short-Form Health Survey scores at 3-mo follow-up in the mark-guided peroral endoscopic myotomy group and standard peroral endoscopic myotomy group. A-D: The pre-operative high-resolution manometry and Eckart scores were significantly decreased compared with the postoperative values in the two groups (all $P < 0.001$); E, F: The pre-operative 36-Item Short-Form Health Survey scores were significantly improved compared with the postoperative values in both groups (all $P < 0.001$).

pull out the tunnel to check the direction, thus saving much operating time.

There are several limitations in this study. First, this was a retrospective study from a single tertiary hospital, and the results need to be confirmed by multi-centers randomized controlled trials. Second, the Eckardt score was used to determine clinical success. However, its construct validity has recently been questioned^[23]. Third, GERDQ has limitations to identify reflux symptoms or GERD after POEM. Fourth, patients were followed up at 3, 12 and 24 mo *via* telephone, and long-term conclusion is unavailable.

In summary, this retrospective study confirmed that the mark-guided POEM and standard POEM were both effective and safe for esophageal achalasia. However, the mark-guided POEM required less procedural duration and showed a lower incidence of reflux symptoms and PPI use compared with the standard POEM.

Table 3 Primary and secondary outcomes in patients at 12 mo follow-up

	Mark-guided POEM (<i>n</i> = 59)	Standard POEM (<i>n</i> = 59)	<i>P</i> value
Overall clinical success (<i>n</i>)	55 (93.2%)	54 (91.5%)	0.73
Eckart score	1 (1-2)	1 (1-2)	0.9
GERDQ score	7 (6-9)	6 (6-9)	0.67
SF-36 score	75 (67-78)	74 (70-78)	0.94
Reflux symptom (<i>n</i>)			
Yes	10 (16.9%)	22 (37.3%)	0.01
No	49 (83.1%)	37 (62.7%)	
PPI use (<i>n</i>)			
Yes	11 (18.6%)	24 (40.7%)	0.009
No	48 (81.4%)	35 (59.3%)	

POEM: Peroral endoscopic myotomy; GERDQ: Gastroesophageal reflux disease questionnaire; SF-36: 36-Item Short-Form Health Survey; PPI: Proton pump inhibitor.

Table 4 Primary and secondary outcomes in patients at 24 mo follow-up

	Mark-guided POEM (<i>n</i> = 48)	Standard POEM (<i>n</i> = 51)	<i>P</i> value
Overall clinical success (<i>n</i>)	44 (92.7%)	47 (92.2%)	0.93
Eckart score	1 (1-2)	1 (1-2)	0.92
GERDQ score	7 (6-9)	7 (6-9)	0.74
SF-36 score	77 (71-80)	76 (72-80)	0.73
Reflux symptom (<i>n</i>)			
Yes	13 (27.1%)	24(47.1%)	0.04
No	35(72.9%)	27 (52.9%)	
PPI use (<i>n</i>)			
Yes	14 (29.2%)	26 (51%)	0.02
No	34 (70.8%)	25 (49%)	

POEM: Peroral endoscopic myotomy; GERDQ: Gastroesophageal reflux disease questionnaire; SF-36: 36-Item Short-Form Health Survey; PPI: Proton pump inhibitor.

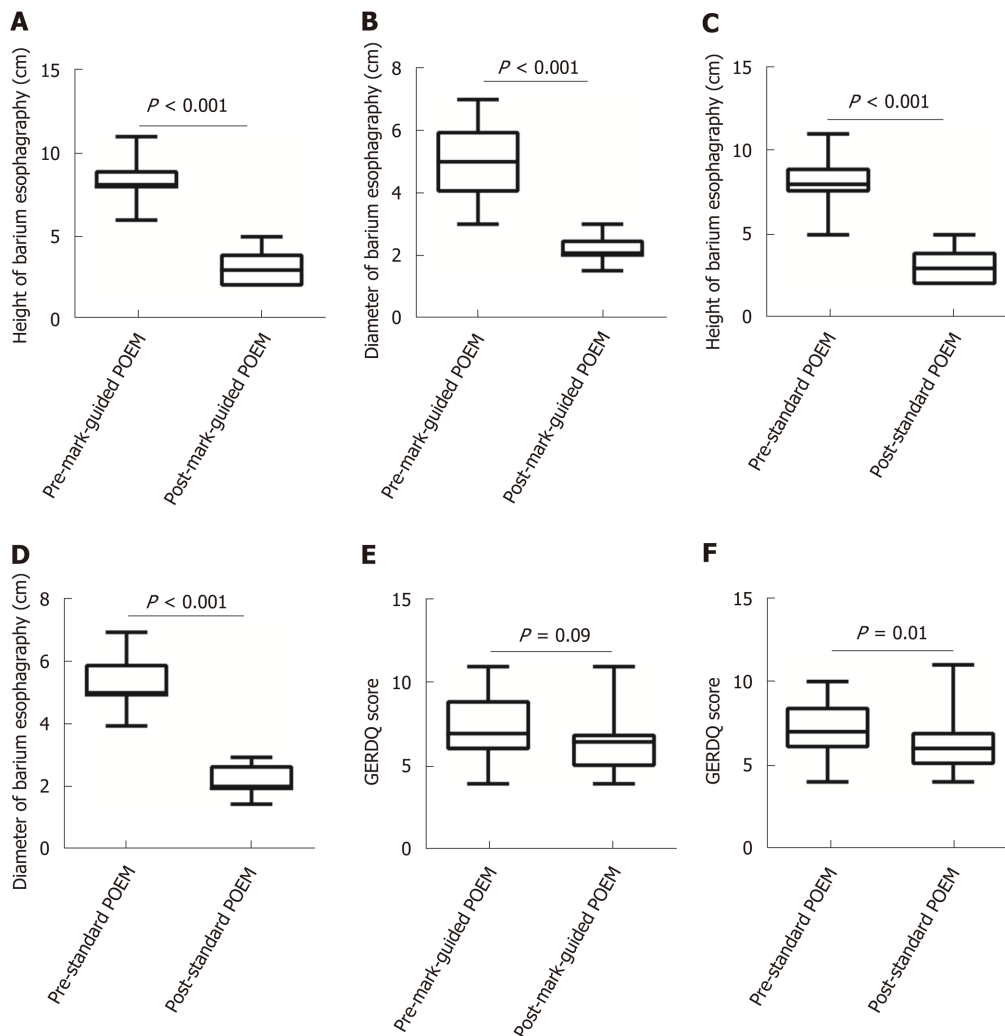


Figure 3 Barium esophagography at 3-mo follow-up in the mark-guided peroral endoscopic myotomy group and standard peroral endoscopic myotomy group. A-D: The post-operative height and diameter of barium esophagography were significantly decreased compared with the pre-operative values in the two groups (all $P < 0.001$); E: The pre-operative Gastroesophageal reflux disease questionnaire score was significantly decreased compared with the post-operative value in the standard peroral endoscopic myotomy group ($P = 0.01$); F: No significant difference was observed between pre-operative and post-operative values in the mark-guided peroral endoscopic myotomy group ($P = 0.09$).

ARTICLE HIGHLIGHTS

Research background

Peroral endoscopic myotomy (POEM) was first described by a study on achalasia treatment in 2010. Subsequently, it was demonstrated that POEM was effective and safe and has become the standard procedure for achalasia worldwide. However, clinical failure and adverse events of POEM have still been concerned. Indeed, POEM procedure can lead to a high incidence of reflux esophagitis.

Research motivation

Several factors are associated with the efficacy and safety of POEM, such as sufficient sub-mucosal injection, limiting mucosal injury and constructing sub-mucosal tunnel straightly. Therefore, we described a novel POEM procedure named mark-guided POEM, which may solve afore-mentioned problems.

Research objectives

This study aimed to compare the efficacy and safety of the novel mark-guided POEM with standard POEM in the improvement of efficacy and safety of achalasia treatment. This retrospective case control study will encourage us to explore the efficacy and safety of the mark-guided POEM for further research, such as multi-centers randomized controlled trials.

Research methods

This retrospective case control study compared the efficacy and safety between the mark-guided POEM and standard POEM.

Research results

This study showed that mark-guided POEM and standard POEM were both effective and safe for achalasia treatment, however, the mark-guided POEM seemed to require less procedural duration and proton pump inhibitor (PPI) use and show a lower incidence of reflux symptoms. However, these results will be confirmed by randomized controlled trials.

Research conclusions

POEM is a promising therapeutic procedure for esophageal achalasia worldwide. However, clinical failure and adverse events of POEM have still been concerned. In order to improve efficacy and safety of achalasia treatment, we described a novel POEM procedure named the mark-guided POEM. We retrospectively compared the efficacy and safety of the mark-guided POEM with standard POEM. The results showed that the clinical success was comparable between the two groups, ranging from 92% to 98%, at 3 mo, 12 mo and 24 mo postoperatively. However, the mark-guided POEM required less procedural duration, less use of PPI and lower incidence of reflux symptoms than the standard POEM. We will conduct multi-centers randomized controlled trial to confirm these results.

Research perspectives

The mark-guided POEM may be superior to standard POEM for achalasia treatment; however, the findings need to be further confirmed using multi-centers randomized controlled trials.

REFERENCES

- 1 **Richter JE.** Achalasia - an update. *J Neurogastroenterol Motil* 2010; **16**: 232-242 [PMID: [20680161](#) DOI: [10.5056/jnm.2010.16.3.232](#)]
- 2 **Sadowski DC, Ackah F, Jiang B, Svenson LW.** Achalasia: incidence, prevalence and survival. A population-based study. *Neurogastroenterol Motil* 2010; **22**: e256-e261 [PMID: [20465592](#) DOI: [10.1111/j.1365-2982.2010.01511.x](#)]
- 3 **Boeckstaens GE, Zaninotto G, Richter JE.** Achalasia. *Lancet* 2014; **383**: 83-93 [PMID: [23871090](#) DOI: [10.1016/S0140-6736\(13\)60651-0](#)]
- 4 **Boeckstaens GE.** The lower oesophageal sphincter. *Neurogastroenterol Motil* 2005; **17** Suppl 1: 13-21 [PMID: [15836451](#) DOI: [10.1111/j.1365-2982.2005.00661.x](#)]
- 5 **Inoue H, Minami H, Kobayashi Y, Sato Y, Kaga M, Suzuki M, Satodate H, Odaka N, Itoh H, Kudo S.** Peroral endoscopic myotomy (POEM) for esophageal achalasia. *Endoscopy* 2010; **42**: 265-271 [PMID: [20354937](#) DOI: [10.1055/s-0029-1244080](#)]
- 6 **Kahrilas PJ, Katzka D, Richter JE.** Clinical Practice Update: The Use of Per-Oral Endoscopic Myotomy in Achalasia: Expert Review and Best Practice Advice From the AGA Institute. *Gastroenterology* 2017; **153**: 1205-1211 [PMID: [28989059](#) DOI: [10.1053/j.gastro.2017.10.001](#)]
- 7 **Benias PC, Korrapati P, Raphael KL, D'Souza LS, Inamdar S, Trindade AJ, Lee C, Kumbhari V, Sejjal DV, Okolo P, Khashab MA, Miller L, Carr-Locke D.** Safety and feasibility of performing peroral endoscopic myotomy as an outpatient procedure with same-day discharge. *Gastrointest Endosc* 2019; **90**: 570-578 [PMID: [31078571](#) DOI: [10.1016/j.gie.2019.04.247](#)]
- 8 **Liu Z, Wang Y, Fang Y, Huang Y, Yang H, Ren X, Xu M, Chen S, Chen W, Zhong Y, Zhang Y, Qin W, Hu J, Cai M, Yao L, Li Q, Zhou P.** Short-term safety and efficacy of peroral endoscopic myotomy for the treatment of achalasia in children. *J Gastroenterol* 2019 [PMID: [31679066](#) DOI: [10.1007/s00535-019-01607-4](#)]
- 9 **Werner YB, Hakanson B, Martinek J, Repici A, von Rahden BHA, Bredenoord AJ, Bisschops R, Messmann H, Vollberg MC, Noder T, Kersten JF, Mann O, Izbicki J, Pazdro A, Fumagalli U, Rosati R, Germer CT, Schijven MP, Emmertmann A, von Renteln D, Fockens P, Boeckstaens G, Rösch T.** Endoscopic or Surgical Myotomy in Patients with Idiopathic Achalasia. *N Engl J Med* 2019; **381**: 2219-2229 [PMID: [31800987](#) DOI: [10.1056/NEJMoa1905380](#)]
- 10 **Ponds FA, Fockens P, Lei A, Neuhaus H, Beyna T, Kandler J, Frieling T, Chiu PWY, Wu JCY, Wong VWY, Costamagna G, Familiari P, Kahrilas PJ, Pandolfino JE, Smout AJPM, Bredenoord AJ.** Effect of Peroral Endoscopic Myotomy vs Pneumatic Dilation on Symptom Severity and Treatment Outcomes Among Treatment-Naïve Patients With Achalasia: A Randomized Clinical Trial. *JAMA* 2019; **322**: 134-144 [PMID: [31287522](#) DOI: [10.1001/jama.2019.8859](#)]
- 11 **Shiwaku H, Inoue H, Sato H, Onimaru M, Minami H, Tanaka S, Sato C, Ogawa R, Okushima N, Yokomichi H.** Peroral endoscopic myotomy for achalasia: a prospective multicenter study in Japan. *Gastrointest Endosc* 2019 [PMID: [31759035](#) DOI: [10.1016/j.gie.2019.11.020](#)]
- 12 **Khashab MA, Vela MF, Thosani N, Agrawal D, Buxbaum JL, Abbas Fehmi SM, Fishman DS, Gurudu SR, Jamil LH, Jue TL, Bijun Sai Kannadath, Law JK, Lee JK, Naveed M, Qumsey BJ, Sawhney MS, Yang J, Wani S.** ASGE guideline on the management of achalasia. *Gastrointest Endosc* 2019 [PMID: [31839408](#) DOI: [10.1016/j.gie.2019.04.231](#)]
- 13 **Chiu PW, Inoue H, Rösch T.** From POEM to POET: Applications and perspectives for submucosal tunnel endoscopy. *Endoscopy* 2016; **48**: 1134-1142 [PMID: [27855465](#) DOI: [10.1055/s-0042-119395](#)]
- 14 **Perbtani YB, Mramba LK, Yang D, Suarez J, Draganov PV.** Life after per-oral endoscopic myotomy: long-term outcomes of quality of life and their association with Eckardt scores. *Gastrointest Endosc* 2018; **87**: 1415-1420.e1 [PMID: [29410304](#) DOI: [10.1016/j.gie.2018.01.019](#)]
- 15 **Wang M, Zhang JZ, Kang XJ, Li L, Huang XL, Aihemaijiang K, Ayinuer A, Li YX, He XL, Gao F.** Relevance between GerdQ score and the severity of reflux esophagitis in Uygur and Han Chinese. *Oncotarget* 2017; **8**: 74371-74377 [PMID: [29088793](#) DOI: [10.18632/oncotarget.20146](#)]
- 16 **Vigneswaran Y, Tanaka R, Gitelis M, Carbray J, Ujiki MB.** Quality of life assessment after peroral endoscopic myotomy. *Surg Endosc* 2015; **29**: 1198-1202 [PMID: [25249144](#) DOI: [10.1007/s00464-014-3793-2](#)]
- 17 **Lee Y, Brar K, Doumouras AG, Hong D.** Peroral endoscopic myotomy (POEM) for the treatment of pediatric achalasia: a systematic review and meta-analysis. *Surg Endosc* 2019; **33**: 1710-1720 [PMID: [30767141](#) DOI: [10.1007/s00464-019-06701-5](#)]

- 18 **Haito-Chavez Y**, Inoue H, Beard KW, Draganov PV, Ujiki M, Rahden BHA, Desai PN, Pioche M, Hayee B, Haji A, Saxena P, Reavis K, Onimaru M, Balassone V, Nakamura J, Hata Y, Yang D, Pannu D, Abbas A, Perbtani YB, Patel LY, Filser J, Roman S, Rivory J, Mion F, Ponchon T, Perretta S, Wong V, Maselli R, Ngamruengphong S, Chen YI, Bukhari M, Hajjiyeva G, Ismail A, Pieratti R, Kumbhari V, Galdos-Cardenas G, Repici A, Khashab MA. Comprehensive Analysis of Adverse Events Associated With Per Oral Endoscopic Myotomy in 1826 Patients: An International Multicenter Study. *Am J Gastroenterol* 2017; **112**: 1267-1276 [PMID: [28534521](#) DOI: [10.1038/ajg.2017.139](#)]
- 19 **Von Renteln D**, Fuchs KH, Fockens P, Bauerfeind P, Vassiliou MC, Werner YB, Fried G, Breithaupt W, Heinrich H, Bredenoord AJ, Kersten JF, Verlaan T, Trevisonno M, Rösch T. Peroral endoscopic myotomy for the treatment of achalasia: an international prospective multicenter study. *Gastroenterology* 2013; **145**: 309-11.e1-3 [PMID: [23665071](#) DOI: [10.1053/j.gastro.2013.04.057](#)]
- 20 **Werner YB**, Costamagna G, Swanström LL, von Renteln D, Familiari P, Sharata AM, Noder T, Schachschal G, Kersten JF, Rösch T. Clinical response to peroral endoscopic myotomy in patients with idiopathic achalasia at a minimum follow-up of 2 years. *Gut* 2016; **65**: 899-906 [PMID: [25934759](#) DOI: [10.1136/gutjnl-2014-308649](#)]
- 21 **Shiwaku H**, Inoue H, Onimaru M, Minami H, Sato H, Sato C, Tanaka S, Ogawa R, Okushima N. Multicenter collaborative retrospective evaluation of peroral endoscopic myotomy for esophageal achalasia: analysis of data from more than 1300 patients at eight facilities in Japan. *Surg Endosc* 2020; **34**: 464-468 [PMID: [31183791](#) DOI: [10.1007/s00464-019-06833-8](#)]
- 22 **Liu XY**, Cheng J, Chen WF, Liu ZQ, Wang Y, Xu MD, Chen SY, Zhong YS, Zhang YQ, Yao LQ, Zhou PH, Li QL. A risk-scoring system to predict clinical failure for patients with achalasia after peroral endoscopic myotomy. *Gastrointest Endosc* 2020; **91**: 33-40.e1 [PMID: [31421076](#) DOI: [10.1016/j.gie.2019.07.036](#)]
- 23 **Taft TH**, Carlson DA, Triggs J, Craft J, Starkey K, Yadlapati R, Gregory D, Pandolfino JE. Evaluating the reliability and construct validity of the Eckardt symptom score as a measure of achalasia severity. *Neurogastroenterol Motil* 2018; **30**: e13287 [PMID: [29315993](#) DOI: [10.1111/nmo.13287](#)]



Published By Baishideng Publishing Group Inc
7041 Koll Center Parkway, Suite 160, Pleasanton, CA 94566, USA
Telephone: +1-925-3991568
E-mail: bpgoffice@wjgnet.com
Help Desk: <http://www.f6publishing.com/helpdesk>
<http://www.wjgnet.com>

