

World Journal of *Gastroenterology*

World J Gastroenterol 2020 April 14; 26(14): 1546-1682



**FIELD OF VISION**

- 1546** SARS-COV-2 infection (coronavirus disease 2019) for the gastrointestinal consultant
Hajifathalian K, Mahadev S, Schwartz RE, Shah S, Sampath K, Schnoll-Sussman F, Brown Jr RS, Carr-Locke D, Cohen DE, Sharaiha RZ

OPINION REVIEW

- 1554** Optimized timing of using infliximab in perianal fistulizing Crohn's disease
Sun XL, Chen SY, Tao SS, Qiao LC, Chen HJ, Yang BL

REVIEW

- 1564** Intestinal epithelial barrier and neuromuscular compartment in health and disease
D'Antongiovanni V, Pellegrini C, Fornai M, Colucci R, Blandizzi C, Antonioli L, Bernardini N
- 1580** Gastrointestinal cancer stem cells as targets for innovative immunotherapy
Chivu-Economescu M, Necula LG, Matei L, Dragu DL, Neagu AI, Alexiu I, Bleotu C, Diaconu CC

MINIREVIEWS

- 1594** Is the measurement of drain amylase content useful for predicting pancreas-related complications after gastrectomy with systematic lymphadenectomy?
Nakanishi K, Kanda M, Sakamoto J, Kadera Y

ORIGINAL ARTICLE**Basic Study**

- 1601** Silymarin, boswellic acid and curcumin enriched dietetic formulation reduces the growth of inherited intestinal polyps in an animal model
Girardi B, Pricci M, Giorgio F, Piazzolla M, Iannone A, Losurdo G, Principi M, Barone M, Ierardi E, Di Leo A

Retrospective Cohort Study

- 1613** Lifestyle factors and long-term survival of gastric cancer patients: A large bidirectional cohort study from China
Zhao LL, Huang H, Wang Y, Wang TB, Zhou H, Ma FH, Ren H, Niu PH, Zhao DB, Chen YT

Retrospective Study

- 1628** Optimal treatment strategies for hepatic portal venous gas: A retrospective assessment
Gonda M, Osuga T, Ikura Y, Hasegawa K, Kawasaki K, Nakashima T
- 1638** Clinical and microbiological characteristics of patients with biliary disease
Gu XX, Zhang MP, Zhao YF, Huang GM

- 1647** Development and validation of a prediction model for microvascular invasion in hepatocellular carcinoma
Wang L, Jin YX, Ji YZ, Mu Y, Zhang SC, Pan SY

Prospective Study

- 1660** Macrophage inhibitory cytokine-1/growth differentiation factor-15 in premalignant and neoplastic tumours in a high-risk pancreatic cancer cohort
O'Neill RS, Emmanuel S, Williams D, Stoita A

CASE REPORT

- 1674** Small bowel racemose hemangioma complicated with obstruction and chronic anemia: A case report and review of literature
Fu JX, Zou YN, Han ZH, Yu H, Wang XJ

ABOUT COVER

Associate Editor of *World Journal of Gastroenterology*, Yung-Jue Bang, MD, PhD, Professor, Department of Internal Medicine, Seoul National University College of Medicine, Seoul 110-744, South Korea

AIMS AND SCOPE

The primary aim of *World Journal of Gastroenterology* (WJG, *World J Gastroenterol*) is to provide scholars and readers from various fields of gastroenterology and hepatology with a platform to publish high-quality basic and clinical research articles and communicate their research findings online.

WJG mainly publishes articles reporting research results and findings obtained in the field of gastroenterology and hepatology and covering a wide range of topics including gastroenterology, hepatology, gastrointestinal endoscopy, gastrointestinal surgery, gastrointestinal oncology, and pediatric gastroenterology.

INDEXING/ABSTRACTING

The WJG is now indexed in Current Contents®/Clinical Medicine, Science Citation Index Expanded (also known as SciSearch®), Journal Citation Reports®, Index Medicus, MEDLINE, PubMed, PubMed Central, and Scopus. The 2019 edition of Journal Citation Report® cites the 2018 impact factor for WJG as 3.411 (5-year impact factor: 3.579), ranking WJG as 35th among 84 journals in gastroenterology and hepatology (quartile in category Q2). CiteScore (2018): 3.43.

RESPONSIBLE EDITORS FOR THIS ISSUE

Responsible Electronic Editor: Yan-Liang Zhang

Proofing Production Department Director: Yun-Xiaojuan Wu

Responsible Editorial Office Director: Ze-Mao Gong

NAME OF JOURNAL

World Journal of Gastroenterology

ISSN

ISSN 1007-9327 (print) ISSN 2219-2840 (online)

LAUNCH DATE

October 1, 1995

FREQUENCY

Weekly

EDITORS-IN-CHIEF

Subrata Ghosh, Andrzej S Tarnawski

EDITORIAL BOARD MEMBERS

<http://www.wjgnet.com/1007-9327/editorialboard.htm>

PUBLICATION DATE

April 14, 2020

COPYRIGHT

© 2020 Baishideng Publishing Group Inc

INSTRUCTIONS TO AUTHORS

<https://www.wjgnet.com/bpg/gerinfo/204>

GUIDELINES FOR ETHICS DOCUMENTS

<https://www.wjgnet.com/bpg/GerInfo/287>

GUIDELINES FOR NON-NATIVE SPEAKERS OF ENGLISH

<https://www.wjgnet.com/bpg/gerinfo/240>

PUBLICATION ETHICS

<https://www.wjgnet.com/bpg/GerInfo/288>

PUBLICATION MISCONDUCT

<https://www.wjgnet.com/bpg/gerinfo/208>

ARTICLE PROCESSING CHARGE

<https://www.wjgnet.com/bpg/gerinfo/242>

STEPS FOR SUBMITTING MANUSCRIPTS

<https://www.wjgnet.com/bpg/GerInfo/239>

ONLINE SUBMISSION

<https://www.f6publishing.com>

Small bowel racemose hemangioma complicated with obstruction and chronic anemia: A case report and review of literature

Ji-Xin Fu, Ya-Nan Zou, Zhi-Hao Han, Hao Yu, Xin-Jian Wang

ORCID number: Ji-Xin Fu (0000-0002-9215-9144); Ya-Nan Zou (0000-0001-7273-129X); Zhi-Hao Han (0000-0001-5280-3989); Hao Yu (0000-0002-4119-0432); Xin-Jian Wang (0000-0001-8248-0551).

Author contributions: Fu JX designed the report, reviewed the literature, and wrote the paper; Zou YN, Yu H, and Wang XJ performed the surgery; Han ZH analyzed and interpreted the imaging findings; Fu JX and Yu H collected the patient's clinical data; Fu JX and Wang XJ analyzed the data and revised the paper; all authors have read and approved the final version of this manuscript.

Informed consent statement: Written informed consent was obtained from the patient for publication of this report and any accompanying images.

Conflict-of-interest statement: The authors declare that they have no conflict of interest.

CARE Checklist (2016) statement: The authors have read the CARE Checklist (2016), and the manuscript was prepared and revised according to the CARE Checklist (2016).

Open-Access: This article is an open-access article that was selected by an in-house editor and fully peer-reviewed by external reviewers. It is distributed in accordance with the Creative Commons Attribution NonCommercial (CC BY-NC 4.0) license, which permits others to distribute, remix, adapt, build upon this work non-commercially,

Ji-Xin Fu, Hao Yu, Xin-Jian Wang, Department of Gastrointestinal Surgery, Weihai Central Hospital, Weihai 264200, Shandong Province, China

Ya-Nan Zou, Department of Anesthesiology, Weihai Central Hospital, Weihai 264200, Shandong Province, China

Zhi-Hao Han, Department of Radiology, Weihai Central Hospital, Weihai 264200, Shandong Province, China

Corresponding author: Xin-Jian Wang, MPhil, Chief Doctor, Director, Professor, Surgeon, Department of Gastrointestinal Surgery, Weihai Central Hospital, No. 3, Mishandong Road Xi, Wendeng District, Weihai 264200, Shandong Province, China. wdwxj@126.com

Abstract

BACKGROUND

Gastrointestinal hemangiomas are rare benign tumors. According to the size of the affected vessels, hemangiomas are histologically classified into cavernous, capillary, or mixed-type tumors, with the cavernous type being the most common and racemose hemangiomas being very rare in the clinic. Melena of uncertain origin and anemia are the main clinical manifestations, and other presentations are rare. Due to the rarity of gastrointestinal hemangiomas and lack of specific manifestations and diagnostic methods, preoperative diagnoses are often delayed or incorrect.

CASE SUMMARY

We report a 5-year-old girl who presented with abdominal pain, nausea, and vomiting for a duration of 10 h. The laboratory studies showed prominent anemia. Computed tomography and contrast-enhanced computed tomography of the abdomen revealed a small bowel obstruction caused by a giant abdominal mass. Segmental resection of the ileal lesions was performed through surgery, and the final pathology results revealed a diagnosis of racemose hemangioma complicated by a small bowel obstruction and simultaneous chronic anemia.

CONCLUSION

The current report will increase the understanding of the diagnosis and treatment of gastrointestinal hemangiomas and provide a review of the related literature.

Key words: Gastrointestinal hemangioma; Racemose hemangioma; Small bowel obstruction; Chronic anemia; Computed tomography; Case report

and license their derivative works on different terms, provided the original work is properly cited and the use is non-commercial. See: <http://creativecommons.org/licenses/by-nc/4.0/>

Manuscript source: Unsolicited manuscript

Received: December 21, 2019

Peer-review started: November 11, 2019

First decision: January 17, 2020

Revised: March 10, 2020

Accepted: March 14, 2020

Article in press: March 14, 2020

Published online: April 14, 2020

P-Reviewer: Chowdhury F, Velnar T

S-Editor: Wang J

L-Editor: Wang TQ

E-Editor: Zhang YL



©The Author(s) 2020. Published by Baishideng Publishing Group Inc. All rights reserved.

Core tip: Gastrointestinal hemangiomas are rare benign tumors, and small bowel racemose hemangiomas complicated by obstructions and chronic anemia are even more rare clinically. Here, we report a 5-year-old girl who presented with abdominal pain, nausea, and vomiting for a duration of 10 h. The preoperative examination revealed an acute obstruction and anemia. A segmental resection of the ileum was performed, and the final pathology revealed a small bowel racemose hemangioma complicated by an obstruction and simultaneous chronic anemia. To improve the diagnosis and treatment of gastrointestinal hemangiomas, we present this unusual report and review some of the related literature.

Citation: Fu JX, Zou YN, Han ZH, Yu H, Wang XJ. Small bowel racemose hemangioma complicated with obstruction and chronic anemia: A case report and review of literature. *World J Gastroenterol* 2020; 26(14): 1674-1682

URL: <https://www.wjgnet.com/1007-9327/full/v26/i14/1674.htm>

DOI: <https://dx.doi.org/10.3748/wjg.v26.i14.1674>

INTRODUCTION

Gastrointestinal hemangiomas are rare benign tumors, representing 0.05% of all gastrointestinal tumors^[1]. These tumors usually present in young people with no sex predilection. Their main clinical manifestation is gastrointestinal bleeding of uncertain origin, which is defined as chronic or recurrent gastrointestinal bleeding of an unknown cause. Other forms of presentation include obstruction, intussusception, intramural hematoma, perforation, and platelet sequestration^[2]. According to the size of the affected vessels, hemangiomas are histologically classified into cavernous, capillary, or mixed-type tumors, with the cavernous type being the most common and racemose hemangioma being very rare in the clinic^[3]. In the gastrointestinal tract, these tumors are more frequently found in the jejunum. Computed tomography (CT) and contrast-enhanced computed tomography (CECT) are the main methods for diagnosing such lesions preoperatively, and capsule endoscopy is significantly helpful for diagnosing small bowel lesions^[4]. Surgical resection is the ideal treatment. This study presents the unusual case of a 5-year-old girl who underwent segmental resection, and the final pathology results revealed a small bowel racemose hemangioma complicated by an obstruction and simultaneous chronic anemia. A review of the current literature was also provided to contextualize the findings of the present study.

CASE PRESENTATION

Chief complaints

A 5-year-old female child was admitted to the Emergency Department of our hospital complaining of abdominal pain, nausea, and vomiting for a duration of 10 h.

History of present illness

The patient suddenly developed abdominal pain 10 h ago, which was total abdominal pain accompanied by nausea and vomiting. There was no pulsatile vomiting. The vomitus was the previously ingested food and yellow-green bile-like substance, and she vomited three times. There was no hematemesis, no fever, no chest tightness or suffocation, and no diarrhea. The abdominal symptoms gradually became aggravated.

History of past illness and personal and family history

The patient was born after a full-term pregnancy by spontaneous vaginal delivery and had a history of iron deficiency anemia for 1 year. Prior to this admission, the patient had been treated with supplemental iron as recommended by her pediatrician for her symptoms but had shown no improvement. Her parents were healthy, and there were no close relatives. Her mother had a healthy pregnancy.

Physical examination

On the physical examination, her heart rate was 99 beats per minute, and her blood pressure was 12/8 KPa. There were no lesions in the oropharynx, and her neck was supple. The lungs were clear, and her heart rate was regular, without a murmur. Her abdomen was soft, and an abdominal mass could be felt on the left lower abdomen, which was tender. The neurologic examination was unremarkable.

Laboratory examinations

The white cell count was $5.41 \times 10^9/L$, with 77.8% of neutrophils; hemoglobin was 78 g/L, with a hematocrit level of 27.7%, and the platelet count was $356 \times 10^9/L$. The serum ferritin level was less than 1.0 $\mu g/L$ (normal range: 15-200). The electrocardiogram and chest X-ray were normal.

Imaging examinations

An initial imaging evaluation by ultrasound revealed an enormous tumor mass in the middle of the abdomen and pelvis with an inhomogeneous echo pattern that was 10.3 cm \times 4.0 cm in size, and several strong echoes and grid-like structures could be seen in the mass with a low blood flow signal on color Doppler flow imaging.

The abdominal lesions were further evaluated by an abdominal CT scan and CECT. The former revealed an ill-circumscribed mass of mixed density in the left lower abdomen that extended to the pelvis. There were multiple high-density nodes in the mass (Figure 1A). The latter revealed that the mass exhibited heterogeneous enhancement following contrast administration. In the venous phase, there were thick and tortuous blood vessels in the mass, which were connected to each other by a honeycomb or racemose appearance (Figure 1B-1D).

FINAL DIAGNOSIS

Considering the large abdominal mass in a young woman with multiple calcifications, the most likely preoperative diagnosis was a teratoma complicated by a small bowel obstruction. However, the final diagnosis by histopathology was small bowel racemose hemangioma complicated by an obstruction and anemia (Figure 2).

TREATMENT

Laparoscopy was performed, and the result revealed a 10 cm \times 4 cm lesion on the ileum; a vascular nature was suspected due to the bluish purple coloration, compressibility, and presence of varices on the surface (Figure 3). The mass invaded the intestinal canal and required a dilated proximal intestinal and segmental small bowel resection.

OUTCOME AND FOLLOW-UP

The patient was discharged without immediate complications on the 8th day, and the hemoglobin increased to 123 g/L at the second month after the operation.

DISCUSSION

Hemangiomas are defined as congenital benign vascular lesions that are venous malformations, not true tumors. Hemangiomas are classified into cavernous, capillary, or mixed tumors; the cavernous type is the most common, and racemose hemangioma is very rare^[3]. According to the biological characteristics of hemangioma, Fishman *et al*^[5] divided them into two categories: Hemangioma and vascular malformations. According to the angiographic findings, vascular malformations can be divided into high-flow and low-flow types, and racemose hemangioma is a complex high-flow type of arteriovenous malformation, which accounts for approximately 1.5% of all hemangiomas and mostly occurs in the head, neck, and limbs^[6,7]. Hemangiomas of the gastrointestinal tract are rare, accounting for only 0.05% of all intestinal neoplasms and 7%-10% of all benign tumors of the small bowel^[8]. According to the literature, small bowel racemose hemangiomas with obstructions and chronic anemia were rarely reported, which makes our case even more unusual.

The PubMed (<https://www.ncbi.nlm.nih.gov/pubmed>), WanFang Data

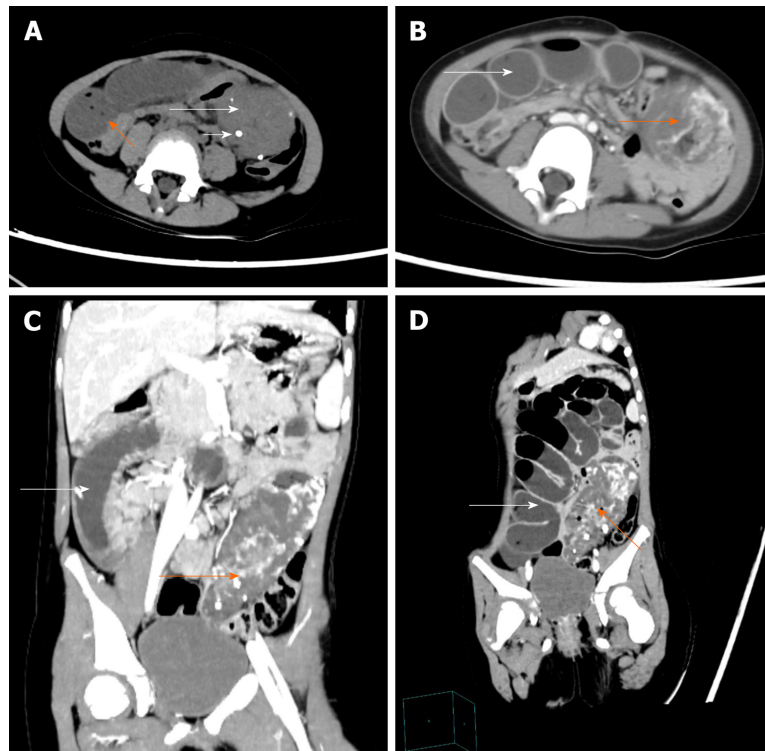


Figure 1 Pre-operative abdominal computed tomography and contrast-enhanced computed tomography images. A: Abdominal computed tomography image showing an ill-circumscribed mass of mixed density in the left lower abdomen (long white arrow) with proximal small bowel dilatation (orange arrow) and multiple nodes with high density in the mass (short white arrow); B-D: Abdominal contrast-enhanced computed tomography images revealing that the mass exhibited heterogeneous enhancement following contrast administration and there were thick and roundabout blood vessels in the mass (orange arrow). There were multiple dilated intestines and air-fluid level within the intestine (white arrow).

(<http://www.wanfangdata.com.cn/index.html>), and China National Knowledge Infrastructure (CNKI; http://kns.cnki.net/kns/brief/default_result.aspx) databases were investigated between 2009 and 2019 to analyze the clinicopathological features and outcomes of patients with gastrointestinal hemangiomas by searching for MeSH terms and keywords such as “hemangioma”, “capsule endoscopy”, “double balloon enteroscopy”, “anemia”, and “gastrointestinal bleeding”. The reference lists were screened to identify additional relevant studies, and a standardized form was used for data extraction. Finally, there were approximately 25 cases of gastrointestinal hemangiomas^[9-31]. The patient information is summarized in Table 1 to analyze the clinicopathological features (Table 2). The mean age of the patients with gastrointestinal hemangioma was 42.9 years (range: 0-75 years). The sex distribution included 14 males and 11 females (Male:Female = 1.27:1), which is consistent with the results of Durer C *et al*^[14]. Gastrointestinal hemangiomas were mainly located in the jejunum and ileum, accounting for 36% and 24% of all gastrointestinal hemangiomas, respectively. The sizes of the gastrointestinal hemangiomas ranged widely from 0.3 cm to 32.5 cm, and the average size was approximately 7.44 cm. In our case, the patient was a 5-year-old girl, and the lesion was confirmed to be located in the ileum with a size of 9 cm x 6 cm.

Clinically, gastrointestinal hemangiomas are symptomatic in 90% of cases, unlike other benign tumors of the gastrointestinal tract that tend to present as an incidental finding^[32]. The most frequent sign is chronic gastrointestinal bleeding, which causes anemia of an unknown origin and rarely leads to massive bleeding. Occasionally, these tumors may cause intestinal obstructions, intussusception, intramural hematoma, perforation, and platelet sequestration^[2]. Among the 25 patients analyzed in our literature, melena, which was observed in 11 (44%) patients, was the main clinical symptom, followed by anemia in 7 (28%), and dizziness in 5 (20%). However, shock and intestinal obstructions caused by gastrointestinal hemangioma were only observed in 1 (4%) patient. Based on the histological examinations, there have been 15 reported cases of cavernous hemangioma, 3 cases of capillary hemangioma^[16,26,28], 2 cases of racemose hemangioma^[29,31], 1 case of hemolymphangioma^[18], and 1 case of hemangiolymphangioma^[19]. Overall, acute intestinal obstruction and chronic anemia

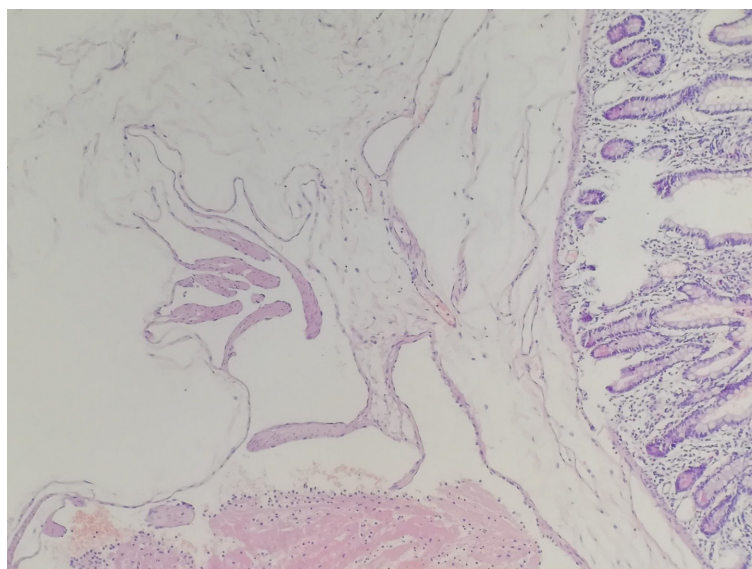


Figure 2 Postoperative histopathological image reveals a small bowel racemose hemangioma (HE, $\times 100$).

caused by a small intestinal racemose hemangioma as in our case are extremely rare.

Gastrointestinal hemangioma is difficult to diagnose preoperatively, especially for small intestinal hemangiomas. Since the most frequent clinical presentation in these patients is gastrointestinal bleeding, the patients frequently undergo gastroscopy and colonoscopy studies with normal results, as in the reported case. However, when the lesions are located in the stomach or colorectal region, gastroscopy and colonoscopy can still have great value in the diagnosis and treatment of this disease. In the literature, among the 25 patients, 10 hemangiomas were located in the stomach or colorectum, 9 of which were diagnosed by endoscopy before the operation. A simple abdominal X-ray may be useful if phleboliths (50% of cases), obstructions, or perforations are present^[1,33]. In our literature review, phleboliths were recognized overlying the right sacrum by a preoperative abdominal X-ray in one case^[11]. CT and CECT are fundamental tools in the preoperative diagnosis of gastrointestinal hemangiomas, especially in emergency situations, because of their speed, availability, and ability to diagnose extraintestinal lesions. Due to the large degree of vascularity, gastrointestinal hemangiomas are homogeneously and significantly enhanced on CECT. Magnetic resonance imaging (MRI), unlike CT, can demonstrate blood flow in the lesion without the administration of contrast medium, and phleboliths are usually void of signal on T1- and T2-weighted images^[1]. For colorectal hemangioma, preoperative MRI can define the size of the lesion, which has great significance for treatment. In our retrospective analysis of 25 patients, half of all positive results before surgery were acquired by CT and/or CECT, and 16% were from MRI. Small bowel video capsule endoscopy (VCE) is a noninvasive imaging test and can be recommended when the source of the bleeding remains unidentified after upper and lower endoscopy. On the other hand, double-balloon enteroscopy (DBE) is an invasive and highly sensitive diagnostic tool that provides both therapeutic and diagnostic interventions^[2]. There were 15 cases of small intestinal hemangioma in our literature, 9 of which were preoperatively diagnosed by small bowel VCE and 6 by DBE. Undoubtedly, small bowel VCE and DBE are very important for the diagnosis of small intestinal hemangiomas. However, small bowel VCE and DBE are not suitable for critical patients with gastrointestinal hemangiomas, such as those with massive hemorrhage, intestinal obstructions, or intussusception. In addition, 30% of the results were false positives, and 20% of the examinations were incomplete^[11].

Based on the literature we reviewed and the CT images of our patient, we summarized the following features of gastrointestinal hemangiomas: (1) CT scan: Tumors tend to appear with mixed density, and there is a blurred boundary between the tumor and the surrounding intestinal tissue; additionally, multiple calcifications representing phleboliths can be recognized inside the tumor on approximately half of all CT studies; (2) CECT: The masses exhibit heterogeneous enhancement following contrast administration; in the venous phase, thick and tortuous blood vessels are present inside the tumor on CT images, and phleboliths can be found in some cases; and (3) For racemose hemangiomas, the characteristic CT manifestations include a dilated feeding artery, malformed vessels, and thick and tortuous draining veins^[11,32,34]. Phleboliths are secondary to thrombosis of the intralesional vessels and subsequent

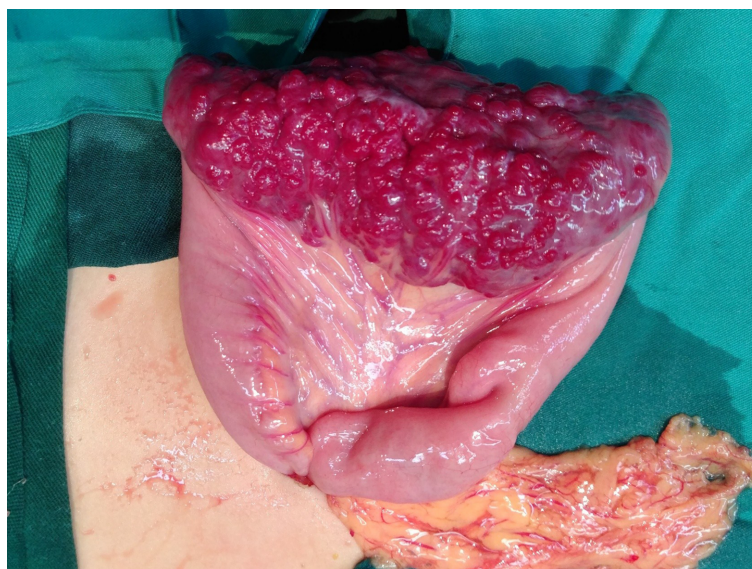

Figure 3 Intraoperative image showing that there was a 10 cm × 4 cm lesion on the ileum with bluish purple coloration and compressible varices on its surface.

partial or total calcifications of the thrombus and are an important diagnostic criterion that can be observed in 26%-50% of adult patients, especially in young patients, and phleboliths are virtually pathognomonic of hemangiomas if they are grouped^[33-35]. Phleboliths and malformed vessels were evident in our case.

The main treatment for hemangiomas is surgical resection of the affected segment^[1,10,36]. Since hemangiomas never metastasize to the lymph nodes or distant organs, local resection is sufficient. However, in some cases of polypoid lesions accessible by endoscopy, especially those located in the stomach or colorectal region, it may be possible to perform polypectomy and cauterization. However, these are still controversial options because of the risk for uncontrollable bleeding and intestinal perforation. In the literature, surgical resection was still the main treatment for gastrointestinal hemangiomas and was applied in 80% of all cases. However, there was an endoscopic resection performed for a stomach hemangioma with a size of 4 cm × 2 cm, resulting in a good clinical course^[48]. In terms of drug therapy, Kaya *et al*^[12] reported a case of neonatal gastric hemangioma successfully cured by propranolol. However, in symptomatic hemangiomas, which may be associated with potentially life-threatening massive bleeding, perforations, intestinal obstructions, and intussusception, surgical resection is the preferred treatment option. Gastrointestinal hemangiomas usually have a satisfying prognosis, and there is no evidence in the literature on the recurrence of hemangiomas^[10,13]. Our patient underwent partial small bowel resection, and two months after the operation, her hemoglobin increased to 123 g/L, with a hematocrit level of 40.6%.

CONCLUSION

In conclusion, hemangiomas of the small intestine are a rare but significant source of gastrointestinal tract bleeding. Since the main symptoms of hemangiomas are not specific, the clinical diagnosis is often delayed or incorrect, and the preoperative diagnosis was mistaken for a teratoma in our case. However, rare pathologies do occur and most importantly, they can present in an unspecific presentation. Therefore, we can say that although gastrointestinal hemangiomas are rare tumors, they should be considered in the differential diagnoses of patients, especially children, who present with gastrointestinal bleeding of an obscure origin or other abdominal symptoms.

Table 1 Gastrointestinal hemangiomas reported in the literature between 2009 and 2019

Ref.	Age (yr)	Sex	Presentation	Preoperative diagnosis study	Hemangioma size (cm)	Location	Histology	Treatment
Attash <i>et al</i> ^[9]	3	M	Hematemesis, anemia	EGD, CECT	17.6 × 13.2	Stomach	Cavernous	Resembling sleeve gastrectomy
Peng <i>et al</i> ^[10]	47	M	Fatigue, dizziness, melena	VCE, CECT	50 × 15	Ileum	Cavernous	Partial small bowel resection
Ocampo <i>et al</i> ^[11]	29	M	Anemia	Abdominal X-ray, CECT	10	Ileum	ND	Segmental small bowel resection
Kaya <i>et al</i> ^[12]	2 d	F	Melena	EGD	ND	Stomach	ND	Propranolol
Fernandes <i>et al</i> ^[13]	56	F	Hematochezia, dizziness	VCE, VECT	14	Ileum	Cavernous	Laparotomy and vascular tumor resection
Durer <i>et al</i> ^[14]	66	M	Anemia	VCE, DBE	2.5	Jejunum	Cavernous	Surgery
Amati <i>et al</i> ^[15]	20	F	Abdominal distention, pain	CT	28 × 26 × 12	Sigmoid colon	Cavernous	Resection of the sigmoid
Wang <i>et al</i> ^[16]	73	M	Melena, weakness, dizziness	VCE, DBE	2 × 1	Ileum	Capillary	Laparotomy
Andrade <i>et al</i> ^[17]	44	F	Melena	Colonoscopy, MRI	7.5 × 3.5	Rectal	ND	Managed conservatively
Li <i>et al</i> ^[18]	68	M	Epigastric discomfort	EUS, CECT	4 × 2	Stomach	Hemolymphangioma	Endoscopic ultrasonography treatment
Iwaya <i>et al</i> ^[19]	70	M	Anemia, melena	VCE, DBE	2 × 1.7 × 1.2	Jejunum	Hemangiolymphangioma	Laparoscopic small bowel resection
Vitor <i>et al</i> ^[20]	18	M	Melena	Colonoscopy, MRI	ND	Rectum	Cavernous	Iron supplementation
Parker <i>et al</i> ^[21]	32	M	Abdominal pain, anorexia, constipation	CT biopsy, MRI	14 × 7 × 7	Ileum	Cavernous	Laparotomy
Ganesanathan <i>et al</i> ^[22]	65	M	Rectal bleeding	Colonoscopy, CT	ND	Left colon and rectum	Cavernous	Managed Conservatively
Takase <i>et al</i> ^[23]	62	M	Anemia, melena	VCE, DBE	1.5	Jejunum	Cavernous	Laparoscopic enterectomy
	52	M	Anemia	CECT, VCE, DBE	1	Ileum	Cavernous	Laparoscopic enterectomy
Kuo <i>et al</i> ^[24]	20	F	Lower abdominal pain, postprandial bloating	CECT	5.6 × 4.6 × 1.5	Jejunum	Cavernous	Segmental resection
Zhang <i>et al</i> ^[25]	44	M	Melena	VCE	ND	Jejunum	Cavernous	Laparotomy with segmental resection
Moein Jahromi <i>et al</i> ^[26]	75	F	Anemia, melena	VCE, DBE	2.7 × 1.7	Jejunum	Capillary	Laparoscopic partial small bowel resection
Fu <i>et al</i> ^[27]	54	F	Painless rectal bleeding	Colonoscopy, CT, MRI	ND	Rectum	Cavernous	3-D laparoscopically assisted surgery
	22	F	Recurrent intermittent rectal bleeding	Colonoscopy, CT	ND	Rectum	Cavernous	3-D laparoscopically assisted surgery
Liao <i>et al</i> ^[28]	11	F	Hematochezia, palpitation, cold sweat	Angiography	1.2 × 1.0	Jejunum	Capillary	Laparoscopic segmental resection

Hu <i>et al</i> ^[29]	31	F	Melena, dizziness	Angiography	0.3 × 0.3	Jejunum	Racemose hemangioma	Laparoscopic segmental resection
Lian <i>et al</i> ^[30]	57	M	Abdominal pain with anus exhausting and defecating	CT	16 × 12 × 8	Jejunum	Cavernous	Reduction of the volvulus and segmental resection
Li <i>et al</i> ^[31]	54	F	Hematemesis, melena, dizziness	EGD, CECT	2 × 2 × 2	Stomach	Racemose hemangioma	Local excision of lesion

ND: Not described; VCE: Video capsule endoscopy; DBE: Double-balloon enteroscopy; CT: Computed tomography; MRI: Magnetic resonance imaging; EUS: Endoscopic ultrasonography; CECT: Contrast-enhanced computed tomography; EGD: Esophagogastroduodenoscopy.

Table 2 Clinicopathological features of gastrointestinal hemangiomas

No. of cases	25		
Age	42.92 ± 22.75 (0-75)	Preoperative diagnosis study	
Sex		CT or CECT	14 (56%)
Male	14 (54%)	Colonoscopy, EGD, or EUS	9 (36%)
Female	11 (44%)	VCE	9 (36%)
Location		DBE	6 (24%)
Jejunum	9 (36%)	MRI	4 (16%)
Ileum	6 (24%)	Angiography	2 (8%)
Colorectum	6 (24%)	Abdominal X-ray	1 (4%)
Stomach	4 (16%)	Histology	
Size	7.44 ± 8.60 ¹ (0.3-32.5)	Cavernous hemangioma	15 (68.2%)
Main symptom		Capillary hemangioma	3 (13.7%)
Melena	11 (44%)	Racemose hemangioma	2 (9.1%)
Anemia	7 (28%)	Hemolymphangioma	1 (4.5%)
Dizziness	5 (20%)	Hemangiolymphangioma	1 (4.5%)
Abdominal distention or pain	5 (20%)	Treatment	
Rectal bleeding or Hematochezia	5 (20%)	Operation	20 (80%)
Hematemesis	2 (8%)	Endoscopy	1 (4%)
Fatigue or weakness	2 (8%)	Medication (propranolol)	1 (4%)
Anorexia or postprandial bloating	2 (8%)	Iron supplementation	1 (4%)
Palpitations or cold sweat	1 (4%)	None	2 (8%)
Anus exhausting and defecating	1 (4%)		

¹The size was the average value of the longitudinal, transverse, and axial lengths of the tumor.

REFERENCES

- Corsi A, Ingegnoli A, Abelli P, De Chiara F, Mancini C, Cavestro GM, Fanigliulo L, Di Mario F, Franzì A, Zompatori M. Imaging of a small bowel cavernous hemangioma: report of a case with emphasis on the use of computed tomography and enteroclysis. *Acta Biomed* 2007; **78**: 139-143 [PMID: 17933282]
- Pera M, Márquez L, Dedeu JM, Sánchez J, García M, Ramón JM, Puigvehí M. Solitary cavernous hemangioma of the small intestine as the cause of long-standing iron deficiency anemia. *J Gastrointest Surg* 2012; **16**: 2288-2290 [PMID: 22875598 DOI: 10.1007/s11605-012-1991-6]
- Regula J, Wronska E, Pachlewski J. Vascular lesions of the gastrointestinal tract. *Best Pract Res Clin Gastroenterol* 2008; **22**: 313-328 [PMID: 18346686 DOI: 10.1016/j.bpg.2007.10.026]
- de Mascarenhas-Saraiva MN, da Silva Araújo Lopes LM. Small-bowel tumors diagnosed by wireless capsule endoscopy: report of five cases. *Endoscopy* 2003; **35**: 865-868 [PMID: 14551868 DOI: 10.1055/s-2003-42625]
- Fishman SJ, Mulliken JB. Hemangiomas and vascular malformations of infancy and childhood. *Pediatr Clin North Am* 1993; **40**: 1177-1200 [PMID: 8255621 DOI: 10.1016/S0031-3955(16)38656-4]
- Seccia A, Salgarello M, Farallo E, Falappa PG. Combined radiological and surgical treatment of arteriovenous malformations of the head and neck. *Ann Plast Surg* 1999; **43**: 359-366 [PMID: 10517461 DOI: 10.1097/00000637-199910000-00003]
- Dimakakos PB, Kotsis TE. Arteriovenous Malformations. In: Liapis CD, Balzer K, Benedetti-Valentini F, Fernandes e Fernandes J. *Vascular Surgery*. Berlin: Springer Berlin Heidelberg, 2007: 573-583. Available from: https://link.springer.com/chapter/10.1007%2F978-3-540-30956-7_50

- 8 Boyle L, Lack EE. Solitary cavernous hemangioma of small intestine. Case report and literature review. *Arch Pathol Lab Med* 1993; 939-941 [PMID: 8368910 DOI: 10.1002/sim.4780121709]
- 9 Attash SM, Ali MS, Al-Nuaimy HA. Isolated cavernous haemangioma of the stomach in a 3-year-old child: an unusual cause of upper GI bleeding. *BMJ Case Rep* 2012; 6: 2012 [PMID: 23045447 DOI: 10.1136/bcr-2012-006979]
- 10 Peng C, Chen H, Li W, Xu R, Zhuang W. A Rare Cause of Recurrent Gastrointestinal Bleeding: Giant Diffuse and Cavernous Intestinal Mesentery Hemangioma in an Adult. *Dig Dis Sci* 2016; 61: 3363-3365 [PMID: 27447475 DOI: 10.1007/s10620-016-4259-2]
- 11 Ocampo Toro WA, Corral Ramos B, Concejo Iglesias P, Cubero Carralero J, Blanco García DF, Barón Ródiz P. Haemangiomas of the Small Intestine: Poorly Known Cause of Gastrointestinal Bleeding of Uncertain Origin. *Cureus* 2018; 10: e3155 [PMID: 30349762 DOI: 10.7759/cureus.3155]
- 12 Kaya H, Gokce IK, Gungor S, Turgut H, Ozdemir R. A Newborn with Gastric Hemangioma Treated Using Propranolol. *Pediatr Gastroenterol Hepatol Nutr* 2018; 21: 341-346 [PMID: 30345249 DOI: 10.5223/pghn.2018.21.4.341]
- 13 Fernandes D, Dionísio I, Neves S, Duarte P. Cavernous hemangioma of small bowel: a rare cause of digestive hemorrhage. *Rev Esp Enferm Dig* 2014; 106: 214-215 [PMID: 25007019]
- 14 Durer C, Durer S, Sharbatji M, Comba IY, Aharoni I, Majeed U. Cavernous Hemangioma of the Small Bowel: A Case Report and Literature Review. *Cureus* 2018; 10: e3113 [PMID: 30338188 DOI: 10.7759/cureus.3113]
- 15 Amati AL, Hecker A, Schwandner T, Ghanem H, Holler J, Reichert M, Padberg W. A hemangioma of the sigmoid colon mesentery presenting as a retroperitoneal tumor: a case report and review. *World J Surg Oncol* 2014; 12: 79 [PMID: 24684941 DOI: 10.1186/1477-7819-12-79]
- 16 Wang B, Lou Z, Zheng W, Zhang J, Liu J. Capillary hemangioma in the ileum: Obscure small-bowel bleeding in an elderly person. *Turk J Gastroenterol* 2018; 29: 520-521 [PMID: 30249572 DOI: 10.5152/tjg.2018.17612]
- 17 Andrade P, Lopes S, Macedo G. Diffuse cavernous hemangioma of the rectum: case report and literature review. *Int J Colorectal Dis* 2015; 30: 1289-1290 [PMID: 26243468 DOI: 10.1007/s00384-015-2329-0]
- 18 Li QY, Xu Q, Fan SF, Zhang Y. Gastric haemolymphangioma: a literature review and report of one case. *Br J Radiol* 2012; 85: e31-e34 [PMID: 22308223 DOI: 10.1259/bjr/31987746]
- 19 Iwaya Y, Streutker CJ, Coneys JG, Marcon N. Hemangiolymphangioma of the small bowel: A rare cause of chronic anemia. *Dig Liver Dis* 2018; 50: 1248 [PMID: 29886080 DOI: 10.1016/j.dld.2018.05.008]
- 20 Vitor S, Oliveira Ferreira A, Lopes J, Velosa J. Hemangioma of the rectum - How misleading can hematochezia be? *Rev Esp Enferm Dig* 2016; 108: 500-501 [PMID: 27554385]
- 21 Parker WT, Harper JG, Rivera DE, Holsten SB, Bowden T. Mesenteric cavernous hemangioma involving small bowel and appendix: a rare presentation of a vascular tumor. *Am Surg* 2009; 75: 811-816 [PMID: 19774953]
- 22 Ganesanathan S, Barlow J, Durai D, Hawthorne AB. Multiple venous malformations in the left colon and rectum: a long-standing case managed conservatively and an update of current literature. *BMJ Case Rep* 2019; 12 [PMID: 30902841 DOI: 10.1136/bcr-2018-227700]
- 23 Takase N, Fukui K, Tani T, Nishimura T, Tanaka T, Harada N, Ueno K, Takamatsu M, Nishizawa A, Okamura A, Kaneda K. Preoperative detection and localization of small bowel hemangioma: Two case reports. *World J Gastroenterol* 2017; 23: 3752-3757 [PMID: 28611528 DOI: 10.3748/wjg.v23.i20.3752]
- 24 Kuo LW, Chuang HW, Chen YC. Small bowel cavernous hemangioma complicated with intussusception: report of an extremely rare case and review of literature. *Indian J Surg* 2015; 77: 123-124 [PMID: 25972669 DOI: 10.1007/s12262-014-1194-3]
- 25 Zhang GY, Luo CJ, Zhao B, Zhan H, Long B, Guo LY, Zhou HN, Jiao ZY. [Small intestinal cavernous hemangioma causing chronic hemorrhage: a case report]. *Nan Fang Yi Ke Da Xue Xue Bao* 2017; 37: 866-868 [PMID: 28736359]
- 26 Moen Jahromi B, Tsai F. Small-bowel hemangioma: rare and hard to find. *Gastrointest Endosc* 2019; 89: 436-437 [PMID: 30359569 DOI: 10.1016/j.gie.2018.10.014]
- 27 Fu ZW, Wang LX, Zhang ZY, Luo QF, Ge HY. Three-dimensional laparoscopy-assisted bowel resection for cavernous hemangioma of the rectum: Report of two cases. *Asian J Endosc Surg* 2019; 12: 337-340 [PMID: 30094939 DOI: 10.1111/ases.12636]
- 28 Liao Ch, Tang HR, Tang HR, Zhang JY, Wang H. Gastrointestinal hemorrhage caused by small intestinal hemangioma in children: a case report. *Zhonghua Waikeputong Zazhi* 2017; 32: 682 [DOI: 10.3760/cma.j.issn.1007-631X.2017.08.014]
- 29 Hu XD, Liu M, Zhang HL, Zhang YN, Feng Y. Lower gastrointestinal hematorrhea induced by hemangioma of jejunum: a case report. *Weichangbingxue He Ganbingxue Zazhi* 2016; 25: 839-840 Available from: http://www.cnki.com.cn/Article_en/CJFDTotat-WCBX201607034.htm
- 30 Lian YJ. Cavernous hemangioma of small intestine with volvulus: a case report. *Zhonghua Waikeputong Zazhi* 2018; 33: 33 [DOI: 10.3760/cma.j.issn.1007-631X.2018.01.010]
- 31 Li SH, Zou WY, Shi SL. Stomach hemangioma: report of one case. *Yixue Yingxiangxue Zazhi* 2011; 22: 829-830 [DOI: 10.3969/j.issn.1008-1062.2011.11.024]
- 32 Huprich JE, Barlow JM, Hansel SL, Alexander JA, Fidler JL. Multiphase CT enterography evaluation of small-bowel vascular lesions. *AJR Am J Roentgenol* 2013; 201: 65-72 [PMID: 23789659 DOI: 10.2214/AJR.12.10414]
- 33 Chen HH, Tu CH, Lee PC, Chiu HH, Wu MS, Wang HP. Endoscopically diagnosed cavernous hemangioma in the deep small intestine: a case report. *Advances in Digestive Medicine* 2015; 2: 74-78 [DOI: 10.1016/j.aidm.2014.03.009]
- 34 Lee NK, Kim S, Kim GH, Jeon TY, Kim DH, Jang HJ, Park DY. Hypervascular subepithelial gastrointestinal masses: CT-pathologic correlation. *Radiographics* 2010; 30: 1915-1934 [PMID: 21057127 DOI: 10.1148/rg.307105028]
- 35 Levy AD, Abbott RM, Rohrmann CA, Frazier AA, Kende A. Gastrointestinal hemangiomas: imaging findings with pathologic correlation in pediatric and adult patients. *AJR Am J Roentgenol* 2001; 177: 1073-1081 [PMID: 11641173 DOI: 10.2214/ajr.177.5.1771073]
- 36 Yoo S. GI-Associated Hemangiomas and Vascular Malformations. *Clin Colon Rectal Surg* 2011; 24: 193-200 [PMID: 22942801 DOI: 10.1055/s-0031-1286003]



Published By Baishideng Publishing Group Inc
7041 Koll Center Parkway, Suite 160, Pleasanton, CA 94566, USA
Telephone: +1-925-3991568
E-mail: bpgoffice@wjgnet.com
Help Desk: <http://www.f6publishing.com/helpdesk>
<http://www.wjgnet.com>

