

# World Journal of *Clinical Cases*

*World J Clin Cases* 2020 May 6; 8(9): 1561-1755





### REVIEW

- 1561** Nutrition management in acute pancreatitis: Clinical practice consideration  
*Lakananurak N, Gramlich L*

### MINIREVIEWS

- 1574** Bone disease in chronic pancreatitis  
*Ahmed A, Deep A, Kothari DJ, Sheth SG*
- 1580** Role of microRNAs in the predisposition to gastrointestinal malignancies  
*Baz M, Ibrahim T*
- 1586** Recurrent anal fistulas: When, why, and how to manage?  
*Emile SH*

### ORIGINAL ARTICLE

#### Case Control Study

- 1592** Removal of biofilm is essential for long-term ventilation tube retention  
*Ma Q, Wang H, Chen ZN, Wu YQ, Yu DZ, Wang PJ, Shi HB, Su KM*

#### Retrospective Cohort Study

- 1600** Neutrophil gelatinase-associated lipocalin does not predict acute kidney injury in heart failure  
*Ferrari F, Scalzotto E, Esposito P, Samoni S, Mistrorigo F, Rizo Topete LM, De Cal M, Virzi GM, Corradi V, Torregrossa R, Valle R, Bianzina S, Aspromonte N, Floris M, Fontanelli A, Brendolan A, Ronco C*
- 1608** Prognosis factors of advanced gastric cancer according to sex and age  
*Alshehri A, Alanezi H, Kim BS*

#### Observational Study

- 1620** Attitudes, knowledge levels and behaviors of Islamic religious officials about organ donation in Turkey: National survey study  
*Akbulut S, Ozer A, Firinci B, Saritas H, Demyati K, Yilmaz S*
- 1632** Serotonin transporter and cholecystokinin in diarrhea-predominant irritable bowel syndrome: Associations with abdominal pain, visceral hypersensitivity and psychological performance  
*Qin G, Zhang Y, Yao SK*

## CASE REPORT

- 1642** Cholesteryl ester storage disease of clinical and genetic characterisation: A case report and review of literature  
*Rashu EB, Junker AE, Danielsen KV, Dahl E, Hamberg O, Borgwardt L, Christensen VB, Wewer Albrechtsen NJ, Gluud LL*
- 1651** Seroconversion of HBsAG coincides super-infection with hepatitis A: A case report  
*Beisel C, Addo MM, zur Wiesch JS*
- 1656** Liver cirrhosis in a child associated with Castleman's disease: A case report  
*Kobayashi S, Inui A, Tsunoda T, Umetsu S, Sogo T, Mori M, Shinkai M, Fujisawa T*
- 1666** Granulocyte colony-stimulating factor-producing squamous cell carcinoma of the tongue exhibiting characteristic fluorine-18 deoxyglucose accumulation on positron emission tomography-computed tomography: A case report  
*Shimamoto H, Hirota Y, Kashima Y, Kinoshita N, Yokokawa M, Ikeda T, Harada H*
- 1674** Expander implantation for correction of high-riding nipple with enlarged nipple-areola complex using revision mastopexy: A case report  
*Qin F, Yu NZ, Yang E, Zeng A, Hao Y, Zhu L, Wang XJ*
- 1679** Pyoderma gangrenosum confused with congenital preauricular fistula infection: A case report  
*Zhao Y, Fang RY, Feng GD, Cui TT, Gao ZQ*
- 1685** Central nervous system relapse in a pediatric anaplastic large cell lymphoma patient with CLTC/ALK translocation treated with alectinib: A case report  
*Yang J, Li J, Gu WY, Jin L, Duan YL, Huang S, Zhang M, Wang XS, Liu Y, Zhou CJ, Gao C, Zheng HY, Zhang YH*
- 1693** Colonic perforation in a nasopharyngeal carcinoma patient treated with fluorouracil: A case report  
*Lu WJ, Li G, Gao L*
- 1698** Thoracoscopic resection of a huge esophageal dedifferentiated liposarcoma: A case report  
*Ye YW, Liao MY, Mou ZM, Shi XX, Xie YC*
- 1705** COVID-19 managed with early non-invasive ventilation and a bundle pharmacotherapy: A case report  
*Peng M, Ren D, Liu XY, Li JX, Chen RL, Yu BJ, Liu YF, Meng X, Lyu YS*
- 1713** Application of curved ablation in liver cancer with special morphology or location: Report of two cases  
*Cao N, Cai HJ, Sun XX, Liu DL, Huang B*
- 1721** Giant ventral hernia simultaneously containing the spleen, a portion of the pancreas and the left hepatic lobe: A case report  
*Luo XG, Lu C, Wang WL, Zhou F, Yu CZ*

- 1729** Endoscopic ultrasonography elastography in the diagnosis of intrapancreatic ectopic spleen: A case report  
*Ge N, Sun SY*
- 1735** Mesonephric adenocarcinoma of the uterine cervix with rare lung metastases: A case report and review of the literature  
*Jiang LL, Tong DM, Feng ZY, Liu KR*
- 1745** Portal hypertension in a patient with biliary hamartomas: A case report  
*Li QQ, Guo XZ, Li HY, Qi XS*

**LETTER TO THE EDITOR**

- 1752** Rare primary lymphoepithelioma-like carcinoma of the renal pelvis  
*Lai SC, Seery S, Diao TX, Wang JY, Liu M*

**ABOUT COVER**

Editorial Board Member of *World Journal of Clinical Cases*, Paul E Sijens, PhD, Associate Professor, Department of Radiology, University Medical Center Groningen and University of Groningen, Groningen 9713 GZ, Netherlands

**AIMS AND SCOPE**

The primary aim of *World Journal of Clinical Cases* (WJCC, *World J Clin Cases*) is to provide scholars and readers from various fields of clinical medicine with a platform to publish high-quality clinical research articles and communicate their research findings online.

WJCC mainly publishes articles reporting research results and findings obtained in the field of clinical medicine and covering a wide range of topics, including case control studies, retrospective cohort studies, retrospective studies, clinical trials studies, observational studies, prospective studies, randomized controlled trials, randomized clinical trials, systematic reviews, meta-analysis, and case reports.

**INDEXING/ABSTRACTING**

The WJCC is now indexed in PubMed, PubMed Central, Science Citation Index Expanded (also known as SciSearch®), and Journal Citation Reports/Science Edition. The 2019 Edition of Journal Citation Reports cites the 2018 impact factor for WJCC as 1.153 (5-year impact factor: N/A), ranking WJCC as 99 among 160 journals in Medicine, General and Internal (quartile in category Q3).

**RESPONSIBLE EDITORS FOR THIS ISSUE**

Responsible Electronic Editor: *Yan-Xia Xing*

Proofing Production Department Director: *Yun-Xiaojuan Wu*

Responsible Editorial Office Director: *Jin-Lai Wang*

**NAME OF JOURNAL**

*World Journal of Clinical Cases*

**ISSN**

ISSN 2307-8960 (online)

**LAUNCH DATE**

April 16, 2013

**FREQUENCY**

Semimonthly

**EDITORS-IN-CHIEF**

Dennis A Bloomfield, Bao-Gan Peng, Sandro Vento

**EDITORIAL BOARD MEMBERS**

<https://www.wjgnet.com/2307-8960/editorialboard.htm>

**PUBLICATION DATE**

May 6, 2020

**COPYRIGHT**

© 2020 Baishideng Publishing Group Inc

**INSTRUCTIONS TO AUTHORS**

<https://www.wjgnet.com/bpg/gerinfo/204>

**GUIDELINES FOR ETHICS DOCUMENTS**

<https://www.wjgnet.com/bpg/GerInfo/287>

**GUIDELINES FOR NON-NATIVE SPEAKERS OF ENGLISH**

<https://www.wjgnet.com/bpg/gerinfo/240>

**PUBLICATION ETHICS**

<https://www.wjgnet.com/bpg/GerInfo/288>

**PUBLICATION MISCONDUCT**

<https://www.wjgnet.com/bpg/gerinfo/208>

**ARTICLE PROCESSING CHARGE**

<https://www.wjgnet.com/bpg/gerinfo/242>

**STEPS FOR SUBMITTING MANUSCRIPTS**

<https://www.wjgnet.com/bpg/GerInfo/239>

**ONLINE SUBMISSION**

<https://www.f6publishing.com>

# Endoscopic ultrasonography elastography in the diagnosis of intrapancreatic ectopic spleen: A case report

Nan Ge, Si-Yu Sun

**ORCID number:** Nan Ge (0000-0002-5764-7054); Si-Yu Sun (0000-0002-7308-0473).

**Author contributions:** Ge N and Sun SY contributed to study planning and manuscript drafting.

**Supported by** Natural Science Fund of Liaoning Province, No. 20180530014.

**Informed consent statement:** Informed written consent was obtained from the relatives of the patient for publication of this report and any accompanying images.

**Conflict-of-interest statement:** The authors declare that they have no conflict of interest.

**Open-Access:** This article is an open-access article that was selected by an in-house editor and fully peer-reviewed by external reviewers. It is distributed in accordance with the Creative Commons Attribution NonCommercial (CC BY-NC 4.0) license, which permits others to distribute, remix, adapt, build upon this work non-commercially, and license their derivative works on different terms, provided the original work is properly cited and the use is non-commercial. See: <http://creativecommons.org/licenses/by-nc/4.0/>

**Manuscript source:** Unsolicited manuscript

**Received:** December 22, 2019

**Peer-review started:** December 23, 2019

**First decision:** February 20, 2020

**Nan Ge, Si-Yu Sun,** Department of Gastroenterology, Shengjing Hospital of China Medical University, Shenyang 110004, Liaoning Province, China

**Corresponding author:** Si-Yu Sun, MD, PhD, Chief Doctor, Director, Professor, Department of Gastroenterology, Shengjing Hospital of China Medical University, No. 36 Sanhao Street, Shenyang 110004, Liaoning Province, China. [sunsy@sj-hospital.org](mailto:sunsy@sj-hospital.org)

## Abstract

### BACKGROUND

Intrapancreatic accessory spleen (IPAS) mimics a pancreatic neoplasm on imaging studies, and due to the lack of radiological diagnostic criteria, patients undergo unnecessary distal pancreatectomies. Endoscopic ultrasonography (EUS) is a reliable and efficient diagnostic modality for pancreatic diseases. However, no EUS criteria have been established for IPAS. We present the EUS-elastography image of IPAS, which may minimize the chance of misdiagnosis in the future.

### CASE SUMMARY

A 50-year-old man was referred for an EUS evaluation after computed tomography showed a hypervascular enhanced mass in the tail of the pancreas, which indicated a neuroendocrine neoplasm. EUS elastography demonstrated that the lesion of interest covered no more than 25% of the region of interest. The patient underwent distal pancreatectomy. However, the resected tissue was evaluated, and the patient was finally diagnosed with IPAS.

### CONCLUSION

IPAS should be considered in patients with suspected pancreatic neuroendocrine tumors of the pancreatic tail before surgery is performed. The differentiation between IPAS and pancreatic neuroendocrine tumors can be demonstrated using EUS-elastography.

**Key words:** Intrapancreatic accessory spleen; Endoscopic ultrasonography; Elastography; Case report

©The Author(s) 2020. Published by Baishideng Publishing Group Inc. All rights reserved.

**Core tip:** We report the case of a patient with intrapancreatic accessory spleen evaluated by endoscopic ultrasonography and endoscopic ultrasonography elastography. We present the endoscopic ultrasound-elastography features of intrapancreatic accessory

**Revised:** March 15, 2020  
**Accepted:** April 10, 2020  
**Article in press:** April 10, 2020  
**Published online:** May 6, 2020

**P-Reviewer:** Kramer JR, Maurea S  
**S-Editor:** Tang JZ  
**L-Editor:** Webster JR  
**E-Editor:** Xing YX



spleen, which may help to minimize the chance of misdiagnosis and prevent patients from undergoing unnecessary surgery in the future.

**Citation:** Ge N, Sun SY. Endoscopic ultrasonography elastography in the diagnosis of intrapancreatic ectopic spleen: A case report. *World J Clin Cases* 2020; 8(9): 1729-1734  
**URL:** <https://www.wjnet.com/2307-8960/full/v8/i9/1729.htm>  
**DOI:** <https://dx.doi.org/10.12998/wjcc.v8.i9.1729>

## INTRODUCTION

The identification of incidental pancreatic lesions is increasing due to advancements in imaging. Diagnosis remains a challenge for clinicians, with intrapancreatic accessory spleen (IPAS) posing a unique dilemma. IPAS mimics a pancreatic neoplasm on imaging studies, and due to the lack of radiological diagnostic criteria, patients undergo unnecessary distal pancreatectomy. Endoscopic ultrasonography (EUS) is one of the most reliable and efficient diagnostic modalities for pancreatic diseases. However, no EUS criteria have been established for IPAS. The use of EUS-elastography may increase diagnostic accuracy. Herein, we present the EUS-elastography image of IPAS.

## CASE PRESENTATION

### Chief complaints

A 50-year-old male patient was referred from the surgery department for an EUS evaluation after a computed tomography scan showed a 1.4-cm round hypervascular enhanced mass in the tail of the pancreas, which indicated a neuroendocrine neoplasm (Figure 1).

### History of present illness

Initially, the mass was found following a computed tomography examination during his regular medical examination. The patient did not complain of any symptoms.

### History of past illness

He has no specific history of past illness.

### Personal and family history

He has no specific personal or family history.

### Physical examination upon admission

The patient did not have positive signs on physical examination.

### Imaging examinations

EUS revealed a 1.2 cm × 1.3 cm, round, well-defined homogenous hypoechoic mass in the pancreatic tail with no other endosonographic pancreatic abnormalities (Figure 2).

EUS elastography was performed and it was found that the lesion covered no more than 25% of the region of interest. To assess the quality and reproducibility of the elastography image, the image was frozen and the stored cine loop was reviewed frame by frame. A consistent color pattern obtained in a number of consecutive frames indicating a good, reliable technique.

The lesion showed a heterogeneous, predominantly green pattern with slight yellow and blue lines, indicating a soft texture (Figure 3).

Real-time tissue quantitative elastography with strain ratio (SR) measurement was also performed. Region of interest A was placed within the pancreatic tail mass and region of interest B in the adjacent parenchyma. An SR (B/A) of 0.74 indicated the softer elasticity of the lesion compared with the surrounding normal pancreatic tissue (Figure 4).

## FINAL DIAGNOSIS

The patient was finally diagnosed with IPAS.



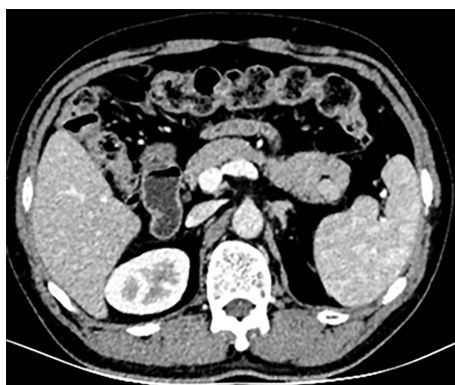


Figure 1 Computed tomography image of the intrapancreatic accessory spleen.

## TREATMENT

The patient underwent distal pancreatectomy as initial CT indicated a neuroendocrine neoplasm.

## OUTCOME AND FOLLOW-UP

Pathological evaluation of the resected tissue showed a 1.3-cm nodule with a complete capsule in the pancreatic tissue, and the nodule was composed entirely of spleen tissue. The final diagnosis was IPAS. The patient had no adverse effects after surgery.

## DISCUSSION

Accessory spleen is a congenital failure of splenic bud fusion during embryogenesis, which is revealed in about 10%-30% of autopsies<sup>[1]</sup>. In most cases, accessory spleens are located near the splenic hilum. The second most common site is the pancreatic tail (17%). IPAS can mimic intrapancreatic tumors, such as neuroendocrine neoplasms<sup>[2-4]</sup>. IPAS is often misdiagnosed as a neuroendocrine neoplasm and treated with distal pancreatectomy. However, asymptomatic IPAS does not require medical treatment, or even surgical resection.

It is important to provide accurate preoperative differential diagnostics to prevent patients undergoing unnecessary surgery.

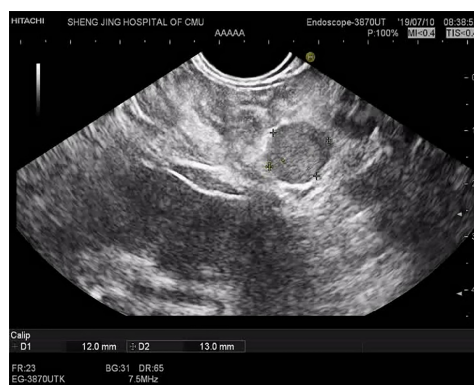EUS has high resolution and is considered one of the most reliable and efficient diagnostic modalities for pancreatobiliary diseases<sup>[5-7]</sup>.

Elastography is a new technique for tissue characterization, providing a noninvasive modality for imaging the mechanical properties of tissue<sup>[8]</sup>. EUS elastography is able to better characterize lesions by tissue stiffness evaluation in various locations which are only accessible from the gastrointestinal tract. Elastography can be adjunct to the EUS examination due to its ease of use, noninvasiveness, and low cost.

EUS elastography for the evaluation of pancreatic tissue was first reported in 2006. The pooled sensitivity and specificity of EUS elastography from 15 studies were 93% and 63%, respectively<sup>[9]</sup>. Most malignant pancreatic lesions appear stiff in elastography<sup>[10]</sup>. It is also reported that in patients with small solid pancreatic lesions, EUS elastography can play an important role in ruling out malignancy if the lesion appears soft<sup>[11]</sup>.

Based on qualitative elastographic evaluation, up to 4 well-defined patterns have been described that characterize solid pancreatic lesions and contribute to their classification: A homogeneous green pattern present commonly in the normal pancreas; a heterogeneous, predominantly green pattern with slight yellow and red lines present only in inflammatory pancreatic masses; a heterogeneous, predominantly blue pattern with small green areas and red lines and a geographic appearance present mainly in pancreatic malignant tumors (including pancreatic adenocarcinoma); and a homogeneous blue pattern present only in pancreatic neuroendocrine malignant lesions<sup>[12]</sup>. Giovannini *et al*<sup>[13]</sup>, using this qualitative evaluation, reported that the sensitivity and specificity for malignancy were 100% and





**Figure 2** Endoscopic ultrasonography image of the intrapancreatic accessory spleen.

67%, respectively. In our case, the lesion showed a heterogeneous, predominantly green pattern with slight yellow and blue lines on qualitative elastographic evaluation, which may exclude pancreatic malignant tumors or neuroendocrine malignant lesions.

SR calculation is based on standard qualitative EUS elastography data<sup>[14]</sup>. Two different areas (A and B) are selected for quantitative elastographic analysis. Area A is selected including as much of the target lesion as possible without including the surrounding tissues. Area B is selected within a soft reference area outside the target lesion. The SR is calculated as the quotient of B/A. In the past few years, several studies have been conducted to determine the accuracy of SR for detecting malignancies. Different cut-off values have been defined, from 3.7 to 24, with sensitivities ranging from 67% to 98%, and specificity ranging from 45% to 71%<sup>[15-20]</sup>. In our case, an SR of 0.74 indicated the soft texture of the lesion, which is seldom found in pancreatic malignant tumors or neuroendocrine malignant lesions<sup>[12]</sup>. When we reviewed the video of the EUS examination, we noticed that this pancreatic tail lesion also had an echogenicity similar to the adjacent spleen tissue.

Recently, Bhutani *et al*<sup>[21]</sup> reported that the “bridge sign” in EUS images may differentiate IPAS from a pancreatic neuroendocrine tumor, which could save the patient an EUS-fine needle aspiration, diagnostic confusion, surgery, anxiety, and healthcare dollars. Therefore, when combined with EUS-elastography, IPAS may not be misdiagnosed by EUS in the future. Moreover, unnecessary surgery and other invasive intervention may be avoided, similar to the current irreplaceable role of EUS diagnosis of gastric ectopic pancreas.

## CONCLUSION

IPAS is a relevant differential diagnosis in patients with suspected pancreatic neuroendocrine tumors of the pancreatic tail, which should be considered before surgery is undertaken. Non-invasive differentiation between IPAS and pancreatic neuroendocrine tumors can be provided using EUS-elastography.

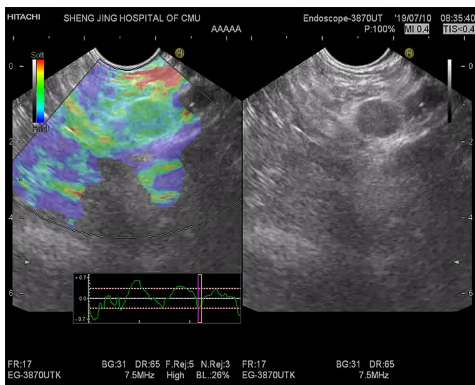


Figure 3 Qualitative elastographic evaluation image of the intrapancreatic accessory spleen.

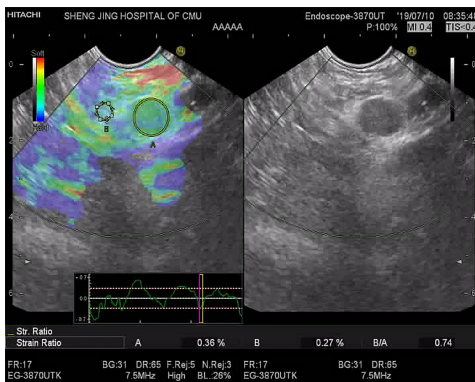


Figure 4 Strain ratio evaluation of the intrapancreatic accessory spleen.

## REFERENCES

- 1 **Dodds WJ**, Taylor AJ, Erickson SJ, Stewart ET, Lawson TL. Radiologic imaging of splenic anomalies. *AJR Am J Roentgenol* 1990; **155**: 805-810 [PMID: [2119113](#) DOI: [10.2214/ajr.155.4.2119113](#)]
- 2 **Zhu HX**, Lou WH, Kuang TT, Wang DS. Post-splenectomy intrapancreatic accessory spleen mimicking endocrine tumor of the pancreas. *Int J Surg Case Rep* 2014; **5**: 1151-1153 [PMID: [25437661](#) DOI: [10.1016/j.ijscr.2014.11.032](#)]
- 3 **Engler CC**, Lemke J, Kornmann M, Barth TF, Schmidt SA, Henne-Bruns D. Ectopic spleen and liver hemangioma mimicking metastatic pancreatic neuroendocrine tumor. *Int J Surg Case Rep* 2015; **17**: 139-142 [PMID: [26670205](#) DOI: [10.1016/j.ijscr.2015.10.041](#)]
- 4 **Kurmann A**, Michel JM, Stauffer E, Egger B. Intrapancreatic Accessory Spleen Misdiagnosed as a Nonsecreting Endocrine Tumor: Case Report and Review of the Literature. *Case Rep Gastroenterol* 2010; **4**: 210-214 [PMID: [20805946](#) DOI: [10.1159/000318857](#)]
- 5 **Laghi A**, Zerunian M, Caruso D. How new technologies could impact on radiology diagnosis and assessment of pancreatic lesions: Future perspectives. *Endosc Ultrasound* 2018; **7**: 310-313 [PMID: [30323159](#) DOI: [10.4103/eus.eus\\_47\\_18](#)]
- 6 **Sato A**, Irisawa A, Bhutani MS, Shibukawa G, Yamabe A, Fujisawa M, Igarashi R, Arakawa N, Yoshida Y, Abe Y, Maki T, Hoshi K, Ohira H. Significance of normal appearance on endoscopic ultrasonography in the diagnosis of early chronic pancreatitis. *Endosc Ultrasound* 2018; **7**: 110-118 [PMID: [28685746](#) DOI: [10.4103/2303-9027.209870](#)]
- 7 **Dong Y**, D'Onofrio M, Hocke M, Jenssen C, Potthoff A, Atkinson N, Ignee A, Dietrich CF. Autoimmune pancreatitis: Imaging features. *Endosc Ultrasound* 2018; **7**: 196-203 [PMID: [28836516](#) DOI: [10.4103/eus.eus\\_23\\_17](#)]
- 8 **Dietrich CF**, Bibby E, Jenssen C, Saftoiu A, Iglesias-Garcia J, Havre RF. EUS elastography: How to do it? *Endosc Ultrasound* 2018; **7**: 20-28 [PMID: [29451165](#) DOI: [10.4103/eus.eus\\_49\\_17](#)]
- 9 **Kitano M**, Yoshida T, Itonaga M, Tamura T, Hatamaru K, Yamashita Y. Impact of endoscopic ultrasonography on diagnosis of pancreatic cancer. *J Gastroenterol* 2019; **54**: 19-32 [PMID: [30406288](#) DOI: [10.1007/s00535-018-1519-2](#)]
- 10 **Harmsen FR**, Domagk D, Dietrich CF, Hocke M. Discriminating chronic pancreatitis from pancreatic cancer: Contrast-enhanced EUS and multidetector computed tomography in direct comparison. *Endosc Ultrasound* 2018; **7**: 395-403 [PMID: [30246709](#) DOI: [10.4103/eus.eus\\_24\\_18](#)]
- 11 **Ignee A**, Jenssen C, Arcidiacono PG, Hocke M, Möller K, Saftoiu A, Will U, Fusaroli P, Iglesias-Garcia J, Ponnudurai R, Petrone MC, Braden B, Burmester E, Dong Y, Atkinson NS, Dietrich CF. Endoscopic ultrasound elastography of small solid pancreatic lesions: a multicenter study. *Endoscopy* 2018; **50**: 1071-1079 [PMID: [29689572](#) DOI: [10.1055/a-0588-4941](#)]
- 12 **Iglesias-Garcia J**, Lariño-Noia J, Domínguez-Muñoz JE. New diagnostic techniques for the differential diagnosis of pancreatic mass: Elastography helps me 100. *Endosc Ultrasound* 2017; **6**: S115-S118 [PMID: [28836516](#) DOI: [10.4103/eus.eus\\_23\\_17](#)]

- 29387706 DOI: [10.4103/eus.eus\\_76\\_17](https://doi.org/10.4103/eus.eus_76_17)]
- 13 **Giovannini M**, Hookey LC, Bories E, Pesenti C, Monges G, Delperio JR. Endoscopic ultrasound elastography: the first step towards virtual biopsy? Preliminary results in 49 patients. *Endoscopy* 2006; **38**: 344-348 [PMID: [16680632](https://pubmed.ncbi.nlm.nih.gov/16680632/) DOI: [10.1055/s-2006-925158](https://doi.org/10.1055/s-2006-925158)]
- 14 **Iglesias-García J**, Lariño-Noia J, Domínguez-Muñoz JE. New Imaging Techniques: Endoscopic Ultrasound-Guided Elastography. *Gastrointest Endosc Clin N Am* 2017; **27**: 551-567 [PMID: [28918798](https://pubmed.ncbi.nlm.nih.gov/28918798/) DOI: [10.1016/j.giec.2017.06.001](https://doi.org/10.1016/j.giec.2017.06.001)]
- 15 **Dawwas MF**, Taha H, Leeds JS, Nayar MK, Oppong KW. Diagnostic accuracy of quantitative EUS elastography for discriminating malignant from benign solid pancreatic masses: a prospective, single-center study. *Gastrointest Endosc* 2012; **76**: 953-961 [PMID: [22854060](https://pubmed.ncbi.nlm.nih.gov/22854060/) DOI: [10.1016/j.gie.2012.05.034](https://doi.org/10.1016/j.gie.2012.05.034)]
- 16 **Lee TH**, Cho YD, Cha SW, Cho JY, Jang JY, Jeong SW, Choi HJ, Moon JH. Endoscopic ultrasound elastography for the pancreas in Korea: a preliminary single center study. *Clin Endosc* 2013; **46**: 172-177 [PMID: [23614128](https://pubmed.ncbi.nlm.nih.gov/23614128/) DOI: [10.5946/ce.2013.46.2.172](https://doi.org/10.5946/ce.2013.46.2.172)]
- 17 **Havre RF**, Ødegaard S, Gilja OH, Nesje LB. Characterization of solid focal pancreatic lesions using endoscopic ultrasonography with real-time elastography. *Scand J Gastroenterol* 2014; **49**: 742-751 [PMID: [24713038](https://pubmed.ncbi.nlm.nih.gov/24713038/) DOI: [10.3109/00365521.2014.905627](https://doi.org/10.3109/00365521.2014.905627)]
- 18 **Rustemovic N**, Opacic D, Ostojic Z, Opacic M, Ledinsky I, Višjić A, Ravić KG, Iveković H, Markoš P. Comparison of elastography methods in patients with pancreatic masses. *Endosc Ultrasound* 2014; **3**: S4 [PMID: [26425528](https://pubmed.ncbi.nlm.nih.gov/26425528/)]
- 19 **Kongkam P**, Lakananurak N, Navicharern P, Chantarojanasiri T, Aye K, Ridditid W, Kritisin K, Angsuwatcharakon P, Aniwat S, Pittayanon R, Sampatanukul P, Treeprasertsuk S, Kullavanijaya P, Rerknimitr R. Combination of EUS-FNA and elastography (strain ratio) to exclude malignant solid pancreatic lesions: A prospective single-blinded study. *J Gastroenterol Hepatol* 2015; **30**: 1683-1689 [PMID: [26238152](https://pubmed.ncbi.nlm.nih.gov/26238152/) DOI: [10.1111/jgh.13067](https://doi.org/10.1111/jgh.13067)]
- 20 **Mayerle J**, Beyer G, Simon P, Dickson EJ, Carter RC, Duthie F, Lerch MM, McKay CJ. Prospective cohort study comparing transient EUS guided elastography to EUS-FNA for the diagnosis of solid pancreatic mass lesions. *Pancreatol* 2016; **16**: 110-114 [PMID: [26602088](https://pubmed.ncbi.nlm.nih.gov/26602088/) DOI: [10.1016/j.pan.2015.10.003](https://doi.org/10.1016/j.pan.2015.10.003)]
- 21 **Bhutani MS**, Singh BS, Cazacu IM, Saftoiu A. Differentiating intrapancreatic accessory spleen from a pancreatic neuroendocrine tumor or metastasis by the "bridge sign". *Endosc Ultrasound* 2019; **8**: 281-282 [PMID: [31249165](https://pubmed.ncbi.nlm.nih.gov/31249165/) DOI: [10.4103/eus.eus\\_29\\_19](https://doi.org/10.4103/eus.eus_29_19)]



Published By Baishideng Publishing Group Inc  
7041 Koll Center Parkway, Suite 160, Pleasanton, CA 94566, USA  
Telephone: +1-925-3991568  
E-mail: [bpgoffice@wjgnet.com](mailto:bpgoffice@wjgnet.com)  
Help Desk: <https://www.f6publishing.com/helpdesk>  
<https://www.wjgnet.com>

