

World Journal of *Gastroenterology*

World J Gastroenterol 2020 April 7; 26(13): 1382-1545



**OPINION REVIEW**

- 1382** Hereditary gastric cancer: Three rules to reduce missed diagnoses
Assumpção P, Araújo T, Khayat A, Ishak G, Santos S, Barra W, Acioli JF, Rossi B, Assumpção P

REVIEW

- 1394** Mouse models of colorectal cancer: Past, present and future perspectives
Bürtin F, Mullins CS, Linnebacher M
- 1427** Possible role of intestinal stem cells in the pathophysiology of irritable bowel syndrome
El-Salhy M

MINIREVIEWS

- 1439** Review of the diagnosis of gastrointestinal lanthanum deposition
Iwamuro M, Urata H, Tanaka T, Okada H

ORIGINAL ARTICLE**Basic Study**

- 1450** Calpain-2 activity promotes aberrant endoplasmic reticulum stress-related apoptosis in hepatocytes
Xie RJ, Hu XX, Zheng L, Cai S, Chen YS, Yang Y, Yang T, Han B, Yang Q

Clinical and Translational Research

- 1463** Clinical relevance of increased serum preneoplastic antigen in hepatitis C-related hepatocellular carcinoma
Yamashita S, Kato A, Akatsuka T, Sawada T, Asai T, Koyama N, Okita K

Case Control Study

- 1474** Effects of long non-coding RNA Opa-interacting protein 5 antisense RNA 1 on colon cancer cell resistance to oxaliplatin and its regulation of microRNA-137
Liang J, Tian XF, Yang W

Retrospective Study

- 1490** Effectiveness and safety of a laparoscopic training system combined with modified reconstruction techniques for total laparoscopic distal gastrectomy
Zhang S, Orita H, Egawa H, Matsui R, Yamauchi S, Yube Y, Kaji S, Takahashi T, Oka S, Inaki N, Fukunaga T
- 1501** Preoperative gamma-glutamyltransferase to lymphocyte ratio predicts long-term outcomes in intrahepatic cholangiocarcinoma patients following hepatic resection
Wang JJ, Li H, Li JX, Xu L, Wu H, Zeng Y

Observational Study

- 1513** Evaluation of ^{177}Lu -Dotatate treatment in patients with metastatic neuroendocrine tumors and prognostic factors
Abou Jokh Casas E, Pubul Núñez V, Anido-Herranz U, del Carmen Mallón Araujo M, del Carmen Pombo Pasin M, Garrido Pumar M, Cabezas Agrícola JM, Cameselle-Teijeiro JM, Hilal A, Ruibal Morell Á
- 1525** Add-on pegylated interferon augments hepatitis B surface antigen clearance *vs* continuous nucleos(t)ide analog monotherapy in Chinese patients with chronic hepatitis B and hepatitis B surface antigen ≤ 1500 IU/mL: An observational study
Wu FP, Yang Y, Li M, Liu YX, Li YP, Wang WJ, Shi JJ, Zhang X, Jia XL, Dang SS

CASE REPORT

- 1540** Small intestinal hemolymphangioma treated with enteroscopic injection sclerotherapy: A case report and review of literature
Xiao NJ, Ning SB, Li T, Li BR, Sun T

ABOUT COVER

Associate Editor of *World Journal of Gastroenterology*, Roberto J Firpi, MD, Associate Professor, Attending Doctor, Department of Medicine, University of Florida, Gainesville, FL 32610, United States

AIMS AND SCOPE

The primary aim of *World Journal of Gastroenterology* (WJG, *World J Gastroenterol*) is to provide scholars and readers from various fields of gastroenterology and hepatology with a platform to publish high-quality basic and clinical research articles and communicate their research findings online.

WJG mainly publishes articles reporting research results and findings obtained in the field of gastroenterology and hepatology and covering a wide range of topics including gastroenterology, hepatology, gastrointestinal endoscopy, gastrointestinal surgery, gastrointestinal oncology, and pediatric gastroenterology.

INDEXING/ABSTRACTING

The WJG is now indexed in Current Contents®/Clinical Medicine, Science Citation Index Expanded (also known as SciSearch®), Journal Citation Reports®, Index Medicus, MEDLINE, PubMed, PubMed Central, and Scopus. The 2019 edition of Journal Citation Report® cites the 2018 impact factor for WJG as 3.411 (5-year impact factor: 3.579), ranking WJG as 35th among 84 journals in gastroenterology and hepatology (quartile in category Q2). CiteScore (2018): 3.43.

RESPONSIBLE EDITORS FOR THIS ISSUE

Responsible Electronic Editor: *Yu-Jie Ma*
Proofing Production Department Director: *Xiang Li*

NAME OF JOURNAL

World Journal of Gastroenterology

ISSN

ISSN 1007-9327 (print) ISSN 2219-2840 (online)

LAUNCH DATE

October 1, 1995

FREQUENCY

Weekly

EDITORS-IN-CHIEF

Subrata Ghosh, Andrzej S Tarnawski

EDITORIAL BOARD MEMBERS

<http://www.wjgnet.com/1007-9327/editorialboard.htm>

EDITORIAL OFFICE

Ze-Mao Gong, Director

PUBLICATION DATE

April 7, 2020

COPYRIGHT

© 2020 Baishideng Publishing Group Inc

INSTRUCTIONS TO AUTHORS

<https://www.wjgnet.com/bpg/gerinfo/204>

GUIDELINES FOR ETHICS DOCUMENTS

<https://www.wjgnet.com/bpg/GerInfo/287>

GUIDELINES FOR NON-NATIVE SPEAKERS OF ENGLISH

<https://www.wjgnet.com/bpg/gerinfo/240>

PUBLICATION MISCONDUCT

<https://www.wjgnet.com/bpg/gerinfo/208>

ARTICLE PROCESSING CHARGE

<https://www.wjgnet.com/bpg/gerinfo/242>

STEPS FOR SUBMITTING MANUSCRIPTS

<https://www.wjgnet.com/bpg/GerInfo/239>

ONLINE SUBMISSION

<https://www.f6publishing.com>



Small intestinal hemolymphangioma treated with enteroscopic injection sclerotherapy: A case report and review of literature

Nian-Jun Xiao, Shou-Bin Ning, Teng Li, Bai-Rong Li, Tao Sun

ORCID number: Nian-Jun Xiao (0000-0002-4055-7968); Shou-Bin Ning (0000-0001-7204-3956); Teng Li (0000-0002-3637-3656); Bai-Rong Li (0000-0001-5758-4447); Tao Sun (0000-0002-2072-268X).

Author contributions: Xiao NJ reviewed the literature and contributed to manuscript drafting; Li T performed the pathological examination and interpreted the pathological images; Li BR and Sun T contributed to manuscript revising; Ning SB was the operator, and he was responsible for the revision of the manuscript for important intellectual content; All authors issued final approval for the version to be submitted.

Informed consent statement: Informed written consent was obtained from the patient for publication of this report and any accompanying images.

Conflict-of-interest statement: The authors declare that they have no conflict of interest.

CARE Checklist (2016) statement: The authors have read the CARE Checklist (2016), and the manuscript was prepared and revised according to the CARE Checklist (2016).

Open-Access: This article is an open-access article that was selected by an in-house editor and fully peer-reviewed by external reviewers. It is distributed in accordance with the Creative Commons Attribution NonCommercial (CC BY-NC 4.0) license, which permits others to distribute, remix, adapt, build

Nian-Jun Xiao, Shou-Bin Ning, Bai-Rong Li, Tao Sun, Department of Gastroenterology, Air Force Medical Center, Beijing 100142, China

Teng Li, Department of Pathology, Air Force Medical Center, Beijing 100142, China

Corresponding author: Shou-Bin Ning, PhD, Chief Doctor, Department of Gastroenterology, Air Force Medical Center, No. 30, Fucheng Road, Haidian District, Beijing 100142, China. ning-shoubin@163.com

Abstract

BACKGROUND

Hemolymphangiomas are rare malformations composed of both lymphatic and vascular vessels and are located in the pancreas, spleen, mediastinum, *etc.* Small intestinal hemolymphangioma is extremely rare and often presents as obscure gastrointestinal bleeding. It is rarely diagnosed correctly before the operation. Endoscopic injection sclerotherapy is usually used as a management of bleeding in esophageal varices and was occasionally reported as a treatment of vascular malformation. The treatment of small intestinal hemolymphangioma with enteroscopic injection sclerotherapy has not been reported.

CASE SUMMARY

A 42-year-old male complained of recurrent episodes of melena and dizziness, fatigue and reduced exercise capacity for more than 2 mo. Gastroduodenoscopy and blood test revealed a gastric ulcer and anemia. Treatment with oral proton-pump inhibitors and iron did not improve symptoms. We then performed a capsule endoscopy and antegrade balloon-assisted enteroscopy and revealed a hemolymphangioma. Considering it is a benign tumor without malignant potential, we performed enteroscopic injection sclerotherapy. He was discharged 4 days later. At follow-up 3 mo later, the melena disappeared. Balloon-assisted enteroscopy revealed an atrophied tumor atrophied and no bleeding. Argon plasma coagulation was applied to the surface of the hemolymphangioma to accelerated healing. When he returned for follow-up 1 year later, anemia was resolved and the tumor had been cured.

CONCLUSION

Balloon-assisted enteroscopy and capsule endoscopy are effective methods for diagnosis of hemolymphangioma. Enteroscopic injection sclerotherapy is an effective treatment.

Key words: Hemolymphangioma; Lymphangioma; Small intestinal tumor; Balloon

upon this work non-commercially, and license their derivative works on different terms, provided the original work is properly cited and the use is non-commercial. See: <http://creativecommons.org/licenses/by-nc/4.0/>

Manuscript source: Unsolicited manuscript

Received: December 4, 2019

Peer-review started: December 4, 2019

First decision: January 13, 2020

Revised: March 4, 2020

Accepted: March 10, 2020

Article in press: March 10, 2020

Published online: April 7, 2020

P-Reviewer: García-Compeán D, Kwon KA

S-Editor: Ma YJ

L-Editor: Filipodia

E-Editor: Ma YJ



assisted enteroscopy; Obscure gastrointestinal bleeding; Enteroscopic injection sclerotherapy; Case report

©The Author(s) 2020. Published by Baishideng Publishing Group Inc. All rights reserved.

Core tip: Small intestinal hemolymphangioma is a rare malformation presenting as obscure gastrointestinal bleeding and anemia. Though the malformation has a typical lymphangiectatic appearance of white patches on the mucosal surface, it is rarely diagnosed correctly before the operation. We report a case of intestinal hemolymphangioma diagnosed by capsule endoscopy and balloon-assisted enteroscopy. We applied a new, minimally invasive therapy named enteroscopic injection sclerotherapy to manage this disease, which has been proven to be effective and safe. The literature review can present a better understanding of this disease and the advantage of the new management.

Citation: Xiao NJ, Ning SB, Li T, Li BR, Sun T. Small intestinal hemolymphangioma treated with enteroscopic injection sclerotherapy: A case report and review of literature. *World J Gastroenterol* 2020; 26(13): 1540-1545

URL: <https://www.wjgnet.com/1007-9327/full/v26/i13/1540.htm>

DOI: <https://dx.doi.org/10.3748/wjg.v26.i13.1540>

INTRODUCTION

Small intestinal hemolymphangioma is a rare benign malformation consisting of blood vessels and lymphatic channels with luminal dilation. Individuals with small intestinal hemolymphangioma may present with obscure gastrointestinal bleeding and anemia. Though the malformation has a typical lymphangiectatic appearance of white patches on the mucosal surface, it is rarely diagnosed correctly with conventional endoscopy due to the special anatomic location. Here we present a case of small intestinal hemolymphangioma diagnosed by capsule endoscopy (CE) and balloon-assisted enteroscopy (BAE). We applied a new, minimally invasive therapy named enteroscopic injection sclerotherapy to manage this disease, which has been proven to be effective and safe.

CASE PRESENTATION

A 42-year-old male complained of recurrent episodes of melena and dizziness, fatigue and reduced exercise capacity for more than 2 mo.

History of present illness

The patient's symptoms started 2 mo ago with recurrent episodes of melena and he frequently felt fatigued. He was diagnosed with a gastric ulcer and anemia after undergoing gastroduodenoscopy, colonoscopy and laboratory blood tests. Then he took oral proton-pump inhibitors and iron for 1.5 mo, but these therapies did not ameliorate the symptoms.

History of past illness

The patient had no previous medical history.

Physical examination

On examination, anemic face and upper abdominal tenderness were noted. The vital signs were normal with a respiratory rate of 18/min, heart rate of 96/min and blood pressure of 102/62 mmHg.

Laboratory examinations

Blood analysis revealed severe iron-deficiency anemia with hemoglobin of 53 g/dL, and fecal occult blood was positive. Blood biochemistry, tumor biomarkers, other blood tests as well as urine analysis were normal. Electrocardiogram and chest X-ray were also normal.

Endoscopic examinations and further diagnostic work-up

When the patient presented in our hospital, two units of blood were transfused. The gastroduodenoscopy was performed again. A sealed ulcer without any signs of bleeding sign were found in the antrum. We then performed a CE. Bleeding was found in the jejunum after running the capsule for 97 min. The total running time in the small bowel was about 300 min. The CE cannot determine the cause of bleeding due to the short stay around the lesion and the influence of the blood. An antegrade BAE was performed, and a protruded lesion was revealed in the jejunum at about 150 cm distal to the ligament of Treitz. It filled half of the intestinal cavity. The tumor was lobulated with white patches on the mucosal surface with blood oozing in the fundus (Figure 1A). Multiple biopsies were taken, and pathological findings further revealed that hyperplastic thin-walled lymphatic and venous with luminal dilation presented in the submucosal area (Figure 1B).

FINAL DIAGNOSIS

The final diagnosis of the presented case was iron-deficiency anemia with intestinal bleeding due to hemolymphangioma.

TREATMENT

Considering it is a benign tumor without malignant potential, we performed enteroscopic injection sclerotherapy with polidocanol to manage the chronic bleeding. The malformation was completely sclerotized, and no bleeding or perforation was experienced. He was discharged 4 d later.

OUTCOME AND FOLLOW-UP

During a follow-up visit, 3 mo after enteroscopic injection sclerotherapy, the patient felt better than before. The patient's hemoglobin was 126 g/dL, and the melena had disappeared. The tumor had atrophied dramatically, and bleeding was hardly observed (Figure 2A). Argon plasma coagulation was applied to the atrophic hemolymphangioma to accelerated healing. At 1 year later the patient returned to our department for the second follow-up. Laboratory blood tests revealed a normal hemoglobin of 140 g/dL. The tumor was gone, and only a few white patches on the mucosal surface were visible (Figure 2B).

DISCUSSION

Hemolymphangioma is an uncommon category of lymphangioma, which is a group of malformations of the lymphatic system. Lymphangioma can be located at the mesentery, pancreas, mediastinum, *etc*, but small intestinal lymphangiomas are extremely rare (less than 1% of all lymphangiomas). Only 19 reports (with 40 patients) of small bowel lymphangioma were reported from 1960 to 2009 in a literature review on lymphangiomas^[1]. About half of those patients presented with gastrointestinal bleeding, and the majority of lesions were within the jejunum. The standard treatment of this disease was surgical resection and only two of the forty patients were treated by BAE. One lesion was treated with an injection of 1:10000 epinephrine and was very small (4 mm × 6 mm)^[2]. The other lesion treated by BAE was not clearly described^[3]. With the advent of CE and BAE, small intestinal lymphangiomas have been found more often, and even small intestinal hemolymphangioma have been reported. We proceeded to a review the literature from 2010 to 2019 by searching "hemolymphangioma [All Fields] OR hemangiolymphangioma [All Fields]" on PubMed. Six case reports of small intestinal hemolymphangioma were found (Table 1)^[4-9]. All of them were located in the proximal jejunum (or duodenum) and presented as anemia due to gastrointestinal bleeding. Six lesions were diagnosed by endoscopy (five enteroscopy and one gastroduodenoscopy), and three were detected by CE examination. These data support that CE and BAE are effective tools for diagnosing hemolymphangioma.

The standard management of hemolymphangioma until recently has been through surgical resection. Surgeons usually aim for complete removal of the tumor because partial ablation of the tumor leads to a 50%-100% recurrence^[4]. But invasive surgery pushes endoscopists to pursue new management methods that are minimally invasive. Hemolymphangioma managed by endoscopy is acceptable for the nature of

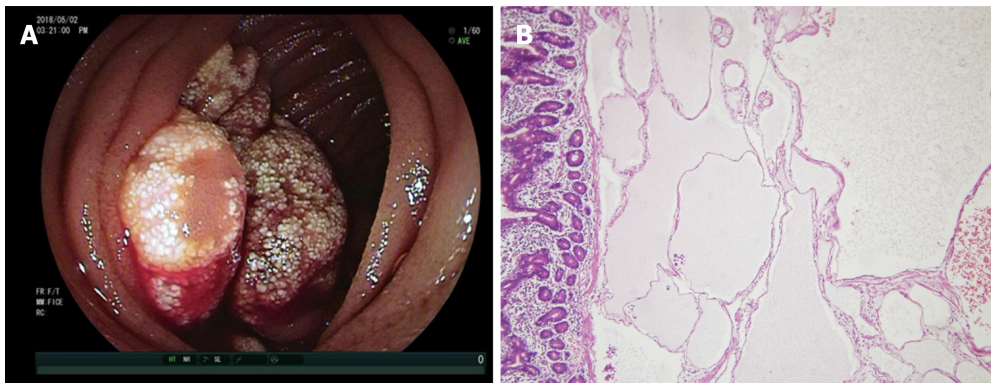


Figure 1 Gross and histologic images of hemolymphangioma. A: Lobulated tumor occupied half of the intestinal cavity with white patches on the mucosal surface and blood oozing in the fundus; B: Histology revealed a hyperplastic thin-walled lymphangion and venous with luminal dilation in the submucosal area. Hematoxylin and eosin $\times 20$.

a benign tumor. Endoscopic mucosal resection with a band ligation device had been reported in managing a gastric hemolymphangioma^[10]. Also, an endoscopic polypectomy and argon plasma coagulation was successfully performed in a jejunal lymphangioma^[11]. Endoscopic injection sclerotherapy is usually used as a treatment for esophageal varices, including the treatment of esophageal hemangioma. Furthermore, polidocanol injection therapy was also applied in small bowel hemangioma without bleeding or perforation^[12]. Based on these precedents and our experience in the treatment of blue rubber bleb nevus syndrome^[13], we performed enteroscopic injection sclerotherapy to manage the jejunum hemolymphangioma. To our knowledge, this is the first case of small intestinal hemolymphangioma successfully treated by enteroscopic injection sclerotherapy. At the 1 year follow-up, no recurrence of anemia or melena proved that this treatment is feasible.

CONCLUSION

In summary, small intestinal hemolymphangioma is a rare malformation consisting of blood vessels and lymphatic channels. The lesion is mainly located within the proximal jejunum and clinically presents as melena and anemia. BAE and CE are effective methods for preoperative diagnosis of hemolymphangioma, and enteroscopic injection sclerotherapy is a feasible, minimally invasive treatment to manage this benign tumor.

Table 1 English literature on PubMed of small intestinal hemolymphangioma from 2010 to 2019

Ref.	Year	Age/sex	Symptom	Location	Tumor size in cm	Diagnostic method	Management
Fang <i>et al</i> ^[4]	2012	57/F	Melena, anemia	30 cm distal to Treitz	5.0	Enteroscopy	Surgical resection
Antonino <i>et al</i> ^[5]	2014	24/F	Anemia	Second portion of duodenum	5.0	Gastroduodenoscopy	Surgical resection
Gómez-Galán <i>et al</i> ^[6]	2016	43/F	Chronic anemia	Distal duodenum	4.0	Capsule endoscopy and enteroscopy	Surgical resection
Blanco <i>et al</i> ^[7]	2017	45/F	Melena, anemia	90 cm distal to Treitz	8.0	Capsule endoscopy and enteroscopy	Laparoscopic small bowel resection
Iwaya <i>et al</i> ^[8]	2018	70/M	Melena, anemia	120 cm distal to Treitz	2.0	Capsule endoscopy and enteroscopy	Laparoscopic small bowel resection
Yang <i>et al</i> ^[9]	2019	20/F	Melena, anemia	60 cm distal to Treitz	10.0	Computed tomography scan and enteroscopy	Laparoscopic small bowel resection

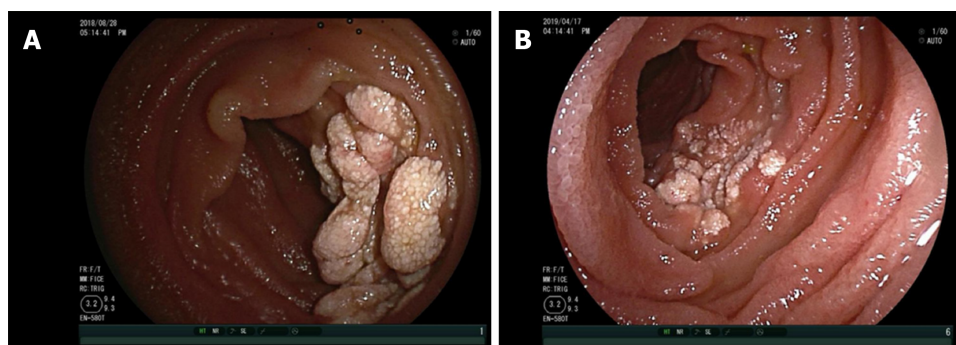


Figure 2 Images at the 3 mo and 1 year follow-up appointments. A: At 3 mo after enteroscopic injection sclerotherapy, hemolymphangioma atrophied dramatically, and bleeding was hardly observed; B: At 1 year later, the hemolymphangioma was gone. A few white patches on the mucosal surface are visible.

REFERENCES

- Morris-Stiff G, Falk GA, El-Hayek K, Vargo J, Bronner M, Vogt DP. Jejunal cavernous lymphangioma. *BMJ Case Rep* 2011; **2011** [PMID: 22696733 DOI: 10.1136/bcr.2011.4022]
- Li F, Osuoha C, Leighton JA, Harrison ME. Double-balloon enteroscopy in the diagnosis and treatment of hemorrhage from small-bowel lymphangioma: a case report. *Gastrointest Endosc* 2009; **70**: 189-190 [PMID: 19152891 DOI: 10.1016/j.gie.2008.09.036]
- Shyung LR, Lin SC, Shih SC, Chang WH, Chu CH, Wang TE. Proposed scoring system to determine small bowel mass lesions using capsule endoscopy. *J Formos Med Assoc* 2009; **108**: 533-538 [PMID: 19586826 DOI: 10.1016/S0929-6646(09)60370-3]
- Fang YF, Qiu LF, Du Y, Jiang ZN, Gao M. Small intestinal hemolymphangioma with bleeding: a case report. *World J Gastroenterol* 2012; **18**: 2145-2146 [PMID: 22563205 DOI: 10.3748/wjg.v18.i17.2145]
- Antonino A, Gragnano E, Sangiuliano N, Rosato A, Maglio M, De Palma M. A very rare case of duodenal hemolymphangioma presenting with iron deficiency anemia. *Int J Surg Case Rep* 2014; **5**: 118-121 [PMID: 24503337 DOI: 10.1016/j.ijscr.2013.12.026]
- Gómez-Galán S, Mosquera-Paz MS, Ceballos J, Cifuentes-Grillo PA, Gutiérrez-Soriano L. Duodenal hemangiolympangioma presenting as chronic anemia: a case report. *BMC Res Notes* 2016; **9**: 426 [PMID: 27581369 DOI: 10.1186/s13104-016-2214-0]
- Blanco Velasco G, Tun Abraham A, Hernández Mondragón O, Blancas Valencia JM. Hemolymphangioma as a cause of overt obscure gastrointestinal bleeding: a case report. *Rev Esp Enferm Dig* 2017; **109**: 213-214 [PMID: 28256143]
- Iwaya Y, Streutker CJ, Coneys JG, Marcon N. Hemangiolympangioma of the small bowel: A rare cause of chronic anemia. *Dig Liver Dis* 2018; **50**: 1248 [PMID: 29886080 DOI: 10.1016/j.dld.2018.05.008]
- Yang J, Zhang Y, Kou G, Li Y. Jejunum Hemolymphangioma Causing Refractory Anemia in a Young Woman. *Am J Gastroenterol* 2019 [PMID: 31658121 DOI: 10.14309/ajg.0000000000000438]
- Kim WT, Lee SW, Lee JU. Bleeding gastric hemolymphangioma: endoscopic therapy is feasible. *Dig Endosc* 2013; **25**: 553-554 [PMID: 23855544 DOI: 10.1111/den.12147]
- Kida A, Matsuda K, Hirai S, Shimatani A, Horita Y, Hiramatsu K, Matsuda M, Ogino H, Ishizawa S, Noda Y. A pedunculated polyp-shaped small-bowel lymphangioma causing gastrointestinal bleeding and treated by double-balloon enteroscopy. *World J Gastroenterol* 2012; **18**: 4798-4800 [PMID: 23002353 DOI: 10.3748/wjg.v18.i34.4798]

- 12 **Igawa A**, Oka S, Tanaka S, Kuniyama S, Nakano M, Chayama K. Polidocanol injection therapy for small-bowel hemangioma by using double-balloon endoscopy. *Gastrointest Endosc* 2016; **84**: 163-167 [PMID: 26907744 DOI: 10.1016/j.gie.2016.02.021]
- 13 **Ning S**, Zhang Y, Zu Z, Mao X, Mao G. Enteroscopic sclerotherapy in blue rubber bleb nevus syndrome. *Pak J Med Sci* 2015; **31**: 226-228 [PMID: 25878650 DOI: 10.12669/pjms.311.5858]



Published By Baishideng Publishing Group Inc
7041 Koll Center Parkway, Suite 160, Pleasanton, CA 94566, USA
Telephone: +1-925-3991568
E-mail: bpgoffice@wjgnet.com
Help Desk: <http://www.f6publishing.com/helpdesk>
<http://www.wjgnet.com>

