

World Journal of *Hepatology*

World J Hepatol 2020 October 27; 12(10): 693-882



REVIEW

- 693** Neoadjuvant treatment strategies for intrahepatic cholangiocarcinoma
Akateh C, Ejaz AM, Pawlik TM, Cloyd JM
- 709** Metabolic syndrome and liver disease in the era of bariatric surgery: What you need to know!
Ziogas IA, Zapsalis K, Giannis D, Tsoulfas G
- 722** Combined liver-kidney transplantation for rare diseases
Knotek M, Novak R, Jaklin-Kelez A, Mrzljak A

MINIREVIEWS

- 738** Hepatocellular carcinoma Liver Imaging Reporting and Data Systems treatment response assessment: Lessons learned and future directions
Aslam A, Do RKG, Kambadakone A, Spieler B, Miller FH, Gabr AM, Charalel RA, Kim CY, Madoff DC, Mendiratta-Lala M
- 754** Tumor necrosis family receptor superfamily member 9/tumor necrosis factor receptor-associated factor 1 pathway on hepatitis C viral persistence and natural history
Peña-Asensio J, Sanz-de-Villalobos E, Miquel J, Larrubia JR
- 766** Apatinib as an alternative therapy for advanced hepatocellular carcinoma
Zhang XH, Cao MQ, Li XX, Zhang T

ORIGINAL ARTICLE

Basic Study

- 775** Hepatitis B virus detected in paper currencies in a densely populated city of India: A plausible source of horizontal transmission?
Das P, Supekar R, Chatterjee R, Roy S, Ghosh A, Biswas S

Case Control Study

- 792** PNPLA3 and TM6SF2 polymorphisms in Brazilian patients with nonalcoholic fatty liver disease
Lisboa QC, Nardelli MJ, Pereira PA, Miranda DM, Ribeiro SN, Costa RSN, Versiani CA, Vidigal PVT, Ferrari TCA, Couto CA

Retrospective Cohort Study

- 807** Impact of sarcopenia on mortality in patients undergoing liver re-transplantation
Dhaliwal A, Larson D, Hiat M, Muinov LM, Harrison WL, Sayles H, Sempokuya T, Olivera MA, Rochling FA, McCashland TM

Retrospective Study

- 816 Increased incidence of and microbiologic changes in pyogenic liver abscesses in the Mexican population
Pérez-Escobar J, Ramirez-Quesada W, Calle-Rodas DA, Chi-Cervera LA, Navarro-Alvarez N, Aquino-Matus J, Ramírez-Hinojosa JP, Moctezuma-Velázquez C, Torre A

Observational Study

- 829 Malnutrition and non-compliance to nutritional recommendations in patients with cirrhosis are associated with a lower survival
Crisan D, Procopet B, Epure A, Stefanescu H, Suciu A, Fodor A, Mois E, Craciun R, Crisan N
- 841 Effect of treating chronic hepatitis C with direct-acting antivirals on extrahepatic cutaneous manifestations
El Kassas M, Hegazy OM, Salah EM
- 850 Novel markers of endothelial dysfunction in hepatitis C virus-related cirrhosis: More than a mere prediction of esophageal varices
Hanafy AS, Basha MAK, Wadea FM

CASE REPORT

- 863 Kratom induced severe cholestatic liver injury histologically mimicking primary biliary cholangitis: A case report
Gandhi D, Ahuja K, Quade A, Batts KP, Patel L
- 870 Severe COVID-19 after liver transplantation, surviving the pitfalls of learning on-the-go: Three case reports
Alconchel F, Cascales-Campos PA, Pons JA, Martínez M, Valiente-Campos J, Gajownik U, Ortiz ML, Martínez-Alarcón L, Parrilla P, Robles R, Sánchez-Bueno F, Moreno S, Ramirez P

LETTER TO THE EDITOR

- 880 Role of platelet-albumin-bilirubin score in predicting re-bleeding after band ligation for acute variceal hemorrhage
Faisal MS, Singh T, Amin H, Modaresi Esfeh J

ABOUT COVER

Editorial board member of *World Journal of Hepatology*, Dr. Fernando Oscar Bessone is Professor of Gastroenterology and Chief of the Gastroenterology and Hepatology Department at the Hospital Provincial del Centenario, University of Rosario School of Medicine (Brazil). Dr. Bessone completed postgraduate training in Clinical Hepatology, Liver Pathology (Hospital de Clinicas, San Pablo, Brazil), Pediatric Hepatology (Hospital da Criança, San Pablo, Brazil), and Liver Transplantation and Clinical Hepatology (Hospital Clinic y Provincial de Barcelona, Spain). He has served as Principal Investigator or Co-Investigator in more than 50 clinical trials, and is currently the Coordinator of the Latin American Registry of Hepatotoxicity. He authored more than 70 articles, 30 book chapters, and more than 140 papers presented at scientific meetings. In addition, he serves as an editorial board member for several international hepatology-related journals. (L-Editor: Filipodia)

AIMS AND SCOPE

The primary aim of *World Journal of Hepatology* (*WJH*, *World J Hepatol*) is to provide scholars and readers from various fields of hepatology with a platform to publish high-quality basic and clinical research articles and communicate their research findings online.

WJH mainly publishes articles reporting research results and findings obtained in the field of hepatology and covering a wide range of topics including chronic cholestatic liver diseases, cirrhosis and its complications, clinical alcoholic liver disease, drug induced liver disease autoimmune, fatty liver disease, genetic and pediatric liver diseases, hepatocellular carcinoma, hepatic stellate cells and fibrosis, liver immunology, liver regeneration, hepatic surgery, liver transplantation, biliary tract pathophysiology, non-invasive markers of liver fibrosis, viral hepatitis.

INDEXING/ABSTRACTING

The *WJH* is now abstracted and indexed in PubMed, PubMed Central, Emerging Sources Citation Index (Web of Science), Scopus, China National Knowledge Infrastructure (CNKI), China Science and Technology Journal Database (CSTJ), and Superstar Journals Database.

RESPONSIBLE EDITORS FOR THIS ISSUE

Production Editor: Li-Li Wang; Production Department Director: Yun-Xiao Jian Wu; Editorial Office Director: Jia-Ping Yan.

NAME OF JOURNAL

World Journal of Hepatology

ISSN

ISSN 1948-5182 (online)

LAUNCH DATE

October 31, 2009

FREQUENCY

Monthly

EDITORS-IN-CHIEF

Nikolaos T Pylasopoulos, Ke-Qin Hu, Koo Jeong Kang

EDITORIAL BOARD MEMBERS

<https://www.wjgnet.com/1948-5182/editorialboard.htm>

PUBLICATION DATE

October 27, 2020

COPYRIGHT

© 2020 Baishideng Publishing Group Inc

INSTRUCTIONS TO AUTHORS

<https://www.wjgnet.com/bpg/gerinfo/204>

GUIDELINES FOR ETHICS DOCUMENTS

<https://www.wjgnet.com/bpg/GerInfo/287>

GUIDELINES FOR NON-NATIVE SPEAKERS OF ENGLISH

<https://www.wjgnet.com/bpg/gerinfo/240>

PUBLICATION ETHICS

<https://www.wjgnet.com/bpg/GerInfo/288>

PUBLICATION MISCONDUCT

<https://www.wjgnet.com/bpg/gerinfo/208>

ARTICLE PROCESSING CHARGE

<https://www.wjgnet.com/bpg/gerinfo/242>

STEPS FOR SUBMITTING MANUSCRIPTS

<https://www.wjgnet.com/bpg/GerInfo/239>

ONLINE SUBMISSION

<https://www.f6publishing.com>

Severe COVID-19 after liver transplantation, surviving the pitfalls of learning on-the-go: Three case reports

Felipe Alconchel, Pedro A Cascales-Campos, Jose A Pons, María Martínez, Josefa Valiente-Campos, Urszula Gajownik, María L Ortiz, Laura Martínez-Alarcón, Pascual Parrilla, Ricardo Robles, Francisco Sánchez-Bueno, Santiago Moreno, Pablo Ramírez

ORCID number: Felipe Alconchel 0000-0002-5483-0312; Pedro A Cascales-Campos 0000-0001-6703-6372; Jose A Pons 0000-0003-4606-1557; María Martínez 0000-0001-7372-0920; Josefa Valiente-Campos 0000-0002-2358-0605; Urszula Gajownik 0000-0002-6903-5506; María L Ortiz 0000-0002-7904-0536; Laura Martínez-Alarcón 0000-0001-7497-6709; Pascual Parrilla 0000-0002-0883-1533; Ricardo Robles 0000-0003-0007-562X; Francisco Sánchez-Bueno 0000-0003-2381-2514; Santiago Moreno 0000-0002-7850-3287; Pablo Ramírez 0000-0003-0629-6749.

Author contributions: Alconchel F, Cascales-Campos PA and Ramírez P designed this article; Alconchel F, Pons JA, Martínez M, Valiente-Campos J, Martínez-Alarcón L, Ortiz ML and Gajownik U collected a substantial portion of data; Alconchel F, Cascales-Campos PA, Parrilla P, Robles R, Sánchez-Bueno F, Moreno S and Ramírez P analysed and interpreted of data; Alconchel F, Cascales-Campos PA and Ramírez P drafted of the manuscript; Parrilla P, Robles R, Sánchez-Bueno F, Moreno S and Ramírez P revised of the manuscript's important intellectual content critically; Parrilla P and Ramírez P supervised; Alconchel F, Cascales-

Felipe Alconchel, Pedro A Cascales-Campos, Josefa Valiente-Campos, Laura Martínez-Alarcón, Pascual Parrilla, Ricardo Robles, Francisco Sánchez-Bueno, Pablo Ramírez, Department of Surgery and Organ Transplantation, Virgen de la Arrixaca University Hospital, Murcia 30120, Spain

Felipe Alconchel, Pedro A Cascales-Campos, Jose A Pons, María Martínez, Josefa Valiente-Campos, Urszula Gajownik, María L Ortiz, Laura Martínez-Alarcón, Pascual Parrilla, Ricardo Robles, Francisco Sánchez-Bueno, Pablo Ramírez, Department of Digestive, Endocrine and Abdominal Surgery and Transplantation, Biomedical Research Institute of Murcia (IMIB-Virgen de la Arrixaca), Murcia 30120, Spain

Jose A Pons, Urszula Gajownik, María L Ortiz, Department of Hepatology, Virgen de la Arrixaca University Hospital, Murcia 30120, Spain

María Martínez, Department of Intensive Care Unit, Virgen de la Arrixaca University Hospital, Murcia 30120, Spain

Santiago Moreno, Department of Infectious Diseases, Ramon y Cajal Hospital, Madrid 28034, Spain

Corresponding author: Felipe Alconchel, MD, PhD, Doctor, Surgeon, Department of Surgery and Organ Transplantation, Virgen de la Arrixaca University Hospital, Ctra. Madrid-Cartagena s/n, Murcia 30120, Spain. alconchelgago@gmail.com

Abstract

BACKGROUND

The novel coronavirus 2019 (COVID-19) pandemic has dramatically transformed the care of the liver transplant patient. In patients who are immunosuppressed and with multiple comorbidities, severe acute respiratory syndrome coronavirus 2 (SARS-CoV-2) infection has been associated with increased severity and mortality. The main objective of this report is to communicate our experience in the therapeutic management of SARS-CoV-2 infection in 3 liver transplant patients. Secondly, we stress the management and investigation of the contagious spreading into a liver transplant ward.

CASE SUMMARY

Campos PA, Pons JA, Martínez M, Valiente-Campos J, Gajownik U, Ortiz ML, Parrila P, Robles R, Sánchez-Bueno F, Moreno S and Ramírez approved of the final version to be published.

Informed consent statement:

Informed written consent was obtained from the patient for publication of this report and any accompanying images.

Conflict-of-interest statement: The authors declare that they have no conflict of interest.

CARE Checklist (2016) statement:

The authors have read the CARE Checklist (2016), and the manuscript was prepared and revised according to the CARE Checklist (2016).

Open-Access: This article is an open-access article that was selected by an in-house editor and fully peer-reviewed by external reviewers. It is distributed in accordance with the Creative Commons Attribution NonCommercial (CC BY-NC 4.0) license, which permits others to distribute, remix, adapt, build upon this work non-commercially, and license their derivative works on different terms, provided the original work is properly cited and the use is non-commercial. See: <http://creativecommons.org/licenses/by-nc/4.0/>

Manuscript source: Invited manuscript

Received: July 29, 2020

Peer-review started: July 29, 2020

First decision: September 12, 2020

Revised: September 12, 2020

Accepted: September 22, 2020

Article in press: September 22, 2020

Published online: October 27, 2020

P-Reviewer: Pandey CK

S-Editor: Zhang L

L-Editor: A

P-Editor: Li X



The patients were two women (aged 61 years and 62 years) and one man (aged 68 years), all of them having recently received a liver transplant. All three patients required intensive care unit admission and invasive mechanical ventilation. Two of them progressed severely until death. The other one, who received tocilizumab, had a good recovery. In the outbreak, the wife of one of the patients and four healthcare professionals involved in their care were also infected.

CONCLUSION

We illustrate in detail the evolution of a nosocomial COVID-19 outbreak in a liver transplant ward. We believe that these findings will contribute to a better understanding of the natural history of the disease and will improve the treatment of the liver transplant patient with COVID-19.

Key Words: Liver transplantation; COVID-19; SARS-CoV-2; Cross infection; Nosocomial infection; Case report

©The Author(s) 2020. Published by Baishideng Publishing Group Inc. All rights reserved.

Core Tip: In patients who are immunosuppressed and with multiple comorbidities, severe acute respiratory syndrome coronavirus 2 (SARS-CoV-2) infection has been associated with increased severity and mortality. We report our experience in the therapeutic management of SARS-CoV-2 infection in 3 liver transplant patients and stress the management and investigation of a contagious spreading into a liver transplant ward.

Citation: Alconchel F, Cascales-Campos PA, Pons JA, Martínez M, Valiente-Campos J, Gajownik U, Ortiz ML, Martínez-Alarcón L, Parrilla P, Robles R, Sánchez-Bueno F, Moreno S, Ramírez P. Severe COVID-19 after liver transplantation, surviving the pitfalls of learning on-the-go: Three case reports. *World J Hepatol* 2020; 12(10): 870-879

URL: <https://www.wjgnet.com/1948-5182/full/v12/i10/870.htm>

DOI: <https://dx.doi.org/10.4254/wjh.v12.i10.870>

INTRODUCTION

After the first cases of coronavirus-2 pneumonia (SARS-CoV-2) were detected in early December 2019 in Wuhan (Hubei, China)^[1,2] a pandemic has overtaken hundreds of countries^[3]. The main active sources are currently located in Europe and the United States^[4]. This medical emergency has tested global healthcare systems, which have established strategic changes and protocols to prioritize healthcare and avoid overloading. The frequency of liver transplantation operations has been seriously affected. Transplant programs depend on the availability of donors, the vast majority of whom are deceased, and medical personnel normally oversee these programs in intensive care units, but these facilities are currently overcrowded. The result of these conditions has been a dramatic decrease in activity in all transplant groups around the world. In Spain, the world leader in organ donation, surgeons had access to the livers of about 100 deceased donors per week during the 3-month period before the detection of the first case of novel coronavirus (COVID-19); this number has since dropped dramatically to a level of only 15 donors per week^[5,6].

In an effort to contain the pandemic, drastic community measures of social confinement and distancing have been established, and these measures extend to the healthcare environment, enhancing telematic activities for the ambulatory management of patients. At the in-hospital level, most of the preventive measures are aimed at preventing the spread of infection by healthcare professionals during the care of COVID-19 patients. The impact of nosocomial infection by COVID-19 has warranted little attention and could be especially relevant to transplant recipients during their hospitalization.

The main objective of our work is to communicate our experience in the therapeutic management of severe SARS-CoV-2 infection in three liver transplant patients who required invasive mechanical ventilation, two of whom had an infection of nosocomial

origin. We also analysed some lessons learned from this experience.

CASE PRESENTATION

Since the detection of the first case of COVID-19 in our region on March 8, 2020, and until May 31st, 2020, a total of twelve liver transplant patients have been hospitalized in our liver transplant unit.

Chief complaints

Case 1: Sixty-one-year-old woman with a liver transplant in September 2019 for cryptogenic cirrhosis. In early March, she was admitted for diarrhea, and a few days later she developed acute respiratory failure, and heart failure. A first RT-PCR of SARS-CoV-2 from throat and pharyngeal swabs was negative but became positive three days later after a second RT-PCR was conducted due to high clinical suspicion (Figure 1). Treatment with hydroxychloroquine and lopinavir/ritonavir was then initiated, adjusting the tacrolimus levels, but the patient suffered progressive clinical and analytical worsening, with the need for invasive mechanical ventilation, associated with pulmonary superinfection by *Enterococcus faecalis* and *Enterococcus faecium* detected in bronchoalveolar lavage fluid. Finally, the patient developed shock with multisystem failure and died in the third week of hospitalization.

Case 2: Sixty-eight-year-old male, transplanted on March 4, 2020, by non-alcoholic steatohepatitis. During the immediate post-transplant period, he was diagnosed with a biliary stricture and was treated endoscopically. His wife, the primary caregiver, tested positive for SARS-CoV-2 via RT-PCR from pharyngeal swabs on March 18, 2020, after reporting slightly compatible symptoms. All staff in contact with her, including the patient himself (who was initially negative), were evaluated with RT-PCR. Of a total of 40 people tested, one hepatologist was positive for SARS-CoV-2; this physician was in contact with all patients admitted at that time. Four days later, the patient, without symptoms, was discharged. Two days after discharge, the patient was readmitted for fever and cough, and the RT-PCR of SARS-CoV-2 was positive (Figure 1). Early treatment with hydroxychloroquine and azithromycin was initiated, adjusting the doses of mycophenolic acid and tacrolimus. Seven days after the positive result, the patient was admitted to the intensive care unit due to deterioration of respiratory function requiring invasive mechanical ventilation and treatment with tocilizumab. The patient progressed satisfactorily to home discharge and asymptomatic, but still with a positive RT-PCR of SARS-CoV-2 two months later.

Case 3: Sixty-two-year-old woman who received a liver transplant in February 2019 secondary to primary biliary cholangitis and was discharged in the first week of March 2020 after an episode of constitutional syndrome. On April 6, 2020, she was readmitted with fever, dyspnea, and diarrhea, with a RT-PCR positive for SARS-CoV-2. Forty-eight hours later, the patient progressively deteriorated, requiring admission to intensive care unit with invasive mechanical ventilation, and was treated with tocilizumab in addition to hydroxychloroquine, azithromycin, and methylprednisolone. Mycophenolic acid was suspended, and doses of tacrolimus were reduced to the minimum necessary. After four days of invasive mechanical ventilation, extubation was performed. In spite of the measures adopted, the patient evolved severely. Two months after the onset of the outbreak, and still with a positive RT-PCR of SARS-CoV-2, she developed a tracheoesophageal fistula. An esophageal prosthesis and an extracorporeal venovenous membrane oxygenation (vv-ECMO) were placed. Forty-five days after the first positive RT-PCR of SARS-CoV-2 the virus was negative in the RT-PCR of the bronchoalveolar lavage. Unfortunately, the patient died eighty days after the onset of the outbreak in our liver transplant unit.

History of present illness

A cluster of three patients who temporarily coincided in the hospitalization ward developed a SARS-CoV-2 [reverse transcription polymerase chain reaction (RT-PCR) throat swab] infection. Given the use of anonymous clinical data and the observational approach of our paper, our work was exempt from approval from an ethics' board. Table 1 shows the main clinical features of these three patients. It is important to note that the wife of case 2, one hepatologist on the transplant team, and three nurses in the ward were also infected with the SARS-CoV-2 virus.

In our transplant unit, the outbreak of SARS-CoV-2 began on March 18. After a

Table 1 Details of the three cases reported

| | Case 1 | Case 2 | Case 3 |
|---|--|--|--|
| Age (yr) | 61 | 68 | 62 |
| Sex | Female | Male | Female |
| LT indication | Cryptogenic cirrhosis | NASH | Primary biliary cholangitis |
| Date of liver transplant | September 7, 2019 | March 3, 2020 | February 13, 2019 |
| Immunosuppression (per day) | Tacrolimus 5 mg and prednisone 5 mg | Tacrolimus 7 mg, mycophenolic acid 2000 mg, prednisone 20 mg | Tacrolimus 3 mg, mycophenolic acid 2000 mg, prednisone 5 mg |
| Blood concentration of tacrolimus (before COVID-19) | 7 ng/mL | 7.5 ng/mL | 5.2 ng/mL |
| Allograft function (before COVID-19) | Normal | Normal | Increased GGT and ALP |
| Comorbidities | Hypothyroidism | Diabetes, hypertension, stroke | Hypertension |
| Laboratory test ¹ : | | | |
| PaO ₂ : FiO ₂ ratio (while IMV) | 237 (76-376) | 367 (337-385) | 256 (133-329) |
| White-cell count ($\times 10^3$ /UL) | 4.50 (2.38-9.87) | 6.61 (1.8-17.4) | 15.71 (7.02-36.14) |
| Lymphocyte count ($\times 10^3$ /UL) | 0.30 (0-0.65) | 0.325 (0.2-1.02) | 1 (0.54-2.01) |
| Platelet count ($\times 10^3$ /UL) | 9.5 (3-38) | 113.5 (37-372) | 290 (158-406) |
| Hemoglobin (g/DL) | 8.7 (6.5-9.4) | 9.2 (7-11.8) | 10.4 (7.6-12.9) |
| IL-6 (pg/mL) | 599 (400-799) | 558 (192-1000) | 54 (50-286) |
| C-reactive protein (mg/DL) | 10.3 (8.2-18.3) | 4 (0.4-13.3) | 1.8 (0.7-4.6) |
| Procalcitonin (ng/mL) | 2.2 (1.1-7.8) | 0.25 (0.12-0.43) | 0.28 (0.17-0.75) |
| Ferritin (ng/mL) | 5338 (814-9862) | 1262 (392-2095) | 2047 (1360-2297) |
| Lactate dehydrogenase (U/L) | 452 (209-649) | 265 (161-378) | 399 (165-646) |
| Aspartate aminotransferase (U/L) | 126 (29-466) | 14 (9-36) | 30 (16-44) |
| Alanine aminotransferase (U/L) | 89 (29-197) | 21 (8-31) | 24 (5-98) |
| Total bilirubin (mg/DL) | 1.2 (0.3-2.65) | 0.56 (0.39-1.23) | 1.82 (0.21-4) |
| Creatine kinase (U/L) | 14 (10-18) | 13 (7-75) | 29 (29-36) |
| Creatinine (mg/DL) | 0.69 (0.45-1.07) | 1.22 (1.04-1.93) | 0.89 (0.54-2.65) |
| D-dimer (ng/mL) | 1073 (565-1825) | 1347 (620 - 3431) | 283 (153-648) |
| Sodium (meq/L) | 137 (128-141) | 139 (136 - 163) | 141 (135-145) |
| Potassium (meq/L) | 4.6 (2.9-5.8) | 4 (3.3-4.9) | 4 (3.2-5.2) |
| Chloride (meq/L) | 102 (97-105) | 103 (100-111) | 107 (99-112) |
| RT-PCR of SARS-CoV-2 | Negative on day 3; positive on day 6 | Negative on day 8; positive on days 13, 36, 42, 47, 54, 65 and 79 | Negative on days 14, 72 and 75; positive on days 26, 42 and 55 |
| Radiologic findings | Bilateral pneumonia, pleural effusion | Bilateral pneumonia, peripheral ground-glass opacity, pleural effusion | Bilateral pneumonia, peripheral ground-glass opacity |
| Treatment | HCQ (200 mg daily), azithromycin (250 mg daily), LPV/r (one dose 400/100 mg), vancomycin (1 g daily) | HCQ (200 mg daily), azithromycin (250 mg daily), tocilizumab (one dose 8 mg/kg), methylprednisolone (180 mg three doses) | HCQ (200 mg daily), azithromycin (250 mg daily), tocilizumab (one dose 8 mg/kg), methylprednisolone (60 mg daily), vv-ECMO |
| Immunosuppressant dose reduction | Yes (low dose of tacrolimus) | Yes (mycophenolic acid suspended and low dose of tacrolimus) | Yes (mycophenolic acid suspended) |
| Rejection during or after COVID-19 | No | No | Yes |
| Complications | Secondary <i>Enterococcus faecalis</i> | Asymptomatic intra-abdominal | Tracheoesophageal fistula |

| (BAL culture) lung infection | collection |
|------------------------------|------------|
|------------------------------|------------|

¹Expressed as the median and range, of the analytical values since the RT-PCR of SARS-CoV-2 was positive until present. ALP: Alkaline phosphatase; BAL: Bronchoalveolar lavage; GGT: Gamma-glutamyltransferase; HCQ: Hydroxychloroquine; ICU: Intensive care unit; IMV: Invasive mechanical ventilation; LPV/r: Lopinavir/ritonavir; NASH: Non-alcoholic steatohepatitis; NE: Norepinephrine; RT-PCR: Reverse transcription polymerase chain reaction; vv-ECMO: Venovenous extracorporeal membrane oxygenation.

positive RT-PCR result in case 1, the wife of case 2 also tested positive after reporting a fever and neck pain. Without delay, we conducted an exhaustive investigation on all the members of the unit (25 nurses and assistants, two cleaning staff, one warden, and nine physicians), with one nursing assistant testing positive for SARS-CoV-2 (hospital admission for ten days for pneumonia, without the need for intensive care unit), two nurses testing positive (one with a mild symptoms and negative RT-PCR at one month, and the other asymptomatic and negative at 13 d), and a hepatologist testing positive (negative at 15 d, asymptomatic and no admission).

Physical examination

The remaining healthcare personnel who tested negative for SARS-CoV-2 were placed in preventive home confinement for 14 d, with negative RT-PCR determinations of SARS-CoV-2 thereafter. In addition, the hospital ward was closed for complete disinfection.

Further diagnostic work-up

Figure 2 shows the epidemiological timeline of the three positive liver transplant recipients as well as the four contacts in the ward (one doctor, one assistant, and two nurses) who tested positive for SARS-CoV-2.

FINAL DIAGNOSIS

The final diagnosis of the presented cases is severe COVID-19 after liver transplantation.

TREATMENT

Case 1 was treated with Hydroxychloroquine (HCQ, 200 mg daily), azithromycin (250 mg daily), lopinavir/ritonavir (one dose 400/100 mg) and vancomycin (1 g daily). The patient in case 2, underwent a treatment that included HCQ (200 mg daily), azithromycin (250 mg daily), tocilizumab (one dose 8 mg/kg) and methylprednisolone (180 mg three doses). In the case of patient 3, however, the outcome was more severe and required the use of a vv-ECMO in addition to HCQ (200 mg daily), azithromycin (250 mg daily), tocilizumab (one dose 8 mg/kg) and methylprednisolone (60 mg daily) (Table 1 and Figure 1).

OUTCOME AND FOLLOW-UP

All three patients required intensive care unit admission and invasive mechanical ventilation (Figure 1). Two of them (cases 1 and 3) progressed severely until death. The other one (case 2), who received tocilizumab, had a good recovery. In the outbreak, the wife of one of the patients and four healthcare professionals involved in their care were also infected (Figure 2).

DISCUSSION

The most appropriate management for transplant recipients who develop COVID-19 and the impact of the infection on this population are not well known. In a previous publication on a population of 111 liver transplant patients with more than ten years of evolution and residents in lombardy (the epicentre of the pandemic in Italy), three

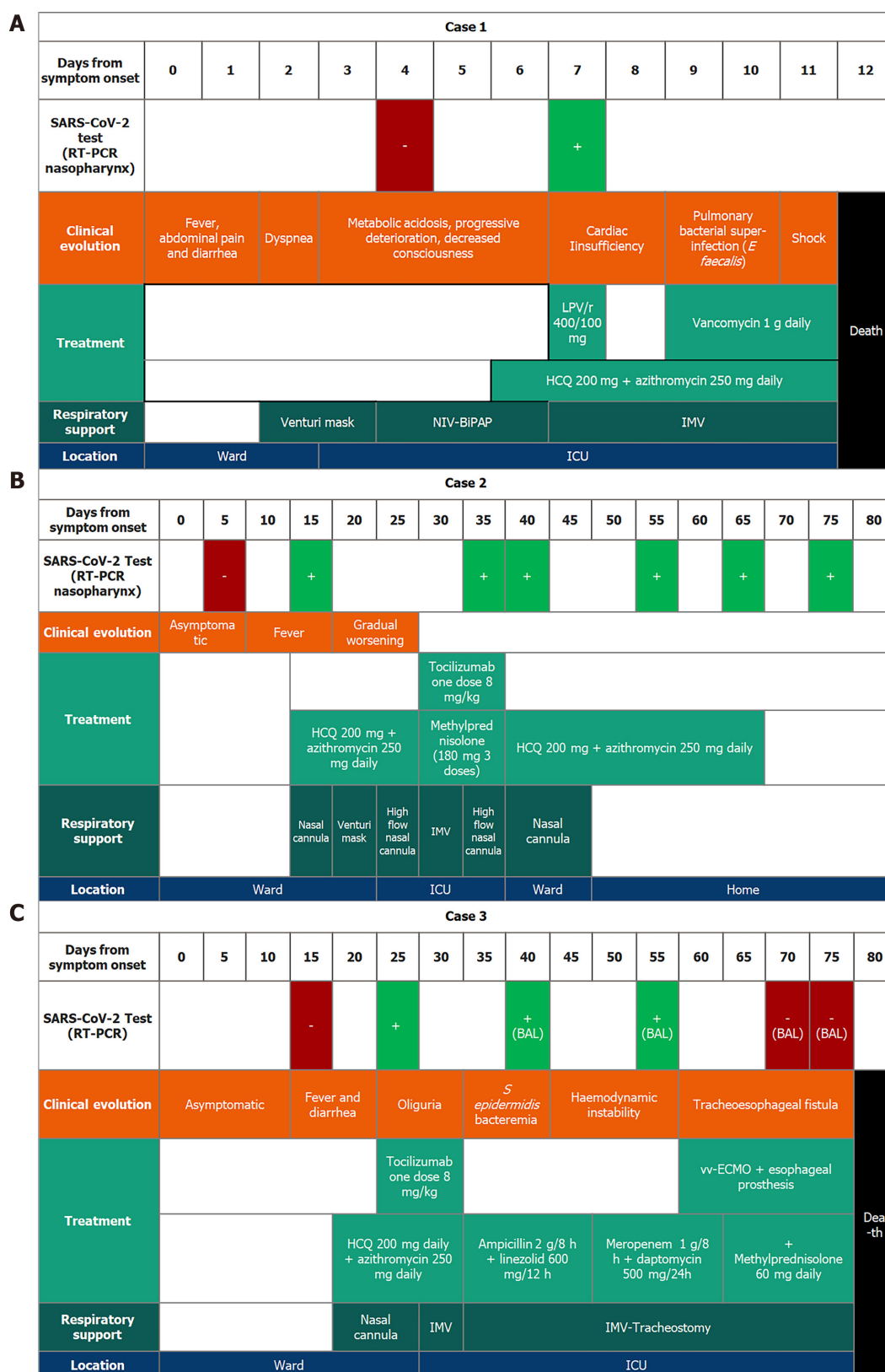


Figure 1 Clinical evolution of each case in a chronological perspective. A: (Case 1) Although the first reverse transcription polymerase chain reaction of severe acute respiratory syndrome coronavirus 2 was negative for the first few days, dyspnea became worse requiring intensive care unit admission. A single dose of lopinavir/ritonavir was administered on day 7; B: (Case 2) A dose of tocilizumab was administered on day 33. The patient improved progressively until he was discharged home; and C: (Case 3) A dose of tocilizumab was administered on day 28. The patient suffered a progressive worsening. A tracheoesophageal fistula was detected and an oesophageal prosthesis was placed. In addition, a venovenous extracorporeal membrane oxygenation was implemented to improve the patient's oxygenation. BAL: Bronchoalveolar lavage; ICU: Intensive care unit; IMV: Invasive mechanical ventilation; LPV/r: Lopinavir/ritonavir; NIV: Non-invasive ventilation; RT-PCR: Reverse transcription polymerase chain reaction; vv-ECMO: Venovenous extracorporeal membrane oxygenation.

deaths were reported due to COVID-19^[7]. The three liver transplant patients were all male and over 65 years old, with a body mass index greater than 28 kg/m² and with cardiovascular risk factors. The occurrence of co-morbidities such as older age, obesity, diabetes mellitus, use of anti-hypertensive drugs, and other cardiovascular risk factors have been associated with more severe clinical manifestations in the general population^[8]. There is no consensus regarding the optimal management of immunosuppressive treatment, and most groups suggest not to modify the immunosuppression strategies in asymptomatic or mild infections, but the experience reported in the literature in severe and critical conditions is variable, and some authors with whom we agree defend the decrease of immunosuppression^[9].

In the physiopathology of SARS-CoV-2, the liver appears to be a susceptible organ^[10] and liver damage occurs according to three mechanisms: (1) Direct cytotoxicity of the virus itself; (2) Indirect damage from autoimmune aetiology; and (3) Hepatotoxicity of drugs used in the management of the infection (remdesivir, tocilizumab, chloroquine and its derivatives, and azithromycin, among others)^[11]. Typical clinical manifestations of SARS-CoV-2 infection include fever, cough, and respiratory distress. The presence of gastrointestinal symptoms at the onset of the picture has been previously reported^[12-15] and, along with the fever, were the initial manifestations in cases 1 and 3 of our series. In this initial phase, the RT-PCR determinations of SARS-CoV-2 were negative in both cases, and the patients presented gastrointestinal and non-respiratory symptoms. This pattern of symptoms was similar to that reported in a renal transplant patient with COVID-19^[16,17].

The clinical situation worsened rapidly in case 1, evolving rapidly towards a fatal outcome. In this patient, elevated levels of C-reactive protein and procalcitonin were detected, as well as severe lymphopenia^[18]. In addition, the presence of *Enterococcus faecium* and *Enterococcus faecalis* was found in the culture of the bronchoalveolar flush, which, in the context of SARS-CoV-2 pneumonia (Figure 1A), undoubtedly triggered the clinical course toward shock and the death of the patient. Although some authors support the hypothesis that SARS-CoV-2 may cause true sepsis of viral origin by direct attack of the virus^[19], this theory is not proven in practice, and we believe that this theory does not explain by itself the fulminant evolution of this patient. Nevertheless, the clinical evolution was favourable in case 2, in which the patient was treated with hydroxychloroquine and tocilizumab. In case 1, we opted for the use of a lopinavir/ritonavir combination, although we do not know if this was correct, but the dose of tacrolimus was closely monitored due to the interaction of these drugs through the inhibition of cytochrome P450 family 3 subfamily A^[20,21]. Several studies have shown that patients infected with SARS-CoV-2 can develop a hyperinflammatory state which leads to an acute respiratory distress syndrome [acute respiratory distress syndrome (ARDS)^[22]]. During ARDS pathogenesis, a "cytokine storm" including IL-6, tumor necrosis factor alpha, and IL-12 is released^[23]. These data suggest, that a blockage of pro-inflammatory pathways could be a therapeutic alternative in the management of patients with severe COVID-19. Tocilizumab is a monoclonal antibody that specifically binds to the IL-6 receptor and inhibits signal transduction mediated by the binding of this receptor to its ligand. In two of our patients, tocilizumab was administered early, even before the need for invasive mechanical ventilation, achieving favorable outcomes. In contrast, in case 1, where tocilizumab was not administered, a situation of shock and multiorgan failure was triggered, resulting in the death of the patient. These findings would be in consonance with what was previously published regarding ARDS and suggest that tocilizumab could be an effective treatment for severe patients with COVID-19.

The liver transplant population has several specific peculiarities. It has been described that, after infection, more than 50% of patients with a liver transplant develop severe forms of the disease^[8]. In addition, the time for virus detection tests among these patients to become negative (clearance) is longer than that among the general population, and positive RT-PCRs of SARS-CoV-2 have been described in transplant patients beyond 53 d from the first positive test^[24], which carries a potentially higher risk of contagion and the need for a longer period of isolation^[25].

The vast majority of measures to prevent infection in the population are focused on non-hospital settings (such as confinement and telemedicine). In hospitals, these measures are preferably designed to prevent the transmission of COVID-19 from patients to healthcare personnel, where the use of personal protective equipment is mandatory. Furthermore, in the case of patients with liver disease, additional measures must be taken. Xiao *et al*^[26] suggest, for example, that the communication between patients and medical staff should be done online and each patient taken care of by one attending doctor and one nurse exclusively.

Preventive measures should begin as soon as the recipient is admitted, including the

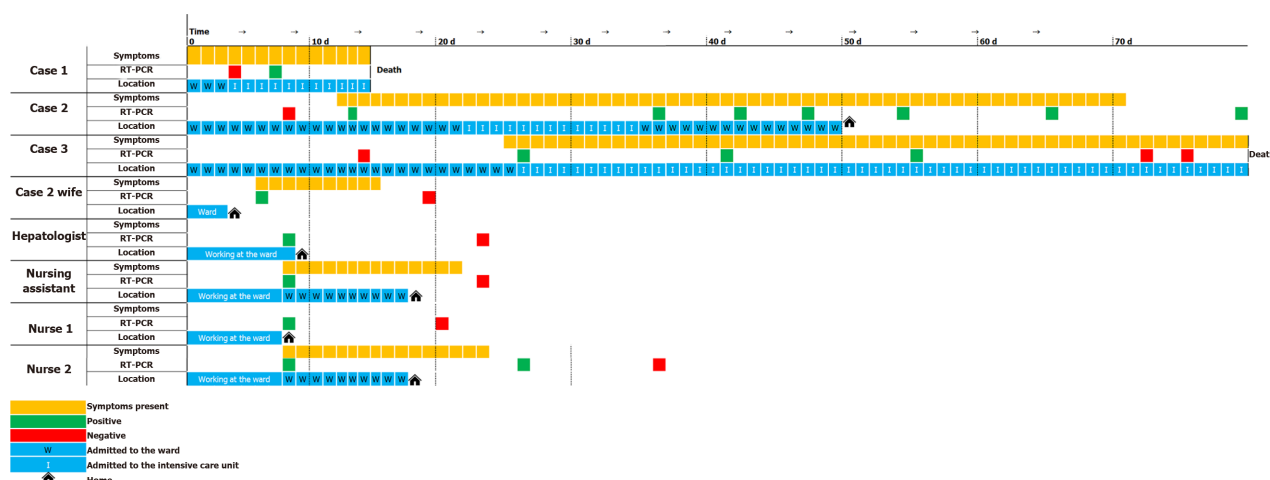


Figure 2 Epidemiological evolution of severe acute respiratory syndrome coronavirus 2 outbreak in our transplant division, according to the presence or absence of symptoms, the positivity of the reverse transcription polymerase chain reaction, and the patients' locations each day from symptoms onset. In orange, when suggestive symptomatology of novel coronavirus 2019 was present. In green, when the reverse transcription polymerase chain reaction of severe acute respiratory syndrome coronavirus 2 was positive. In red, when reverse transcription polymerase chain reaction was performed but was negative. W: Admitted to the ward; I: Admitted to the intensive care unit.

existence of a specific safety circuit until the result of the RT-PCR is known. For example, two of our patients who were candidates for transplant in the last week have tested positive on the day of the transplant but had no symptoms, and the donor grafts were therefore transplanted to other recipients. In addition to community transmission (case 1), nosocomial transmission of the virus must also be considered (cases 2 and 3). Once a case of nosocomial transmission is discovered, special measures should be applied not only to ward staff but also to all ward patients and facilities. In our experience after case 2, the entire ward was evacuated, and a procedure of disinfection and a quarantine of the premises and of all healthcare staff who had worked on the ward were undertaken.

Another problem in relation to the in-hospital management of SARS-CoV-2-infected transplant patients resides in the discordance between the positivity of RT-PCR and the symptoms suggestive of COVID-19, indicating a high-risk window of infection^[27]. As other published works have examined^[28], in the outbreak that took place in our unit, there was a period in which healthcare professionals and companions who were asymptomatic carriers of SARS-CoV-2 concurred in space and time with other patients and healthcare professionals who did not have the virus. These circumstances favored the propagation of the virus until the first positive case was detected and the necessary measures were taken.

A final, equally important aspect is the real impact of the COVID-19 pandemic on organ donation, transplant policies, and waiting list mortality, which altogether constitute the so-called "indirect mortality" from SARS-CoV-2. Most countries have implemented emergency policies to prevent contagion, ranging from issuing systematic screening tests for SARS-CoV-2 in all donors and recipients, limiting donation to far from the hospital where the graft will be implanted, restricting liver transplant activity only in acute liver failure or critical patients^[29,30], and implementing telemedicine in outpatient follow-up. In these circumstances, increases in both mortality among those on the waiting list and in the number of drop-outs due to clinical worsening or tumour progression (indirect deaths from COVID-19) are to be expected. In fact, in Spain, organ donation and transplantation have decreased dramatically. Before the declaration of the state of alarm on March 13, 2020, there were 7.2 donors and 16 transplants per day on average, but since that date, the rates have fallen to an average of 1.2 donors and 2.1 transplants per day^[3].

CONCLUSION

Therefore, there are several lessons learned from our experience. Firstly, early administration of anti-IL-6 monoclonal antibodies could be beneficial in slowing down the cytokine storm in critically ill patients with COVID-19. Secondly, the disease

prodrome in two patients were the gastrointestinal and not the respiratory symptoms. Finally, COVID-19 is highly contagious, so drastic preventive measures and exhaustive epidemiological investigations must be conducted in the case of clinical suspected disease in the ward, even if the RT-PCR of SARS-CoV-2 has been tested negative.

Many uncertainties persist in relation to the diagnosis, treatment, and management of COVID-19 in liver transplant patients. It is certain that we will learn more about the disease and be able to treat it more effectively in the coming months. In the meantime, we are walking blind, and we must rely on our scarce previous experience, on our intuition, and on the oldest methodology in medicine: Trial and error.

REFERENCES

- Guan WJ**, Ni ZY, Hu Y, Liang WH, Ou CQ, He JX, Liu L, Shan H, Lei CL, Hui DSC, Du B, Li LJ, Zeng G, Yuen KY, Chen RC, Tang CL, Wang T, Chen PY, Xiang J, Li SY, Wang JL, Liang ZJ, Peng YX, Wei L, Liu Y, Hu YH, Peng P, Wang JM, Liu JY, Chen Z, Li G, Zheng ZJ, Qiu SQ, Luo J, Ye CJ, Zhu SY, Zhong NS; China Medical Treatment Expert Group for Covid-19. Clinical Characteristics of Coronavirus Disease 2019 in China. *N Engl J Med* 2020; **382**: 1708-1720 [PMID: [32109013](#) DOI: [10.1056/NEJMoa2002032](#)]
- Zhu N**, Zhang D, Wang W, Li X, Yang B, Song J, Zhao X, Huang B, Shi W, Lu R, Niu P, Zhan F, Ma X, Wang D, Xu W, Wu G, Gao GF, Tan W; China Novel Coronavirus Investigating and Research Team. A Novel Coronavirus from Patients with Pneumonia in China, 2019. *N Engl J Med* 2020; **382**: 727-733 [PMID: [31978945](#) DOI: [10.1056/NEJMoa2001017](#)]
- Li Q**, Guan X, Wu P, Wang X, Zhou L, Tong Y, Ren R, Leung KSM, Lau EHY, Wong JY, Xing X, Xiang N, Wu Y, Li C, Chen Q, Li D, Liu T, Zhao J, Liu M, Tu W, Chen C, Jin L, Yang R, Wang Q, Zhou S, Wang R, Liu H, Luo Y, Liu Y, Shao G, Li H, Tao Z, Yang Y, Deng Z, Liu B, Ma Z, Zhang Y, Shi G, Lam TTY, Wu JT, Gao GF, Cowling BJ, Yang B, Leung GM, Feng Z. Early Transmission Dynamics in Wuhan, China, of Novel Coronavirus-Infected Pneumonia. *N Engl J Med* 2020; **382**: 1199-1207 [PMID: [31995857](#) DOI: [10.1056/NEJMoa2001316](#)]
- COVID-19 Map. Johns Hopkins Coronavirus Resource Center [Internet]. [Cited 2020 April 20]. Available from: <https://coronavirus.jhu.edu/map.html>
- Organización Nacional de Trasplantes (ONT)**. COVID-19: Impacto en la actividad de donación y trasplantes [Internet]. [Cited 2020 April 20]. Available from: http://www.ont.es/infesp/Paginas/Impacto_tx.aspx#_blank
- Ahn C**, Amer H, Anglicheau D, Ascher NL, Baan CC, Battsetset G, Bat-Iredui B, Berney T, Betjes MGH, Bichu S, Birn H, Brennan D, Bromberg J, Caillard S, Cannon RM, Cantarovich M, Chan A, Chen ZS, Chapman JR, Cole EH, Cross N, Durand F, Egawa H, Emond JC, Farrero M, Friend PJ, Geissler EK, Ha J, Haberal MA, Henderson ML, Hesselink DA, Humar A, Jassem W, Jeong JC, Kaplan B, Kee T, Kim SJ, Kumar D, Legendre CM, Man K, Moulin B, Muller E, Munkhbat R, Od-Erdene L, Perrin P, Rela M, Tanabe K, Tedesco Silva H, Tinkam KT, Tullius SG, Wong G. Global Transplantation COVID Report March 2020. *Transplantation* 2020; **104**: 1974-1983 [PMID: [32243281](#) DOI: [10.1097/TP.0000000000003258](#)]
- Bhoori S**, Rossi RE, Citterio D, Mazzaferro V. COVID-19 in long-term liver transplant patients: preliminary experience from an Italian transplant centre in Lombardy. *Lancet Gastroenterol Hepatol* 2020; **5**: 532-533 [PMID: [32278366](#) DOI: [10.1016/S2468-1253\(20\)30116-3](#)]
- Boyersky BJ**, Po-Yu Chiang T, Werbel WA, Durand CM, Avery RK, Getsin SN, Jackson KR, Kernodle AB, Van Pilsum Rasmussen SE, Massie AB, Segev DL, Garonzik-Wang JM. Early impact of COVID-19 on transplant center practices and policies in the United States. *Am J Transplant* 2020; **20**: 1809-1818 [PMID: [32282982](#) DOI: [10.1111/ajt.15915](#)]
- Pons JA**, Ramirez P, Revilla-Nuin B, Pascual D, Baroja-Mazo A, Robles R, Sanchez-Bueno F, Martinez L, Parrilla P. Immunosuppression withdrawal improves long-term metabolic parameters, cardiovascular risk factors and renal function in liver transplant patients. *Clin Transplant* 2009; **23**: 329-336 [DOI: [10.1111/j.1399-0012.2008.00944.x](#)]
- Zhong Z**, Zhang Q, Xia H, Wang A, Liang W, Zhou W, Zhou L, Liu X, Rao L, Li Z, Peng Z, Mo P, Xiong Y, Ye S, Wang Y, Ye Q. Clinical characteristics and immunosuppressant management of coronavirus disease 2019 in solid organ transplant recipients. *Am J Transplant* 2020; **20**: 1916-1921 [PMID: [32282986](#) DOI: [10.1111/ajt.15928](#)]
- Fix OK**, Hameed B, Fontana RJ, Kwok RM, McGuire BM, Mulligan DC, Pratt DS, Russo MW, Schilsky ML, Verna EC, Loomba R, Cohen DE, Bezerra JA, Reddy KR, Chung RT. Clinical Best Practice Advice for Hepatology and Liver Transplant Providers During the COVID-19 Pandemic: AASLD Expert Panel Consensus Statement. *Hepatology* 2020; **72**: 287-304 [PMID: [32298473](#) DOI: [10.1002/hep.31281](#)]
- Zhou Z**, Zhao N, Shu Y, Han S, Chen B, Shu X. Effect of Gastrointestinal Symptoms in Patients With COVID-19. *Gastroenterology* 2020; **158**: 2294-2297 [PMID: [32199880](#) DOI: [10.1053/j.gastro.2020.03.020](#)]
- Jin X**, Lian JS, Hu JH, Gao J, Zheng L, Zhang YM, Hao SR, Jia HY, Cai H, Zhang XL, Yu GD, Xu KJ, Wang XY, Gu JQ, Zhang SY, Ye CY, Jin CL, Lu YF, Yu X, Yu XP, Huang JR, Xu KL, Ni Q, Yu CB, Zhu B, Li YT, Liu J, Zhao H, Zhang X, Yu L, Guo YZ, Su JW, Tao JJ, Lang GJ, Wu XX, Wu WR, Qv TT, Xiang DR, Yi P, Shi D, Chen Y, Ren Y, Qiu YQ, Li LJ, Sheng J, Yang Y. Epidemiological, clinical and virological characteristics of 74 cases of coronavirus-infected disease 2019 (COVID-19) with gastrointestinal symptoms. *Gut* 2020; **69**: 1002-1009 [PMID: [32213556](#) DOI: [10.1136/gutjnl-2020-320926](#)]
- Wan Y**, Li J, Shen L, Zou Y, Hou L, Zhu L, Faden HS, Tang Z, Shi M, Jiao N, Li Y, Cheng S, Huang Y, Wu D, Xu Z, Pan L, Zhu J, Yan G, Zhu R, Lan P. Enteric involvement in hospitalised patients with COVID-19 outside Wuhan. *Lancet Gastroenterol Hepatol* 2020; **5**: 534-535 [PMID: [32304638](#) DOI: [10.1016/S2468-1253\(20\)30116-3](#)]

- 10.1016/S2468-1253(20)30118-7]
- 15 **Pereira MR**, Mohan S, Cohen DJ, Husain SA, Dube GK, Ratner LE, Arcasoy S, Aversa MM, Benvenuto LJ, Dadhania DM, Kapur S, Dove LM, Brown RS Jr, Rosenblatt RE, Samstein B, Uriel N, Farr MA, Satlin M, Small CB, Walsh TJ, Kodiyanplakkal RP, Miko BA, Aaron JG, Tsapepas DS, Emond JC, Verna EC. COVID-19 in solid organ transplant recipients: Initial report from the US epicenter. *Am J Transplant* 2020; **20**: 1800-1808 [PMID: [32330343](#) DOI: [10.1111/ajt.15941](#)]
 - 16 **Guillen E**, Pineiro GJ, Revuelta I, Rodriguez D, Bodro M, Moreno A, Campistol JM, Diekmann F, Ventura-Aguar P. Case report of COVID-19 in a kidney transplant recipient: Does immunosuppression alter the clinical presentation? *Am J Transplant* 2020; **20**: 1875-1878 [PMID: [32198834](#) DOI: [10.1111/ajt.15874](#)]
 - 17 **Akalin E**, Azzi Y, Bartash R, Seethamraju H, Parides M, Hemmige V, Ross M, Forest S, Goldstein YD, Ajaimy M, Liriano-Ward L, Pynadath C, Loarte-Campos P, Nandigam PB, Graham J, Le M, Rocca J, Kinkhabwala M. Covid-19 and Kidney Transplantation. *N Engl J Med* 2020; **382**: 2475-2477 [PMID: [32329975](#) DOI: [10.1056/NEJMc2011117](#)]
 - 18 **Qin J**, Wang H, Qin X, Zhang P, Zhu L, Cai J, Yuan Y, Li H. Perioperative Presentation of COVID-19 Disease in a Liver Transplant Recipient. *Hepatology* 2020 [PMID: [32220017](#) DOI: [10.1002/hep.31257](#)]
 - 19 **Li H**, Liu L, Zhang D, Xu J, Dai H, Tang N, Su X, Cao B. Hypothesis SARS-CoV-2 and viral sepsis: observations and hypotheses. *Lancet* 2020 [DOI: [10.1016/S0140-6736\(20\)30920-X](#)]
 - 20 **Yeh RF**, Gaver VE, Patterson KB, Rezk NL, Baxter-Meheux F, Blake MJ, Eron JJ Jr, Klein CE, Rublein JC, Kashuba AD. Lopinavir/ritonavir induces the hepatic activity of cytochrome P450 enzymes CYP2C9, CYP2C19, and CYP1A2 but inhibits the hepatic and intestinal activity of CYP3A as measured by a phenotyping drug cocktail in healthy volunteers. *J Acquir Immune Defic Syndr* 2006; **42**: 52-60 [PMID: [16639344](#) DOI: [10.1097/01.qai.0000219774.20174.64](#)]
 - 21 **Cao B**, Wang Y, Wen D, Liu W, Wang J, Fan G, Ruan L, Song B, Cai Y, Wei M, Li X, Xia J, Chen N, Xiang J, Yu T, Bai T, Xie X, Zhang L, Li C, Yuan Y, Chen H, Li H, Huang H, Tu S, Gong F, Liu Y, Wei Y, Dong C, Zhou F, Gu X, Xu J, Liu Z, Zhang Y, Li H, Shang L, Wang K, Li K, Zhou X, Dong X, Qu Z, Lu S, Hu X, Ruan S, Luo S, Wu J, Peng L, Cheng F, Pan L, Zou J, Jia C, Wang J, Liu X, Wang S, Wu X, Ge Q, He J, Zhan H, Qiu F, Guo L, Huang C, Jaki T, Hayden FG, Horby PW, Zhang D, Wang C. A Trial of Lopinavir-Ritonavir in Adults Hospitalized with Severe Covid-19. *N Engl J Med* 2020; **382**: 1787-1799 [PMID: [32187464](#) DOI: [10.1056/NEJMoa2001282](#)]
 - 22 **Mehta P**, McAuley DF, Brown M, Sanchez E, Tattersall RS, Manson JJ; HLH Across Speciality Collaboration, UK. COVID-19: consider cytokine storm syndromes and immunosuppression. *Lancet* 2020; **395**: 1033-1034 [PMID: [32192578](#) DOI: [10.1016/S0140-6736\(20\)30628-0](#)]
 - 23 **Teachey DT**, Rheingold SR, Maude SL, Zugmaier G, Barrett DM, Seif AE, Nichols KE, Suppa EK, Kalos M, Berg RA, Fitzgerald JC, Aplenc R, Gore L, Grupp SA. Cytokine release syndrome after blinatumomab treatment related to abnormal macrophage activation and ameliorated with cytokine-directed therapy. *Blood* 2013; **121**: 5154-5157 [PMID: [23678006](#) DOI: [10.1182/blood-2013-02-485623](#)]
 - 24 **Liu H**, He X, Wang Y, Zhou S, Zhang D, Zhu J, He Q, Zhu Z, Li G, Sun L, Wang J, Cheng G, Liu Z, Lau G. Management of COVID-19 in patients after liver transplantation: Beijing working party for liver transplantation. *Hepatol Int* 2020; **14**: 432-436 [PMID: [32277387](#) DOI: [10.1007/s12072-020-10043-z](#)]
 - 25 **Huang JF**, Zheng KI, George J, Gao HN, Wei RN, Yan HD, Zheng MH. Fatal outcome in a liver transplant recipient with COVID-19. *Am J Transplant* 2020; **20**: 1907-1910 [PMID: [32277591](#) DOI: [10.1111/ajt.15909](#)]
 - 26 **Xiao Y**, Pan H, She Q, Wang F, Chen M. Prevention of SARS-CoV-2 infection in patients with decompensated cirrhosis. *Lancet Gastroenterol Hepatol* 2020; **5**: 528-529 [PMID: [32197093](#) DOI: [10.1016/S2468-1253\(20\)30080-7](#)]
 - 27 **Gandhi M**, Yokoe DS, Havlir DV. Asymptomatic Transmission, the Achilles' Heel of Current Strategies to Control Covid-19. *N Engl J Med* 2020; **382**: 2158-2160 [PMID: [32329972](#) DOI: [10.1056/NEJMe2009758](#)]
 - 28 **Young BE**, Ong SWX, Kalimuddin S, Low JG, Tan SY, Loh J, Ng OT, Marimuthu K, Ang LW, Mak TM, Lau SK, Anderson DE, Chan KS, Tan TY, Ng TY, Cui L, Said Z, Kurupatham L, Chen MI, Chan M, Vasoo S, Wang LF, Tan BH, Lin RTP, Lee VJM, Leo YS, Lye DC; Singapore 2019 Novel Coronavirus Outbreak Research Team. Epidemiologic Features and Clinical Course of Patients Infected With SARS-CoV-2 in Singapore. *JAMA* 2020; **323**: 1488-1494 [PMID: [32125362](#) DOI: [10.1001/jama.2020.3204](#)]
 - 29 **Tzedakis S**, Jeddou H, Houssel-Debry P, Sulpice L, Boudjema K. COVID-19: Thoughts and comments from a tertiary liver transplant center in France. *Am J Transplant* 2020; **20**: 1952-1953 [PMID: [32282972](#) DOI: [10.1111/ajt.15918](#)]
 - 30 **Vargas M**, Iacovazzo C, Servillo G. Additional Suggestions for Organ Donation during COVID-19 Outbreak. *Transplantation* 2020; **104**: 1984-1985 [PMID: [32413015](#) DOI: [10.1097/TP.0000000000003314](#)]



Published by **Baishideng Publishing Group Inc**
7041 Koll Center Parkway, Suite 160, Pleasanton, CA 94566, USA

Telephone: +1-925-3991568

E-mail: bpgoffice@wjgnet.com

Help Desk: <https://www.f6publishing.com/helpdesk>

<https://www.wjgnet.com>

