

World Journal of *Clinical Cases*

World J Clin Cases 2020 April 26; 8(8): 1343-1560



**GUIDELINES**

- 1343** Prevention program for the COVID-19 in a children's digestive endoscopy center
Ma XP, Wang H, Bai DM, Zou Y, Zhou SM, Wen FQ, Dai DL

REVIEW

- 1350** Predictive factors for central lymph node metastases in papillary thyroid microcarcinoma
Wu X, Li BL, Zheng CJ, He XD
- 1361** Probiotic mixture VSL#3: An overview of basic and clinical studies in chronic diseases
Cheng FS, Pan D, Chang B, Jiang M, Sang LX

MINIREVIEWS

- 1385** Hypertransaminasemia in the course of infection with SARS-CoV-2: Incidence and pathogenetic hypothesis
Zippi M, Fiorino S, Occhigrossi G, Hong W
- 1391** Stability and infectivity of coronaviruses in inanimate environments
Ren SY, Wang WB, Hao YG, Zhang HR, Wang ZC, Chen YL, Gao RD
- 1400** Status, challenges, and future prospects of stem cell therapy in pelvic floor disorders
Cheng J, Zhao ZW, Wen JR, Wang L, Huang LW, Yang YL, Zhao FN, Xiao JY, Fang F, Wu J, Miao YL

ORIGINAL ARTICLE**Retrospective Study**

- 1414** Bedside score predicting retained common bile duct stone in acute biliary pancreatitis
Khoury T, Kadah A, Mahamid M, Mari A, Sbeit W

Observational Study

- 1424** Clinicopathological differences and correlations between right and left colon cancer
Kalantzis I, Nonni A, Pavlakis K, Delicha EM, Miltiadou K, Kosmas C, Ziras N, Gkoumas K, Gakiopoulou H
- 1444** Hemodynamic characteristics in preeclampsia women during cesarean delivery after spinal anesthesia with ropivacaine
Zhao N, Xu J, Li XG, Walline JH, Li YC, Wang L, Zhao GS, Xu MJ

CASE REPORT

- 1454** Mucosa-associated lymphoid tissue lymphoma simulating Crohn's disease: A case report
Stundiene I, Maksimaityte V, Liakina V, Valantinas J

- 1463** Suicide attempt using potassium tablets for congenital chloride diarrhea: A case report
Iijima S
- 1471** Embolization of pancreatic arteriovenous malformation: A case report
Yoon SY, Jeon GS, Lee SJ, Kim DJ, Kwon CI, Park MH
- 1477** Novel frameshift mutation in the SACS gene causing spastic ataxia of charlevoix-saguenay in a consanguineous family from the Arabian Peninsula: A case report and review of literature
Al-Ajmi A, Shamsah S, Janicijevic A, Williams M, Al-Mulla F
- 1489** Duodenal mature teratoma causing partial intestinal obstruction: A first case report in an adult
Chansoon T, Angkathunyakul N, Aroonroch R, Jirasiritham J
- 1495** Rare anaplastic sarcoma of the kidney: A case report
Kao JL, Tsung SH, Shiao CC
- 1502** Unusual association of Axenfeld-Rieger syndrome and wandering spleen: A case report
Chang YL, Lin J, Li YH, Tsao LC
- 1507** Primary cutaneous mantle cell lymphoma: Report of a rare case
Zheng XD, Zhang YL, Xie JL, Zhou XG
- 1515** Typical ulcerative colitis treated by herbs-partitioned moxibustion: A case report
Lin YY, Zhao JM, Ji YJ, Ma Z, Zheng HD, Huang Y, Cui YH, Lu Y, Wu HG
- 1525** Bronchogenic cyst of the stomach: A case report
He WT, Deng JY, Liang H, Xiao JY, Cao FL
- 1532** Laparoscopic umbilical trocar port site endometriosis: A case report
Ao X, Xiong W, Tan SQ
- 1538** Unusual presentation of congenital radioulnar synostosis with osteoporosis, fragility fracture and nonunion: A case report and review of literature
Yang ZY, Ni JD, Long Z, Kuang LT, Tao SB
- 1547** Hydatidiform mole in a scar on the uterus: A case report
Jiang HR, Shi WW, Liang X, Zhang H, Tan Y
- 1554** Pulmonary contusion mimicking COVID-19: A case report
Chen LR, Chen ZX, Liu YC, Peng L, Zhang Y, Xu Q, Lin Q, Tao YM, Wu H, Yin S, Hu YJ

ABOUT COVER

Editorial Board Member of *World Journal of Clinical Cases*, Steven M Schwarz, MD, Professor, Department of Pediatrics, SUNY-Downstate Medical Center, Brooklyn, NY 11203, United States

AIMS AND SCOPE

The primary aim of *World Journal of Clinical Cases* (WJCC, *World J Clin Cases*) is to provide scholars and readers from various fields of clinical medicine with a platform to publish high-quality clinical research articles and communicate their research findings online.

WJCC mainly publishes articles reporting research results and findings obtained in the field of clinical medicine and covering a wide range of topics, including case control studies, retrospective cohort studies, retrospective studies, clinical trials studies, observational studies, prospective studies, randomized controlled trials, randomized clinical trials, systematic reviews, meta-analysis, and case reports.

INDEXING/ABSTRACTING

The WJCC is now indexed in PubMed, PubMed Central, Science Citation Index Expanded (also known as SciSearch®), and Journal Citation Reports/Science Edition. The 2019 Edition of Journal Citation Reports cites the 2018 impact factor for WJCC as 1.153 (5-year impact factor: N/A), ranking WJCC as 99 among 160 journals in Medicine, General and Internal (quartile in category Q3).

RESPONSIBLE EDITORS FOR THIS ISSUE

Responsible Electronic Editor: Ji-Hong Liu

Proofing Production Department Director: Xiang Li

Responsible Editorial Office Director: Jin-Lai Wang

NAME OF JOURNAL

World Journal of Clinical Cases

ISSN

ISSN 2307-8960 (online)

LAUNCH DATE

April 16, 2013

FREQUENCY

Semimonthly

EDITORS-IN-CHIEF

Dennis A Bloomfield, Bao-Gan Peng, Sandro Vento

EDITORIAL BOARD MEMBERS

<https://www.wjgnet.com/2307-8960/editorialboard.htm>

PUBLICATION DATE

April 26, 2020

COPYRIGHT

© 2020 Baishideng Publishing Group Inc

INSTRUCTIONS TO AUTHORS

<https://www.wjgnet.com/bpg/gerinfo/204>

GUIDELINES FOR ETHICS DOCUMENTS

<https://www.wjgnet.com/bpg/GerInfo/287>

GUIDELINES FOR NON-NATIVE SPEAKERS OF ENGLISH

<https://www.wjgnet.com/bpg/gerinfo/240>

PUBLICATION ETHICS

<https://www.wjgnet.com/bpg/GerInfo/288>

PUBLICATION MISCONDUCT

<https://www.wjgnet.com/bpg/gerinfo/208>

ARTICLE PROCESSING CHARGE

<https://www.wjgnet.com/bpg/gerinfo/242>

STEPS FOR SUBMITTING MANUSCRIPTS

<https://www.wjgnet.com/bpg/GerInfo/239>

ONLINE SUBMISSION

<https://www.f6publishing.com>

Bronchogenic cyst of the stomach: A case report

Wen-Ting He, Jing-Yu Deng, Han Liang, Jian-Yu Xiao, Fu-Liang Cao

ORCID number: Wen-Ting He (0000-0002-1752-9643); Jing-Yu Deng (0000-0003-4299-1327); Han Liang (0000-0002-5674-0994); Jian-Yu Xiao (0000-0001-8645-7252); Fu-Liang Cao (0000-0003-0320-5936).

Author contributions: He WT was the major contributor in writing the manuscript and editing the pictures; Liang H advised the manuscript; Deng JY was involved in drafting, writing, and editing the manuscript, and reviewed the manuscript as corresponding author; Xiao JY and Cao FL contributed to providing results obtained by radiology and endoscopy; all authors read and approved the final manuscript.

Supported by National Natural Science Foundation of China, No. 81572372; National Key Research and Development Program "Major Chronic Non-infectious Disease Research", No. 2016YFC1303200; and National Key Research and Development Program "Precision Medicine Research", No. 2017YFC0908304.

Informed consent statement: Written informed consent was obtained from the patient for publication of this case report and any accompanying images.

Conflict-of-interest statement: The authors declare no conflict of interest.

CARE Checklist (2016) statement: The authors have read the CARE Checklist (2016), and the manuscript was prepared and revised according to the CARE Checklist (2016).

Open-Access: This article is an open-access article that was

Wen-Ting He, Jing-Yu Deng, Han Liang, Department of Gastroenterology, Tianjin Medical University Cancer Institute and Hospital, National Clinical Research Center for Cancer, Key Laboratory of Cancer Prevention and Therapy, Tianjin, and Tianjin's Clinical Research Center for Cancer, Tianjin 300060, China

Jian-Yu Xiao, Department of Radiology, Tianjin Medical University Cancer Institute and Hospital, National Clinical Research Center for Cancer, Key Laboratory of Cancer Prevention and Therapy, Tianjin, and Tianjin's Clinical Research Center for Cancer, Tianjin 300060, China

Fu-Liang Cao, Department of Endoscopy, Tianjin Medical University Cancer Institute and Hospital, National Clinical Research Center for Cancer, Key Laboratory of Cancer Prevention and Therapy, Tianjin, and Tianjin's Clinical Research Center for Cancer, Tianjin 300060, China

Corresponding author: Jing-Yu Deng, MD, PhD, Chief Doctor, Professor, Department of Gastroenterology, Tianjin Medical University Cancer Institute and Hospital, National Clinical Research Center for Cancer, Key Laboratory of Cancer Prevention and Therapy, Tianjin, and Tianjin's Clinical Research Center for Cancer, West Lake Road, Hexi District, Tianjin 300060, China. dengery@126.com

Abstract

BACKGROUND

Gastric bronchogenic cysts (BCs) are extremely rare cystic masses caused by abnormal development of the respiratory system during the embryonic period. Gastric bronchial cysts are rare lesions first reported in 1956; as of 2019, only 37 cases are available in the MEDLINE/PubMed online databases. BCs usually have no clinical symptoms in the early stage, and their imaging findings also lack specificity. Therefore, they are difficult to diagnose before histopathological examination.

CASE SUMMARY

A 55-year-old woman presented at our hospital with intermittent epigastric pain. She had a slightly high level of serum carbohydrate antigen 72-4 (CA 72-4). Endoscopic ultrasound found that a cystic mass originated from the submucosa of the posterior gastric wall near the cardia, indicating a diagnosis of cystic hygroma of the stomach. Furthermore, a computed tomography scan demonstrated a quasi-circular cystic mass closely related to the lesser curvature of the gastric fundus with a low density. Because the imaging examinations did not suggest a malignancy and the patient required complete resection, she underwent laparoscopic surgery. As an intraoperative finding, this cystic lesion was located in the posterior wall of the fundus and contained some yellow viscous liquid. Finally, the pathologists verified that the cyst in the fundus was a

selected by an in-house editor and fully peer-reviewed by external reviewers. It is distributed in accordance with the Creative Commons Attribution NonCommercial (CC BY-NC 4.0) license, which permits others to distribute, remix, adapt, build upon this work non-commercially, and license their derivative works on different terms, provided the original work is properly cited and the use is non-commercial. See: <http://creativecommons.org/licenses/by-nc/4.0/>

Manuscript source: Invited manuscript

Received: December 29, 2019

Peer-review started: December 29, 2019

First decision: January 19, 2020

Revised: March 27, 2020

Accepted: April 10, 2020

Article in press: April 10, 2020

Published online: April 26, 2020

P-Reviewer: Andrejic-Visnjic B, Fatemi R, Lambrecht NW

S-Editor: Dou Y

L-Editor: Wang TQ

E-Editor: Li X



gastric BC. The patient recovered well with normal CA 72-4 levels, and her course was uneventful at 10 mo.

CONCLUSION

This is a valuable report as it describes an extremely rare case of gastric BC. Moreover, this is the first case of BC to present with elevated CA 72-4 levels.

Key words: Bronchogenic cyst; Stomach; Submucosal lesion; Endoscopic ultrasound-guided fine needle aspiration; Endosonography; Case report

©The Author(s) 2020. Published by Baishideng Publishing Group Inc. All rights reserved.

Core tip: Gastric bronchogenic cysts (BCs) are extremely rare and present as non-characteristic cysts on preoperative examinations. We report a rare case of gastric BC with elevated carbohydrate antigen 72-4 which is symptomatic and even not be considered for a correct diagnosis before surgery. The diagnosis of gastric BC was confirmed by the final pathological results after laparoscopic resection. We emphasize that BCs should be included in the differential diagnosis of cysts occurring in the stomach detected by imaging. And we recommend trying to acquire indication whether the mass invades the stomach wall through enhanced computed tomography to give doctors confidence in diagnosis. Endoscopic ultrasound-guided fine needle aspiration may provide the definite diagnosis of gastric BCs and even allows for conservative treatment, but much research will be still needed to confirm that.

Citation: He WT, Deng JY, Liang H, Xiao JY, Cao FL. Bronchogenic cyst of the stomach: A case report. *World J Clin Cases* 2020; 8(8): 1525-1531

URL: <https://www.wjgnet.com/2307-8960/full/v8/i8/1525.htm>

DOI: <https://dx.doi.org/10.12998/wjcc.v8.i8.1525>

INTRODUCTION

Gastric bronchogenic cysts (BCs) are an extremely rare congenital disease. They present as a cystic mass formed due to the abnormal development of the respiratory system during the embryonic period^[1]. According to the location of the lesion, they can be divided into a mediastinal type, an intrapulmonary type, and an ectopic type^[2]. Compared with rare extrathoracic and subdiaphragmatic BCs, gastric BCs are even more hard to be seen^[3]. It has been put forwarded that BCs may have very rare chances to lose contact with the tracheobronchial tree and migrate to other parts^[4]. Gastric bronchial cysts was first reported in 1956, and as of 2019, only a few cases have been described in reports available in the MEDLINE/PubMed online databases. The age at diagnosis of BCs covers a large range, from 25 to 81 years, its incidence is approximately twice as high in females as in males, and it generally occurs in the posterior wall of the gastric body and the lesser curve of the stomach^[5]. Usually, there are no obvious clinical symptoms in the early stage of the disease, but upper abdominal pain, nausea, and vomiting are the most common symptoms at present. These may be related to the enlargement of the cyst causing swelling and exerting pressure on surrounding tissues and organs or secondary infection and perforation^[6]. Its imaging findings also lack specificity. In view of the above situation, diagnosing this condition before surgery is difficult, and the rate of misdiagnosis is high; however, fortunately, its prognosis is good^[7]. To lay a foundation for future clinical work, we report a 55-year-old patient with gastric BC and performed a review of the literature.

CASE PRESENTATION

Chief complaints

Intermittent epigastric pain.

History of present illness

A 55-year-old Chinese female patient visited our hospital presenting with intermittent

epigastric pain for 3 mo with no nausea, vomiting, sour regurgitation, belch, dysphagia, melena, or weight loss. In addition, she recovered spontaneously.

History of past illness

She had a history of contrast medium-related hypersensitivity reactions.

Personal and family history

She had a caesarean section 27 years ago.

Physical examination upon admission

Her abdomen was smooth and soft and free of tenderness or an overt mass. The bowel sounds were normal.

Laboratory examinations

On admission, among the tumor markers, only carbohydrate antigen 72-4 (CA 72-4) level was slightly high at 8.30 U/mL (normal range, 0-6.9 U/mL). Other results, including blood biochemistry, complete blood count and so on, were within normal limits.

Imaging examinations

An endoscopic ultrasound (EUS) examination showed a 45 mm × 49 mm single cyst originating from the gastric submucosa. It also revealed that the cyst, without any echoes or colour flow signals, was located in the posterior wall of the fundus close to the cardia. These results indicated the possibility of cystic hygroma of the stomach (Figure 1). Furthermore, a plain computed tomography (CT) scan demonstrated a 52 mm × 43 mm quasi-circular mass. It appeared to have a low density of 29 HU and was closely related to the stomach wall of the lesser curvature of the gastric fundus, which also showed an extraluminal growth pattern with an obvious border (Figure 2). In addition, no obvious enlarged lymph nodes were found around the stomach or retroperitoneal area. Based on the above findings, a possibility for benign cyst of the gastric submucosa was considered preoperatively.

FINAL DIAGNOSIS

Based on the obtained specimen, this mass was accompanied by a complete capsule with a rough inner wall and measured approximately 70 mm × 60 mm × 20 mm in size. It was found to contain viscous yellow liquid. Microscopically, pseudostratified ciliated columnar epithelial cells could be observed in the cyst lining, and the structure of these cells was the same as that of the bronchus (Figure 3). Combined with immunohistochemical staining for CK7 (+), CK20 (-), TTF1 (-), and S-100 (-), the pathologists ultimately verified that this cystic mass of the fundus was a gastric BC.

TREATMENT

As the above imaging examinations did not clearly indicate the benign or malignant nature of the cyst and the patient wished to have the lesion completely removed, we performed a da Vinci robotic-assisted laparoscopic partial gastrectomy. Intraoperative findings of this cystic mass showed it was a smooth single-port cyst originating from the submucosa of the posterior gastric wall close to the cardia. Through surgical exploration, the gastric cavity was confirmed to be intact and smooth, and no discrete nodules were noted. Then, the cystic mass was curatively resected from the stomach, and the surgeons paid attention to avoiding cyst rupture simultaneously (Figure 4).

OUTCOME AND FOLLOW-UP

The patient recovered well, and her symptoms disappeared completely with a repeat CA 72-4 level normalized to 24 U/mL (0-37 U/mL) after surgery. There was no recurrence in the following 10 mo.

DISCUSSION

On imaging, a rounded cystic lesion with a well-defined boundary and no intracystic septa was noted. EUS is usually used to determine which layer of the gastric wall the

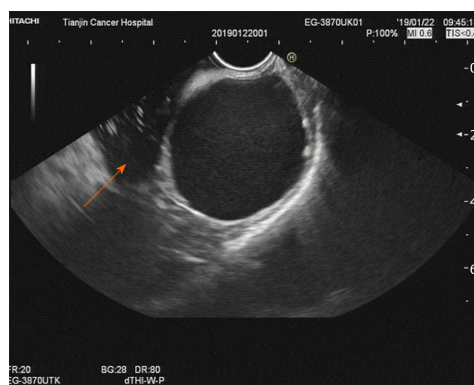


Figure 1 Imaging at admission. An endoscopic ultrasound examination showed a 45 mm × 49 mm single cyst originating from the gastric submucosa (arrow). It also revealed that the cyst, without any echoes or color flow signals, was located in the posterior wall of the fundus close to the cardia. These results indicated the possibility of cystic hygroma of the stomach.

lesion originates from and its general location. EUS can also reveal liquid within the cyst depending on the smooth wall and almost no echo in the lumen^[8]. CT shows the location of the cyst and its relationship with surrounding tissues. On a plain CT scan, a hypodense lesion was observed, while on contrast-enhanced scan, there was no enhancement^[8]. Approximately half of the cysts showed a water density value of less than 20 HU on CT^[8,9]. It should be noted that if the fluid component within the cyst is thick due to a high protein content, haemorrhage, infection or calcification, a deep lesion, or poorly displayed flow signal, ultrasonography will show hypoechoic signals, and the CT value will increase^[4,9-11]. These cause the cysts to be easily mistaken for solid tumors^[2,12,13].

Above CT and EUS features are still not characteristic to distinguish gastric BCs from other lesions found in the submucosa of the stomach.

The final diagnosis usually depends on a pathological examination of postoperative specimens. Pathological examination will show that the capsule contains viscous or jelly-like fluid and that the wall of the capsule is lined with pseudostratified ciliated columnar epithelium accompanied by glands, smooth muscle, and cartilage tissue in partial lesions^[2,14]. Some scholars believe that the discovery of ciliated respiratory epithelium and mucin on the stomach wall by EUS-guided fine needle aspiration (EUS-FNA) is sufficient for a presumptive diagnosis of cyst type, although cyst wall cartilage is considered to be the most classic basis for diagnosing BCs, a feature that cannot be unrecognized by EUS-FNA^[15]. However, there is only one case with no recurrence after being diagnosed and treated as gastric BC by EUS-FNA currently^[15].

Despite the questionable indications for surgical intervention, the most common choice is to remove the cyst completely *via* a surgical operation. We suggest that asymptomatic gastric BCs should be followed, while open surgery or laparoscopic surgery should be selected for large and symptomatic lesions, especially those with symptoms of infection and even malignant lesions^[16,17]. For smaller lesions, conservative or minimally invasive treatments are also being explored. It has been reported that EUS-FNA and endoscopic mucosal resection successfully cure gastric BCs^[15,18].

This is an interesting case with symptoms, elevated CA 72-4, and even unclear preoperative diagnosis. The patient's epigastric pain was caused by the enlargement of the cyst and compression of the stomach.

One of the most unusual characteristics in this case was the correlative elevated CA 72-4 level, as in all other reported cases CA 19-9 was selected when tumor markers were raised, including those with oesophageal origins^[9], gastric origins^[18], and mediastinal origins^[19,20]. Therefore, this is the first case of gastric BCs to manifest as described above. Consistent with this, these elevated tumor markers returned to normal after surgery^[7,9,19-21], prompting us to suggest that there seems to be a direct relationship between the benign BCs and elevated tumor marker levels. However, no specific indicators have been found, and the importance of different elevated tumor markers for gastric BCs needs to be further studied.

The most regrettable thing in this case is that the preoperative diagnosis is not clear. First, it is easy to be ignored on account of the rarity of BCs. The possibility of gastric BCs should be considered when imaging suggests fluid-containing cysts in the gastric submucosa. Second, its non-specific imaging results cannot give a clear hint. Third, because the patient was allergic to the contrast agent, he failed to perform an

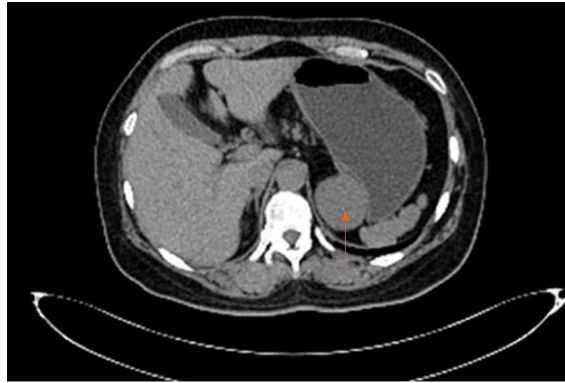


Figure 2 Imaging at admission. A plain computed tomography scan demonstrated a 52 mm × 43 mm quasi-circular mass (arrow). It appeared to have a low density of 29 HU and was closely related to the lesser curvature of the gastric fundus, which also showed an extraluminal growth pattern with an obvious border.

enhanced CT which will further suggest whether the cystic lesions invaded the gastric wall. At last, after EUS revealed liquid within the cyst, no attempt was made to obtain further cytological diagnosis by EUS-FNA which maybe allow for the possibility of a confirmed diagnosis. We emphasize that BCs should be reserved in the differential diagnosis of cysts occurring in the stomach detected by imaging. And we recommend trying to acquire indication whether the mass invades the stomach wall through enhanced CT to give doctors confidence in diagnosis. EUS-FNA may provide the definite diagnosis of gastric BC and even allows for conservative treatment, but much research is still needed to confirm it.

CONCLUSION

This report is significant because it describes a very rare case of gastric BC. In addition, this is the first report to describe an increase in CA 72-4 levels in BC. This finding could be conducive to achieving better preoperative diagnoses and better choice of treatment and improving our understanding of the disease.

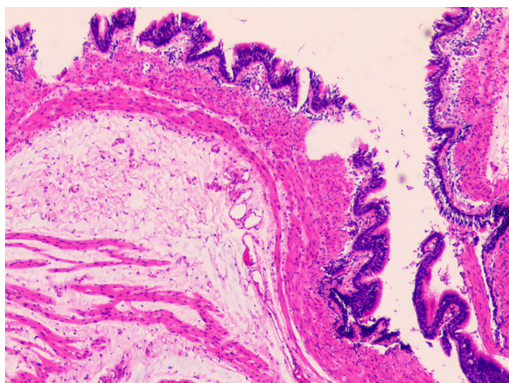


Figure 3 Postoperative histopathology. Microscopically, pseudostratified ciliated columnar epithelial cells could be observed in the cyst wall, and the structure of these cells was the same as that of the bronchus. Combined with immunohistochemical staining for CK7 (+), CK20 (-), TTF1 (-), and S-100 (-), the pathologists ultimately verified that this cystic mass of the fundus was a gastric bronchogenic cyst (×100).

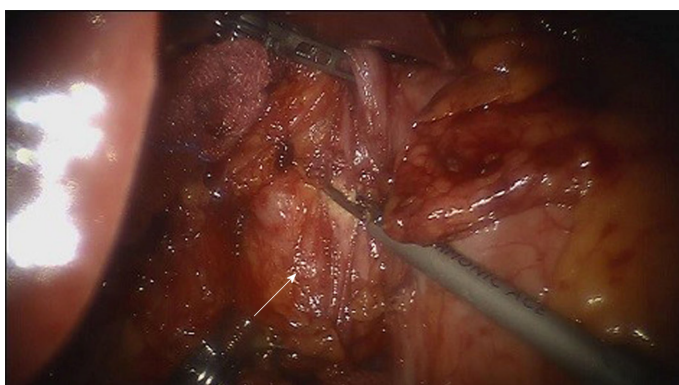


Figure 4 Imaging during operation. Intraoperative findings of this cystic mass showed that it was a smooth single-port cyst originating from the submucosa of the posterior gastric wall close to the cardia (arrow). Then, the cystic mass was curatively resected from the stomach, and the surgeons paid attention to avoiding cyst rupture simultaneously.

REFERENCES

- 1 **Ubukata H**, Satani T, Motohashi G, Konishi S, Goto Y, Watanabe Y, Nakada I, Tabuchi T. Intra-abdominal bronchogenic cyst with gastric attachment: report of a case. *Surg Today* 2011; **41**: 1095-1100 [PMID: 21773899 DOI: 10.1007/s00595-010-4398-6]
- 2 **McAdams HP**, Kirejczyk WM, Rosado-de-Christenson ML, Matsumoto S. Bronchogenic cyst: imaging features with clinical and histopathologic correlation. *Radiology* 2000; **217**: 441-446 [PMID: 11058643 DOI: 10.1148/radiology.217.2.r00nv19441]
- 3 **Takeda S**, Miyoshi S, Minami M, Ohta M, Masaoka A, Matsuda H. Clinical spectrum of mediastinal cysts. *Chest* 2003; **124**: 125-132 [PMID: 12853514 DOI: 10.1378/chest.124.1.125]
- 4 **Sumiyoshi K**, Shimizu S, Enjoji M, Iwashita A, Kawakami K. Bronchogenic cyst in the abdomen. *Virchows Arch A Pathol Anat Histopathol* 1985; **408**: 93-98 [PMID: 3933174 DOI: 10.1007/bf00739965]
- 5 **Yang X**, Guo K. Bronchogenic cyst of stomach: two cases report and review of the English literature. *Wien Klin Wochenschr* 2013; **125**: 283-287 [PMID: 23579880 DOI: 10.1007/s00508-013-0352-0]
- 6 **Monin MI**, Pudovikov SS, Topalov KP. [Surgical treatment of mediastinal tumors and cysts]. *Vestn Khir Im I I Grek* 1987; **138**: 12-15 [PMID: 3672770]
- 7 **Tan KK**, Nandini CL, Ho CK. A case of gastric bronchogenic cyst in Singapore with multiple intrigues. *ANZ J Surg* 2010; **80**: 286-287 [PMID: 20575959 DOI: 10.1111/j.1445-2197.2010.05260.x]
- 8 **Murakami R**, Machida M, Kobayashi Y, Ogura J, Ichikawa T, Kumazaki T. Retroperitoneal bronchogenic cyst: CT and MR imaging. *Abdom Imaging* 2000; **25**: 444-447 [PMID: 10926202 DOI: 10.1007/s002610000019]
- 9 **Cheng Y**, Chen D, Shi L, Yang W, Sang Y, Duan S, Chen Y. Surgical treatment of an esophageal bronchogenic cyst with massive upper digestive tract hematoma without esophagectomy: a case report and the review of the literature. *Ther Clin Risk Manag* 2018; **14**: 699-707 [PMID: 29765221 DOI: 10.2147/TCRM.S153145]
- 10 **Sirivella S**, Ford WB, Zikria EA, Miller WH, Samadani SR, Sullivan ME. Foregut cysts of the mediastinum. Results in 20 consecutive surgically treated cases. *J Thorac Cardiovasc Surg* 1985; **90**: 776-782 [PMID: 4058048 DOI: 10.1016/S0022-5223(19)38547-2]
- 11 **Wiech T**, Walch A, Werner M. Histopathological classification of nonneoplastic and neoplastic gastrointestinal submucosal lesions. *Endoscopy* 2005; **37**: 630-634 [PMID: 16010607 DOI: 10.1055/s-2005-870127]
- 12 **Melo N**, Pitman MB, Rattner DW. Bronchogenic cyst of the gastric fundus presenting as a gastrointestinal

- stromal tumor. *J Laparoendosc Adv Surg Tech A* 2005; **15**: 163-165 [PMID: [15898909](#) DOI: [10.1089/lap.2005.15.163](#)]
- 13 **Fazel A**, Moezardalan K, Varadarajulu S, Draganov P, Eloubeidi MA. The utility and the safety of EUS-guided FNA in the evaluation of duplication cysts. *Gastrointest Endosc* 2005; **62**: 575-580 [PMID: [16185972](#) DOI: [10.1016/j.gie.2005.06.014](#)]
 - 14 **Cuyppers P**, De Leyn P, Cappelle L, Verougstraete L, Demedts M, Deneffe G. Bronchogenic cysts: a review of 20 cases. *Eur J Cardiothorac Surg* 1996; **10**: 393-396 [PMID: [8817131](#) DOI: [10.1016/s1010-7940\(96\)80103-5](#)]
 - 15 **Sato M**, Irisawa A, Bhutani MS, Schnadig V, Takagi T, Shibukawa G, Wakatsuki T, Imamura H, Takahashi Y, Sato A, Hikichi T, Obara K, Hashimoto Y, Watanabe K, Ohira H. Gastric bronchogenic cyst diagnosed by endosonographically guided fine needle aspiration biopsy. *J Clin Ultrasound* 2008; **36**: 237-239 [PMID: [18027836](#) DOI: [10.1002/jcu.20425](#)]
 - 16 **Shibahara H**, Arai T, Yokoi S, Hayakawa S. Bronchogenic cyst of the stomach involved with gastric adenocarcinoma. *Clin J Gastroenterol* 2009; **2**: 80-84 [PMID: [26192170](#) DOI: [10.1007/s12328-008-0042-z](#)]
 - 17 **Sun L**, Lu L, Fu W, Li W, Liu T. Gastric bronchogenic cyst presenting as a gastrointestinal stromal tumor. *Int J Clin Exp Pathol* 2015; **8**: 13606-13612 [PMID: [26722583](#)]
 - 18 **Lee SH**, Park DH, Park JH, Kim HS, Park SH, Kim SJ, Oh MH. Endoscopic mucosal resection of a gastric bronchogenic cyst that was mimicking a solid tumor. *Endoscopy* 2006; **38** Suppl 2: E12-E13 [PMID: [17366384](#) DOI: [10.1055/s-2006-944862](#)]
 - 19 **Okubo A**, Sone S, Ogushi F, Ogura T, Uyama T, Monden Y, Ii K. A case of bronchogenic cyst with high production of antigen CA 19-9. *Cancer* 1989; **63**: 1994-1997 [PMID: [2702572](#)]
 - 20 **Okabayashi K**, Motohiro A, Ueda H, Ondo K, Kawahara K, Shirakusa T. Subcarinal bronchogenic cyst with high carbohydrate antigen 19-9 production. *Jpn J Thorac Cardiovasc Surg* 2002; **50**: 46-48 [PMID: [11855101](#) DOI: [10.1007/bf02913488](#)]
 - 21 **Chen J**, Liu Q, Ling Y, Yang H, Wen J, Luo K, Hu Y, Tan Z, Fu J. Extraordinarily elevated serum CA19-9 in a patient with posterior mediastinum cyst: a case report. *Clin Chem Lab Med* 2017; **55**: e279-e281 [PMID: [28672729](#) DOI: [10.1515/ccbm-2017-0001](#)]



Published By Baishideng Publishing Group Inc
7041 Koll Center Parkway, Suite 160, Pleasanton, CA 94566, USA
Telephone: +1-925-3991568
E-mail: bpgoffice@wjgnet.com
Help Desk: <https://www.f6publishing.com/helpdesk>
<https://www.wjgnet.com>

