

Name of Journal: *World Journal of Clinical Cases*

Manuscript NO: 54183

Manuscript Type: CASE REPORT

Portal hypertension in a case with biliary hamartomas: A case report

Li QQ *et al.* BH

Qian-Qian Li, Xiao-Zhong Guo, Hong-Yu Li, Xing-Shun Qi

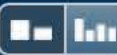BACKGROUND

Biliary hamartomas (BH) are a rare benign disease caused by malformation of the intrahepatic bile ducts. BH are occasionally diagnosed, but often lacking obvious clinical symptoms. They are usually diagnosed by biopsy and imaging tests in clinical practice. Few studies have reported the association of BH with portal hypertension.

CASE SUMMARY

A 40-year-old man was repeatedly admitted to our hospital due to hematochezia. The source of bleeding was considered as gastroesophageal

Match Overview



1	Internet 50 words crawled on 05-Jan-2020 tgh.amegroups.com	3%
2	Internet 18 words crawled on 26-Jan-2004 intl-radiographics.rsna.org	1%
3	Crossref 12 words Sherlock. "Cysts and Congenital Biliary Abnormalities", <i>Diseases of the Liver and Biliary System</i> , 12/12/2001	1%

Portal hypertension in a case with biliary hamartomas:



ALL

IMAGES

VIDEOS

58,800 Results

Any time ▾

Case Report: Portal Hypertension Secondary to Isolated ...

<https://www.ncbi.nlm.nih.gov/pmc/articles/PMC3391043>

Jul 01, 2012 · Conclusion. We have **reported a case** in which isolated **hepatic TB** caused **portal hypertension** and **gastrointestinal bleeding** mimicking some of the clinical and pathologic features of **hepatic schistosomiasis**. In endemic areas, TB should be considered in the differential diagnosis of non-cirrhotic **portal hypertension**.

Cited by: 5

Author: Mona Mojtahedzadeh, Salman Otouke...

Publish Year: 2012

Pulmonary hypertension associated with primary biliary ...

<https://www.ncbi.nlm.nih.gov/pmc/articles/PMC1374510>

Pulmonary hypertension associated with primary **biliary cirrhosis** in the absence of **portal hypertension: a case report**. Department of Medicine, ...

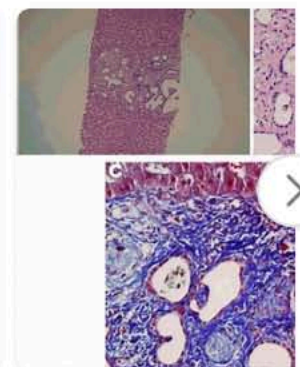
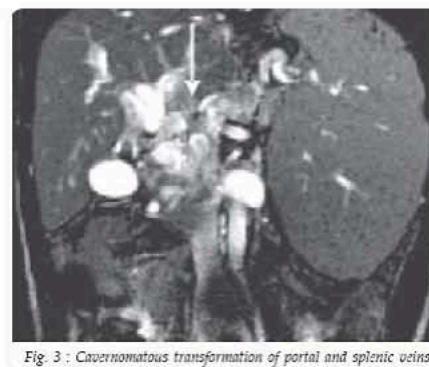
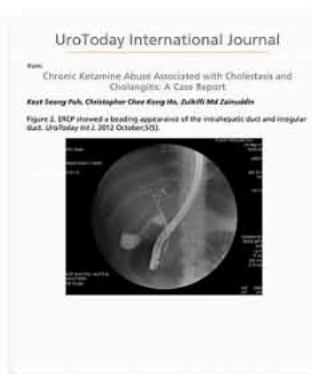
Cited by: 19

Author: E M Yoshida, S R Erb, D N Ostrow, D R ...

Publish Year: 1994

Images of Portal Hypertension in a case with BILIARY Hamartomas ...

bing.com/images



See more images of Portal Hypertension in a case with BILIARY Hamartomas a case report



Portal hypertension in a case with biliary hamartomas: A



ALL

IMAGES

VIDEOS

MAPS

NEWS

SHOPPING

59,100 Results

Any time ▾

Case Report: Portal Hypertension Secondary to Isolated ...

<https://www.ncbi.nlm.nih.gov/pmc/articles/PMC3391043>

Jul 01, 2012 · Conclusion. We have **reported a case** in which isolated **hepatic TB** caused **portal hypertension** and **gastrointestinal bleeding** mimicking some of the clinical and ... +

Cited by: 5

Author: Mona Mojtahedzadeh, Salman Otoukesh,...

Publish Year: 2012

Pulmonary hypertension associated with primary biliary ...

<https://www.ncbi.nlm.nih.gov/pmc/articles/PMC1374510>

Pulmonary hypertension associated with primary **biliary cirrhosis** in the absence of **portal hypertension: a case report**. Department of Medicine, University of ...

Cited by: 19

Author: E M Yoshida, S R Erb, D N Ostrow, D R ...

Publish Year: 1994

Biliary Hamartoma - PubMed Central (PMC)

<https://www.ncbi.nlm.nih.gov/pmc/articles/PMC4462460>

Nov 06, 2013 · Although **jaundice** and **portal hypertension** may arise as a result of **mass effect**, patients are usually asymptomatic . The **biliary hamartomas** may be single or ... +

[PDF] Intrahepatic cholangiocarcinoma and portal hypertension ...

www.mjpath.org.my/2018/v40n3/intrahepatic-cholangiocarcinoma.pdf

portal hypertension, which could be associated with **excessive bleeding** and perioperative morbidity. **Adequate care** is required when clinical evidence of **portal hypertension** exists in a patient ... +

Portal hypertensive biliopathy | Radiology Case ...

<https://radiopaedia.org/cases/portal-hypertensive-biliopathy>

Case Discussion. **Portal** biliopathy (PB) is a rare disorder defined as abnormalities of the extrahepatic and intrahepatic bile ducts (usually obstruction), gallbladder and cystic duct, observed in patients ... +

Hepatic von Meyenburg complex: A trigger of severe portal ...

<https://www.researchgate.net/publication/23483061...>

<https://www.ncbi.nlm.nih.gov/pmc/articles/PMC3391043/> Introduction. We report a case of intrahepatic cholangiocarcinoma and portal hypertension