

# World Journal of *Gastroenterology*

*World J Gastroenterol* 2020 June 28; 26(24): 3318-3516



**OPINION REVIEW**

- 3318** Extended lymphadenectomy in hilar cholangiocarcinoma: What it will bring?  
*Li J, Zhou MH, Ma WJ, Li FY, Deng YL*

**REVIEW**

- 3326** Non-invasive tests for the prediction of primary hepatocellular carcinoma  
*Marasco G, Colecchia A, Silva G, Rossini B, Eusebi LH, Ravaoli F, Dajti E, Alemanni LV, Colecchia L, Renzulli M, Golfieri R, Festi D*
- 3344** Intestinal  $\text{Ca}^{2+}$  absorption revisited: A molecular and clinical approach  
*Areco VA, Kohan R, Talamoni G, Tolosa de Talamoni NG, Peralta López ME*
- 3365** Interventions of natural and synthetic agents in inflammatory bowel disease, modulation of nitric oxide pathways  
*Kamalian A, Sohrabi Asl M, Dolatshahi M, Afshari K, Shamshiri S, Momeni Roudsari N, Momtaz S, Rahimi R, Abdollahi M, Abdolghaffari AH*
- 3401** Long noncoding RNAs in gastric cancer: From molecular dissection to clinical application  
*Gao Y, Wang JW, Ren JY, Guo M, Guo CW, Ning SW, Yu S*

**MINIREVIEWS**

- 3413** Ultrasound liver elastography beyond liver fibrosis assessment  
*Ferraioli G, Barr RG*
- 3421** Recent progress in pulsed electric field ablation for liver cancer  
*Liu ZG, Chen XH, Yu ZJ, Lv J, Ren ZG*

**ORIGINAL ARTICLE****Basic Study**

- 3432** Hepatoprotective effects of *Hovenia dulcis* seeds against alcoholic liver injury and related mechanisms investigated *via* network pharmacology  
*Meng X, Tang GY, Zhao CN, Liu Q, Xu XY, Cao SY*

**Retrospective Cohort Study**

- 3447** Comparison of operative link for gastritis assessment, operative link on gastric intestinal metaplasia assessment, and TAIM stagings among men with atrophic gastritis  
*Nieminen AA, Kontto J, Puolakkainen P, Virtamo J, Kokkola A*

- 3458** Multiphase computed tomography radiomics of pancreatic intraductal papillary mucinous neoplasms to predict malignancy  
*Polk SL, Choi JW, McGettigan MJ, Rose T, Ahmed A, Kim J, Jiang K, Balagurunathan Y, Qi J, Farah PT, Rath A, Permuth JB, Jeong D*

**Retrospective Study**

- 3472** Transjugular intrahepatic portosystemic shunt for pyrrolizidine alkaloid-related hepatic sinusoidal obstruction syndrome  
*Zhou CZ, Wang RF, Lv WF, Fu YQ, Cheng DL, Zhu YJ, Hou CL, Ye XJ*

**Observational Study**

- 3484** Evaluation of characteristics of left-sided colorectal perfusion in elderly patients by angiography  
*Zhang C, Li A, Luo T, Li Y, Li F, Li J*

**SYSTEMATIC REVIEWS**

- 3495** Clinical efficacy of the over-the-scope clip device: A systematic review  
*Bartell N, Bittner K, Kaul V, Kothari TH, Kothari S*

**ABOUT COVER**

Editorial board member of *World Journal of Gastroenterology*, Dr. Ji is a Distinguished Professor in Shanghai University of Traditional Chinese medicine, Shanghai, China. Having received his Bachelor degree from Yangzhou College of medicine in 1991, Dr. Ji undertook his postgraduate training first at Hubei College of Traditional Chinese medicine, received his Master degree in 1994, and then at Shanghai University of Traditional Chinese medicine, received his PhD in 1997. He became Chief Physician in the Gastroenterology Division, Longhua Hospital affiliated to Shanghai University of Traditional Chinese medicine since 2004. His ongoing research interests are applying Evidence-based medicine methods to study the effects, and managing the disease-syndrome pattern establishment of integrative medicine on digestive diseases. Currently, he is the President of the Shanghai Association for the Study of the Liver with integrative medicine.

**AIMS AND SCOPE**

The primary aim of *World Journal of Gastroenterology* (WJG, *World J Gastroenterol*) is to provide scholars and readers from various fields of gastroenterology and hepatology with a platform to publish high-quality basic and clinical research articles and communicate their research findings online. WJG mainly publishes articles reporting research results and findings obtained in the field of gastroenterology and hepatology and covering a wide range of topics including gastroenterology, hepatology, gastrointestinal endoscopy, gastrointestinal surgery, gastrointestinal oncology, and pediatric gastroenterology.

**INDEXING/ABSTRACTING**

The WJG is now indexed in Current Contents®/Clinical Medicine, Science Citation Index Expanded (also known as SciSearch®), Journal Citation Reports®, Index Medicus, MEDLINE, PubMed, PubMed Central, and Scopus. The 2019 edition of Journal Citation Report® cites the 2018 impact factor for WJG as 3.411 (5-year impact factor: 3.579), ranking WJG as 35<sup>th</sup> among 84 journals in gastroenterology and hepatology (quartile in category Q2).

**RESPONSIBLE EDITORS FOR THIS ISSUE**

Electronic Editor: Yan-Liang Zhang; Production Department Director: Yun-Xiaojuan Wu; Editorial Office Director: Ze-Mao Gong.

**NAME OF JOURNAL**

*World Journal of Gastroenterology*

**ISSN**

ISSN 1007-9327 (print) ISSN 2219-2840 (online)

**LAUNCH DATE**

October 1, 1995

**FREQUENCY**

Weekly

**EDITORS-IN-CHIEF**

Andrzej S Tarnawski, Subrata Ghosh

**EDITORIAL BOARD MEMBERS**

<http://www.wjgnet.com/1007-9327/editorialboard.htm>

**PUBLICATION DATE**

June 28, 2020

**COPYRIGHT**

© 2020 Baishideng Publishing Group Inc

**INSTRUCTIONS TO AUTHORS**

<https://www.wjgnet.com/bpg/gerinfo/204>

**GUIDELINES FOR ETHICS DOCUMENTS**

<https://www.wjgnet.com/bpg/GerInfo/287>

**GUIDELINES FOR NON-NATIVE SPEAKERS OF ENGLISH**

<https://www.wjgnet.com/bpg/gerinfo/240>

**PUBLICATION ETHICS**

<https://www.wjgnet.com/bpg/GerInfo/288>

**PUBLICATION MISCONDUCT**

<https://www.wjgnet.com/bpg/gerinfo/208>

**ARTICLE PROCESSING CHARGE**

<https://www.wjgnet.com/bpg/gerinfo/242>

**STEPS FOR SUBMITTING MANUSCRIPTS**

<https://www.wjgnet.com/bpg/GerInfo/239>

**ONLINE SUBMISSION**

<https://www.f6publishing.com>





## Observational Study

# Evaluation of characteristics of left-sided colorectal perfusion in elderly patients by angiography

Chao Zhang, Ang Li, Tao Luo, Yu Li, Fei Li, Jia Li

**ORCID number:** Chao Zhang (0000-0002-1825-0097); Ang Li (0000-0003-4795-8374); Tao Luo (0000-0002-4641-0027); Yu Li (0000-0002-7188-2528); Fei Li (0000-0002-1713-967X); Jia Li (0000-0001-6343-252X).

**Author contributions:** Zhang C and Li A are co-first authors; Zhang C, Li A, and Li J designed and performed the research; Zhang C, Li A and Luo T performed the angiography; Li Y and Li F contributed the analytical tools; Zhang C, Li Y, and Li F analyzed and interpreted the data; Zhang C wrote the manuscript; Li A and Li J revised the manuscript; all authors read and approved the final manuscript.

**Supported by** the National Natural Science Foundation of China, No. 81800483.

### Institutional review board

**statement:** The study was reviewed and approved by the Ethical Committee of Xuanwu Hospital, Capital Medical University (Beijing).

**Informed consent statement:** All study participants, or their legal guardian, provided informed written consent prior to study enrollment.

### Conflict-of-interest statement:

There are no conflicts of interest to report.

**Data sharing statement:** No additional data are available.

**STROBE statement:** This study meets the requirements of the

**Chao Zhang, Ang Li, Tao Luo, Yu Li, Fei Li, Jia Li,** Department of General Surgery, Xuanwu Hospital, Capital Medical University, Beijing 100053, China

**Chao Zhang, Ang Li, Tao Luo, Yu Li, Fei Li, Jia Li,** Gastroenteropancreatic Center, National Clinical Research Center for Geriatric Diseases, Beijing 100053, China

**Corresponding author:** Jia Li, MD, PhD, Chief Doctor, Department of General Surgery, Xuanwu Hospital, Capital Medical University, No. 45, Changchun Street, Xicheng District, Beijing 100053, China. [Jiali35@126.com](mailto:Jiali35@126.com)

## Abstract

### BACKGROUND

Handling of the inferior mesenteric artery (IMA) and maintaining anastomotic perfusion are important in radical resection of left-sided colorectal cancer. However, the branching of this artery and the drainage patterns of this vein vary among individuals, and the characteristics and perfusion region of this artery in elderly patients remain unclear.

### AIM

To evaluate the characteristics and perfusion region of the IMA in elderly patients using angiography.

### METHODS

We enrolled 154 patients (> 65 years old) who underwent digital subtraction angiography of the IMA. The characteristics, bifurcation, and distribution of the IMA and termination of the anastomotic perfusion of the left colon and rectum were examined using digital subtraction angiography. Collateral arterial arches and the IMA hemoperfusion region were also recorded. Perfusion regions were cross-referenced with clinical and anatomical features by the univariate analysis.

### RESULTS

Of 154 patients, 25 (16.2%) had IMA lesions. The left colic artery arose independently from the IMA in 44.2% of patients, shared a trunk with the sigmoid artery in 35.1%, shared an opening with the sigmoid and superior rectal arteries in 16.9%, and was absent in 5.1%. The IMA perfusion region stopped at the splenic flexure in 50 (32.5%) patients. The collateral circulation existed in the colonic perfusion region, including the marginal artery (Drummond's artery), the ascending branch of the left colonic artery to supply the transverse colon, and the arc of Riolo with a frequency of 100%, 22.7%, and 1.9%, respectively. The IMA perfusion region was independently associated with the comorbidity of

STROBE guidelines.

**Open-Access:** This article is an open-access article that was selected by an in-house editor and fully peer-reviewed by external reviewers. It is distributed in accordance with the Creative Commons Attribution NonCommercial (CC BY-NC 4.0) license, which permits others to distribute, remix, adapt, build upon this work non-commercially, and license their derivative works on different terms, provided the original work is properly cited and the use is non-commercial. See: <http://creativecommons.org/licenses/by-nc/4.0/>

**Manuscript source:** Unsolicited manuscript

**Received:** February 1, 2020

**Peer-review started:** February 1, 2020

**First decision:** March 15, 2020

**Revised:** March 17, 2020

**Accepted:** May 19, 2020

**Article in press:** May 19, 2020

**Published online:** June 28, 2020

**P-Reviewer:** Fiori E, Kawabata H, Richardson WS, Viswanath Y

**S-Editor:** Zhang H

**L-Editor:** Wang TQ

**E-Editor:** Zhang YL



atherosclerosis, IMA atherosclerotic lesion, branching pattern, collateral circulation, and marginal artery integrity.

## CONCLUSION

The IMA and its branches are prone to arteriosclerosis, and IMA perfusion may be interrupted at the splenic flexure in elderly patients. The applicability and precision of preoperative angiography for evaluating the IMA branching and perfusion patterns could facilitate geriatric laparoscopic left-sided colorectal cancer surgery with suspicion of poor IMA perfusion.

**Key words:** Anatomy; Digital subtraction angiography; Elderly; Inferior mesenteric artery; Left-sided colectomy

©The Author(s) 2020. Published by Baishideng Publishing Group Inc. All rights reserved.

**Core tip:** In this study, we enrolled 154 patients (> 65 years old) who underwent digital subtraction angiography of the inferior mesenteric artery (IMA). The characteristics and perfusion patterns of the IMA were examined. Perfusion regions were cross-referenced with clinical and anatomical features. Our study demonstrated that 25 (16.2%) patients had IMA lesions and the IMA perfusion region stopped at the splenic flexure in 50 (32.5%) elderly patients. The IMA perfusion region was independently associated with IMA atherosclerotic lesion, branching pattern, collateral circulation, and marginal artery integrity. Thus, the applicability and precision of preoperative angiography for evaluating the IMA branching and perfusion patterns could facilitate geriatric laparoscopic left-sided colorectal cancer surgery with suspicion of poor IMA perfusion.

**Citation:** Zhang C, Li A, Luo T, Li Y, Li F, Li J. Evaluation of characteristics of left-sided colorectal perfusion in elderly patients by angiography. *World J Gastroenterol* 2020; 26(24): 3484-3494

**URL:** <https://www.wjgnet.com/1007-9327/full/v26/i24/3484.htm>

**DOI:** <https://dx.doi.org/10.3748/wjg.v26.i24.3484>

## INTRODUCTION

Colorectal cancer (CRC) largely affects elderly patients, and the incidence of CRC increases with age, peaking at 70 years<sup>[1,2]</sup>. Laparoscopic surgery has made it possible for elderly CRC patients to undergo surgical treatment and has become a standard procedure around the world. Handling of the inferior mesenteric artery (IMA) and vein is important in low anterior resection and abdominoperineal excision for radical resection of left-sided CRC. However, the branching pattern of the IMA varies among individuals, and the hemoperfusion region has become one of the important issues related to the anastomotic complication and the outcome of CRC resection in elderly patients. Thus, it is very important to identify these variations to ensure successful vessel ligation during surgery for left-sided CRC. Additionally, no evidence-based studies have focused on IMA perfusion and arterial communication between the superior mesenteric artery (SMA) and IMA in elderly patients. Understanding the characteristics of these vessels and applying appropriate techniques are mandatory for improving the quality of surgery and the outcomes in elderly CRC patients. To the best of our knowledge, this report is the first to address the angiographic anatomy of the left-side colectomy in elderly patients. In the present study, we aimed to demonstrate the characteristics, bifurcation, and distribution of the IMA and termination of the anastomotic perfusion of the left colon and rectum in elderly patients using digital subtraction angiography (DSA) that could facilitate safe CRC tumor resection in elderly population.

## MATERIALS AND METHODS

### Patient selection

Here, we present a retrospective study (Jan 2016–Dec 2018) of 837 patients who

underwent abdominal angiographic examination. This study was approved by the hospital ethical committee, and all participants signed an informed consent form. The inclusion criteria were as follows: (1) Patients aged  $\geq 65$  years<sup>[2,3]</sup>; (2) Patients who underwent interventional therapy and selective IMA angiography; and (3) Patients with stable vital signs without arterial spasm or excessive contraction. Patients with a history of abdominal surgery or radiotherapy, vasculitis (such as Leriche syndrome and Takayasu disease), congenital vascular malformation, acute hemorrhage, or severe shock were excluded. A total of 154 patients were finally included to be observed.

### **Digital subtraction angiography protocol**

DSA was performed under local anesthesia, usually using the right femoral approach. A 5-F cobra-shaped catheter (Cordis, NJ, United States) or the SIM1 catheter (Cook, IN, United States) was introduced into the femoral artery to catheterize the abdominal aorta and the catheter tip was towards the anterior (ventral) direction. Selective DSA was performed with the catheter tip in the proximal part of the IMA using nonionic Optiray contrast medium (ioversol, 350 mg I/mL; Covidien, Dublin, Ireland; 9 mL, 3 mL/s) with the anteroposterior oblique projection. All DSA procedures were performed by abdominal interventional radiologists with over 10 years of experience (Zhang C, Li A and Luo T).

### **Measurements and classification**

The general and IMA-specific characteristics were analyzed. The branching pattern of the IMA was classified into four different categories according to the origin of the left colic artery (LCA). The length and diameter of the IMA trunk were also measured. Collateral arterial arches and the IMA hemoperfusion region were also recorded. All data were measured and analyzed using the Philips Medical Workshop System (Philips Medical Co., NY, United States).

### **Statistical analysis**

Student's *t*-test and the chi-squared test were applied to evaluate differences in continuous variables and categorical variables for univariate analyses, respectively. All of the analyses were performed using the IBM SPSS Statistics 22 software, and differences were considered statistically significant at  $P < 0.05$ .

## **RESULTS**

### **Overall characteristics of patients**

Between January 2016 and December 2018, a total of 154 patients were retrospectively observed, including those with digestive system malignancy, like colorectal, hepatobiliary (primary or metastasis), and pancreatic cancer, who did not undergo open or laparoscopic abdominal surgery; and gastrointestinal hemorrhage without severe shock or arterial spasm or excessive contraction (Figure 1). Out of 154 patients, 90 were male and 64 were female. The patients' age ranged between 65 and 92 years; the average age was  $72.5 \pm 5.5$  years. Forty (26.0%) patients had a history of atherosclerosis, including 34 coronary heart disease; 11 ischemic cerebrovascular disease; and 4 arteriosclerotic obliteration of the lower limb (Table 1).

### **IMA characteristics and branching patterns**

In this study, we observed that the length of the IMA trunk varied from 1.1 to 7.8 cm, with an average length of  $3.7 \pm 1.5$  cm. The diameter of the IMA trunk was  $3.4 \pm 0.5$  mm and varied between 2.1 and 4.8 mm (Table 1). Of all 154 patients, 25 had arteriosclerotic lesions in the IMA and its branches, including 10 with stenosis, 3 with occlusion, and 12 with atherosclerotic plaque in the arterial wall (Figure 2). We also evaluated the branches of the IMA, including the LCA, sigmoid artery (SA), and superior rectal artery (SRA). We classified the branching patterns of the LCA into four types: Type I, LCA arose independently from the IMA; type II, the LCA and SA arose from the IMA at the same point; type III, the LCA, SA, and SRA were branched from a common trunk from the IMA; and type IV, the LCA was lacking as described in a previous radiological study<sup>[4]</sup>. The patterns of the IMA are shown in Figure 3. The majority of patients were classified with either type I [ $n = 68$  (44.2%)] or type II [ $n = 54$  (35.1%)]; 26 (16.9%) of them had the common bifurcation of the IMA (type III), and a small number of patients [ $n = 6$  (3.9%)] lacked the LCA (type IV).

### **IMA perfusion region and collateral circulation**

We also observed the arterial perfusion region of the IMA by angiography (Figure 4). In all cases, perfusion from the IMA to the distal region reached the middle of the

**Table 1** General characteristics and inferior mesenteric artery characteristics

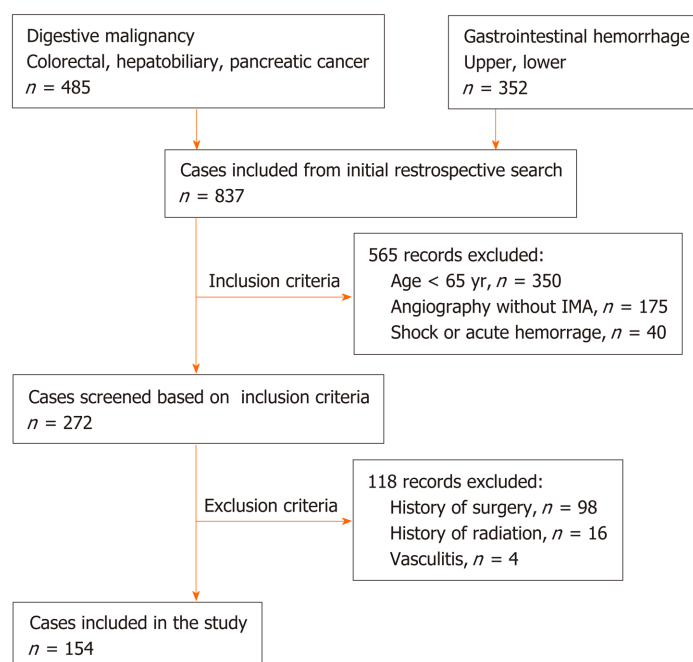
	Number	Percent (%)
Sex		
Male	94	61.0
Female	60	39.0
Age, yr	72.5 ± 5.5	
BMI, kg/m <sup>2</sup>	23.49 ± 3.31	
Comorbidity		
CHD	34	22.1
ICVD	11	7.1
ASO	4	2.6
T2DM	14	9.1
IMA diameter (mm)	3.4 ± 0.5	
IMA trunk length (cm)	3.7 ± 1.5	
Type of LCA bifurcation		
Type I	68	44.2
Type II	54	35.1
Type III	26	16.9
Type IV	6	3.9
Marginal artery		
Integrity	80	51.9
Impaired integrity	74	48.1
aLCA and arc of Riolan		
Existence	38	24.7
Inexistence	116	75.3
IMA or its branches lesion		
Existence	25	16.2
Inexistence	129	83.8
IMA perfusion region		
ASF	50	32.5
ATC	104	67.5

IMA: Inferior mesenteric artery; CHD: Coronary heart disease; ICVD: Ischemic cerebrovascular disease; ASO: Arteriosclerotic obliteration of lower limb; T2DM: Type 2 diabetes mellitus; aLCA: Ascending left colic artery; ASF: Inferior mesenteric artery perfuse only achieves splenic flexure or lower; ATC: Inferior mesenteric artery perfusion achieves to the transverse colon.

rectum, and arterial perfusion to the proximal region exceeded the splenic flexure and reached the transverse colon in 104 (67.5%) cases (Figure 4A). However, in 50 (32.5%) patients, perfusion terminated at the splenic flexure (Figure 4B) and supplied only the descending colon (Figure 4C and D). The interruption of hemoperfusion in the area of the splenic flexure of the colon through the connection of the left branch of the middle colonic artery and the ascending branch of the LCA is known as Griffiths' critical point, which demonstrates that the integrity of the marginal artery is impaired; this occurred in 74 (48.1%) of the elderly patients in our study.

The collateral circulation existed in the colonic perfusion region, including the marginal artery (Drummond's artery), the ascending branch of the LCA (aLCA) to supply the transverse colon, and the other thick, tortuous arterial arch (arc of Riolan), which may connect the mesenteric collateral channels, with a frequency of 100%, 22.7%, and 1.9%, respectively (Figure 5). When the marginal artery or the aLCA was involved as a bypass during mesenteric occlusion, it became grossly enlarged. There were 2 cases of mesenteric artery trunk occlusion, including 1 in the SMA and 1 in the IMA. The arc of Riolan and Drummond's artery compensated in the case of SMA occlusion (Figure 5B), and the aLCA and Drummond's artery compensated for IMA occlusion (Figure 5C).

To determine which clinical features or IMA characteristics would be associated with the hemoperfusion region of the IMA, univariate and multivariate regression analyses were performed. The results showed that the integrity of the marginal artery and compensation of the collateral circulation, such as the aLCA and the arc of Riolan,



**Figure 1** Flow chart summarizing patient enrollment.

were independently associated with the hemoperfusion region of the IMA. The collateral circulation could increase the region of IMA perfusion; however, the presence of the impaired integrity of the marginal artery decreased the IMA perfusion region, only supplying areas lower than the splenic flexure. In addition, the type IV IMA pattern could be a negative factor for IMA hemoperfusion, with a *P* value equal to 0.05. Meanwhile, the univariate analysis also revealed that the presence of IMA atherosclerotic lesions or comorbidity of atherosclerosis could be negative factors for IMA hemoperfusion, with a *P* value less than 0.05 (Table 2).

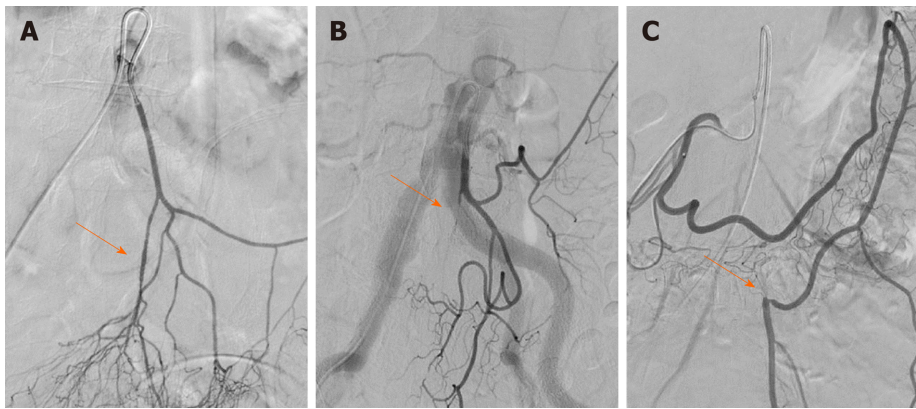
## DISCUSSION

Anastomotic healing is an important issue in CRC surgery and could be influenced by many factors, including the ligation level of the IMA, continuity of marginal vessels, presence of atherosclerotic lesions in the mesenteric artery, and exertion of mesenteric tension on the site of anastomosis in the operative process<sup>[5]</sup>. Anastomotic ischemia is believed to be one of the major reasons and risks for the development of anastomotic leakage<sup>[6,7]</sup>. Hence, it is very important to identify variations in the IMA to ensure adequate anastomotic perfusion during left-sided colorectal operations. On the other hand, atherosclerotic diseases may also affect visceral arteries in elderly patients, such as the IMA and its branches, but no related studies have focused on evaluating the conditions of the IMA in elderly patients.

Importantly, there are two methods to divide and ligate the IMA during surgery for left-sided CRC: Ligating the IMA proximal to the origin of the LCA (high ligation); and performing ligation distal to the origin of the LCA (low ligation)<sup>[8]</sup>. To date, the region of lymphadenectomy and the frequency of anastomotic leakage in the two techniques remain controversial<sup>[9]</sup>. In high ligation, the left colon becomes more mobile and more lymph nodes are dissected<sup>[10]</sup>, whereas in low ligation, possible ischemia in the proximal colon is avoided<sup>[11]</sup>. However, some studies have reported that high ligation of the IMA does not increase the frequency of anastomotic leakage<sup>[12]</sup>. Hence, understanding the anatomy and applying appropriate techniques are of instructive significance for improving the quality of surgery and the outcomes.

First, we evaluated the variations in IMA branching. In the majority of cases, the IMA was classified as type I or II (79.3%). These results are consistent with the previous results of 3D-CT angiography, which revealed frequencies of types I, II, III, and IV of 41% to 47%, 9% to 20%, 27% to 44%, and 5% to 6%, respectively<sup>[4,13]</sup>. As an anatomical variation, the low ligation procedure should theoretically correspond to the IMA pattern at different levels and the branches<sup>[14]</sup>. The LCA can easily be preserved in standard type I patients, with the ligation level below the LCA and



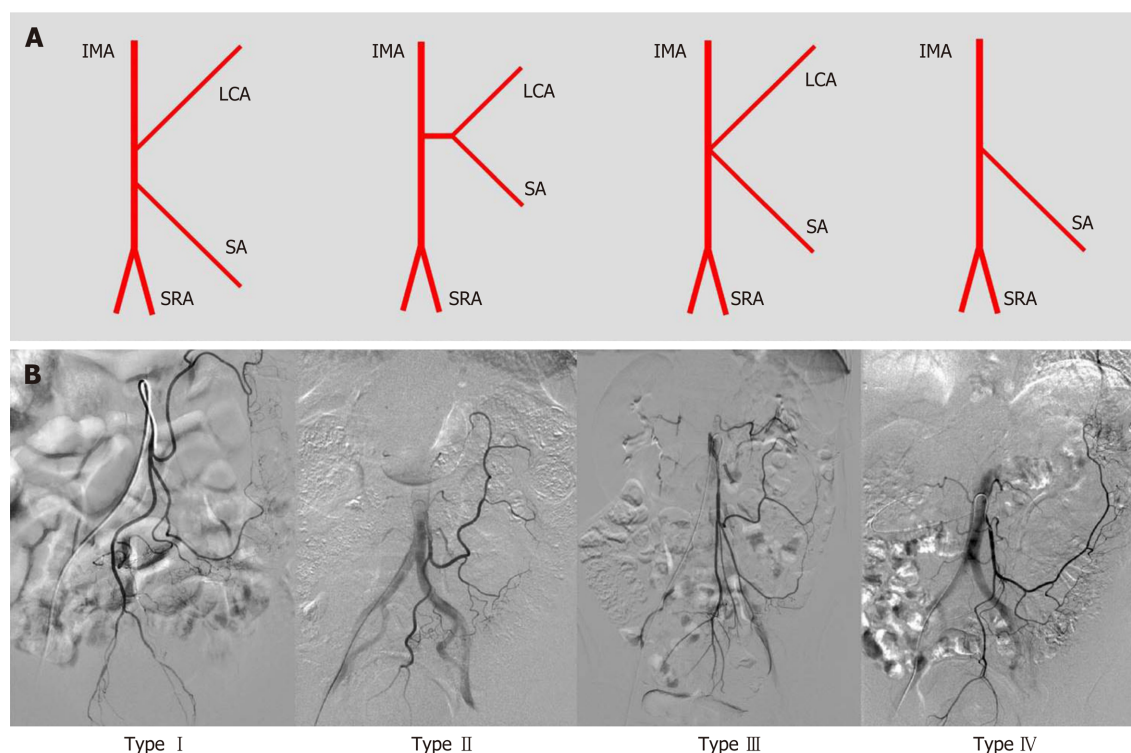


**Figure 2** Demonstration of lesions in the inferior mesenteric artery and branches of the inferior mesenteric artery on digital subtraction angiography. The arrows represent the lesion sites including stenosis and occlusion. A: Superior rectal artery stenosis with plaque; B: Superior rectal artery occlusion; C: Inferior mesenteric artery trunk occlusion. The distal blood supply came from left colic artery compensation for the superior mesenteric artery.

above the SA. However, in type II patients, the vessels of the sigmoid colon are very likely to remain with retention of the LCA. Surgeons should pay more attention to hemostasis during dissection of the sigmoid colon. In type III patients, low ligation is relatively difficult, and for branch ligation, it is necessary to separate the IMA bifurcation carefully to clearly expose the LCA, SA, and even SRA. Patients suspected of having type IV variation should undergo an adequate preoperative imaging evaluation, such as by 3D-CT angiography, to determine the existence of the LCA. Excessive separation of the IMA to search for the LCA among the vessels of the left colon may cause entry of the wrong plane and lead to injury of the gonadal vessels or even the ureter.

Ensuring the best colonic perfusion remains a concern to surgeons<sup>[15,16]</sup>. The purpose of our study was to reveal the arterial characteristics of elderly patients and determine an anatomical basis for the surgical strategy in terms of the process of IMA ligation. Although multiple techniques have been used for evaluating the perfusion of the left colorectum, including angiography<sup>[17]</sup>, laparoscopic ultrasonography<sup>[18]</sup>, and ICG fluorescence-assisted navigation<sup>[19]</sup>, only angiography can demonstrate the perfusion region of the whole colorectum, the flow direction, and the collateral arteries directly, without requiring extra time during the operation. Indeed, in our study, the hemoperfusion region of the IMA was observed. Interestingly, the range of IMA perfusion also varied, but in most cases (67.5%), the IMA could supply beyond the splenic flexure to the transverse colon, even reaching the hepatic flexure in some cases. However, in 32.5% of cases, the hemoperfusion of the IMA split at or below the splenic flexure. Based on the univariate and multivariate regression analyses in this study, the integrity of the marginal artery, collateral compensation, type IV IMA pattern, IMA atherosclerotic lesion, and history of atherosclerosis could be independently associated with hemoperfusion of the left-sided colorectum.

Generally, this phenomenon is interrupted when the LCA bifurcates at Griffith's point, which is located at the splenic flexure, where the left branch of the middle colic artery meets the aLCA. This area receives poor hemoperfusion, and it is susceptible to damage and ischemia in radical resection of left-sided CRC. A previous study has reported that if the marginal artery is deficient at Griffith's point, over-dissection and freeing of the proximal limb could result in anastomotic ischemia<sup>[20]</sup>. Our study also revealed that the hemoperfusion of the IMA only reached the descending colon, with an incomplete marginal artery at Griffith's point. For this reason, considerable care must be taken not to disrupt the bifurcation of the LCA that replaces the function of the marginal artery in this area<sup>[21]</sup>. Collateral compensation could be a protective factor against proximal limb hemoperfusion. Three different types of collateral vessels were discerned<sup>[22]</sup>: Drummond's artery, the aLCA, and the arc of Riolan. The marginal artery of the colon runs along the descending colon, with a prevalence of 100%. However, the other two run close to the center of the mesentery: The aLCA, representing the left arm of the SMA-IMA connection, is reported to be present in 63% to 100% of patients<sup>[23]</sup>. Nevertheless, in our study, the aLCA was present in only 24.7% of the 154 elderly patients because the aLCA was counted only when forming an arch with the Drummond's artery at the distal transverse colon. The arc of Riolan is supposedly a thick, tortuous, uniform vessel connecting the proximal segments of the middle colic artery and LCA, representing the central point of anastomosis<sup>[24]</sup>. It can be distinguished from a normal aLCA because while this vessel is not tortuous, it runs



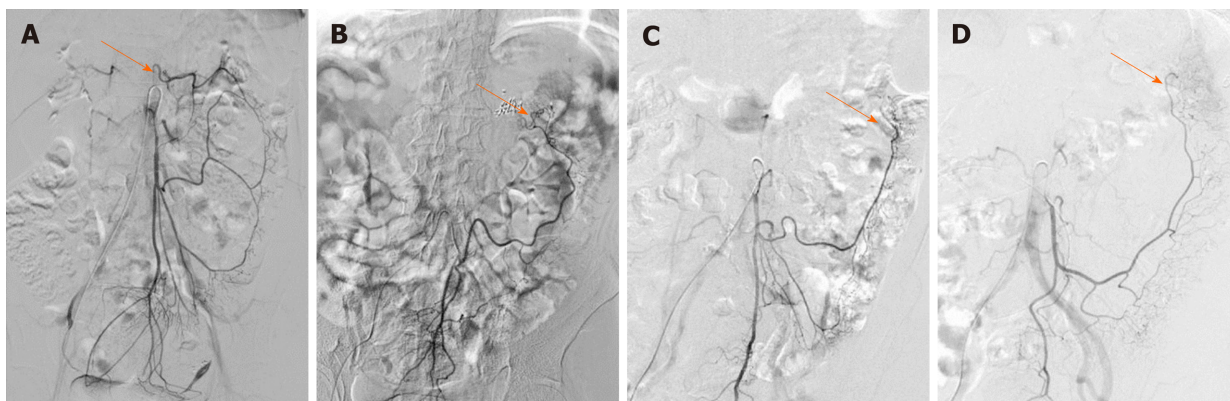**Figure 3 Patterns of inferior mesenteric artery bifurcation.** A: Illustration of the bifurcation of the inferior mesenteric artery (IMA) [only one sigmoid artery (SA) was showed in the illustration of IMA branches]. Type I: The LCA arose independently from IMA; type II: The LCA and SA arose from the IMA at the same point; type III: The LCA, SA, and SRA were branched from a common trunk from the IMA; and type IV: LCA was lacking; B: Angiography of the bifurcation of the IMA. IMA: Inferior mesenteric artery; SRA: Superior rectal artery; LCA: Left colic artery; SA: Sigmoid artery.

along the descending colon and is rarely visualized by angiography.

However, IMA lesions, history of arteriosclerosis, and IMA pattern (absence of the LCA) were still identified as being associated with the hemoperfusion of the left colon based on univariate regression analysis. A previous study<sup>[25]</sup> reported that the existence of plaque increased with age, and the prevalence of plaque in the IMA was approximately 7% in all age groups; in our study, this value was 16.2% in elderly patients. Furthermore, more lesions emerged at bifurcations, such as at the opening of the IMA and SRA. Similar to the carotid and lower limb arteries, bifurcations facilitate turbulence and plaque formation, inducing stenosis or occlusion<sup>[26,27]</sup>. On angiography in our study, the lesions could be a risk factor for poor hemoperfusion of the left-side colon. Similarly, in one case report, an abnormally dilated ex-collateral artery induced colic ischemia with an imbalance in the blood flow after sigmoid colectomy<sup>[28]</sup>. When the colic ischemia is chronic, the ischemic colitis occurs. Ischemic colitis is most commonly caused by insulting to the small vessels supplying the colon, including atherosclerosis and complication of vascular and bowel surgeries. The risk factors for ischemic colitis included age greater than 60, diabetes, hypertension, atherosclerosis, and other factors<sup>[29]</sup>. Regarding the prevalence of ischemic colitis for the anatomic considerations, the left part of the colon seems to be more affected by ischemic colitis in 75%-80% of cases because of the incomplete vascular anastomosis at Griffith's point as above mentioned, which could just demonstrate the correlation between such changes and the vessel characteristics<sup>[30,31]</sup>.

The present study had some inherent limitations. Angiography could show only the anteroposterior plane of the region, and no Dyna-CT reconstruction was performed because it is difficult for elderly patients to cooperate with holding abdominal respiration. Alternatively, 3D-CT angiography could also provide helpful information, including length, branching, pattern, and the surrounding position of the IMA, to determine the optimal ligation level of the IMA in laparoscopic radical resection of left-sided CRC, which can precisely estimate the difficulties of the surgery and make the individual surgical strategy<sup>[4,13]</sup>. Moreover, because this study was not a randomized controlled study of left-sided CRC, it is difficult to determine the advantages and reveal the significance of presurgical angiography of the IMA, such as shortened operative time and reduced blood loss; additionally, anastomotic hemoperfusion after colectomy was not presented.

In conclusion, the IMA and its branches are prone to arteriosclerosis, as are the



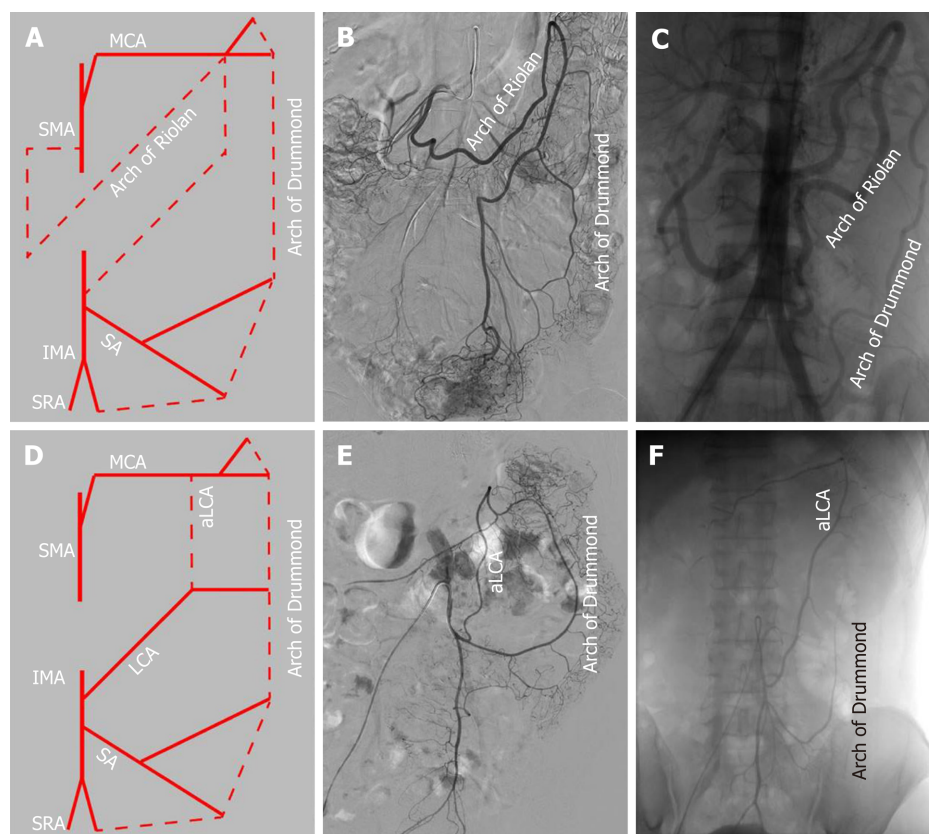
**Figure 4 Demonstration of the colonic hemoperfusion region by angiography of the inferior mesenteric artery.** The arrows represent the inferior mesenteric artery (IMA) perfusion to the proximal region of the colon. A: IMA perfusion exceeded the splenic flexure and reached the transverse colon; B: IMA perfusion only achieved the splenic flexure and stopped; C: IMA perfusion reached only the descending colon with the left colic artery; D: IMA perfusion reached only the descending colon without the left colic artery.

carotid and coronary arteries, in the elderly population. We concluded that IMA perfusion may be interrupted at the splenic flexure, the risk for which is increased with an incomplete marginal artery, the lack of other collateral arteries, and other factors. The applicability and precision of preoperative angiography for identification of the IMA branching pattern and perfusion region could mitigate the difficulties of the surgery and lead to individualized surgical strategies for elderly CRC patients.

**Table 2** Univariate and multivariate analyses of inferior mesenteric artery hemoperfusion region with clinical features

	ATC	ASF	Univariate analysis		Multivariate analysis		
	<i>n</i> = 104	<i>n</i> = 50	<i>t</i> / <sup>2</sup> value	<i>P</i> value	95%CI	OR	<i>P</i> value
Age, mean ± SD, yr	71.92 ± 5.41	73.8 ± 5.57	0.35	0.73	-		
Gender, male <i>vs</i> female, ratio	1.36	2.12	1.51	0.219	-		
BMI, mean ± SD, kg/m <sup>2</sup>	23.17 ± 3.19	24.15 ± 3.55	1.73	0.09	-		
Comorbidity of atherosclerosis, <i>n</i> (%)	22 (21.2)	18 (36)	3.87	0.049	0.331-5.980	1.407	0.643
Comorbidity of diabetes, <i>n</i> (%)	8 (7.7)	6 (12)	0.76	0.384	-		
IMA diameter, mean ± SD, mm	3.40 ± 0.57	3.35 ± 0.46	-0.51	0.61	-		
IMA lesion, <i>n</i> (%)	13 (12.5)	12 (24)	3.28	0.036	0.228-7.553	1.314	0.76
Type IV of IMA pattern, <i>n</i> (%)	2 (1.9)	4 (8)	3.93	0.051	0.001-1.051	0.038	0.054
Impaired integrity of marginal artery, <i>n</i> (%)	28 (26.9)	46 (92)	57.29	< 0.001	0.001-0.029	0.006	< 0.001
Existence of aLCA and arc of Riolan	36 (34.6)	2 (4)	17.03	< 0.001	14.823-457.702	82.368	< 0.001

ASF: Inferior mesenteric artery perfuse only achieves splenic flexure or lower; ATC: Inferior mesenteric artery perfusion achieves to the transverse colon; aLCA: Ascending left colic artery.



**Figure 5** Patterns of the arterial arch connecting the superior mesenteric artery and inferior mesenteric artery, including the arc of Riolan (meandering mesenteric artery), Drummond's artery (marginal artery), and ascending left colic artery. A: Illustration of the arc of Riolan and Drummond's artery; B: Angiography of IMA trunk occlusion with the arc of Riolan and Drummond's artery; C: Angiography of SMA trunk occlusion with an abnormally enlarged arc of Riolan and Drummond's artery; D: Illustration of the aLCA; E: Angiography of the normal Drummond artery with the aLCA to the transverse colon; F: Angiography of the aLCA with an incomplete Drummond artery. IMA: Inferior mesenteric artery; SMA: Superior mesenteric artery; SRA: Superior rectal artery; SA: Sigmoid artery; LCA: Left colic artery; aLCA: Ascending left colic artery; MCA: middle colic artery.

## ARTICLE HIGHLIGHTS

### Research background

Laparoscopic surgery has made it possible for elderly colorectal cancer (CRC) patients to undergo surgical treatment and has become a standard procedure around the world. Handling of the inferior mesenteric artery (IMA) and vein is important in low anterior resection and



abdominoperineal excision for radical resection of left-sided CRC. The IMA characteristics and the hemoperfusion region have become one of the important issues related to the anastomotic complication and the outcome of CRC resection in elderly patients. However, the characteristics, bifurcation, and distribution and the hemoperfusion region of the IMA remain unclear in elderly patients

### Research motivation

We demonstrated the characteristics, bifurcation, and distribution of the IMA and termination of the anastomotic perfusion of the left colon and rectum in elderly patients.

### Research objectives

To retrospectively analyze the clinical and IMA angiographic characteristics of 154 patients over 65 years using digital subtraction angiography.

### Research methods

We enrolled 154 patients (> 65 years old) who underwent digital subtraction angiography of the IMA. The clinical characteristics, bifurcation, and distribution of the IMA and termination of the anastomotic perfusion of the left colon and rectum were examined. Perfusion regions were cross-referenced with clinical and anatomical features.

### Research results

Of 154 patients, 25 (16.2%) had IMA lesions. The left colic artery arose independently from the IMA in 44.2% of patients, shared a trunk with the sigmoid artery in 35.1%, shared an opening with the sigmoid and superior rectal arteries in 16.9%, and was absent in 5.1%. The IMA perfusion region stopped at the splenic flexure in 50 (32.5%) patients. Collateral circulation other than the marginal artery, including the ascending left colic artery and the arc of Rioloan, appeared in 38 patients. The inferior mesenteric artery perfusion region was independently associated with the IMA atherosclerotic lesion, branching pattern, collateral circulation, and marginal artery integrity.

### Research conclusions

The IMA and its branches are prone to arteriosclerosis in the elderly population. IMA perfusion may be interrupted at the splenic flexure, the risk for which is increased with an incomplete marginal artery, the lack of other collateral arteries, and the comorbidity of atherosclerosis.

### Research perspectives

The applicability and precision of preoperative angiography for the IMA branching and perfusion patterns could facilitate geriatric laparoscopic surgery, especially for the elderly left-sided colorectal cancer patients who are suspected with poor IMA perfusion.

## REFERENCES

- 1 **Audisio RA**, Papamichael D. Treatment of colorectal cancer in older patients. *Nat Rev Gastroenterol Hepatol* 2012; **9**: 716-725 [PMID: 23045000 DOI: 10.1038/nrgastro.2012.196]
- 2 **Hasegawa H**, Kitagawa D, Shibahara K, Funahashi S, Kitamura M. [Study of the Treatment for Colorectal Cancer(CRC)in Elderly People Aged 80 Years or Older]. *Gan To Kagaku Ryoho* 2019; **46**: 742-744 [PMID: 31164521]
- 3 **Cassidy J**, Saltz LB, Giantonio BJ, Kabbinavar FF, Hurwitz HI, Rohr UP. Effect of bevacizumab in older patients with metastatic colorectal cancer: pooled analysis of four randomized studies. *J Cancer Res Clin Oncol* 2010; **136**: 737-743 [PMID: 19904559 DOI: 10.1007/s00432-009-0712-3]
- 4 **Murono K**, Kawai K, Kazama S, Ishihara S, Yamaguchi H, Sunami E, Kitayama J, Watanabe T. Anatomy of the inferior mesenteric artery evaluated using 3-dimensional CT angiography. *Dis Colon Rectum* 2015; **58**: 214-219 [PMID: 25585080 DOI: 10.1097/DCR.0000000000000285]
- 5 **McDermott FD**, Heeney A, Kelly ME, Steele RJ, Carlson GL, Winter DC. Systematic review of preoperative, intraoperative and postoperative risk factors for colorectal anastomotic leaks. *Br J Surg* 2015; **102**: 462-479 [PMID: 25703524 DOI: 10.1002/bjs.9697]
- 6 **Cirocchi R**, Trastulli S, Farinella E, Desiderio J, Listorti C, Parisi A, Noya G, Boselli C. Is inferior mesenteric artery ligation during sigmoid colectomy for diverticular disease associated with increased anastomotic leakage? A meta-analysis of randomized and non-randomized clinical trials. *Colorectal Dis* 2012; **14**: e521-e529 [PMID: 22632654 DOI: 10.1111/j.1463-1318.2012.03103.x]
- 7 **Zeng J**, Su G. High ligation of the inferior mesenteric artery during sigmoid colon and rectal cancer surgery increases the risk of anastomotic leakage: a meta-analysis. *World J Surg Oncol* 2018; **16**: 157 [PMID: 30071856 DOI: 10.1186/s12957-018-1458-7]
- 8 **Corder AP**, Karanjia ND, Williams JD, Heald RJ. Flush aortic tie versus selective preservation of the ascending left colic artery in low anterior resection for rectal carcinoma. *Br J Surg* 1992; **79**: 680-682 [PMID: 1643485 DOI: 10.1002/bjs.1800790730]
- 9 **Hida J**, Okuno K. High ligation of the inferior mesenteric artery in rectal cancer surgery. *Surg Today* 2013; **43**: 8-19 [PMID: 23052748 DOI: 10.1007/s00595-012-0359-6]
- 10 **Bonnet S**, Berger A, Hentati N, Abid B, Chevallier JM, Wind P, Delmas V, Douard R. High tie versus low tie vascular ligation of the inferior mesenteric artery in colorectal cancer surgery: impact on the gain in colon length and implications on the feasibility of anastomoses. *Dis Colon Rectum* 2012; **55**: 515-521 [PMID: 22513429 DOI: 10.1097/DCR.0b013e318246f1a2]
- 11 **Park MG**, Hur H, Min BS, Lee KY, Kim NK. Colonic ischemia following surgery for sigmoid colon and rectal cancer: a study of 10 cases and a review of the literature. *Int J Colorectal Dis* 2012; **27**: 671-675 [PMID: 22124677 DOI: 10.1007/s00384-011-1372-8]



- 12 Rutegård M, Hemmingsson O, Matthiessen P, Rutegård J. High tie in anterior resection for rectal cancer confers no increased risk of anastomotic leakage. *Br J Surg* 2012; **99**: 127-132 [PMID: 22038493 DOI: 10.1002/bjs.7712]
- 13 Ke J, Cai J, Wen X, Wu X, He Z, Zou Y, Qiu J, He X, He X, Lian L, Wu X, Zhou Z, Lan P. Anatomic variations of inferior mesenteric artery and left colic artery evaluated by 3-dimensional CT angiography: Insights into rectal cancer surgery - A retrospective observational study. *Int J Surg* 2017; **41**: 106-111 [PMID: 28323157 DOI: 10.1016/j.ijsu.2017.03.012]
- 14 Zhou J, Zhang S, Huang J, Huang P, Peng S, Lin J, Li T, Wang J, Huang M. [Accurate low ligation of inferior mesenteric artery and root lymph node dissection according to different vascular typing in laparoscopic radical resection of rectal cancer]. *Zhonghua Wei Chang Wai Ke Za Zhi* 2018; **21**: 46-52 [PMID: 29354899]
- 15 Cirocchi R, Trastulli S, Farinella E, Desiderio J, Vettoretto N, Parisi A, Boselli C, Noya G. High tie versus low tie of the inferior mesenteric artery in colorectal cancer: a RCT is needed. *Surg Oncol* 2012; **21**: e111-e123 [PMID: 22770982 DOI: 10.1016/j.suronc.2012.04.004]
- 16 Yang Y, Wang G, He J, Zhang J, Xi J, Wang F. High tie versus low tie of the inferior mesenteric artery in colorectal cancer: A meta-analysis. *Int J Surg* 2018; **52**: 20-24 [PMID: 29432970 DOI: 10.1016/j.ijsu.2017.12.030]
- 17 Allison AS, Bloor C, Faux W, Arumugam P, Widdison A, Lloyd-Davies E, Maskell G. The angiographic anatomy of the small arteries and their collaterals in colorectal resections: some insights into anastomotic perfusion. *Ann Surg* 2010; **251**: 1092-1097 [PMID: 20485132 DOI: 10.1097/SLA.0b013e3181deb649]
- 18 Sadakari Y, Nagai S, Velasquez VV, Nagayoshi K, Fujita H, Ohuchida K, Manabe T, Ohtsuka T, Nakamura M. Application of ultrasonography to high-tie and low-tie vascular ligation of the inferior mesenteric artery in laparoscopic colorectal cancer surgery: technical notes. *Surg Endosc* 2019; **33**: 309-314 [PMID: 29943055 DOI: 10.1007/s00464-018-6302-1]
- 19 Gröne J, Koch D, Kreis ME. Impact of intraoperative microperfusion assessment with Pinpoint Perfusion Imaging on surgical management of laparoscopic low rectal and anorectal anastomoses. *Colorectal Dis* 2015; **17** Suppl 3: 22-28 [PMID: 26394739 DOI: 10.1111/codi.13031]
- 20 Lin PH, Chaikof EL. Embryology, anatomy, and surgical exposure of the great abdominal vessels. *Surg Clin North Am* 2000; **80**: 417-433, xiv [PMID: 10685160 DOI: 10.1016/s0039-6109(05)70413-8]
- 21 Al-Asari SF, Lim D, Min BS, Kim NK. The relation between inferior mesenteric vein ligation and collateral vessels to splenic flexure: anatomical landmarks, technical precautions and clinical significance. *Yonsei Med J* 2013; **54**: 1484-1490 [PMID: 24142655 DOI: 10.3349/ymj.2013.54.6.1484]
- 22 Renner K, Ausch C, Rosen HR, Perik E, Hochwarter G, Schiessel R, Firbas W. [Collateral circulation of the left colon: historic considerations and actual clinical significance]. *Chirurg* 2003; **74**: 575-578 [PMID: 12883808 DOI: 10.1007/s00104-003-0634-6]
- 23 Predescu D, Popa B, Gheorghe M, Predescu I, Jinescu G, Boeriu M, Constantinou S. The vascularization pattern of the colon and surgical decision in esophageal reconstruction with colon. A selective SMA and IMA arteriographic study. *Chirurgia (Bucur)* 2013; **108**: 161-171 [PMID: 23618563]
- 24 Lange JF, Komen N, Akkerman G, Nout E, Horstmannshoff H, Schlesinger F, Bonjer J, Kleinrensink GJ. Riolan's arch: confusing, misnomer, and obsolete. A literature survey of the connection(s) between the superior and inferior mesenteric arteries. *Am J Surg* 2007; **193**: 742-748 [PMID: 17512289 DOI: 10.1016/j.amjsurg.2006.10.022]
- 25 Güneç Beşer C, Karcaaltıncaba M, Çelik HH, Başar R. The prevalence and distribution of the atherosclerotic plaques in the abdominal aorta and its branches. *Folia Morphol (Warsz)* 2016; **75**: 364-375 [PMID: 26821603 DOI: 10.5603/FM.a2016.0005]
- 26 DeBaakey ME, Glaeser DH. Patterns of atherosclerosis: effect of risk factors on recurrence and survival-analysis of 11,890 cases with more than 25-year follow-up. *Am J Cardiol* 2000; **85**: 1045-1053 [PMID: 10781750 DOI: 10.1016/s0002-9149(00)00694-9]
- 27 Alimohammadi M, Pichardo-Almaraz C, Agu O, Díaz-Zuccarini V. A multiscale modelling approach to understand atherosclerosis formation: A patient-specific case study in the aortic bifurcation. *Proc Inst Mech Eng H* 2017; **231**: 378-390 [PMID: 28427316 DOI: 10.1177/0954411917697356]
- 28 Ikeda A, Takahashi H, Miyoshi N, Haraguchi N, Hata T, Matsuda C, Yamamoto H, Mizushima T, Doki Y, Mori M. Colonic ischemia developed after laparoscopic colectomy for rectosigmoid cancer with focal infrarenal aortic stenosis. *Asian J Endosc Surg* 2018; **11**: 270-273 [PMID: 29316285 DOI: 10.1111/ases.12455]
- 29 Park CJ, Jang MK, Shin WG, Kim HS, Kim HS, Lee KS, Lee JY, Kim KH, Park JY, Lee JH, Kim HY, Nam ES, Yoo JY. Can we predict the development of ischemic colitis among patients with lower abdominal pain? *Dis Colon Rectum* 2007; **50**: 232-238 [PMID: 17164969 DOI: 10.1007/s10350-006-0753-5]
- 30 Glauser PM, Wermuth P, Cathomas G, Kuhnt E, Käser SA, Maurer CA. Ischemic colitis: clinical presentation, localization in relation to risk factors, and long-term results. *World J Surg* 2011; **35**: 2549-2554 [PMID: 21882031 DOI: 10.1007/s00268-011-1205-5]
- 31 Douberis M, Panagopoulos P, Scherz S, Dellaporta E, Kouklakis G. Update on ischemic colitis: from etiopathology to treatment including patients of intensive care unit. *Scand J Gastroenterol* 2016; **51**: 893-902 [PMID: 27152750 DOI: 10.3109/00365521.2016.1162325]



Published by Baishideng Publishing Group Inc  
7041 Koll Center Parkway, Suite 160, Pleasanton, CA 94566, USA  
Telephone: +1-925-3991568  
E-mail: [bpgoffice@wjgnet.com](mailto:bpgoffice@wjgnet.com)  
Help Desk: <http://www.f6publishing.com/helpdesk>  
<http://www.wjgnet.com>

