

World Journal of *Clinical Cases*

World J Clin Cases 2020 August 26; 8(16): 3377-3620



OPINION REVIEW

- 3377** Novel computerized psychometric tests as primary screening tools for the diagnosis of minimal hepatic encephalopathy
Luo M, Mu R, Liu JF, Bai FH

REVIEW

- 3390** Management of cancer patients during COVID-19 pandemic at developing countries
González-Montero J, Valenzuela G, Ahumada M, Barajas O, Villanueva L

MINIREVIEWS

- 3405** Liver in the limelight in the corona (COVID-19) time
Chela HK, Pasha SB, Basar O, Daglilar E, Tahan V
- 3411** Steroid-responsive pancreatitis
Pelaez-Luna M, Soriano-Rios A, Lira-Treviño AC, Uscanga-Domínguez L

ORIGINAL ARTICLE

Clinical and Translational Research

- 3431** Application of molybdenum target X-ray photography in imaging analysis of caudal intervertebral disc degeneration in rats
Su QH, Zhang Y, Shen B, Li YC, Tan J
- 3440** Accuracy study of a binocular-stereo-vision-based navigation robot for minimally invasive interventional procedures
Wang R, Han Y, Luo MZ, Wang NK, Sun WW, Wang SC, Zhang HD, Lu LJ

Retrospective Study

- 3450** Value of virtual bronchoscopic navigation and transbronchial ultrasound-guided sheath-guided exploration in diagnosis of peripheral lung cancer
Liu Y, Wang F, Zhang QC, Tong ZH
- 3458** Significance of serum fibroblast growth factor-23 and miR-208b in pathogenesis of atrial fibrillation and their relationship with prognosis
Chen JM, Zhong YT, Tu C, Lan J
- 3465** Home quarantine compliance is low in children with fever during COVID-19 epidemic
Lou Q, Su DQ, Wang SQ, Gao E, Li LQ, Zhuo ZQ

- 3474** Combination of endoscopic submucosal dissection and laparoscopic sentinel lymph node dissection in early mucinous gastric cancer: Role of lymph node metastasis

Li H, Zhao LL, Zhang XC, Liu DX, Wang GY, Huo ZB, Chen SB

- 3483** Factors affecting failed trial of labor and countermeasures: A retrospective analysis

Wang JG, Sun JL, Shen J

- 3493** Value of miR-1271 and glypican-3 in evaluating the prognosis of patients with hepatocellular carcinoma after transcatheter arterial chemoembolization

Guo Z, Wang J, Li L, Liu R, Fang J, Tie B

Observational Study

- 3503** Follow-up study on symptom distress in esophageal cancer patients undergoing repeated dilation

Liu L, Liu QW, Wu XD, Liu SY, Cao HJ, Hong YT, Qin HY

- 3515** Long-term medical treatment of patients with severe burns at exposed sites

Du Y, Lv GZ, Yu S, Wang D, Tan Q

CASE REPORT

- 3527** Laparoscopic management of a giant mucinous benign ovarian mass weighing 10150 grams: A case report

Sanna E, Madeddu C, Melis L, Nemolato S, Macciò A

- 3534** Concurrent hepatocellular carcinoma metastasis to stomach, colon, and brain: A case report

Kim R, Song J, Kim SB

- 3542** Disseminated osteomyelitis after urinary tract infection in immunocompetent adult: A case report

Kim YJ, Lee JH

- 3548** Pelvic lipomatosis and renal transplantation: A case report

Zhao J, Fu YX, Feng G, Mo CB

- 3553** Intestinal obstruction in pregnancy with reverse rotation of the midgut: A case report

Zhao XY, Wang X, Li CQ, Zhang Q, He AQ, Liu G

- 3560** Clinical laboratory investigation of a patient with an extremely high D-dimer level: A case report

Sun HX, Ge H, Xu ZQ, Sheng HM

- 3567** Recovery from a biliary stricture of a common bile duct ligature injury: A case report

Fan Z, Pan JY, Zhang YW

- 3573** Spontaneous pneumomediastinum in an elderly COVID-19 patient: A case report

Kong N, Gao C, Xu MS, Xie YL, Zhou CY

- 3578** Acute generalized exanthematous pustulosis with airway mucosa involvement: A case report

Li LL, Lu YQ, Li T

- 3583** Multifocal neuroendocrine cell hyperplasia accompanied by tumorlet formation and pulmonary sclerosing pneumocytoma: A case report
Han XY, Wang YY, Wei HQ, Yang GZ, Wang J, Jia YZ, Ao WQ
- 3591** Giant benign phyllodes breast tumour with pulmonary nodule mimicking malignancy: A case report
Zhang T, Feng L, Lian J, Ren WL
- 3601** Spontaneous multivessel coronary artery spasm diagnosed with intravascular ultrasound imaging: A case report
Wu HY, Cao YW, Chang FJ, Liang L
- 3608** Delayed perforation after endoscopic resection of a colonic laterally spreading tumor: A case report and literature review
Zhou GYJ, Hu JL, Wang S, Ge N, Liu X, Wang GX, Sun SY, Guo JT
- 3616** First branchial cleft cyst accompanied by external auditory canal atresia and middle ear malformation: A case report
Zhang CL, Li CL, Chen HQ, Sun Q, Liu ZH

ABOUT COVER

Editorial board member of *World Journal of Clinical Cases*, Dr. Kvolik is a Professor in the School of Medicine, Osijek University, Croatia. She obtained her MD degree, with specialization in the field of anesthesiology, resuscitation and intensive care from the Zagreb Medical School, Croatia. Afterwards, she undertook postgraduate training in Clinical Pharmacology at the same institution, defending both a Master's thesis and PhD thesis. In 2006, she joined the Osijek University Medical Faculty as a lecturer and was promoted to Professor in 2009. In 2012, she was elected Head of the Department of Anesthesiology, Resuscitation, Intensive Care and Pain Therapy, a position she occupies to this day. She is also the current Head of the Intensive Care Unit at the Osijek University Hospital, Croatia. (L-Editor: Filipodia)

AIMS AND SCOPE

The primary aim of *World Journal of Clinical Cases* (*WJCC*, *World J Clin Cases*) is to provide scholars and readers from various fields of clinical medicine with a platform to publish high-quality clinical research articles and communicate their research findings online.

WJCC mainly publishes articles reporting research results and findings obtained in the field of clinical medicine and covering a wide range of topics, including case control studies, retrospective cohort studies, retrospective studies, clinical trials studies, observational studies, prospective studies, randomized controlled trials, randomized clinical trials, systematic reviews, meta-analysis, and case reports.

INDEXING/ABSTRACTING

The *WJCC* is now indexed in Science Citation Index Expanded (also known as SciSearch®), Journal Citation Reports/Science Edition, PubMed, and PubMed Central. The 2020 Edition of Journal Citation Reports® cites the 2019 impact factor (IF) for *WJCC* as 1.013; IF without journal self cites: 0.991; Ranking: 120 among 165 journals in medicine, general and internal; and Quartile category: Q3.

RESPONSIBLE EDITORS FOR THIS ISSUE

Production Editor: Ji-Hong Liu; Production Department Director: Xiang Li; Editorial Office Director: Jin-Lai Wang.

NAME OF JOURNAL

World Journal of Clinical Cases

ISSN

ISSN 2307-8960 (online)

LAUNCH DATE

April 16, 2013

FREQUENCY

Semimonthly

EDITORS-IN-CHIEF

Dennis A Bloomfield, Sandro Vento, Bao-Gan Peng

EDITORIAL BOARD MEMBERS

<https://www.wjgnet.com/2307-8960/editorialboard.htm>

PUBLICATION DATE

August 26, 2020

COPYRIGHT

© 2020 Baishideng Publishing Group Inc

INSTRUCTIONS TO AUTHORS

<https://www.wjgnet.com/bpg/gerinfo/204>

GUIDELINES FOR ETHICS DOCUMENTS

<https://www.wjgnet.com/bpg/GerInfo/287>

GUIDELINES FOR NON-NATIVE SPEAKERS OF ENGLISH

<https://www.wjgnet.com/bpg/gerinfo/240>

PUBLICATION ETHICS

<https://www.wjgnet.com/bpg/GerInfo/288>

PUBLICATION MISCONDUCT

<https://www.wjgnet.com/bpg/gerinfo/208>

ARTICLE PROCESSING CHARGE

<https://www.wjgnet.com/bpg/gerinfo/242>

STEPS FOR SUBMITTING MANUSCRIPTS

<https://www.wjgnet.com/bpg/GerInfo/239>

ONLINE SUBMISSION

<https://www.f6publishing.com>

Retrospective Study

Combination of endoscopic submucosal dissection and laparoscopic sentinel lymph node dissection in early mucinous gastric cancer: Role of lymph node metastasis

Hua Li, Li-Li Zhao, Xiao-Chong Zhang, Deng-Xiang Liu, Gui-Ying Wang, Zhi-Bin Huo, Shu-Bo Chen

ORCID number: Hua Li 0000-0003-2423-7689; Li-Li Zhao 0000-0001-8969-6697; Xiao-Chong Zhang 0000-0003-2476-5553; Deng-Xiang Liu 0000-0003-4047-1379; Gui-Ying Wang 0000-0001-8685-2826; Zhi-Bin Huo 0000-0003-3985-1972; Shu-Bo Chen 0000-0001-5958-4416.

Author contributions: Li H, Zhao LL, Zhang XC, and Liu DX contributed equally to this work; Huo ZB, Chen SB, and Wang GY should be regarded as co-corresponding authors of this article; Huo ZB, Chen SB, and Wang GY designed the research; Li H analyzed the data and drafted the manuscript; Zhao LL and Zhang XC revised the manuscript critically for important intellectual content and contributed to the data analysis; Liu DX helped draft the manuscript; all authors read and approved the final manuscript.

Institutional review board

statement: This study is a retrospective study for the data of patients collected from the Department of Surgical Oncology, Xing Tai People's Hospital during 1988-2016. No human body was involved in this study. According to our hospital's policy, this study does not require an approval by

Hua Li, Li-Li Zhao, Xiao-Chong Zhang, Deng-Xiang Liu, Zhi-Bin Huo, Shu-Bo Chen, Institute of Cancer Control, Xingtai People's Hospital, Xingtai 054001, Hebei Province, China

Gui-Ying Wang, Department of General Surgery, Fourth Affiliated Hospital of Hebei Medical University, Shijiazhuang 050000, Hebei Province, China

Corresponding author: Zhi-Bin Huo, PhD, Professor, Institute of Cancer Control, Xingtai People's Hospital, No. 16 Hongxing Street, Xingtai 054001, Hebei Province, China. zhibinhwcw@126.com

Abstract

BACKGROUND

Recent evidence showed that combining endoscopic submucosal dissection (ESD) and laparoscopic sentinel lymph node dissection may avoid unnecessary gastrectomy in treating early mucinous gastric cancer (EMGC) patients with risks of positive lymph node metastasis (pLNM).

AIM

To explore the predictive factors for pLNM in EMGC, and to optimize the clinical application of combining ESD and sentinel lymph node dissection in a proper subgroup of patients with EMGC.

METHODS

Thirty-one patients with EMGC who had undergone gastrectomy with lymph node dissection were consecutively enrolled from January 1988 to December 2016. Univariate and multivariate logistic regression analyses were used to estimate the association between the rates of pLNM and clinicopathological factors, providing odds ratio (OR) with 95% confidence interval. And the association between the number of predictors and the pLNM rate was also investigated.

RESULTS

Depth of invasion (OR = 7.342, 1.127-33.256, $P = 0.039$), tumor diameter (OR = 9.158, 1.348-29.133, $P = 0.044$), and lymphatic vessel involvement (OR = 27.749, 1.821-33.143, $P = 0.019$) turned out to be significant and might be the independent risk factors for predicating pLNM in the multivariate analysis. For patients with 1, 2, and 3 risk factors, the pLNM rates were 9.1%, 33.3%, and 75.0%, respectively.

the hospital institutional review board.

Informed consent statement: All study participants, or their legal guardian, provided informed written consent prior to study enrollment.

Conflict-of-interest statement: No conflict of interest is declared by the authors.

Data sharing statement: No additional data are available.

Open-Access: This article is an open-access article that was selected by an in-house editor and fully peer-reviewed by external reviewers. It is distributed in accordance with the Creative Commons Attribution NonCommercial (CC BY-NC 4.0) license, which permits others to distribute, remix, adapt, build upon this work non-commercially, and license their derivative works on different terms, provided the original work is properly cited and the use is non-commercial. See: <http://creativecommons.org/licenses/by-nc/4.0/>

Manuscript source: Unsolicited manuscript

Received: March 20, 2020

Peer-review started: March 20, 2020

First decision: April 29, 2020

Revised: July 5, 2020

Accepted: July 16, 2020

Article in press: July 16, 2020

Published online: August 26, 2020

P-Reviewer: Tanabe S

S-Editor: Zhang L

L-Editor: Wang TQ

P-Editor: Wang LL



pLNM was not detected in seven patients without any of these risk factors.

CONCLUSION

ESD might serve as a safe and sufficient treatment for intramucosal EMGC if tumor size ≤ 2 cm, and when lymphatic vessel involvement is absent by postoperative histological examination. Combining ESD and sentinel lymph node dissection could be recommended as a safe and effective treatment for EMGC patients with a potential risk of pLNM.

Key words: Endoscopic submucosal dissection; Early gastric cancer; Mucinous gastric cancer; Laparoscopic sentinel lymph node dissection

©The Author(s) 2020. Published by Baishideng Publishing Group Inc. All rights reserved.

Core tip: A combination of laparoscopic sentinel lymph node dissection (SLND) and endoscopic submucosal dissection (ESD) may avoid unnecessary surgical intervention in early mucinous gastric cancer (EMGC) patients having a potential risk of positive lymph node metastasis (pLNM). ESD allows the complete local resection of the primary tumor, and SLND enables the confirmation of lymph node status. We performed this current retrospective study to identify risk factors that are predictive factor for pLNM in EMGC and to establish a primary criterion and working flowchart to expand the possibility of using ESD and SLND for the treatment of EMGC. The combination of ESD and SLND could be recommended as an effective, minimally invasive treatment for EMGC patients with a high risk of pLNM.

Citation: Li H, Zhao LL, Zhang XC, Liu DX, Wang GY, Huo ZB, Chen SB. Combination of endoscopic submucosal dissection and laparoscopic sentinel lymph node dissection in early mucinous gastric cancer: Role of lymph node metastasis. *World J Clin Cases* 2020; 8(16): 3474-3482

URL: <https://www.wjgnet.com/2307-8960/full/v8/i16/3474.htm>

DOI: <https://dx.doi.org/10.12998/wjcc.v8.i16.3474>

INTRODUCTION

Endoscopic submucosal dissection (ESD) has been increasingly performed in the recent decade all over the world given the clinical evidence and well-accepted benefits^[1-5]. ESD is considered a standard treatment for specific early gastric cancer (EGC) with a relatively low lymph node metastasis (LNM) risk, *e.g.*, intramucosal differentiated adenocarcinoma and ≤ 2 cm in diameter with no ulcers^[6]. Meanwhile, in undifferentiated EGC with a high risk of pLNM, gastrectomy together with lymphadenectomy is usually performed as the standard surgical procedure^[7]. Undifferentiated gastric carcinoma consists of mucinous adenocarcinoma, poorly differentiated adenocarcinoma, and primary signet ring cell carcinoma^[6]. However, for approximately 96% of surgical patients with early mucinous gastric cancer (EMGC) confined to the mucosa, no pLNM was observed, suggesting that it might be over-treated for these cases^[8]. Therefore, we have proposed new methods to minimize the chance of surgical resection for EMGC. The new technique allows minimally invasive resection of gastric lesions through ESD and laparoscopic sentinel lymph node dissection (SLND)^[9-11].

Therefore, we performed this retrospective study to identify risk factors that accounted for pLNM in EMGC and to propose a primary criterion and working flowchart to optimize the indication of applying ESD and SLND in the treatment of EMGC.

MATERIALS AND METHODS

Patients

The retrospective study enrolled early gastric cancer patients who had undergone

gastrectomy with lymphadenectomy in the Department of Oncology, Xingtai People's Hospital (Xingtai, China) from January 1988 to December 2016.

The inclusion criteria were: (1) Lymphadenectomy beyond D1 dissection; (2) Number of harvested lymph nodes > 16; (3) Pathologically diagnosed with EMGC according to the Japanese Classification of Gastric Carcinoma (JCGC 4th edition)^[6,9]; and (4) Enough data for further analyses from the medical records.

After applying the inclusion criteria, a total of 31 patients with pathologically confirmed EMGC were eligible for the final analyses. There were more men than women (21 *vs* 10) in this study and the mean age was 48 years old (range from 27 to 81).

Lymph node dissection and classification

Lymph nodes were dissected from the *en bloc* specimens after ESD approach and evaluated by an experienced surgeon according to the classification released by the Japanese Classification of Gastric Carcinoma (JCGC 4th edition)^[6,9]. Afterwards, the dissected lymph nodes were sectioned and examined using the hematoxylin and eosin and immunohistochemical staining to collect the histopathologic characteristics. The presence of lymph node metastasis and lymphovascular invasion (LVI) was examined and determined by D2-40 antibody. A series of consistent measuring methods were applied to guarantee the consistency of the treatment and examination results of samples in the past 28 years. Pathological slides were double-checked by another pathologist who was blinded to previous results.

Association between clinicopathological characteristics and lymph node metastasis

We recorded and collected clinicopathological data according to the JCGC for further analyses^[6]. These features included sex (female/male), gastric cancer family history, age, depth of cancer invasion (mucosa/submucosa), macroscopic type, tumor size, lymphatic vessel involvement, presence of ulceration, anatomic location of tumor (lower 1/3, middle 1/3, or upper 1/3 of the stomach), number of tumor sites (single or multitude). Moreover, associations between pLNM and various clinicopathological features were explored.

Statistical analysis

All statistical analyses in this present study were performed using SPSS software, version 25.0 (IBM Corp, NY, United States). The chi-square test was used to estimate the association between the status of pLNM and clinicopathological characteristics. Furthermore, we used multivariate stepwise logistic regression analysis to determine the independent risk factors for pLNM, providing odds ratios and 95% confidence intervals. A *P* value < 0.05 was considered statistically significant.

RESULTS

Association between clinicopathological factors and lymph node metastasis status

The results of χ^2 test for association between pLNM and clinicopathological features are displayed in **Table 1**. There were trends that submucosal invasion, tumor diameter > 2 cm, and presence of LVI were associated with high risks of pLNM (*P* < 0.05). Meanwhile, no significant association was observed between pLNM and family history, macroscopic type, presence of ulceration, anatomic location of tumor, number of tumor sites, age, or sex.

Potential independent risk factors for positive lymph node metastasis

The univariate analysis from logistic regression showed that three clinicopathological parameters including submucosal invasion, large tumor size, and presence of LVI were significantly associated with pLNM. Moreover, the multivariate analysis confirmed that these three parameters were independent risk factors for pLNM (*P* < 0.05, **Table 2**).

Lymph node metastasis in EMGC

Seven (22.6%) of 31 patients diagnosed with EMGC had pLNM. The relationship between pLNM and the three independent risk factors (submucosal invasion, large tumor size, and LVI) was also investigated in EMGC. In EMGC, for patients with 1, 2, and 3 risk factors, pLNM rates were 9.1% (1/11), 33.3% (3/9), and 75.0% (3/4), respectively. For the other seven patients with no risk factors, no pLNM was found

Table 1 Univariate analysis of potential risk factors for positive lymph node metastasis

Factor	Lymph node metastasis	
	Positive number	P value
Age (yr)		0.839
< 60 (<i>n</i> = 19)	4	
≥ 60 (<i>n</i> = 12)	3	0.850
Sex		
Male (<i>n</i> = 21)		
Female (<i>n</i> = 10)		
Macroscopic type		
I (<i>n</i> = 2)	0	
II (<i>n</i> = 22)	6	
III (<i>n</i> = 7)	1	
Family medical history		0.904
Positive (<i>n</i> = 5)	1	
Negative (<i>n</i> = 26)	6	
Location		0.317
Upper (<i>n</i> = 3)	1	
Middle (<i>n</i> = 8)	0	
Lower (<i>n</i> = 20)	6	
Number of tumors		0.490
Single (<i>n</i> = 29)	7	
Multitude (<i>n</i> = 2)	0	
Depth of invasion		0.036
Mucosa (<i>n</i> = 22)	2	
Submucosa (<i>n</i> = 9)	5	
Tumor size in diameter		0.040
≤ 2 cm (<i>n</i> = 25)	3	
> 2 cm (<i>n</i> = 6)	4	
Lymphatic vessel involvement		0.003
Negative (<i>n</i> = 23)	1	
Positive (<i>n</i> = 8)	6	
Ulceration		0.589
Negative (<i>n</i> = 25)	5	
Positive (<i>n</i> = 6)	2	

(Figure 1).

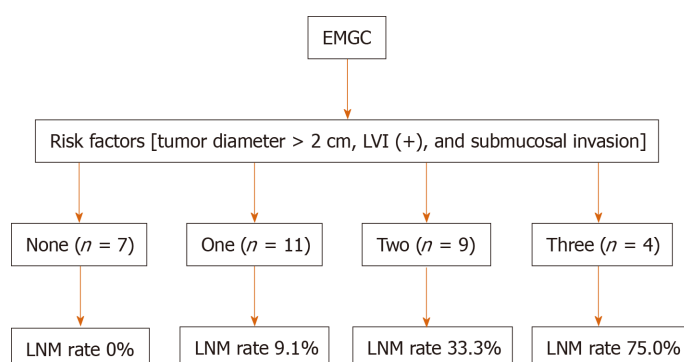
DISCUSSION

Conventional gastrectomy with lymphadenectomy has been considered a standard treatment for EGC. However, in recent two decades, mounting studies have demonstrated non-inferior long-term outcomes of ESD compared with surgical gastrectomy^[12,13]. The theoretical advantages of ESD over traditional subtotal gastrectomy are less invasiveness, less cost, and better preservation of physiological function^[14,15]. Recently, ESD is widely used as curative treatment for differentiated-type

Table 2 Multivariate analysis of potential risk factors for positive lymph node metastasis

Factor	Hazard ratio	95%CI	P value
Depth of invasion	7.342	1.127-33.256	0.039
Mucosa			
Submucosa			
Tumor size	9.158	1.348-29.133	0.044
≤ 2 cm			
> 2 cm			
Lymphatic vessel involvement	27.749	1.821-33.14	0.019
Negative			0
Positive			

CI: Confidence interval.

**Figure 1** Association between the three identified risk factors and positive lymph node metastasis in early mucinous gastric cancer.

EMGC: Early mucinous gastric cancer; LNM: Lymph node metastasis.

EGC that has less risk of LNM^[7,16]. For patients with EMGC, major surgery such as gastrectomy with SLND is usually performed even though ESD could also remove the primary gastric lesion *en bloc*. However, this kind of surgery may eventually turn out to be unnecessary for many EMGC patients, because about 96% of EMGC patients who had undergone gastrectomy were actually at a low risk of LNM. If the primary gastric tumor could be removed *en bloc* and lymph node metastasis status could be pathologically determined prior to surgery, unnecessary surgical intervention might be avoided. Combining SLND and ESD may avoid unnecessary surgical intervention in EMGC patients with a low risk of pLNM.

The prediction model or proper working flowchart to predict the status of pLNM could optimize treatment approach for EGC. In order to achieve this aim, we try to develop a possible working flowchart of expanding indication of ESD in EMGC. And we retrospectively analyzed the EMGC cases to determine whether the presence of pLNM could be predicted by clinicopathologic features. Our results suggested that several clinicopathologic features accounted for the presence of pLNM: Submucosal invasion, tumor diameter > 2 cm, and positive LVI. These results focusing on EMGC are in line with some previous researchers' reports, indicating a significant association of large tumor, positive LVI, and submucosal invasion with high pLNM risk^[12,13,17-19].

During the research, we tried to divide patients into subgroups among EMGC cases and to see if in one or more subgroups we could rule out the risk of pLNM, *i.e.*, ESD could curably treat these patients. Fortunately, from the results we found that for patients with intramucosal cancer, when tumor size ≤ 2 cm or without LVI, no pLNM had been observed, indicating that for these EMGC cases, ESD could be safely and efficaciously performed while unnecessary gastrectomy might be avoided. On top of that, the association between the three risk factors and pLNM rate was further investigated to optimize the treatment of EMGC. Interestingly, based on current results we could found that there is a strong association between pLNM risk and the

number of the three clinicopathologic factors. When there were 1, 2, and 3 risk factors, the rates of pLNM were 9.1% (1/11), 33.3% (3/9), and 75.0% (3/4), respectively. To achieve a better curative outcome, conventional gastrectomy with enough lymphadenectomy are needed in these patients with risk factors.

Combining ESD and SLND might avoid unnecessary gastrectomy in EMGC patients. ESD could ensure *en bloc* resection of the primary tumor while SLND could confirm the lymph node metastatic status^[19,20]. A sentinel node is defined as the lymph node that directly receives lymphatic drainage from the primary tumor^[21]. Thus, the sentinel node might be the first few lymph nodes affected by LNM. In order to detect the sentinel node by laparoscopic surgery, four trocar ports were prepared under general anesthesia. Gastric endoscope was then inserted through the patient's mouth to confirm the presence and location of cancer lesions. To navigate the sentinel lymph nodes, indo-cyanine green dye was injected submucosally around the cancer lesion. Next, stained lymph nodes were identified in the laparoscopic view, and basic dissection was performed. The dissected sentinel lymph nodes were then immediately sent for intra-operative frozen section evaluation. If SLND reveals positive LNM, the patient was then converted to gastrectomy with conventional lymph node dissection at this point^[22-24].

We must acknowledge several limitations in the present study. First, it was a single institutional cohort study with limited population, which might lead to information and selection bias. And the evolving standard of clinical treatment and technology in the past decades might also lead to bias. Therefore, more large-scale prospective studies are needed to verify our findings. As the study results suggest, we developed a novel working flowchart for treatment of patients with EMGC (Figure 2). ESD may be a sufficient treatment for intramucosal EMGC if tumor size ≤ 2 cm, and when LVI is absent upon postoperative histological examination. ESD allowed the complete removal of the primary gastric cancer, and SLND confirmed lymph node status in these patients. If intra-operative SLND reveals positive LNM or specimens from ESD indicates the presence of LVI, it is better to perform conventional gastrectomy with lymphadenectomy. In conclusion, combining ESD and SLND could be recommended as a safe and effective treatment for EMGC patients with a high risk of pLNM.

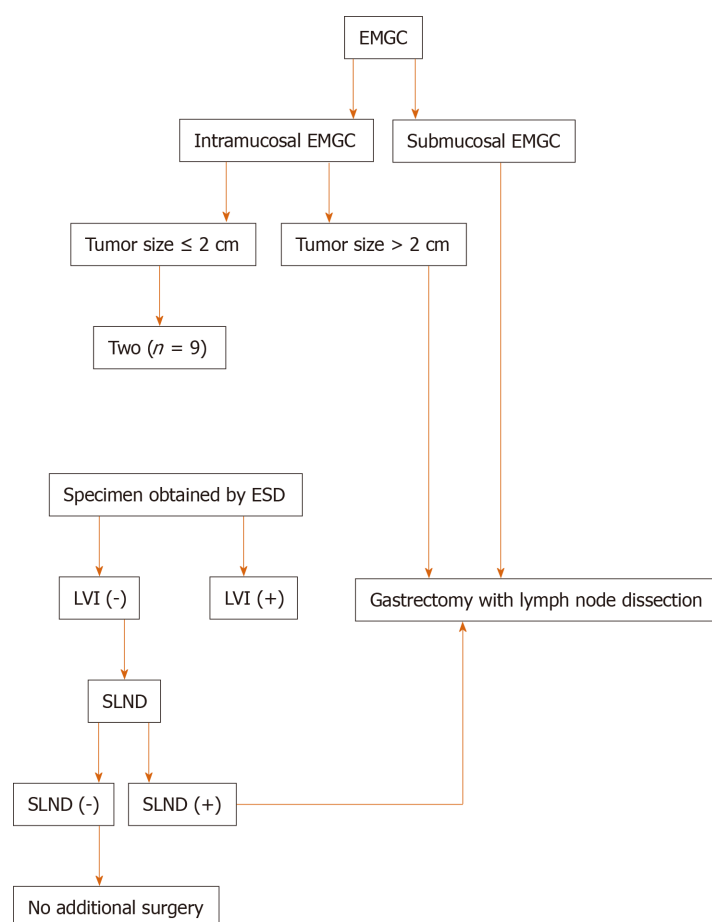


Figure 2 Flow chart of the therapeutic strategy for cases with early mucinous gastric cancer. EMGC: Early mucinous gastric cancer; LNM: Lymph node metastasis; ESD: Endoscopic submucosal dissection; SLND: Sentinel lymph node dissection.

ARTICLE HIGHLIGHTS

Research background

Endoscopic submucosal dissection (ESD) has become a standard treatment for tumors meeting the specific criteria characteristic of very low lymph node metastasis (LNM) risk: Intramucosal differentiated adenocarcinoma and ≤ 2 cm in size with no ulcers. Meanwhile, in undifferentiated early gastric cancer with a high risk of LNM, gastrectomy with lymph node dissection is usually performed as the standard surgical procedure. For undifferentiated gastric cancer, it consists of mucinous adenocarcinoma, poorly differentiated adenocarcinoma, and primary signet ring cell carcinoma. However, for approximately 96% of surgical patients with early mucinous gastric cancer (EMGC) confined to the mucosa, no LNM was observed, suggesting that it might be over-treated for these cases. Therefore, we have proposed new methods to minimize gastric resection for EMGC. The new technique allows minimally invasive resection of gastric lesions through ESD and laparoscopic sentinel lymph node dissection (SLND).

Research motivation

We attempted to identify a subgroup of EMGC patients in whom the risk of LNM can be ruled out and treated them by ESD and SLND, which may serve as a breakthrough treatment for EMGC.

Research objectives

We carried out this retrospective study to determine the clinicopathological factors that are predictive of LNM in EMGC. Furthermore, we established a simple criterion to expand the possibility of using ESD and SLND for the treatment of EMGC.

Research methods

The association between the clinicopathological factors and the presence of LNM was retrospectively analyzed by univariate and multivariate logistic regression analyses. Odds ratios (OR) with 95% confidence intervals (CIs) were calculated. We further examined the relationship between the positive number of the three significant predictive factors and the LNM rate.

Research results

Depth of invasion (OR = 7.342, 95%CI: 1.127-33.256, $P = 0.039$), the tumor diameter (OR = 9.158, 95%CI: 1.348-29.133, $P = 0.044$), and lymphatic vessel involvement (OR = 27.749, 95%CI: 1.821-33.143, $P = 0.019$) were found to be significant and independent risk factors for LNM by multivariate analysis. For patients with one, two, and three of the risk factors, the LNM rates were 9.1%, 33.3%, and 75.0% respectively. LNM were not found in seven patients without one or more of the three risk factors.

Research conclusions

ESD might be a sufficient treatment for intramucosal EMGC if tumor size ≤ 2 cm, and when LVI is absent upon postoperative histological examination. The combination of ESD and SLND could be recommended as an effective, minimally invasive treatment for EMGC patients having a potential risk of LNM.

Research perspectives

The minimalization of therapeutic invasiveness in order to preserve quality of life is a major topic in the management of early gastric cancer. One of the critical factors in choosing minimally invasive surgery for EMGC would be the precise prediction of whether the patient has LNM or not. Therefore, in the future, the combination of ESD and SLND could be recommended as an effective, minimally invasive treatment for EMGC patients having a potential risk of LNM.

REFERENCES

- 1 Jeon HK, Lee SJ, Kim GH, Park DY, Lee BE, Song GA. Endoscopic submucosal dissection for undifferentiated-type early gastric cancer: short- and long-term outcomes. *Surg Endosc* 2018; **32**: 1963-1970 [PMID: 29046960 DOI: 10.1007/s00464-017-5892-3]
- 2 Choi MK, Kim GH, Park DY, Song GA, Kim DU, Ryu DY, Lee BE, Cheong JH, Cho M. Long-term outcomes of endoscopic submucosal dissection for early gastric cancer: a single-center experience. *Surg Endosc* 2013; **27**: 4250-4258 [PMID: 23765426 DOI: 10.1007/s00464-013-3030-4]
- 3 Zhu ZL, Shi HP, Beeharry MK, Feng TN, Yan M, Yuan F, Zheng-Gang Zhu, Zhang BY, Wu W. Expanding the indication of endoscopic submucosal dissection for undifferentiated early gastric cancer is safe or not? *Asian J Surg* 2020; **43**: 526-531 [PMID: 31706922 DOI: 10.1016/j.asjsur.2019.08.006]
- 4 Bang CS, Baik GH, Shin IS, Kim JB, Suk KT, Yoon JH, Kim YS, Kim DJ, Shin WG, Kim KH, Kim HY, Lim H, Kang HS, Kim JH, Kim JB, Jung SW, Kae SH, Jang HJ, Choi MH. Endoscopic submucosal dissection for early gastric cancer with undifferentiated-type histology: A meta-analysis. *World J Gastroenterol* 2015; **21**: 6032-6043 [PMID: 26019470 DOI: 10.3748/wjg.v21.i19.6032]
- 5 Fukunaga S, Nagami Y, Shiba M, Ominami M, Tanigawa T, Yamagami H, Tanaka H, Muguruma K, Watanabe T, Tominaga K, Fujiwara Y, Ohira M, Hirakawa K, Arakawa T. Long-term prognosis of expanded-indication differentiated-type early gastric cancer treated with endoscopic submucosal dissection or surgery using propensity score analysis. *Gastrointest Endosc* 2017; **85**: 143-152 [PMID: 27365265 DOI: 10.1016/j.gie.2016.06.049]
- 6 Japanese Gastric Cancer Association. Japanese gastric cancer treatment guidelines 2014 (ver. 4). *Gastric Cancer* 2017; **20**: 1-19 [PMID: 27342689 DOI: 10.1007/s10120-016-0622-4]
- 7 Son T, Kwon IG, Hyung WJ. Minimally invasive surgery for gastric cancer treatment: current status and future perspectives. *Gut Liver* 2014; **8**: 229-236 [PMID: 24827617 DOI: 10.5009/gnl.2014.8.3.229]
- 8 Gotoda T, Yanagisawa A, Sasako M, Ono H, Nakanishi Y, Shimoda T, Kato Y. Incidence of lymph node metastasis from early gastric cancer: estimation with a large number of cases at two large centers. *Gastric Cancer* 2000; **3**: 219-225 [PMID: 11984739 DOI: 10.1007/pl00011720]
- 9 Gotoda T. Endoscopic resection of early gastric cancer. *Gastric Cancer* 2007; **10**: 1-11 [PMID: 17334711 DOI: 10.1007/s10120-006-0408-1]
- 10 Ryu SJ, Kim BW, Kim BG, Kim JH, Kim JS, Kim JI, Park JM, Oh JH, Kim TH, Kim JJ, Park SM, Park CH, Song KY, Lee JH, Kim SG, Kim DJ, Kim W. Endoscopic submucosal dissection versus surgical resection for early gastric cancer: a retrospective multicenter study on immediate and long-term outcome over 5 years. *Surg Endosc* 2016; **30**: 5283-5289 [PMID: 27338583 DOI: 10.1007/s00464-016-4877-y]
- 11 Kitagawa Y, Takeuchi H, Takagi Y, Natsugoe S, Terashima M, Murakami N, Fujimura T, Tsujimoto H, Hayashi H, Yoshimizu N, Takagane A, Mohri Y, Nabeshima K, Uenosono Y, Kinami S, Sakamoto J, Morita S, Aikou T, Miwa K, Kitajima M. Sentinel node mapping for gastric cancer: a prospective multicenter trial in Japan. *J Clin Oncol* 2013; **31**: 3704-3710 [PMID: 24019550 DOI: 10.1200/JCO.2013.50.3789]
- 12 Tanabe S, Hirabayashi S, Oda I, Ono H, Nashimoto A, Isobe Y, Miyashiro I, Tsujitani S, Seto Y, Fukagawa T, Nunobe S, Furukawa H, Koderia Y, Kaminishi M, Katai H. Gastric cancer treated by endoscopic

- submucosal dissection or endoscopic mucosal resection in Japan from 2004 through 2006: JGCA nationwide registry conducted in 2013. *Gastric Cancer* 2017; **20**: 834-842 [PMID: [28205058](#) DOI: [10.1007/s10120-017-0699-4](#)]
- 13 **Fujimoto A**, Goto O, Nishizawa T, Ochiai Y, Horii J, Maehata T, Akimoto T, Kinoshita S, Sagara S, Sasaki M, Uraoka T, Yahagi N. Gastric ESD may be useful as accurate staging and decision of future therapeutic strategy. *Endosc Int Open* 2017; **5**: E90-E95 [PMID: [28210705](#) DOI: [10.1055/s-0042-119392](#)]
- 14 **Hiki N**, Yamamoto Y, Fukunaga T, Yamaguchi T, Nunobe S, Tokunaga M, Miki A, Ohyama S, Seto Y. Laparoscopic and endoscopic cooperative surgery for gastrointestinal stromal tumor dissection. *Surg Endosc* 2008; **22**: 1729-1735 [PMID: [18074180](#) DOI: [10.1007/s00464-007-9696-8](#)]
- 15 **Tsujimoto H**, Yaguchi Y, Kumano I, Takahata R, Ono S, Hase K. Successful gastric submucosal tumor resection using laparoscopic and endoscopic cooperative surgery. *World J Surg* 2012; **36**: 327-330 [PMID: [22187132](#) DOI: [10.1007/s00268-011-1387-x](#)]
- 16 **Hyung WJ**, Cheong JH, Kim J, Chen J, Choi SH, Noh SH. Application of minimally invasive treatment for early gastric cancer. *J Surg Oncol* 2004; **85**: 181-5; discussion 186 [PMID: [14991872](#) DOI: [10.1002/jso.20018](#)]
- 17 **Fujii H**, Ishii E, Tochtani S, Nakaji S, Hirata N, Kusanagi H, Narita M. Lymph node metastasis after endoscopic submucosal dissection of a differentiated gastric cancer confined to the mucosa with an ulcer smaller than 30 mm. *Dig Endosc* 2015; **27**: 159-161 [PMID: [24684669](#) DOI: [10.1111/den.12261](#)]
- 18 **Min BH**, Kim ER, Kim KM, Park CK, Lee JH, Rhee PL, Kim JJ. Surveillance strategy based on the incidence and patterns of recurrence after curative endoscopic submucosal dissection for early gastric cancer. *Endoscopy* 2015; **47**: 784-793 [PMID: [26111362](#) DOI: [10.1055/s-0034-1392249](#)]
- 19 **Natsugoe S**, Arigami T, Uenosono Y, Yanagita S. Novel surgical approach based on the sentinel node concept in patients with early gastric cancer. *Ann Gastroenterol Surg* 2017; **1**: 180-185 [PMID: [29863111](#) DOI: [10.1002/ags3.12027](#)]
- 20 **Aikou T**, Higashi H, Natsugoe S, Hokita S, Baba M, Tako S. Can sentinel node navigation surgery reduce the extent of lymph node dissection in gastric cancer? *Ann Surg Oncol* 2001; **8**: 90S-93S [PMID: [11599911](#)]
- 21 **Morton DL**, Wen DR, Wong JH, Economou JS, Cagle LA, Storm FK, Foshag LJ, Cochran AJ. Technical details of intraoperative lymphatic mapping for early stage melanoma. *Arch Surg* 1992; **127**: 392-399 [PMID: [1558490](#) DOI: [10.1001/archsurg.1992.01420040034005](#)]
- 22 **Cho WY**, Kim YJ, Cho JY, Bok GH, Jin SY, Lee TH, Kim HG, Kim JO, Lee JS. Hybrid natural orifice transluminal endoscopic surgery: endoscopic full-thickness resection of early gastric cancer and laparoscopic regional lymph node dissection--14 human cases. *Endoscopy* 2011; **43**: 134-139 [PMID: [21108175](#) DOI: [10.1055/s-0030-1255955](#)]
- 23 **Ko WJ**, Kim YM, Yoo IK, Cho JY. Clinical outcomes of minimally invasive treatment for early gastric cancer in patients beyond the indications of endoscopic submucosal dissection. *Surg Endosc* 2018; **32**: 3798-3805 [PMID: [29464402](#) DOI: [10.1007/s00464-018-6105-4](#)]
- 24 **Abe N**, Takeuchi H, Ohki A, Yanagida O, Masaki T, Mori T, Sugiyama M. Long-term outcomes of combination of endoscopic submucosal dissection and laparoscopic lymph node dissection without gastrectomy for early gastric cancer patients who have a potential risk of lymph node metastasis. *Gastrointest Endosc* 2011; **74**: 792-797 [PMID: [21951475](#) DOI: [10.1016/j.gie.2011.06.006](#)]



Published by **Baishideng Publishing Group Inc**
7041 Koll Center Parkway, Suite 160, Pleasanton, CA 94566, USA

Telephone: +1-925-3991568

E-mail: bpgoffice@wjgnet.com

Help Desk: <https://www.f6publishing.com/helpdesk>

<https://www.wjgnet.com>

