

Name of Journal: *World Journal of Clinical Cases*

Manuscript NO: 55568

Manuscript Type: CASE REPORT

Concurrent hepatocellular carcinoma metastasis to stomach, colon, and brain: a case report

Kim R *et al.* Concurrent hepatocellular carcinoma metastasis

Ryounggo Kim, Jooyweon Song, Sang Bum Kim

Abstract

BACKGROUND

Extrahepatic metastasis (EHM) from hepatocellular carcinoma (HCC) occurs in 10%-15% of cases following initial treatment. The most frequent sites of EHM are the lungs

Match Overview

- 1

Crossref 17 words
Hyo Jeong Kang, Hui Jeong Jeong, So-Woon Kim, Eunsil Yu, Young-Joo Lee, So Yeon Kim, Jihun Kim. "Hepatocellular Car

1%
- 2

Internet 11 words
crawled on 17-Apr-2020
diagnosticpathology.biomedcentral.com

1%
- 3

Crossref 11 words
Fukuoka, Kazuya, Eriko Masachika, Miki Honda, Yoshitane Tsukamoto, and Takashi Nakano. "Isolated metastases of hep...

1%
- 4

Crossref 11 words
Haruki, Koichiro, Takeyuki Misawa, Takeshi Gocho, Ryota Sai to, Hiroaki Shiba, Tadashi Akiba, and Katsuhiko Yanaga. "Hep

1%

国内版 国际版



Concurrent hepatocellular carcinoma metastasis to stomach, color



ALL

IMAGES

VIDEOS

39,200 Results

Any time ▾

Hepatocellular carcinoma with colonic metastasis

<https://www.ncbi.nlm.nih.gov/pmc/articles/PMC4294065>

Hepatocellular carcinoma (HCC) is one of the most common **malignant tumours** in the world. More than 500,000 people are diagnosed with HCC each year, and the **disease** is responsible for 250,000 deaths annually. **Extrahepatic metastasis** to the **colon** is rare and usually presents with bloody stools. In this study, we report the case of a patient with **HCC** who was previously known to have **metastases** to the ...

Cited by: 1

Author: Tzu-Ming Ou, Wen-Chiuan Tsai, Tsai-Yuan ...

Publish Year: 2014

Lymphoepithelioma-like hepatocellular carcinoma: a case ...

<https://www.ncbi.nlm.nih.gov/pmc/articles/PMC3654885>

May 04, 2013 · We **report** a rare **case** of lymphoepithelioma-like **hepatocellular carcinoma**. A 79-year-old Japanese man had undergone curative resection of extrahepatic bile ducts because of bile duct **cancer** 9 years prior. The bile duct **cancer** was diagnosed as mucosal adenocarcinoma, ...

Cited by: 10

Author: Masahiro Shinoda, Yoshie Kadota, Hanako ...

Publish Year: 2013

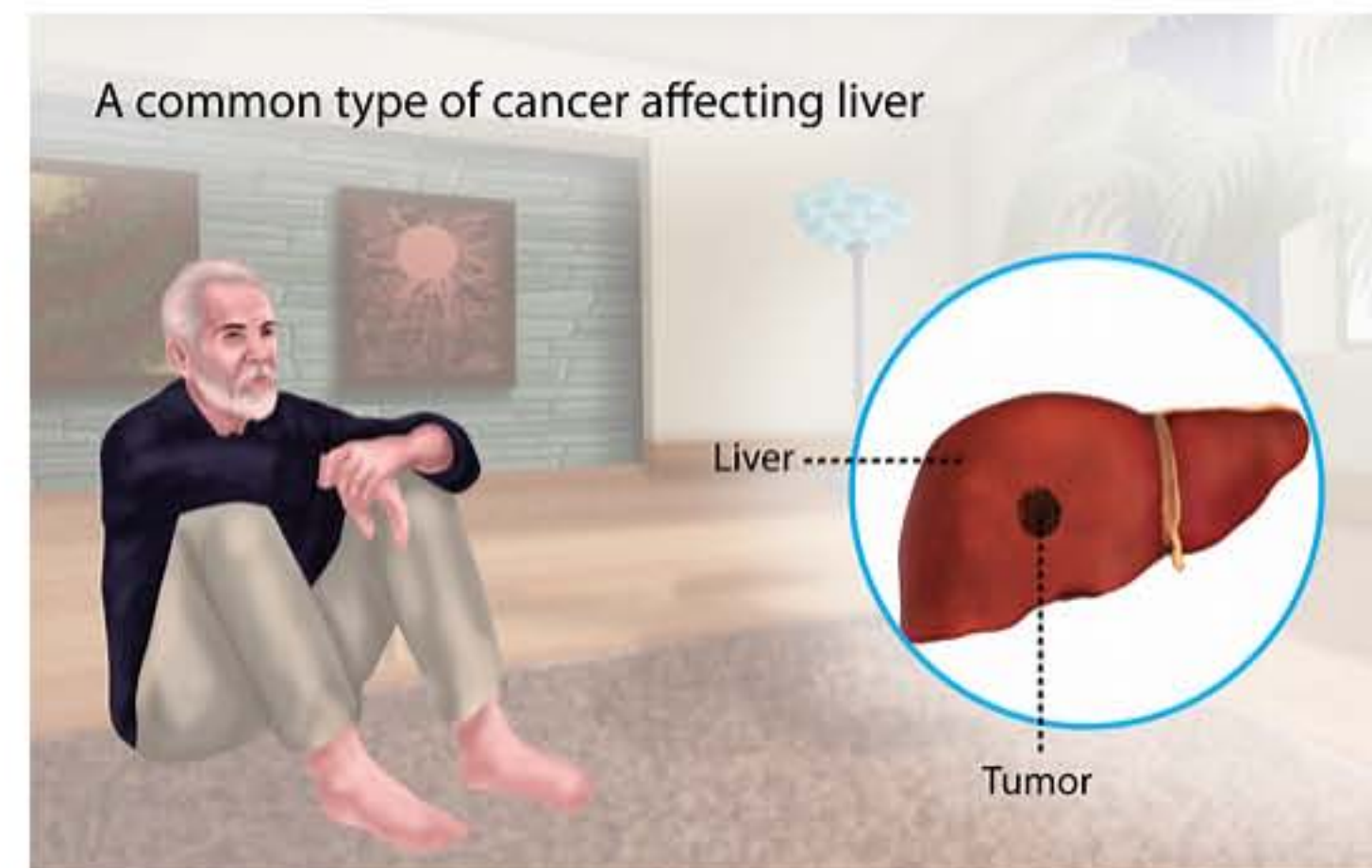
Leptomeningeal metastasis from hepatocellular carcinoma ...

<https://www.ncbi.nlm.nih.gov/pmc/articles/PMC4048255>

Case presentation. We herein **report** a **case** of leptomeningeal **metastasis** from **hepatocellular carcinoma** in a 53-year-old woman with concomitant systemic **metastases** to the lung, bone, **brain**, kidney, adrenal

Hepatocellular Carcinoma

Medical Condition



The most common form of liver cancer often seen in people with chronic liver diseases like cirrhosis.

Rare (Fewer than 200,000 cases per year in US)

May be preventable by vaccine



37,900 Results

Any time ▾

Hepatocellular carcinoma with colonic metastasis

<https://www.ncbi.nlm.nih.gov/pmc/articles/PMC4294065>

Hepatocellular carcinoma (HCC) is one of the most common **malignant tumours** in the world. More than 500,000 people are diagnosed with HCC each year, and the **disease** is responsible for 250,000 deaths annually. **Extrahepatic metastasis** to the **colon** is rare and usually presents with bloody stools. In this study, we report the case of a patient with **HCC** who was previously known to have **metastases** ...

Cited by: 1**Author:** Tzu-Ming Ou, Wen-Chiuan Tsai, Tsai-Yua...**Publish Year:** 2014

Lymphoepithelioma-like hepatocellular carcinoma: a case ...

<https://www.ncbi.nlm.nih.gov/pmc/articles/PMC3654885>

May 04, 2013 · We **report** a rare **case** of lymphoepithelioma-like **hepatocellular carcinoma**. A 79-year-old Japanese man had undergone curative resection of extrahepatic bile ducts because of bile duct **cancer** 9 years prior. The bile duct **cancer** was diagnosed as mucosal adenocarcinoma, ...

Cited by: 10**Author:** Masahiro Shinoda, Yoshie Kadota, Hanak...**Publish Year:** 2013

Hepatocellular Carcinoma Brain Metastases: A Single ...

<https://www.sciencedirect.com/science/article/pii/S1878875020306604>

Apr 11, 2020 · Background. **Brain metastases** (BMs) from **hepatocellular carcinoma** (HCC) are rare, with a paucity of reported cases. In the present retrospective cohort **report**, we assessed the proportion of BMs arising from HCC and characterized the related details, including patient demographics, clinical characteristics, treatment modalities, and survival outcomes.

Author: Samuel R. Falkson, Hriday P. Bhamb...**Publish Year:** 2020

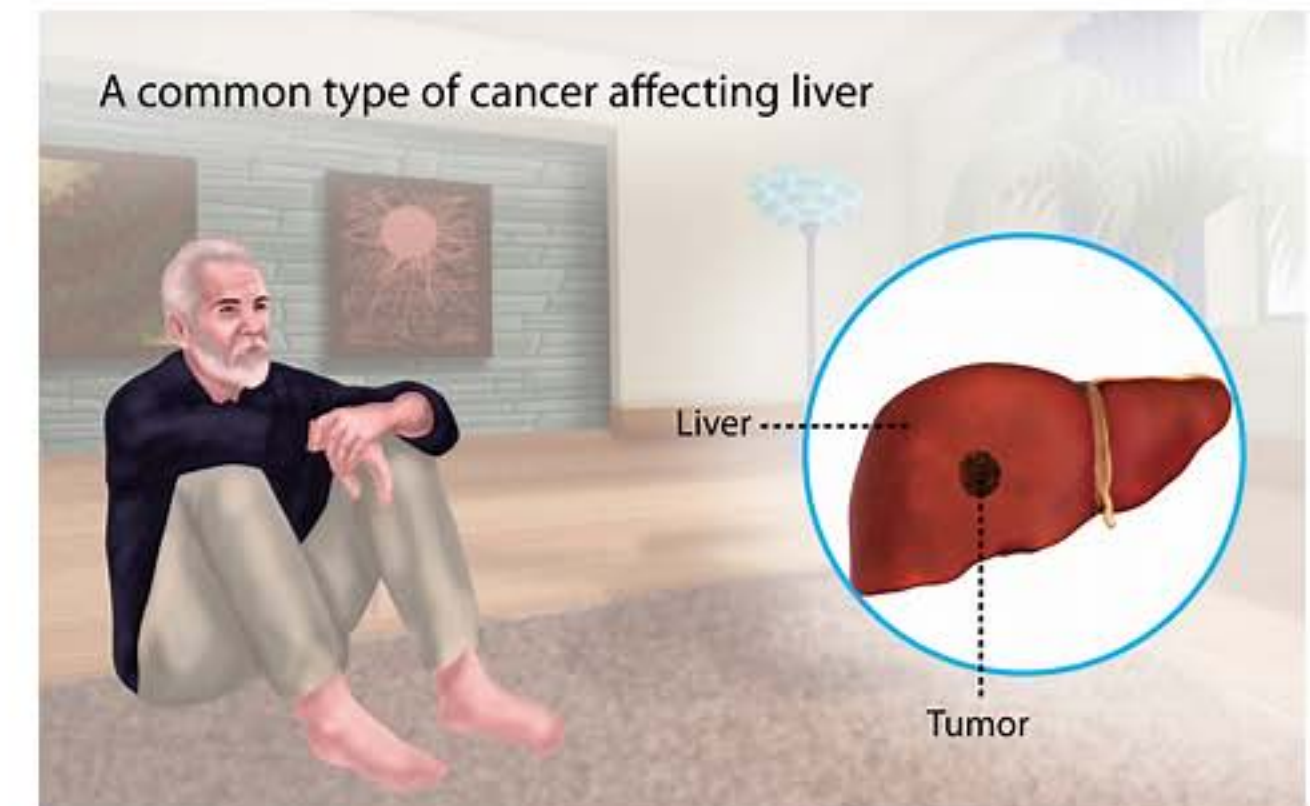
Hepatocarcinoma with metastasis to the anterior mediastinum

<https://hrjournal.net/article/view/1778> ▾

Introduction. **Hepatocellular carcinoma** (HCC) has high incidence and mortality rates, being the most common primary liver **cancer** [] and the third leading cause of **cancer** mortality. It usually starts with a solitary encapsulated lesion that often shows slow growth and is asymptomatic for a long time. [] HCC is usually associated with liver cirrhosis, which may impair treatment tolerability and ...

Hepatocellular Carcinoma

Medical Condition



The most common form of liver cancer often seen in people with chronic liver diseases like cirrhosis.

Rare (Fewer than 200,000 cases per year in US)

May be preventable by vaccine

Often requires lab test or imaging

Treatment from medical professional advised

Can last several months or years

Caused mainly due to the chronic infection of the liver or DNA mutation of the liver cells. Characterized by unexplained weight loss, upper abdominal pain and yellowing of the skin. Treatment options include hepatectomy, target drug delivery and the use of radiation to kill the cancerous cells.

Symptoms

The early stages of the disease do not present any symptoms but in the