

Match Overview

1	Crossref 27 words Toyoki Kudo, Kenichi Suzuki, Yuichi Mori, Masashi Misawa et al. "Endocytoscopy for the differential diagnosis of colo ..."	2%
2	Internet 15 words crawled on 26-Jul-2019 tessera.spandidos-publications.com	1%
3	Internet 11 words crawled on 31-Jul-2018 www.thieme-connect.de	1%
4	Crossref 11 words Yasuharu Maeda, Shin-ei Kudo, Noriyuki Ogata, Yuichi Mori et al. "Endoscopic intramucosal capillary network cha"	1%
5	Crossref 10 words Saitoh, Yusuke, Yuhei Inaba, Takahiro Sasaki, Ryuji Sugiyama, Ryuji Sukegawa, and Mikihiro Fujiya. "The manageme"	1%
6	Internet 10 words crawled on 31-Oct-2019 www.wjgnet.com	1%
7	Crossref 10 words Taishi Okumura, Shin-ei Kudo, Katsuro Ichimasa, "A Dimi"	1%

Name of Journal: *World Journal of Gastrointestinal Endoscopy*

Manuscript NO: 56326

Manuscript Type: CASE REPORT

Small invasive colon cancer with adenoma observed by endocytoscopy: A case report

Yoshika Akimoto, Shin-ei Kudo, Katsuro Ichimasa, Yuta Kouyama, Masashi Misawa, Tomokazu Hisayuki, Toyoki Kudo, Tetsuo Nemoto

Abstract

BACKGROUND

Endocytoscopy is a next-generation endoscopic system that facilitates real-time histopathologic endoscopic diagnosis of colorectal lesions by virtue of its 520 ×



A small invasive colon cancer with adenoma observed by endocopy X



ALL

IMAGES

VIDEOS

447,000 Results

Any time ▾

Endocytoscopy for the differential diagnosis of colorectal ...

<https://www.sciencedirect.com/science/article/pii/S0016510719324794>

To the best of our knowledge, the present study is the first to validate the **differential diagnosis of colorectal adenoma** using **endocytoscopy**, and our findings suggest that **endocytoscopy** can **diagnose low-grade adenoma** with high accuracy.

Author: Toyoki Kudo, Kenichi Suzuki, Yuichi ... **Publish Year:** 2020


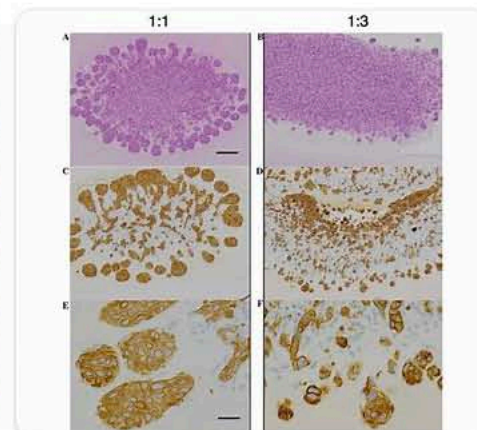
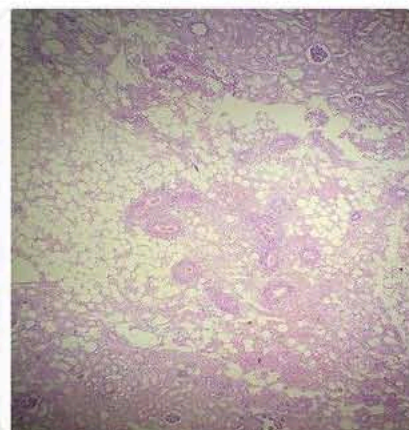
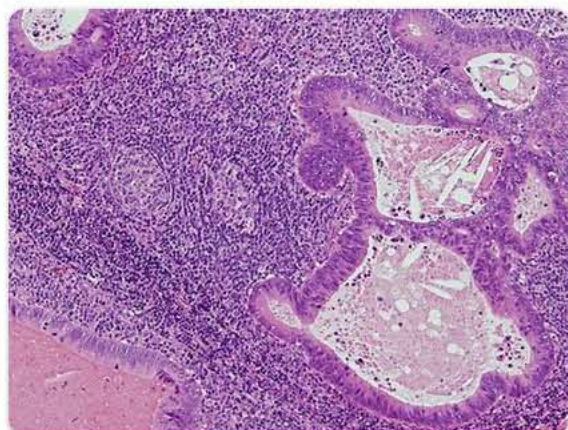
Estimation of Invasion Depth: The First Key to Successful ...

<https://www.ncbi.nlm.nih.gov/pmc/articles/PMC6453840>

Mar 27, 2019 · In a pilot study, the diagnostic accuracy of **endocytoscopy for deep invasive submucosal cancer** was 95.9% . **Endocytoscopy** images were also interpreted using artificial intelligence, and the algorithm obtained after 5,543 images from 238 lesions could **diagnose invasive colorectal cancer** in 200 test images with an accuracy of 94.1% .

Author: Bo-In Lee, Takahisa Matsuda **Publish Year:** 2019

Images of a Small Invasive colon Cancer with Adenoma Observed B...

<bing.com/images>[See all images >](#)

国内版

国际版



Small invasive colon cancer with adenoma observed by endocytoscopy: ,



Sign in



ALL

IMAGES

VIDEOS

548,000 Results

Any time ▼

Risk of progression of advanced adenomas to colorectal ...

<https://www.ncbi.nlm.nih.gov/pmc/articles/PMC2095643>

Jun 25, 2007 · For example, the cost effectiveness analyses of **colorectal cancer** screening by Frazier et al 11 and O'Leary et al 16 assumed a base-case value of 5% for the annual transition rate from high-risk polyps to localised **cancer** regardless of age, citing the 1987 **report** of Stryker et al from the Mayo clinic case series as pertinent reference. 9 ...

Cited by: 284

Author: Hermann Brenner, Michael Hoffmeister, C...

Publish Year: 2007

Advanced small-cell colon carcinoma: a case report ...

<https://jmedicalcasereports.biomedcentral.com/articles/10.1186/1752-1947-7-74> ▼

Mar 18, 2013 · **Small-cell colon** carcinoma is a very rare disease among **colon** neoplasms; it is difficult to achieve long-term survival due to its aggressive **tumor** behavior. Here we **report** the long-term survival of a patient with advanced **small-cell colon** carcinoma achieved by a combination of surgery and continuous chemotherapy. A 67-year-old Japanese man underwent abdominal computed tomography ...

Search Tools

Turn off Hover Translation (关闭取词)



Small invasive colon cancer with adenoma observed by endocytosc



ALL

IMAGES

VIDEOS

MAPS

NEWS

SHOPPING

556,000 Results

Any time ▾

[Understanding Your Pathology Report: Colon Polyps \(Sessile ...](#)

<https://www.cancer.org/treatment/understanding-your...> ▾

Feb 27, 2017 · Understanding Your Pathology **Report: Colon** Polyps (Sessile or Traditional Serrated **Adenomas**) When your **colon** was biopsied, the samples taken were studied under the microscope by a specialized doctor with many years of training called a pathologist. The pathologist sends your doctor a **report** that gives a diagnosis for each sample taken.

[Advanced small-cell colon carcinoma: a case report ...](#)

<https://jmedicalcasereports.biomedcentral.com/articles/10.1186/1752-1947-7-74> ▾

Mar 18, 2013 · **Small-cell colon** carcinoma is a very rare disease among **colon** neoplasms; it is difficult to achieve long-term survival due to its aggressive **tumor** behavior. Here we **report** the long-term survival of a patient with advanced **small-cell colon** carcinoma achieved by a combination of surgery and continuous chemotherapy. A 67-year-old Japanese man underwent abdominal computed tomography ...

Author: Toshiaki Iwase, Yoshinori Masuda, Ta... **Publish Year:** 2013

[Colorectal neuroendocrine carcinoma: A case report and ...](#)

<https://www.ncbi.nlm.nih.gov/pmc/articles/PMC6692263>

Jul 26, 2019 · CASE SUMMARY. Here, we report the case of patient with **NEC** showing an aggressive growth pattern that resulted in the rupture of the **tumor** to the outside the colon after stenting of the internal **colonic stenosis**. In addition, the **tumor** invaded into the duodenum, thereby causing duodenal stenosis that required an additional stent in the duodenum.

Cited by: 2 **Author:** Tomoaki Yoshida, Kenya Kamimura, Kaz...

Publish Year: 2019

PEOPLE ALSO ASK

Do all adenomatous polyps turn into cancer? ▾

How is a biopsy done on an intestinal tumor? ▾

What is adenomatous polyp of ascending colon? ▾

Can adenomas be removed during a colonoscopy? ▾