

Match Overview

1	Internet 40 words crawled on 16-Jul-2020 www.hindawi.com	2%
2	Internet 29 words crawled on 27-Apr-2020 f6publishing.blob.core.windows.net	2%

²
Name of Journal: *World Journal of Clinical Cases*

Manuscript NO: 57746

Manuscript Type: CASE REPORT

Large and unusual presentation of gallbladder adenoma: A case report

Lin-Li Cao, Hua Shan

Abstract

BACKGROUND

Gallbladder adenoma is a relatively rare benign tumor with a potential for malignant transformation if found to be greater than 1 cm in size.



ALL

IMAGES

VIDEOS

177,000 Results

Any time ▾

Large villous adenoma of gallbladder: A case report

<https://www.ncbi.nlm.nih.gov/pmc/articles/PMC3540215>

PRESENTATION OF CASE. The clinical data including images, surgical specimen and pathological results of this **gallbladder adenoma** larger than 50 mm were analyzed. This huge **gallbladder adenoma** had unique imaging appearance, and the pathological examination revealed the lesion to be villous adenoma with mild to moderate dysplasia.

Cited by: 1

Author: Wangxun Jin, Chengwu Zhang, Jie Liu, Z...

Publish Year: 2013

Large villous adenoma of gallbladder: A case report.

<https://www.ncbi.nlm.nih.gov/pubmed/23276760>

Villous adenoma of gallbladder is extremely rare and is considered as a premalignant condition that eventually progresses to **adenocarcinoma** via the **adenoma-carcinoma sequence**. **PRESENTATION OF CASE:** The clinical data including **images**, surgical specimen and pathological results of this **gallbladder adenoma** larger than 50mm were analyzed.

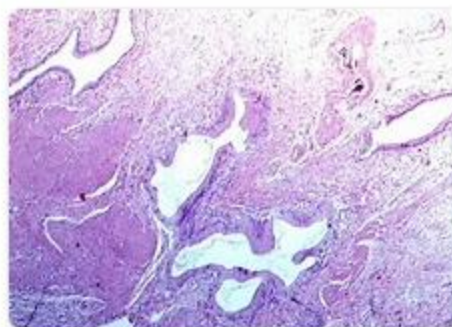
Cited by: 1

Author: Wangxun Jin, Chengwu Zhang, Jie Liu, Z...

Publish Year: 2013

Images of Large and unusual presentation of gallbladder ade...

<bing.com/images>



See all images >



ALL

IMAGES

VIDEOS

410,000 Results

Any time ▾

Large villous adenoma of gallbladder: A case report

<https://www.ncbi.nlm.nih.gov/pmc/articles/PMC3540215>

PRESENTATION OF CASE. The clinical data including images, surgical specimen and pathological results of this **gallbladder adenoma** larger than 50 mm were analyzed. This huge **gallbladder adenoma** had unique imaging appearance, **and** the pathological examination revealed the lesion to be villous **adenoma** with mild to moderate dysplasia.

Cited by: 1

Author: Wangxun Jin, Chengwu Zhang, Jie Liu, Zho...

Publish Year: 2013

Large villous adenoma of gallbladder: A case report

<https://pubmed.ncbi.nlm.nih.gov/23276760>

Villous adenoma of gallbladder is extremely rare and is considered as a premalignant condition that eventually progresses to **adenocarcinoma** via the **adenoma-carcinoma sequence**. **Presentation of case:** The clinical data including images, surgical specimen and **pathological results** of this **gallbladder adenoma** larger than 50mm were analyzed.

Cited by: 1

Author: Wangxun Jin, Chengwu Zhang, Jie Liu, Zho...

Publish Year: 2013

(PDF) Large villous adenoma of gallbladder: A case report

https://www.researchgate.net/publication/234019158_Large_villous_adenoma_of...

Villous adenoma of gallbladder is extremely rare and is considered as a premalignant condition that eventually progresses to **adenocarcinoma** via the **adenoma-carcinoma sequence**. **Presentation of case ...**

An unusual association of diffuse adenomyomatosis with ...

<https://pubmed.ncbi.nlm.nih.gov/20423477>

The **adenoma** of the **gallbladder**, together with the **dysplasia**, represents a biological carcinogenetic model. **Carcinoma** has rarely been **reported** in **adenomyomatosis**. Degenerative risk suggests surgery should be mandatory when there is a concomitant presence of **large adenoma** and **adenomyomatosis**.

Cited by: 5

Author: Isidoro Di Carlo, Adriana Toro, Elia Pulvirent...

Publish Year: 2010

Surgical resection of solid gallbladder adenocarcinoma ...

<https://www.ncbi.nlm.nih.gov/pmc/articles/PMC4328207>

Abstract. This **report** describes a **case** of a patient with a **large solid gallbladder adenocarcinoma** that was completely resected through aggressive surgery. The patient was a 57-year-old woman who had been diagnosed with **advanced gallbladder cancer**, had no indications for **surgical resection** and was



Large and unusual presentation of gallbladder adenoma: A case rep



ALL

IMAGES

VIDEOS

MAPS

NEWS

SHOPPING

423,000 Results

Any time ▾

Large villous adenoma of gallbladder: A case report

<https://www.ncbi.nlm.nih.gov/pmc/articles/PMC3540215>

PRESENTATION OF CASE. The clinical data including images, surgical specimen and pathological results of this **gallbladder adenoma** larger than 50 mm were analyzed. This huge **gallbladder adenoma** had unique imaging appearance, and the pathological examination revealed the lesion to be villous **adenoma** with mild to moderate dysplasia.

Cited by: 1

Author: Wangxun Jin, Chengwu Zhang, Jie Liu, Z...

Publish Year: 2013

Large villous adenoma of gallbladder: A case report ...

<https://www.sciencedirect.com/science/article/pii/S2210261212002283>

Jan 01, 2013 · **PRESENTATION OF CASE.** The clinical data including images, surgical specimen and pathological results of this **gallbladder adenoma** larger than 50 mm were analyzed. This huge **gallbladder adenoma** had unique imaging appearance, and the pathological examination revealed the lesion to be villous **adenoma** with mild to moderate dysplasia.

Cited by: 1

Author: Wangxun Jin, Chengwu Zhang, Jie Liu, Z...

Publish Year: 2013

Large villous adenoma of gallbladder: A case report

<https://pubmed.ncbi.nlm.nih.gov/23276760>

Presentation of case: The clinical data including images, surgical specimen and pathological results of this **gallbladder adenoma** larger than 50mm were analyzed. This huge **gallbladder adenoma** had unique imaging appearance, and the pathological examination revealed the lesion to be villous **adenoma** with mild to moderate dysplasia.

Cited by: 1

Author: Wangxun Jin, Chengwu Zhang, Jie Liu, Z...

Publish Year: 2013

Large villous adenoma of gallbladder: A case report.

<https://www.ncbi.nlm.nih.gov/pubmed/23276760>

Villous adenoma of gallbladder is extremely rare and is considered as a premalignant condition that eventually progresses to **adenocarcinoma** via the **adenoma-carcinoma** sequence. **PRESENTATION**

OF CASE. The clinical data including images, surgical specimen and pathological **results** of this

<https://www.ncbi.nlm.nih.gov/pmc/articles/PMC3540215/>

larger than 50mm were analyzed. This huge **gallbladder adenoma** had unique