

# World Journal of *Clinical Cases*

*World J Clin Cases* 2020 December 6; 8(23): 5835-6212



## Contents

Semimonthly Volume 8 Number 23 December 6, 2020

### EDITORIAL

- 5835** Understanding the immunopathogenesis of COVID-19: Its implication for therapeutic strategy  
*Shimizu Y*

### OPINION REVIEW

- 5844** What is the gut feeling telling us about physical activity in colorectal carcinogenesis?  
*Cigrovski Berkovic M, Cigrovski V, Bilic-Curcic I, Mrzljak A*

### REVIEW

- 5852** Latest developments in chronic intestinal pseudo-obstruction  
*Zhu CZ, Zhao HW, Lin HW, Wang F, Li YX*

### ORIGINAL ARTICLE

#### Case Control Study

- 5866** Correlation between ductus venosus spectrum and right ventricular diastolic function in isolated single-umbilical-artery foetus and normal foetus in third trimester  
*Li TG, Nie F, Xu XY*

#### Retrospective Cohort Study

- 5876** Clinical efficacy of integral theory-guided laparoscopic integral pelvic floor/ligament repair in the treatment of internal rectal prolapse in females  
*Yang Y, Cao YL, Zhang YY, Shi SS, Yang WW, Zhao N, Lyu BB, Zhang WL, Wei D*

#### Retrospective Study

- 5887** Treatment of Kümmell's disease with sequential infusion of bone cement: A retrospective study  
*Zhang X, Li YC, Liu HP, Zhou B, Yang HL*
- 5894** Application value analysis of magnetic resonance imaging and computed tomography in the diagnosis of intracranial infection after craniocerebral surgery  
*Gu L, Yang XL, Yin HK, Lu ZH, Geng CJ*
- 5902** Focal intrahepatic strictures: A proposal classification based on diagnosis-treatment experience and systemic review  
*Zhou D, Zhang B, Zhang XY, Guan WB, Wang JD, Ma F*
- 5918** Preliminary analysis of the effect of vagus nerve stimulation in the treatment of children with intractable epilepsy  
*Fang T, Xie ZH, Liu TH, Deng J, Chen S, Chen F, Zheng LL*

- 5926** Scoring system for poor limb perfusion after limb fracture in children  
*Zhu T, Shi Y, Yu Q, Zhao YJ, Dai W, Chen Y, Zhang SS*
- 5935** Overexpression of CD155 is associated with PD-1 and PD-L1 expression on immune cells, rather than tumor cells in the breast cancer microenvironment  
*Wang RB, Li YC, Zhou Q, Lv SZ, Yuan KY, Wu JP, Zhao YJ, Song QK, Zhu B*
- 5944** Application of computer tomography-based 3D reconstruction technique in hernia repair surgery  
*Wang F, Yang XF*
- 5952** Effect of methylprednisolone in severe and critical COVID-19: Analysis of 102 cases  
*Zhu HM, Li Y, Li BY, Yang S, Peng D, Yang X, Sun XL, Zhang M*

**Observational Study**

- 5962** Genetic diagnosis history and osteoarticular phenotype of a non-transfusion secondary hemochromatosis  
*Ruan DD, Gan YM, Lu T, Yang X, Zhu YB, Yu QH, Liao LS, Lin N, Qian X, Luo JW, Tang FQ*
- 5976** Abdominal ventral rectopexy with colectomy for obstructed defecation syndrome: An alternative option for selected patients  
*Wang L, Li CX, Tian Y, Ye JW, Li F, Tong WD*
- 5988** Surgical treatment of multiple magnet ingestion in children: A single-center study  
*Cai DT, Shu Q, Zhang SH, Liu J, Gao ZG*

**Randomized Clinical Trial**

- 5999** Efficacy and economic benefits of a modified Valsalva maneuver in patients with paroxysmal supraventricular tachycardia  
*Wang W, Jiang TF, Han WZ, Jin L, Zhao XJ, Guo Y*

**CASE REPORT**

- 6009** Duodenal giant stromal tumor combined with ectopic varicose hemorrhage: A case report  
*Li DH, Liu XY, Xu LB*
- 6016** Healthy neonate born to a SARS-CoV-2 infected woman: A case report and review of literature  
*Wang RY, Zheng KQ, Xu BZ, Zhang W, Si JG, Xu CY, Chen H, Xu ZY, Wu XM*
- 6026** Pleomorphic adenoma of the trachea: A case report and review of the literature  
*Liao QN, Fang ZK, Chen SB, Fan HZ, Chen LC, Wu XP, He X, Yu HP*
- 6036** Neoadjuvant targeted therapy for apocrine carcinoma of the breast: A case report  
*Yang P, Peng SJ, Dong YM, Yang L, Yang ZY, Hu XE, Bao GQ*
- 6043** Huge encrusted ureteral stent forgotten for over 25 years: A case report  
*Kim DS, Lee SH*

- 6048** Roxadustat for treatment of erythropoietin-hyporesponsive anemia in a hemodialysis patient: A case report  
*Yu WH, Li XJ, Yuan F*
- 6056** Suspected SARS-CoV-2 infection with fever and coronary heart disease: A case report  
*Gong JR, Yang JS, He YW, Yu KH, Liu J, Sun RL*
- 6064** Interpersonal psychotherapy-based psychological intervention for patient suffering from COVID-19: A case report  
*Hu CC, Huang JW, Wei N, Hu SH, Hu JB, Li SG, Lai JB, Huang ML, Wang DD, Chen JK, Zhou XY, Wang Z, Xu Y*
- 6071** Optical coherence tomography angiography characteristics in Waldenström macroglobulinemia retinopathy: A case report  
*Li J, Zhang R, Gu F, Liu ZL, Sun P*
- 6080** Forty-nine years old woman co-infected with SARS-CoV-2 and Mycoplasma: A case report  
*Gao ZA, Gao LB, Chen XJ, Xu Y*
- 6086** Endoscopic fenestration in the diagnosis and treatment of delayed anastomotic submucosal abscess: A case report and review of literature  
*Zhang BZ, Wang YD, Liao Y, Zhang JJ, Wu YF, Sun XL, Sun SY, Guo JT*
- 6095** Small-cell neuroendocrine carcinoma of the rectum — a rare tumor type with poor prognosis: A case report and review of literature  
*Chen ZZ, Huang W, Wei ZQ*
- 6103** Laparoscopic left lateral sectionectomy in pediatric living donor liver transplantation by single-port approach: A case report  
*Li H, Wei L, Zeng Z, Qu W, Zhu ZJ*
- 6110** Malignant meningioma with jugular vein invasion and carotid artery extension: A case report and review of the literature  
*Chen HY, Zhao F, Qin JY, Lin HM, Su JP*
- 6122** Neuronal intranuclear inclusion disease mimicking acute cerebellitis: A case report  
*Guo JJ, Wang ZY, Wang M, Jiang ZZ, Yu XF*
- 6130** Hemophagocytic lymphohistiocytosis caused by STAT1 gain-of-function mutation is not driven by interferon- $\gamma$ : A case report  
*Liu N, Zhao FY, Xu XJ*
- 6136** Single door laminoplasty plus posterior fusion for posterior atlantoaxial dislocation with congenital malformation: A case report and review of literature  
*Zhu Y, Wu XX, Jiang AQ, Li XF, Yang HL, Jiang WM*
- 6144** Occipital nodular fasciitis easily misdiagnosed as neoplastic lesions: A rare case report  
*Wang T, Tang GC, Yang H, Fan JK*

- 6150** Postoperative secondary aggravation of obstructive sleep apnea-hypopnea syndrome and hypoxemia with bilateral carotid body tumor: A case report  
*Yang X, He XG, Jiang DH, Feng C, Nie R*
- 6158** Uncontrolled central hyperthermia by standard dose of bromocriptine: A case report  
*Ge X, Luan X*
- 6164** Acute celiac artery occlusion secondary to blunt trauma: Two case reports  
*Li H, Zhao Y, Xu YA, Li T, Yang J, Hu P, Ai T*
- 6172** Multiple ectopic goiter in the retroperitoneum, abdominal wall, liver, and diaphragm: A case report and review of literature  
*Qin LH, He FY, Liao JY*
- 6181** Symptomatic and optimal supportive care of critical COVID-19: A case report and literature review  
*Pang QL, He WC, Li JX, Huang L*
- 6190** Primary breast cancer patient with poliomyelitis: A case report  
*Wang XM, Cong YZ, Qiao GD, Zhang S, Wang LJ*
- 6197** Discontinuous polyostotic fibrous dysplasia with multiple systemic disorders and unique genetic mutations: A case report  
*Lin T, Li XY, Zou CY, Liu WW, Lin JF, Zhang XX, Zhao SQ, Xie XB, Huang G, Yin JQ, Shen JN*
- 6206** Novel triple therapy for hemorrhagic ascites caused by endometriosis: A case report  
*Han X, Zhang ST*

**ABOUT COVER**

Peer-reviewer of *World Journal of Clinical Cases*, Dr. Mohamad Adam Bujang is a Research Officer at the Institute for Clinical Research, Ministry of Health, Malaysia. After receiving his Bachelor's degree in Statistics from MARA University of Technology in 2004, Dr. Adam undertook his postgraduate study at the same university, receiving his Master's degree (MBA) in 2008 and his PhD in Information Technology and Quantitative Sciences in 2017. Currently, he works as a biostatistician and researcher in the Clinical Research Centre, Sarawak General Hospital. His ongoing research interests involve such research methodologies as sampling techniques, sample size planning, and statistical analyses. Since 2016, he has served as an active member of the Malaysia Institute of Statistics and the Association of Clinical Registries Malaysia. (L-Editor: Filipodia)

**AIMS AND SCOPE**

The primary aim of *World Journal of Clinical Cases* (*WJCC*, *World J Clin Cases*) is to provide scholars and readers from various fields of clinical medicine with a platform to publish high-quality clinical research articles and communicate their research findings online.

*WJCC* mainly publishes articles reporting research results and findings obtained in the field of clinical medicine and covering a wide range of topics, including case control studies, retrospective cohort studies, retrospective studies, clinical trials studies, observational studies, prospective studies, randomized controlled trials, randomized clinical trials, systematic reviews, meta-analysis, and case reports.

**INDEXING/ABSTRACTING**

The *WJCC* is now indexed in Science Citation Index Expanded (also known as SciSearch®), Journal Citation Reports/Science Edition, PubMed, and PubMed Central. The 2020 Edition of Journal Citation Reports® cites the 2019 impact factor (IF) for *WJCC* as 1.013; IF without journal self cites: 0.991; Ranking: 120 among 165 journals in medicine, general and internal; and Quartile category: Q3.

**RESPONSIBLE EDITORS FOR THIS ISSUE**

Production Editor: Yan-Xia Xing; Production Department Director: Yun-Xiaojian Wu; Editorial Office Director: Jin-Lai Wang.

**NAME OF JOURNAL**

*World Journal of Clinical Cases*

**ISSN**

ISSN 2307-8960 (online)

**LAUNCH DATE**

April 16, 2013

**FREQUENCY**

Semimonthly

**EDITORS-IN-CHIEF**

Dennis A Bloomfield, Sandro Vento, Bao-gan Peng

**EDITORIAL BOARD MEMBERS**

<https://www.wjgnet.com/2307-8960/editorialboard.htm>

**PUBLICATION DATE**

December 6, 2020

**COPYRIGHT**

© 2020 Baishideng Publishing Group Inc

**INSTRUCTIONS TO AUTHORS**

<https://www.wjgnet.com/bpg/gerinfo/204>

**GUIDELINES FOR ETHICS DOCUMENTS**

<https://www.wjgnet.com/bpg/GerInfo/287>

**GUIDELINES FOR NON-NATIVE SPEAKERS OF ENGLISH**

<https://www.wjgnet.com/bpg/gerinfo/240>

**PUBLICATION ETHICS**

<https://www.wjgnet.com/bpg/GerInfo/288>

**PUBLICATION MISCONDUCT**

<https://www.wjgnet.com/bpg/gerinfo/208>

**ARTICLE PROCESSING CHARGE**

<https://www.wjgnet.com/bpg/gerinfo/242>

**STEPS FOR SUBMITTING MANUSCRIPTS**

<https://www.wjgnet.com/bpg/GerInfo/239>

**ONLINE SUBMISSION**

<https://www.f6publishing.com>





## Uncontrolled central hyperthermia by standard dose of bromocriptine: A case report

Xin Ge, Xue Luan

**ORCID number:** Xin Ge 0000-0003-2999-3547; Xue Luan 0000-0001-8906-8906.

**Author contributions:** Ge X contributed to the concept, drafting, reporting, and revising of the case; Luan X acquired clinical data and revised the manuscript. All authors have read and approved the final manuscript.

### Informed consent statement:

Informed written consent was obtained from the patient for publication of this report and any accompanying images.

**Conflict-of-interest statement:** The authors declare that they have no conflict of interest to disclose.

### CARE Checklist (2016) statement:

The authors have read the CARE Checklist (2016), and the manuscript was prepared and revised according to the CARE Checklist (2016).

**Open-Access:** This article is an open-access article that was selected by an in-house editor and fully peer-reviewed by external reviewers. It is distributed in accordance with the Creative Commons Attribution NonCommercial (CC BY-NC 4.0) license, which permits others to distribute, remix, adapt, build upon this work non-commercially,

**Xin Ge**, Department of Intensive Care Unit, Wuxi 9<sup>th</sup> Affiliated Hospital of Soochow University, Hand Institution of Wuxi City, Wuxi 214000, Jiangsu Province, China

**Xin Ge**, Traumatic Center, Wuxi 9<sup>th</sup> Affiliated Hospital of Soochow University, Hand Institution of Wuxi City, Wuxi 214000, Jiangsu Province, China

**Xue Luan**, Department of Neurosurgery, Central Hospital of Jinzhou, Jinzhou 121000, Liaoning Province, China

**Corresponding author:** Xin Ge, MD, PhD, Assistant Professor, Director, Department of intensive care unit, Wuxi 9<sup>th</sup> Affiliated Hospital of Soochow University, Hand Institution of Wuxi City, No. 999 Liangxi Road, WuXi 214000, Jiangsu Province, China. [sirgexin@163.com](mailto:sirgexin@163.com)

## Abstract

### BACKGROUND

Some patients present to the intensive care unit due to noninfectious pathologies resulting in fever, especially acute neurological injuries, including brain trauma and intracranial haemorrhage. The cause has been identified to be central hyperthermia characterized by a high core temperature and a poor response to antipyretics and antibiotics. However, no proper guidelines on how to treat central hyperthermia have been developed for clinical practice.

### CASE SUMMARY

A 63-year-old woman was transferred to our hospital due to injury after a traffic accident. Eight hours after admission, her pupils enlarged bilaterally from 2.5 mm to 4.0 mm. She developed severe coma and underwent decompressive craniectomy. She was diagnosed with central hyperthermia after surgery and was prescribed bromocriptine. The standard dose of bromocriptine could not control her hyperpyrexia, and we prescribed 30 mg a day to control her temperature.

### CONCLUSION

Bromocriptine may be effective in controlling central hyperthermia and have a dosage effect.

**Key Words:** Central hyperthermia; Bromocriptine; Side effect; Case report

©The Author(s) 2020. Published by Baishideng Publishing Group Inc. All rights reserved.

and license their derivative works on different terms, provided the original work is properly cited and the use is non-commercial. See: <http://creativecommons.org/licenses/by-nc/4.0/>

**Manuscript source:** Unsolicited manuscript

**Specialty type:** Medicine, research and experimental

**Country/Territory of origin:** China

**Peer-review report's scientific quality classification**

Grade A (Excellent): 0

Grade B (Very good): 0

Grade C (Good): C

Grade D (Fair): 0

Grade E (Poor): 0

**Received:** July 11, 2020

**Peer-review started:** July 11, 2020

**First decision:** September 24, 2020

**Revised:** September 30, 2020

**Accepted:** October 20, 2020

**Article in press:** October 20, 2020

**Published online:** December 6, 2020

**P-Reviewer:** Smyrniotis V

**S-Editor:** Zhang L

**L-Editor:** Wang TQ

**P-Editor:** Zhang YL



**Core Tip:** Central hyperthermia is characterized by a high core temperature and a poor response to antipyretics and antibiotics. No guidelines on how to treat central hyperthermia have been developed for clinical practice, but bromocriptine has been reported to control the condition effectively. A unique female patient who had central hyperthermia that could not be controlled by a standard dose of bromocriptine was treated in our department. We prescribed 30 mg bromocriptine per day to control her hyperpyrexia.

**Citation:** Ge X, Luan X. Uncontrolled central hyperthermia by standard dose of bromocriptine: A case report. *World J Clin Cases* 2020; 8(23): 6158-6163

**URL:** <https://www.wjgnet.com/2307-8960/full/v8/i23/6158.htm>

**DOI:** <https://dx.doi.org/10.12998/wjcc.v8.i23.6158>

## INTRODUCTION

Fever has been reported to be a frequent complication in intensive care unit patients and associated with high mortality and unfavourable prognoses<sup>[1]</sup>. Noninfectious pathologies resulting in fever, especially acute neurological injuries such as brain trauma and intracranial haemorrhage, affect some patients. The cause has been identified as central hyperthermia, which is characterized by a high core temperature and a poor response to antipyretics and antibiotics<sup>[2]</sup>. Currently, no guidelines on how to treat central hyperthermia have been developed for clinical practice. However, a multimodal approach that includes the administration of additional medications, such as morphine, fentanyl, surface or intravascular cooling devices, and especially bromocriptine, has been reported<sup>[3]</sup>. A unique female patient who had central hyperthermia uncontrollable by a standard dose of bromocriptine was treated in our department. We prescribed 30 mg bromocriptine per day to control her hyperpyrexia. The results of a literature search suggest that a high dose of bromocriptine of 30 mg per day to treat central hyperthermia has not been previously reported.

## CASE PRESENTATION

### Chief complaints

A 63-year-old woman was transferred to our hospital due to injury after a traffic accident.

### History of present illness

She was hit broadside, rolled off the car's roof, and fell to the ground.

### Physical examination

In the emergency room, the patient was in a moderate coma [Glasgow Coma Scale (GCS) score 9, E2V2M5]. However, 8 h later, her pupils enlarged bilaterally from 2.5 mm to 4.0 mm. The patient developed a coma (GCS: 6, E1V1M4) and received a computed tomography (CT) scan immediately. Unfortunately, an intracranial pressure monitor was not available in our centre, so a standard fronto-temporo-parietal decompressive craniectomy was performed.

### Laboratory examinations

Most of laboratory examinations were normal.

### Imaging examinations

The CT scan in the emergency department illustrated that there were specks of blood in the left frontal and temporal lobes and there was no midline shift (Figure 1). Eight hours later, repeat CT showed that the specks of blood in the left frontal and temporal lobes had become haematomas causing a 9 mm midline shift (Figure 2).



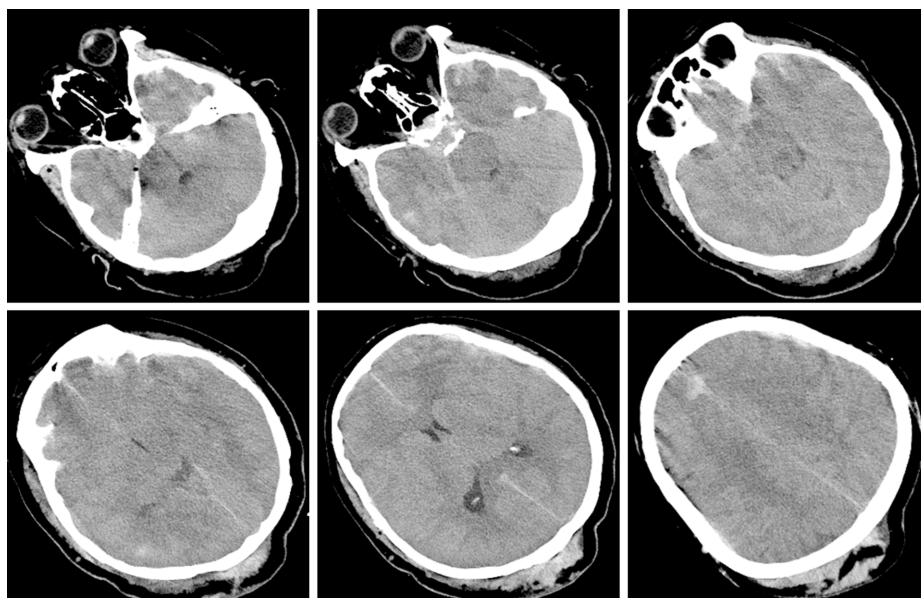


Figure 1 pecks of blood in the left frontal and temporal lobes.

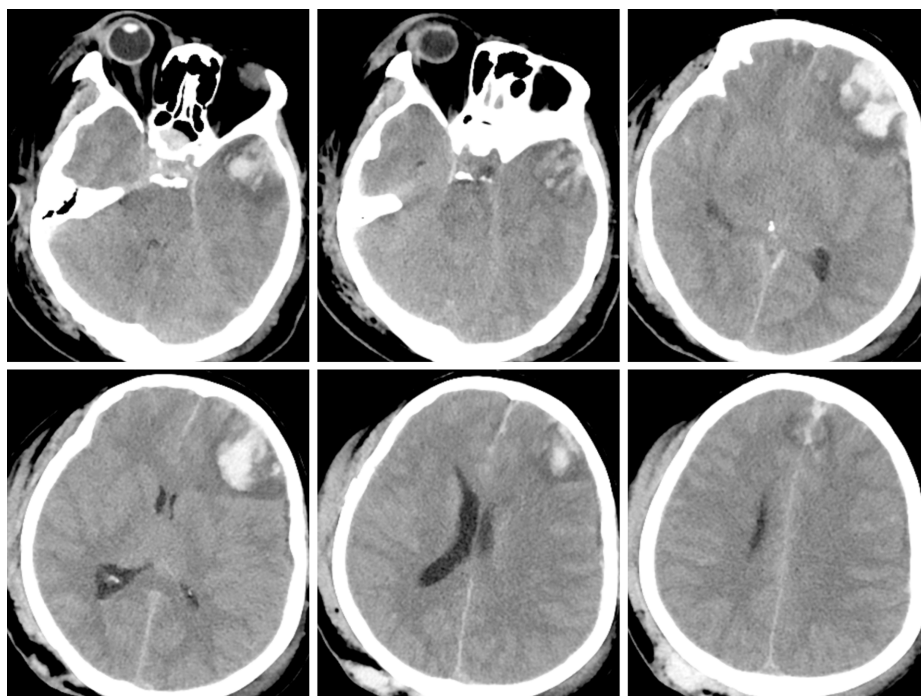


Figure 2 Haematomas in the left frontal and temporal lobes and 9 mm midline shift.

---

## FINAL DIAGNOSIS

---

Central hyperthermia.

---

## TREATMENT

---

We decided to increase the dose of bromocriptine. Five milligrams of bromocriptine three times a day was prescribed. Sixteen hours later, her temperature dropped to 37.5 °C and remained at this level for a short time; 3 h later, her temperature increased again. This phenomenon was observed three times during the following day. The next day, after obtaining written informed consent from the patient's legally authorized representative, we prescribed 5 mg bromocriptine six times a day. As expected, her

temperature dropped to 36.5 °C and remained at this temperature, but her heart rate declined from 95 to 57 per min, and her blood pressure decreased. Five days after her temperature was controlled, we attempted to decrease the dose of bromocriptine to 5 mg four times a day but failed. Her temperature rose again to 40.1 °C and dropped to 38.0 °C for 3 to 4 h. We resumed the previous dose, and her temperature became stable. The side effects of the drug included declines in her heart rate and blood pressure. Her heart rate had decreased to 41 per min but remained stable with vasoactive drugs. Seven days later, we tried to decrease the dose of bromocriptine and failed again. Six weeks after surgery, when bromocriptine had been administered for 34 d, we decreased the dose and managed to successfully stop administration within 2 wk (Figure 3).

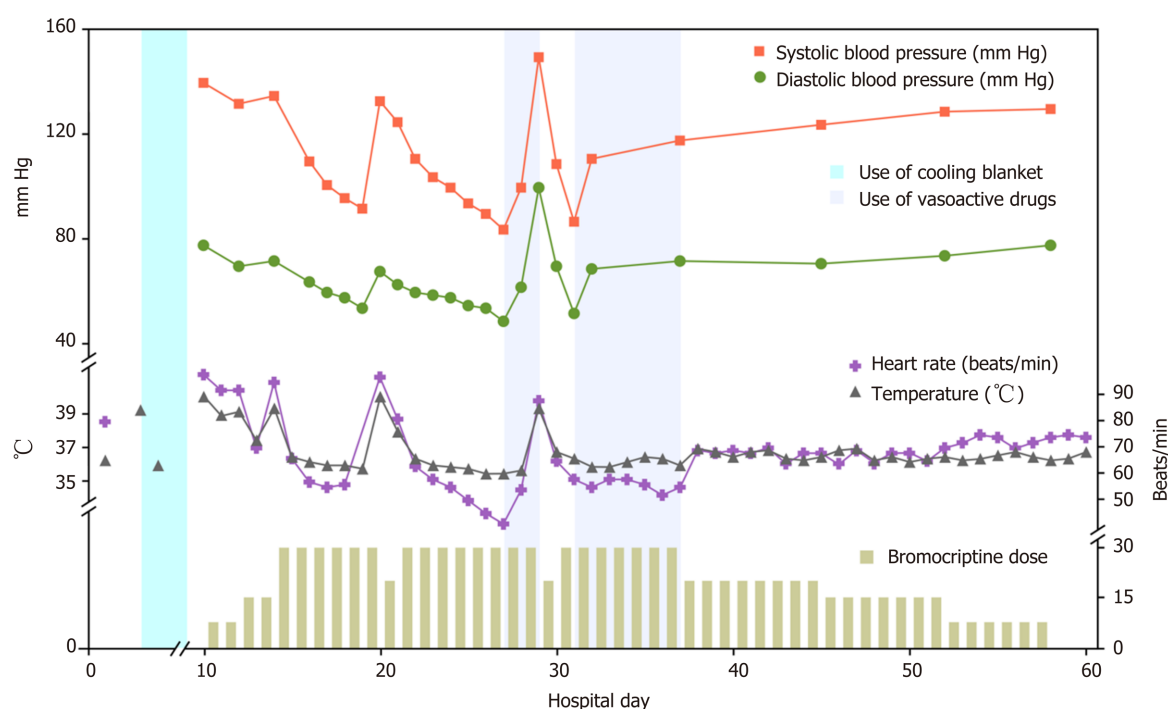
## OUTCOME AND FOLLOW-UP

Eight weeks after surgery, her GCS score was 5 (E1VTM3). She underwent a magnetic resonance imaging (MRI) scan, which illustrated speck signals in the midbrain, pontine, and pituitarium and multiple damage signals in the left frontal, temporal, and occipital lobes, basal ganglia, thalamus, and corpus callosum (Figure 4). The MRI findings were supportive of the diagnosis of diffuse axonal injury (DAI). She was sent to rehabilitation center. The GCS score was 8 (E3VTM4) 6 mo later.

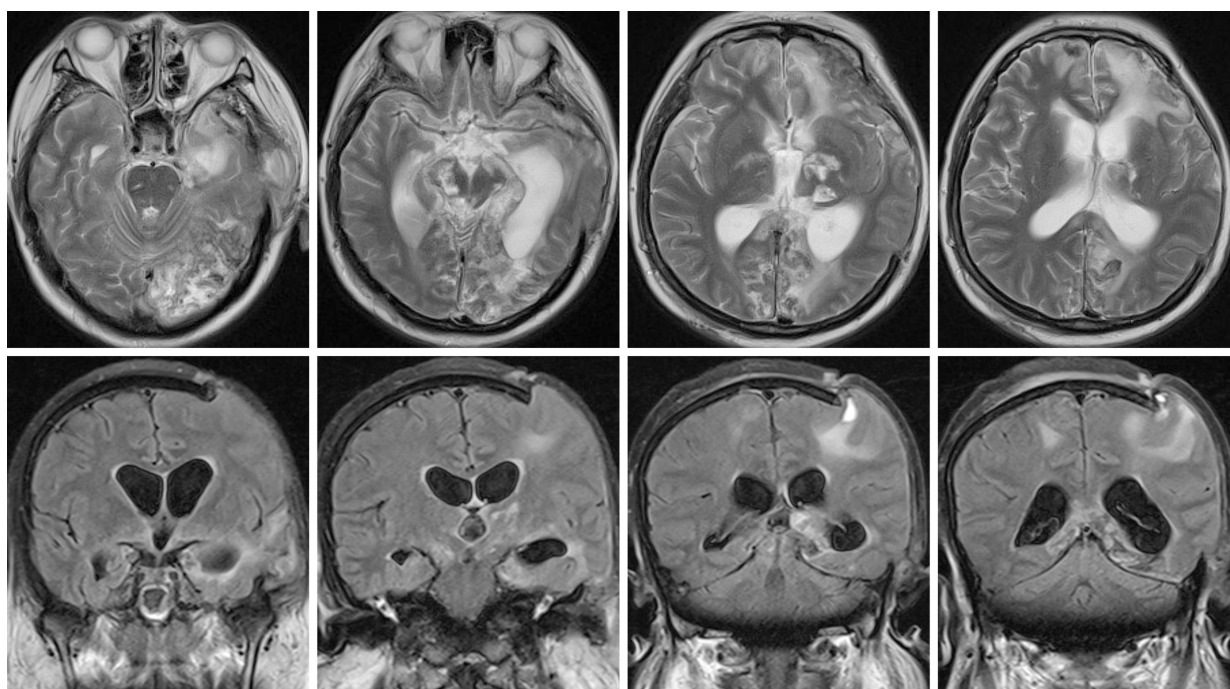
## DISCUSSION

An elevated temperature affects not only the brain but also other organs and may increase the risk of mortality<sup>[4]</sup>. A noninfectious pathology resulting in fever in a patient with severe TBI is not uncommon, and it is known as neurogenic fever<sup>[5]</sup>. Neurogenic fever is characterized by symptoms of hyperthermia, tachycardia, hyperhidrosis, hypertension, and sometimes seizures, which are referred to as dysautonomia or paroxysmal sympathetic hyperactivity or diencephalic syndrome<sup>[6]</sup>. However, the symptoms of tachycardia, hyperhidrosis, and hypertension were not found in this patient. A previous study indicated that the characteristics of central hyperthermia may be due to the compression of hypothalamic and brainstem thermoregulatory centres<sup>[7]</sup>. Some areas, including the preoptic area of the hypothalamus, inputs from spinothalamocortical relay pathways, and the lateral parabrachial nucleus at the junction of the pons and medulla, may regulate the thermo-regulating centres<sup>[8]</sup>.

In this case study, the MRI findings confirmed the diagnosis of DAI. DAI is a rotational acceleration-deceleration traumatic brain injury due to strain or shearing forces. DAI has three distinctive structural features<sup>[9]</sup>: (1) Diffuse supratentorial damage to axons (grade I); (2) A focal lesion in the corpus callosum (grade II); and (3) A focal lesion or lesions in the rostral brain stem (grade III). Therefore, this patient represents a severe case because the MRI scan showed all of these features. Hypothalamus injuries have been associated with autonomic dysfunction symptoms observed in DAI cases<sup>[9]</sup>. The compression of the hypothalamus and brainstem may result in the deregulation of the selective loss of warm-sensitive neurons, progesterone or prostaglandin hormonal changes leading to modifications in the firing rate of heat-sensitive neurons in the medial preoptic nucleus, or osmotic changes detected by the organum vasculosum laminae terminalis<sup>[10]</sup>. Bromocriptine is a dopamine D2 agonist drug that acts on the hypothalamus and the corpus striatum. Its efficacy in the treatment of central hyperthermia<sup>[3]</sup> and paroxysmal sympathetic hyperactivity<sup>[11]</sup> has been reported in previous studies because of its effects on dopaminergic transmission. A dose of 7.5 mg per day has been reported and indicated to be effective<sup>[3]</sup>. We tried to prescribe the same dose to control central hyperthermia but failed. On the basis of the clinical findings, we increased the dose to 30 mg per day, which was successful. The side effects of bromocriptine at high doses during treatment were bradycardia and hypotension. It was found that the higher the dosage of bromocriptine, the worse the bradycardia and hypotension. We used vasoactive drugs such as atropine and norepinephrine to stabilize hemodynamics in patients and succeeded. We attempted to decrease the dose of bromocriptine twice but failed due to severe side effects. Therefore, we conclude that both the effect of bromocriptine in controlling hyperpyrexia and the dosage effect were demonstrated in this study.



**Figure 3** Fluctuations of marked temperature, blood pressure, heart rate, and dose of bromocriptine and treatments with cooling blanket and vasoactive drugs were noted during the clinical course.



**Figure 4** Speck signals in the midbrain, pontine, and pituitarium and multiple damage signals in the left frontal, temporal and occipital lobes, basal ganglia, thalamus, and corpus callosum.

## CONCLUSION

This case report demonstrates that bromocriptine may be used to control central hyperthermia, and the dose may affect the clinical effect. Central hyperthermia caused by severe DAI can be treated with high doses of bromocriptine. Side effects should be considered and, if required, managed with vasoactive drugs.

## ACKNOWLEDGEMENTS

The authors would like to thank the patient and her family.

## REFERENCES

- 1 **Niven DJ**, Laupland KB. Pyrexia: aetiology in the ICU. *Crit Care* 2016; **20**: 247 [PMID: 27581757 DOI: 10.1186/s13054-016-1406-2]
- 2 **Yu KW**, Huang YH, Lin CL, Hong CZ, Chou LW. Effectively managing intractable central hyperthermia in a stroke patient by bromocriptine: a case report. *Neuropsychiatr Dis Treat* 2013; **9**: 605-608 [PMID: 23662059 DOI: 10.2147/NDT.S44547]
- 3 **Kang SH**, Kim MJ, Shin IY, Park DW, Sohn JW, Yoon YK. Bromocriptine for control of hyperthermia in a patient with mixed autonomic hyperactivity after neurosurgery: a case report. *J Korean Med Sci* 2012; **27**: 965-968 [PMID: 22876068 DOI: 10.3346/jkms.2012.27.8.965]
- 4 **Lee BH**, Inui D, Suh GY, Kim JY, Kwon JY, Park J, Tada K, Tanaka K, Ietsugu K, Uehara K, Dote K, Tajimi K, Morita K, Matsuo K, Hoshino K, Hosokawa K, Lee KH, Lee KM, Takatori M, Nishimura M, Sanui M, Ito M, Egi M, Honda N, Okayama N, Shime N, Tsuruta R, Nogami S, Yoon SH, Fujitani S, Koh SO, Takeda S, Saito S, Hong SJ, Yamamoto T, Yokoyama T, Yamaguchi T, Nishiyama T, Igarashi T, Kakihana Y, Koh Y; Fever and Antipyretic in Critically ill patients Evaluation (FACE) Study Group. Association of body temperature and antipyretic treatments with mortality of critically ill patients with and without sepsis: multi-centered prospective observational study. *Crit Care* 2012; **16**: R33 [PMID: 22373120 DOI: 10.1186/cc11211]
- 5 **Meier K**, Lee K. Neurogenic Fever. *J Intensive Care Med* 2017; **32**: 124-129 [PMID: 26772198 DOI: 10.1177/0885066615625194]
- 6 **Meyfroidt G**, Baguley IJ, Menon DK. Paroxysmal sympathetic hyperactivity: the storm after acute brain injury. *Lancet Neurol* 2017; **16**: 721-729 [PMID: 28816118 DOI: 10.1016/S1474-4422(17)30259-4]
- 7 **Deogaonkar A**, De Georgia M, Bae C, Abou-Chebl A, Andrefsky J. Fever is associated with third ventricular shift after intracerebral hemorrhage: pathophysiologic implications. *Neurol India* 2005; **53**: 202-206; discussion 206-207 [PMID: 16010060 DOI: 10.4103/0028-3886.16411]
- 8 **Morrison SF**, Nakamura K. Central Mechanisms for Thermoregulation. *Annu Rev Physiol* 2019; **81**: 285-308 [PMID: 30256726 DOI: 10.1146/annurev-physiol-020518-114546]
- 9 **Frati A**, Cerretani D, Fiaschi AI, Frati P, Gatto V, La Russa R, Pesce A, Pinchi E, Santurro A, Frascchetti F, Fineschi V. Diffuse Axonal Injury and Oxidative Stress: A Comprehensive Review. *Int J Mol Sci* 2017; **18**: 2600 [PMID: 29207487 DOI: 10.3390/ijms18122600]
- 10 **Rango M**, Arighi A, Airaghi L, Bresolin N. Central hyperthermia, brain hyperthermia and low hypothalamus temperature. *Clin Auton Res* 2012; **22**: 299-301 [PMID: 22875550 DOI: 10.1007/s10286-012-0174-6]
- 11 **Deepika A**, Mathew MJ, Kumar SA, Devi BI, Shukla D. Paroxysmal sympathetic hyperactivity in pediatric traumatic brain injury: A case series of four patients. *AutonNeurosci* 2015; **193**: 149-151 [PMID: 26277041 DOI: 10.1016/j.autneu.2015.08.003]



Published by **Baishideng Publishing Group Inc**  
7041 Koll Center Parkway, Suite 160, Pleasanton, CA 94566, USA

**Telephone:** +1-925-3991568

**E-mail:** [bpgoffice@wjgnet.com](mailto:bpgoffice@wjgnet.com)

**Help Desk:** <https://www.f6publishing.com/helpdesk>

<https://www.wjgnet.com>

