

# World Journal of *Clinical Oncology*

*World J Clin Oncol* 2020 December 24; 11(12): 968-1083



## Contents

Monthly Volume 11 Number 12 December 24, 2020

## EDITORIAL

- 968** COVID-19 and information and communication technology in radiation oncology: A new paradigm  
*Fernández C, Ruiz V, Couñago F*
- 976** Practice change in the management of metastatic urothelial carcinoma after ASCO 2020  
*Gajate P, Torres-Jiménez J, Bueno-Bravo C, Couñago F*
- 983** Stereotactic body radiation therapy: A good dance partner of oligometastatic non-small cell lung cancer to the sound of SINDAS study  
*Mielgo-Rubio X, Garde-Noguera J, Juan O, Couñago F*
- 990** New standard in locally advanced rectal cancer  
*Solé S, Baeza R, Gabler C, Couñago F*

## MINIREVIEWS

- 996** Predictive indicators of successful tyrosine kinase inhibitor discontinuation in patients with chronic myeloid leukemia  
*Stuckey R, López-Rodríguez JF, Sánchez-Sosa S, Segura-Díaz A, Sánchez-Farías N, Bilbao-Sieyro C, Gómez-Casares MT*
- 1008** Fluoropyrimidine-induced cardiotoxicity  
*Deac AL, Burz CC, Bocsan IC, Buzoianu AD*

## ORIGINAL ARTICLE

## Retrospective Study

- 1018** Forkhead box P3 and indoleamine 2,3-dioxygenase co-expression in Pakistani triple negative breast cancer patients  
*Asghar K, Loya A, Rana IA, Bakar MA, Farooq A, Tahseen M, Ishaq M, Masood I, Rashid MU*
- 1029** Overall and cause-specific survival for mucoepidermoid carcinoma of the major salivary glands: Analysis of 2210 patients  
*Taylor ZC, Kaya EA, Bunn JD, Guss ZD, Mitchell BJ, Fairbanks RK, Lamoreaux WT, Wagner AE, Peressini BJ, Lee CM*

## Prospective Study

- 1045** Assessment of burden and coping strategies among caregivers of cancer patients in sub-Saharan Africa  
*Akpan-Idiok PA, Ehiemere IO, Asuquo EF, Chabo JAU, Osuchukwu EC*

## CASE REPORT

- 1064** Latent brain infection with *Moraxella osloensis* as a possible cause of cerebral gliomatosis type 2: A case report  
*Strojnik T, Kavalari R, Gornik-Kramberger K, Rupnik M, Robnik SL, Popovic M, Velnar T*

- 1070** Preoperative rectal tumor embolization as an adjunctive tool for bloodless abdominoperineal excision: A case report  
*Feitosa MR, de Freitas LF, Filho AB, Nakiri GS, Abud DG, Landell LM, Brunaldi MO, da Rocha JJR, Feres O, Parra RS*
- 1076** Endometrial clear cell carcinoma invading the right oviduct with a cooccurring ipsilateral oviduct adenomatoid tumor: A case report  
*Hu ZX, Tan MH, Li QZ, Xu JL, Chen W, Xie ZH, Zhou YJ, Liang Q, An JH, Shen H*

**ABOUT COVER**

Editorial board member of *World Journal of Clinical Oncology*, Dr. Ramon Andrade de Mello is Professor of Medical Oncology, Federal University of São Paulo (UNIFESP) in São Paulo, Brazil, and University of Algarve in Faro, Portugal. He also serves as Head of the Medical Oncology discipline at UNIFESP. Professor de Mello performs both basic and clinical research on biomarkers, gastrointestinal cancer, and lung cancer; further, he maintains an active office working in medical oncology. He is editor of three books and author of several scientific articles, chapters and comments on basic and clinical research. He has presented more than 100 papers at congresses and conferences in several countries. Furthermore, he serves as editorial board member of several reputed scientific journals. (L-Editor: Filipodia)

**AIMS AND SCOPE**

The primary aim of *World Journal of Clinical Oncology* (WJCO, *World J Clin Oncol*) is to provide scholars and readers from various fields of oncology with a platform to publish high-quality basic and clinical research articles and communicate their research findings online.

WJCO mainly publishes articles reporting research results and findings obtained in the field of oncology and covering a wide range of topics including art of oncology, biology of neoplasia, breast cancer, cancer prevention and control, cancer-related complications, diagnosis in oncology, gastrointestinal cancer, genetic testing for cancer, gynecologic cancer, head and neck cancer, hematologic malignancy, lung cancer, melanoma, molecular oncology, neurooncology, palliative and supportive care, pediatric oncology, surgical oncology, translational oncology, and urologic oncology.

**INDEXING/ABSTRACTING**

The WJCO is now abstracted and indexed in PubMed, PubMed Central, Emerging Sources Citation Index (Web of Science), China National Knowledge Infrastructure (CNKI), China Science and Technology Journal Database (CSTJ), and Superstar Journals Database.

**RESPONSIBLE EDITORS FOR THIS ISSUE**

Production Editor: Li-Li Wang; Production Department Director: Yun-Xiao Jian Wu; Editorial Office Director: Ze-Mao Gong.

**NAME OF JOURNAL**

*World Journal of Clinical Oncology*

**ISSN**

ISSN 2218-4333 (online)

**LAUNCH DATE**

November 10, 2010

**FREQUENCY**

Monthly

**EDITORS-IN-CHIEF**

Hiten RH Patel

**EDITORIAL BOARD MEMBERS**

<https://www.wjgnet.com/2218-4333/editorialboard.htm>

**PUBLICATION DATE**

December 24, 2020

**COPYRIGHT**

© 2020 Baishideng Publishing Group Inc

**INSTRUCTIONS TO AUTHORS**

<https://www.wjgnet.com/bpg/gerinfo/204>

**GUIDELINES FOR ETHICS DOCUMENTS**

<https://www.wjgnet.com/bpg/GerInfo/287>

**GUIDELINES FOR NON-NATIVE SPEAKERS OF ENGLISH**

<https://www.wjgnet.com/bpg/gerinfo/240>

**PUBLICATION ETHICS**

<https://www.wjgnet.com/bpg/GerInfo/288>

**PUBLICATION MISCONDUCT**

<https://www.wjgnet.com/bpg/gerinfo/208>

**ARTICLE PROCESSING CHARGE**

<https://www.wjgnet.com/bpg/gerinfo/242>

**STEPS FOR SUBMITTING MANUSCRIPTS**

<https://www.wjgnet.com/bpg/GerInfo/239>

**ONLINE SUBMISSION**

<https://www.f6publishing.com>

## Preoperative rectal tumor embolization as an adjunctive tool for bloodless abdominoperineal excision: A case report

Marley Ribeiro Feitosa, Lucas Fernandes de Freitas, Antonio Balestrim Filho, Guilherme Seizem Nakiri, Daniel Giansante Abud, Ligia Magnani Landell, Mariângela Ottoboni Brunaldi, Jose Joaquim Ribeiro da Rocha, Omar Feres, Rogério Serafim Parra

**ORCID number:** Marley Ribeiro

Feitosa 0000-0002-4440-2023; Lucas Fernandes de Freitas 0000-0002-0746-7549; Antonio Balestrim Filho 0000-0001-5232-1525; Guilherme S Nakiri 0000-0001-5132-6914; Daniel Giansante Abud 0000-0002-6171-669X; Ligia Magnani Landell 0000-0002-6433-6887; Mariângela Ottoboni Brunaldi 0000-0002-7404-6779; Jose JR da Rocha 0000-0001-7118-0545; Omar Feres 0000-0003-3593-0526; Rogério Serafim Parra 0000-0002-5566-9284.

**Author contributions:** Feitosa MR and Parra RS designed the study, collected data, analyzed and interpreted the data, drafted and revised the manuscript; de Freitas LF, Filho AB and Abud DG collected data, analyzed and interpreted the data; Nakiri GS, da Rocha JJR and Feres O analyzed and interpreted the data, and revised the manuscript; Brunaldi MO prepared the images, and performed data analysis and interpretation; all authors contributed to the analysis and interpretation of the data, revision of the manuscript for important intellectual content, granted final approval of the version to be published and agreed to be accountable for all aspects of the work in ensuring that questions

Marley Ribeiro Feitosa, Lucas Fernandes de Freitas, Antonio Balestrim Filho, Jose Joaquim Ribeiro da Rocha, Omar Feres, Rogério Serafim Parra, Department of Surgery and Anatomy, Medicine School of Ribeirão Preto, University of São Paulo, Ribeirão Preto 14048900, São Paulo, Brazil

Guilherme Seizem Nakiri, Daniel Giansante Abud, Department of Internal Medicine, Medical School of Ribeirão Preto, University of São Paulo, Ribeirão Preto 14048900, São Paulo, Brazil

Ligia Magnani Landell, Mariângela Ottoboni Brunaldi, Department of Pathology and Forensic Medicine, Medicine School of Ribeirão Preto, University of São Paulo, Ribeirão Preto 14048900, São Paulo, Brazil

**Corresponding author:** Rogério Serafim Parra, MD, PhD, Staff Physician, Department of Surgery and Anatomy, Medical School of Ribeirão Preto, University of São Paulo, No. 3900 Av. Bandeirantes, Ribeirão Preto 14048900, São Paulo, Brazil. [rsparra@hcrp.usp.br](mailto:rsparra@hcrp.usp.br)

### Abstract

#### BACKGROUND

Abdominoperineal excision (APE)-related hemorrhage can be challenging due to difficult access to pelvic organs and the risk of massive blood loss. The objective of the present study was to demonstrate the use of preoperative embolization (PE) as a strategy for blood preservation in a patient with a large low rectal tumor with a high risk of bleeding, scheduled for APE.

#### CASE SUMMARY

A 56-year-old man presented to our institution with a one-year history of anal bleeding and rectal tenesmus. The patient was diagnosed with bulky adenocarcinoma limited to the rectum. As the patient refused any clinical treatment, surgery without previous neoadjuvant chemoradiation was indicated. The patient underwent a tumor embolization procedure, two days before surgery performed *via* the right common femoral artery. The tumor was successfully devascularized and no major bleeding was noted during APE. Postoperative recovery was uneventful and a one-year follow-up showed no signs of recurrence.

#### CONCLUSION

Therapeutic tumor embolization may play a role in bloodless surgeries and

related to the accuracy or integrity of any part of the work are appropriately investigated and resolved.

**Informed consent statement:** All authors carefully protected the patient's anonymity. The patient signed an informed consent allowing the publication of this case report and any other related publication.

**Conflict-of-interest statement:** The authors report no conflict of interest.

**CARE Checklist (2016) statement:** We have read the CARE Checklist (2016), and the manuscript was prepared and revised according to the CARE Checklist (2016).

**Open-Access:** This article is an open-access article that was selected by an in-house editor and fully peer-reviewed by external reviewers. It is distributed in accordance with the Creative Commons Attribution NonCommercial (CC BY-NC 4.0) license, which permits others to distribute, remix, adapt, build upon this work non-commercially, and license their derivative works on different terms, provided the original work is properly cited and the use is non-commercial. See: <http://creativecommons.org/licenses/by-nc/4.0/>

**Manuscript source:** Invited manuscript

**Specialty type:** Oncology

**Country/Territory of origin:** Brazil

**Peer-review report's scientific quality classification**

Grade A (Excellent): 0  
Grade B (Very good): B  
Grade C (Good): C  
Grade D (Fair): 0  
Grade E (Poor): 0

**Received:** July 16, 2020

**Peer-review started:** July 16, 2020

**First decision:** August 7, 2020

**Revised:** August 20, 2020

**Accepted:** October 20, 2020

**Article in press:** October 20, 2020

increase surgical and oncologic prognoses. We describe a patient with a bulky low rectal tumor who successfully underwent preoperative embolization and bloodless abdominoperineal resection.

**Key Words:** Rectal neoplasms; Proctectomy; Bloodless medical and surgical procedures; Embolization, therapeutic; Colorectal surgery; Case report

©The Author(s) 2020. Published by Baishideng Publishing Group Inc. All rights reserved.

**Core Tip:** Abdominoperineal excision (APE) remains a major surgery with considerable morbidity. Half of patients undergoing APE have some type of postoperative complication, and bleeding requiring transfusion of blood products is the main morbidity of the procedure. Preoperative embolization as a strategy for blood preservation in a giant rectal hemangioma has been successfully described.

**Citation:** Feitosa MR, de Freitas LF, Filho AB, Nakiri GS, Abud DG, Landell LM, Brunaldi MO, da Rocha JJR, Feres O, Parra RS. Preoperative rectal tumor embolization as an adjunctive tool for bloodless abdominoperineal excision: A case report. *World J Clin Oncol* 2020; 11(12): 1070-1075

**URL:** <https://www.wjgnet.com/2218-4333/full/v11/i12/1070.htm>

**DOI:** <https://dx.doi.org/10.5306/wjco.v11.i12.1070>

## INTRODUCTION

An abdominoperineal excision (APE) consists on a combined abdominal and perineal resection of the anorectum and may be performed in benign conditions and malignancies. In low rectal cancer, advances in chemoradiotherapy and surgical devices have warranted a decrease in APE rates. Nevertheless, in those cases with anal sphincter involvement, the operation may undoubtedly be an alternative for oncologic control<sup>[1]</sup>.

Despite the evolution of colorectal surgery, such as the development of laparoscopic access and robotic surgery, proctectomy remains a major surgery with considerable morbidity<sup>[2]</sup>. Approximately half of patients undergoing APE have some type of postoperative complication, and bleeding requiring transfusion of blood products is the main morbidity of the procedure<sup>[3]</sup>.

APE-related hemorrhage can be challenging due to difficult access to pelvic organs and the risk of massive blood loss (> 1000 mL of blood)<sup>[4]</sup>. Furthermore, blood loss and blood transfusions have been associated with worse oncologic and postoperative outcomes in non-metastatic colorectal cancer. This effect is not completely understood but immunomodulatory signals leading to immunosuppression may be involved in adverse events<sup>[5]</sup>.

The concept of bloodless surgery involves a series of perioperative strategies to prevent transfusion of blood products<sup>[6]</sup>. Recent studies have shown promising results in patients who have adopted this strategy, in bloodless centers<sup>[7]</sup>. Of note, the positive effect on surgical results depends on the adoption of adequate blood conservation methods<sup>[6]</sup>. The objective of the present study was to demonstrate the use of preoperative embolization (PE) as a strategy for blood preservation in a patient with a large low rectal tumor with a high risk of bleeding, scheduled for APE.

## CASE PRESENTATION

### Chief complaints

The patient was a 56-year-old man who suffered from anal bleeding and rectal tenesmus.

### History of present illness

He presented to our institution with a one-year history of anal bleeding and rectal

**Published online:** December 24, 2020

**P-Reviewer:** Yoon YS

**S-Editor:** Fan JR

**L-Editor:** Webster JR

**P-Editor:** Wang LL



tenesmus. Worsening of symptoms was progressive. The patient also reported anorectal pain and weight loss (15% of body weight in the same period).

### **History of past illness**

No underlying diseases were reported by the patient.

### **Physical examination**

Physical examination was normal, except for a rectal mass starting 1 cm from the anal border, circumferential and obstructive.

### **Laboratory examinations**

Laboratory tests were normal, except for a hemoglobin level of 9.4 g/dL. Carcinoembryonic antigen level was 3.34 ng/mL.

### **Imaging examinations**

Colonoscopy was incomplete due to the bulky rectal mass. Tumor biopsy revealed a rectal adenocarcinoma. Abdominal and thoracic contrast-enhanced computed tomography scans showed extensive parietal thickening of the rectum, with an extension of 17.5 cm without signs of locoregional and distant metastasis (Figure 1).

## **FINAL DIAGNOSIS**

The patient was diagnosed with bulky adenocarcinoma limited to the rectum. As he refused any clinical treatment, surgery without previous neoadjuvant chemoradiation was indicated.

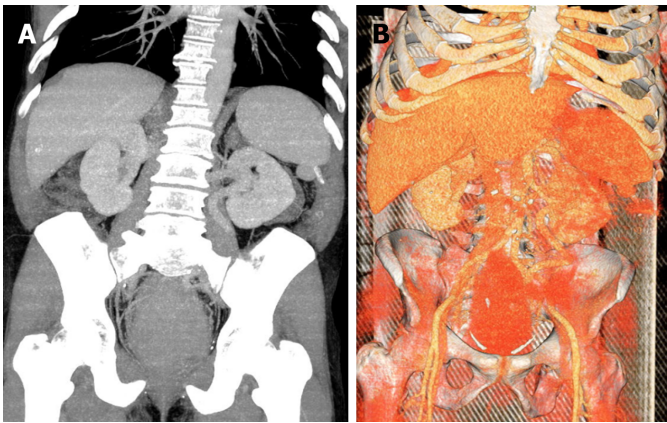
## **TREATMENT**

The patient also refused blood transfusion due to religious belief. To decrease bleeding during surgery, the patient underwent a tumor embolization procedure, two days before surgery performed *via* the right common femoral artery. Devascularization was performed with regular micra tris-acryl gelatin microspheres (500 µm) until partial reduction of vascular flow in the tumor topography. Metal coils were also released in the main trunk of the rectal arteries with subsequent administration of acrylic glue (25% n-butyl-cyanoacrylate). Angiographic control evidenced occlusion of the main branch and preservation of collateral circulation of the rectum and part of the tumor topography by small adjacent rectal branches (Figure 2). Regarding the surgical procedure, due to the absence of an adequate anal margin, we opted for an APE with total mesorectum excision and terminal colostomy in the upper left quadrant of the abdomen. A large rectal tumor occupying the entire pelvis was diagnosed, and there was no involvement of other abdominal organs (Figure 3). There was no blood transfusion during the operation. Pre- and postoperative hemoglobin levels were 9.4 and 9.1 g/dL, respectively. Analysis of the surgical specimen showed an adenocarcinoma of the rectum and anal canal, 15 cm in longitudinal length and invasion of the muscularis propria. A total of 54 disease-free lymph nodes were retrieved. There was no angiolymphatic and perineural invasion; however, extensive tumor necrosis was observed (Figure 4).

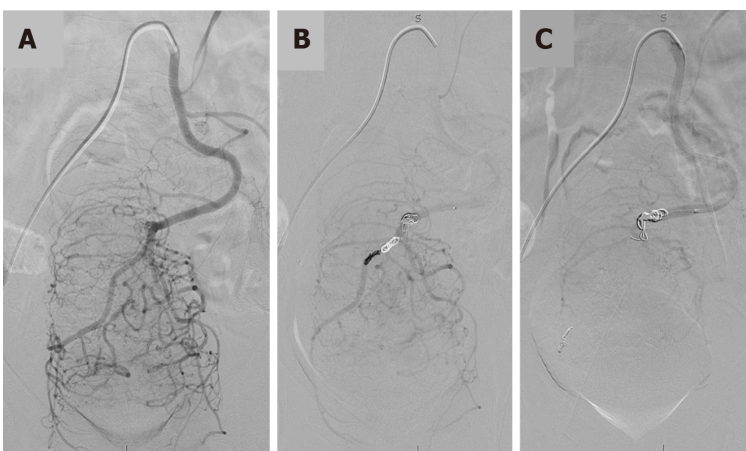
## **OUTCOME AND FOLLOW-UP**

Surgical margins were free of neoplasia and tumor staging was classified as pT2pN0cM0. The patient was discharged on the 7<sup>th</sup> postoperative day due to a metabolic ileus clinically managed. Adjuvant chemotherapy was not performed and no synchronous colonic neoplasms were diagnosed during the colonoscopy performed three months after surgery. Clinical evaluation 12 mo after surgery, showed no evidence of cancer recurrence.





**Figure 1** Computed tomography scans with vascular reconstruction. A: A bulky rectal tumor with B: Marked hypervascularization.



**Figure 2** Preoperative embolization. A: Digital subtraction angiography (DSA) of the inferior mesenteric artery identifying the enlarged superior rectal artery with prominent branches supplying the rectal tumor; B: DSA of the inferior mesenteric artery after 300-500 micra tris-acryl gelatin microspheres distal embolization into the superior rectal artery and partial occlusion of its main branch with controlled detachable platinum coils; C: Final DSA control of the inferior mesenteric artery after injection of N-butyl-2 cyanoacrylate with ethiodol 1:4 at the bifurcation of the right and left branches of the superior rectal artery, showing a significant reduction in distal arterial supply.

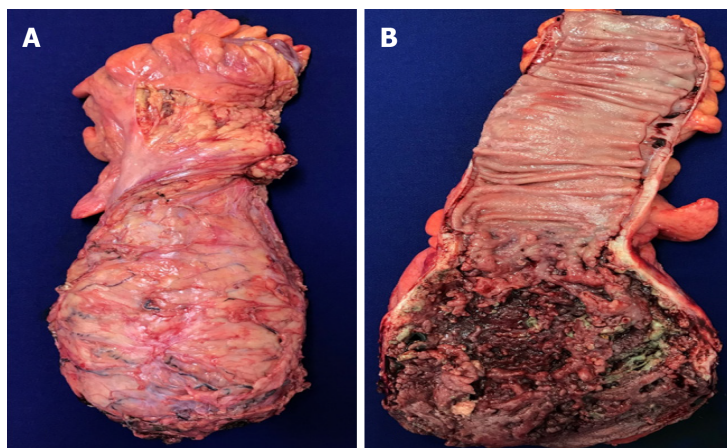
## DISCUSSION

Under normal conditions, the evaluation of blood supply in the distal rectum and mesorectum shows a predominance of blood vessels within the rectal wall<sup>[6]</sup>. In rectal cancer patients contrast-enhanced endoscopic ultrasound imaging usually reveals well vascularized masses with inhomogeneous enhancement of the contrast resulting from necrotic areas<sup>[9]</sup>. In the reported case, although atypical, a hypervascularized mass, with a predominance of blood vessels in the mesorectum was observed, as demonstrated by imaging exams. This hypervascularization is a hallmark of cancer and may be associated with the worst oncologic outcomes and with surgical complications (accidents during dissection and greater blood loss)<sup>[10]</sup>.

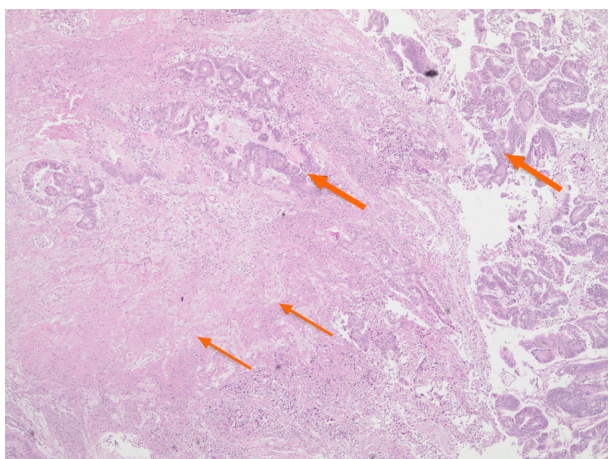
The most common measures of blood conservation in oncologic patients have been discussed elsewhere and can be grouped according to the period in which they are started<sup>[6]</sup>. In APE patients, preoperative measures include treatment of anemia, suspension of substances that interfere with coagulation and careful procedure. Intraoperatively, it is important to minimize surgical trauma and to identify the proper surgical plane to perform a fine total mesorectal excision. Also, there is potential for autologous blood salvage and autologous normovolemic hemodilution. Postoperatively, lower levels of hemoglobin should be tolerated whenever possible and laboratory testing should be reduced to a minimum<sup>[6]</sup>.

PE as a strategy to reduce intraoperative blood loss is a concept that has been developed for several anatomical territories. In pelvic tumors, devascularization rates greater than 75% can be obtained<sup>[11]</sup>. In our experience, PE was safe and successfully reduced intraoperative bleeding in a patient with a giant cavernous hemangioma of





**Figure 3 Surgical specimen after abdominal perineal resection.** A: Total mesorectal excision; B: Extensive tumor necrosis can be observed after opening the surgical specimen.



**Figure 4 Rectal adenocarcinoma (thick arrows) showing extensive tumor necrosis (thin arrows).** Hematoxylin and Eosin stain, × 40 magnification.

the rectum<sup>[12]</sup>. Although relatively simple and safe, PE can lead to significant tumor necrosis and a higher risk of bleeding, therefore, surgical resection of the tumor mass must be performed early. At our institution, we perform the definitive operation within 48 h after PE.

To the best of our knowledge, PE of bulky rectal tumors with modern techniques has not been described; however the rationale sounds reasonable, since a correlation between devascularization and less blood loss has been observed in other hypervascular tumors such as in renal masses<sup>[13]</sup>. In our experience, preoperative embolization of locally advanced rectal tumors reduces the blood content within bulky masses and can be used as an effective and safe adjunct to blood conservation. However, prospective and randomized studies are necessary to reveal the causal relationship between PE and reduced blood loss in bulky rectal masses.

## CONCLUSION

Based on our experience and on a literature review we believe that preoperative embolization of rectal cancer may be an adjunctive tool in bloodless rectal surgeries.

## REFERENCES

- 1 **Hawkins AT**, Albutt K, Wise PE, Alavi K, Sudan R, Kaiser AM, Bordeianou L; Continuing Education Committee of the SSAT. Abdominoperineal Resection for Rectal Cancer in the Twenty-First Century: Indications, Techniques, and Outcomes. *J Gastrointest Surg* 2018; **22**: 1477-1487

- [PMID: 29663303 DOI: 10.1007/s11605-018-3750-9]
- 2 **Han C**, Yan P, Jing W, Li M, Du B, Si M, Yang J, Yang K, Cai H, Guo T. Clinical, pathological, and oncologic outcomes of robotic-assisted versus laparoscopic proctectomy for rectal cancer: A meta-analysis of randomized controlled studies. *Asian J Surg* 2020; **43**: 880-890 [PMID: 31964585 DOI: 10.1016/j.asjsur.2019.11.003]
  - 3 **Tooley JE**, Sceats LA, Bohl DD, Read B, Kin C. Frequency and timing of short-term complications following abdominoperineal resection. *J Surg Res* 2018; **231**: 69-76 [PMID: 30278971 DOI: 10.1016/j.jss.2018.05.009]
  - 4 **Bonello VA**, Bhangu A, Fitzgerald JE, Rasheed S, Tekkis P. Intraoperative bleeding and haemostasis during pelvic surgery for locally advanced or recurrent rectal cancer: a prospective evaluation. *Tech Coloproctol* 2014; **18**: 887-893 [PMID: 24890577 DOI: 10.1007/s10151-014-1150-z]
  - 5 **Kwon HY**, Kim BR, Kim YW. Association of preoperative anemia and perioperative allogenic red blood cell transfusion with oncologic outcomes in patients with nonmetastatic colorectal cancer. *Curr Oncol* 2019; **26**: e357-e366 [PMID: 31285680 DOI: 10.3747/co.26.4983]
  - 6 **Frank SM**, Chaturvedi S, Goel R, Resar LMS. Approaches to Bloodless Surgery for Oncology Patients. *Hematol Oncol Clin North Am* 2019; **33**: 857-871 [PMID: 31466609 DOI: 10.1016/j.hoc.2019.05.009]
  - 7 **Resar LM**, Wick EC, Almasri TN, Dackiw EA, Ness PM, Frank SM. Bloodless medicine: current strategies and emerging treatment paradigms. *Transfusion* 2016; **56**: 2637-2647 [PMID: 27473810 DOI: 10.1111/trf.13736]
  - 8 **Murad-Regadas SM**, Regadas FSP, Dealcanfreitas ID, Regadas Filho FSP, Fernandes GOdS, Albuquerque MCF, Regadas CM, Regadas MM. Establishing the normal ranges of female and male anal canal and rectal wall vascularity with color Doppler anorectal ultrasonography. *J Col* 2018; **38**: 207-213 [DOI: 10.1016/j.jcol.2018.03.005]
  - 9 **Cartana ET**, Gheonea DI, Cherciu IF, Streața I, Uscatu CD, Nicoli ER, Ioana M, Pirici D, Georgescu CV, Alexandru DO, Șurlin V, Gruionu G, Săftoiu A. Assessing tumor angiogenesis in colorectal cancer by quantitative contrast-enhanced endoscopic ultrasound and molecular and immunohistochemical analysis. *Endosc Ultrasound* 2018; **7**: 175-183 [PMID: 28685747 DOI: 10.4103/eus.eus\_7\_17]
  - 10 **Seeber A**, Gunsilius E, Gastl G, Pircher A. Anti-Angiogenics: Their Value in Colorectal Cancer Therapy. *Oncol Res Treat* 2018; **41**: 188-193 [PMID: 29562227 DOI: 10.1159/000488301]
  - 11 **Shimohira M**, Nagai K, Hashizume T, Nakagawa M, Ozawa Y, Sakurai K, Matsushita Y, Yamada S, Otsuka T, Shibamoto Y. Preoperative transarterial embolization using gelatin sponge for hypervascular bone and soft tissue tumors in the pelvis or extremities. *Acta Radiol* 2016; **57**: 457-462 [PMID: 26082444 DOI: 10.1177/0284185115590435]
  - 12 **Carvalho RGd**, Feitosa MR, Urbano G, Guzela VR, Joviliano EE, Féres O, Rocha JJRD. Preoperative embolization of a cavernous hemangioma of the rectum. *J Col* 2014; **34**: 52-54 [DOI: 10.1016/j.jcol.2013.12.008]
  - 13 **Li D**, Pua BB, Madoff DC. Role of embolization in the treatment of renal masses. *Semin Intervent Radiol* 2014; **31**: 70-81 [PMID: 24596442 DOI: 10.1055/s-0033-1363845]



Published by **Baishideng Publishing Group Inc**  
7041 Koll Center Parkway, Suite 160, Pleasanton, CA 94566, USA

**Telephone:** +1-925-3991568

**E-mail:** [bpgoffice@wjgnet.com](mailto:bpgoffice@wjgnet.com)

**Help Desk:** <https://www.f6publishing.com/helpdesk>

<https://www.wjgnet.com>

