

Match Overview

1	Internet 51 words crawled on 02-Apr-2020 www.wjgnet.com	2%
2	Crossref 40 words Michael C. Cheung, Eduardo A. Perez, Manuel A. Molina, Xia oling Jin et al. "Defining the Role of Surgery for Primary Gas...	2%
3	Crossref 37 words Christine Castro, Yaqoot Khan, Michael Awasum, Kristina Bel ostocki, Gary Rosenblum, Elise Belilos, Steven Carsons. "Ca	2%
4	Crossref 30 words Lin Wang, Liang Zong, Hidetsugu Nakazato, Wen-Yue Wang, Chao-Feng Li, Yan-Fen Shi, Guo-Chao Zhang, Tao Tang. "F...	1%
5	Crossref 19 words Elina Shustef, Carlos A. Torres-Cabala, Jonathan L. Curry, Mi chael T. Tetzlaff et al. "Intraepithelial Melanoma in the Stoma...	1%
6	Crossref 15 words Alexander Augustyn, Emma Diaz de Leon, Adam C. Yopp. "... imary Gastric Melanoma: Case Report of a Rare Malignancy",	1%
7	Crossref 12 words Wen-Shu Ma, Jing-Guang Ma, Li-Na Xing. "Efficacy and safet y of recombinant human adenovirus p53 combined with che ...	1%

Name of Journal: *World Journal of Clinical Cases*

Manuscript NO: 58471

Manuscript Type: CASE REPORT

Primary gastric melanoma in a young women: A case report

Long G-J *et al.* PGM in a 31-year-old woman

Abstract

BACKGROUND

Most melanomas identified in the stomach are metastatic. The primary gastric melanoma (PGM) form is extremely rare. As such, clinical reports of PGM are correspondingly scarce in the literature, lending to the challenge of diagnosis and treatment.

CASE SUMMARY

A 31-year-old woman presented with 1 mo history of dysphagia but no symptoms of

A case report of primary gastric melanoma in a young women



ALL

IMAGES

VIDEOS

5,250,000 Results

Any time ▼

Primary Gastric Melanoma: Case Report of a Rare Malignancy

<https://www.ncbi.nlm.nih.gov/pmc/articles/PMC4387358>

Feb 11, 2015 · **Gastrointestinal melanoma** is most often the result of metastatic disease, with up to 60% of patients with **metastatic melanoma** having gastrointestinal (GI) involvement upon autopsy. 13,14 However, sporadic **reports** of **primary gastric melanoma** exist, totaling 11 cases in the literature. 2-12 Additionally, cases involving the **esophagus**, small intestine, gall bladder, common bile duct, and transverse colon have also been **reported**...

Cited by: 3

Author: Alexander Augustyn, Emma Diaz de Leo...

Publish Year: 2015

Malignant melanoma of the stomach presenting in a woman: a ...

<https://jmedicalcasereports.biomedcentral.com/articles/10.1186/1752-1947-5-94>



Mar 09, 2011 · **Case presentation.** In this **case report the clinical course** and treatment of a **woman** with **melanoma** of the **stomach**, without any other detectable **primary lesion**, is presented and discussed. A 55-year-old **Turkish woman** presented to our clinic with complaints of muscle pain and bone pain in the left side of her chest.

Cited by: 9

Author: Vedat Goral, Feyzullah Ucmak, Serdar Y...

Publish Year: 2011

Malignant gastrointestinal melanomas of unknown origin ...

<https://www.ncbi.nlm.nih.gov/pmc/articles/PMC4171183>

Aug 07, 2007 · They reported a **rare clinical case of a young woman** with a **bleeding jejunal melanoma**, whose early **clinical presentation** was an **intestinal invagination**. The article is also referred to the rarity of **gastrointestinal melanomas** as well as their possible primary nature.

Cited by: 26

Author: A Manouras, M Genetzakis, E Lagoudia...

Publish Year: 2007



ALL

IMAGES

VIDEOS

5,400,000 Results

Any time ▼

Primary Gastric Melanoma: Case Report of a Rare Malignancy

<https://www.ncbi.nlm.nih.gov/pmc/articles/PMC4387358>

Feb 11, 2015 · Primary gastric melanoma is an uncommon malignancy that manifests with symptoms such as **abdominal pain**, **nausea**, **hematemesis**, and **melen**, as well as nonspecific symptoms of **fatigue**, **anemia**, and **weight loss**. Accurate diagnosis depends on **biopsy** and **IHC staining** for melanoma markers such as SOX10, S100, and **HMB-45**.

Cited by: 3**Author:** Alexander Augustyn, Emma Diaz de Leon, ...**Publish Year:** 2015

Primary gastric melanoma: A case report with imaging ...

<https://pubmed.ncbi.nlm.nih.gov/31802836>

Background: Most melanomas identified in the **stomach** are metastatic; **primary gastric melanoma** (PGM) is extremely rare, and the relevant studies are relatively scarce. PGM may be incorrectly diagnosed as other **gastric** malignant tumor types. **Case** summary: We describe a rare **case** of PGM confirmed through long-term clinical observation and pathological diagnosis.

Cited by: 1**Author:** Jian Wang, Fang Yang, Wei-Qun Ao, Chang ...**Publish Year:** 2019

Gastric Metastasis of Malignant Melanoma: Report of a Case ...

<https://www.ncbi.nlm.nih.gov/pmc/articles/PMC4513808>

Case Report. We present the **case** of a 43-year-old female patient with metastases of a malignant **melanoma** to the lesser curvature of the **stomach**. The **primary** malignant **melanoma** of the right breast was resected 2 years previously.

Cited by: 3**Author:** Nader El-Sourani, Achim Troja, Hans-Rudol...**Publish Year:** 2014

ALL IMAGES VIDEOS MAPS NEWS SHOPPING

1,590,000 Results Any time ▾

Including results for primary gastric melanoma in a young **woman** a case report.
Do you want results only for Primary gastric melanoma in a young women: A case report?

Primary Gastric Melanoma: Case Report of a Rare Malignancy

<https://www.ncbi.nlm.nih.gov/pmc/articles/PMC4387358>

Feb 11, 2015 - **Primary gastric melanoma** is an uncommon malignancy that manifests with symptoms such as **abdominal pain**, **nausea**, hematemesis, and **melena**, as well as nonspecific symptoms of fatigue, anemia, and weight loss. Accurate diagnosis depends on biopsy and IHC staining for melanoma markers such as SOX10, S100, and **HMB-45**.

Cited by: 3 **Author:** Alexander Augustyn, Emma Diaz de Leon...
Publish Year: 2015

Primary gastric melanoma: A case report with imaging ...

<https://pubmed.ncbi.nlm.nih.gov/31802836>

Background: Most melanomas identified in the **stomach** are metastatic; **primary gastric melanoma** (PGM) is extremely rare, and the relevant studies are relatively scarce. PGM may be incorrectly diagnosed as other **gastric** malignant tumor types. **Case** summary: We describe a rare **case** of PGM confirmed through long-term clinical observation and pathological diagnosis.

Cited by: 1 **Author:** Jian Wang, Fang Yang, Wei-Qun Ao, Cha...
Publish Year: 2019

Primary gastric melanoma: A case report with imaging ...

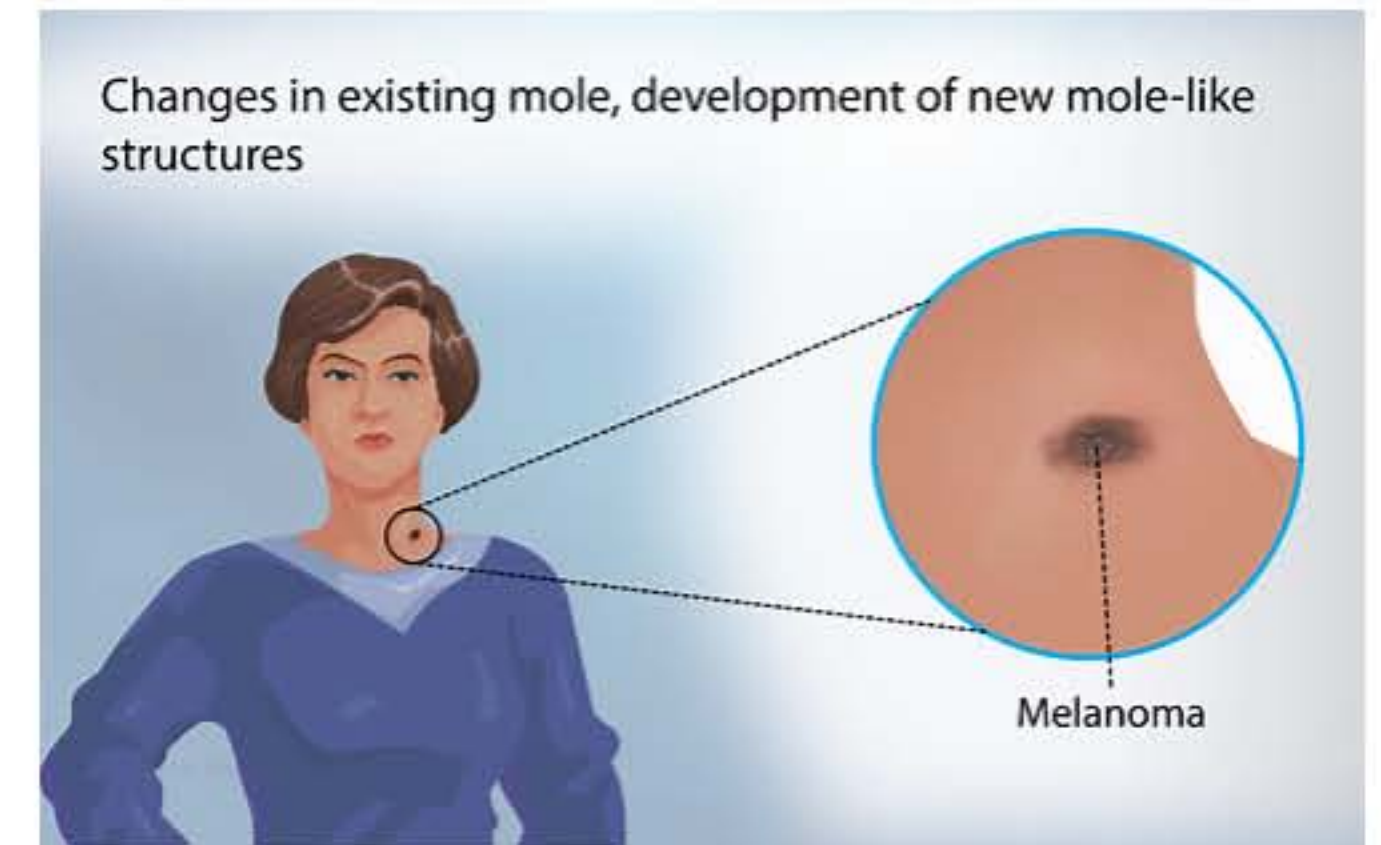
<https://www.ncbi.nlm.nih.gov/pubmed/31802836>

Nov 28, 2019 - **Primary gastric melanoma: A case report** with imaging findings and 5-year follow-up. ...
A 67-year-old **woman** presented to our hospital with recurrent chest tightness and chest pain. Digital gastrointestinal radiography revealed a circular shadow in the **gastric** cardia. Computed tomography (CT) revealed a heterogeneous tumor with uneven enhancement.

Cited by: 1 **Author:** Jian Wang, Fang Yang, Wei-Qun Ao, Cha...
Publish Year: 2019

Melanoma

Medical Condition



A type of skin cancer.

- Rare (Fewer than 200,000 cases per year in US)
- Not known to be contagious
- No vaccine available
- Often requires lab test or imaging
- Treatment from medical professional advised
- Can last several months

Exposure to ultra violet may increase the risk of developing the disease. Common symptoms include a rapid change in an existing mole, or an unusual growth on the skin. Early diagnosis and treatment is extremely important.