

World Journal of *Hepatology*

World J Hepatol 2020 November 27; 12(11): 883-1135



REVIEW

- 883** Malnutrition in cirrhosis: More food for thought
Chapman B, Sinclair M, Gow PJ, Testro AG

MINIREVIEWS

- 897** Paraneoplastic syndromes in cholangiocarcinoma
Rahman SU, Sana MK, Tahir Z, Ali A, Shah PA
- 908** Noninvasive scores for the prediction of esophageal varices and risk stratification in patients with cirrhosis
Bangaru S, Benhammou JN, Tabibian JH
- 919** Natrema and liver transplantation: The right amount of salt for a good recipe
Lenci I, Milana M, Grassi G, Signorello A, Aglitti A, Baiocchi L

ORIGINAL ARTICLE

Basic Study

- 931** Inhibition of vascular adhesion protein-1 modifies hepatic steatosis *in vitro* and *in vivo*
Shepherd EL, Karim S, Newsome PN, Lalor PF
- 949** Aceclofenac-induced hepatotoxicity: An ameliorative effect of *Terminalia bellirica* fruit and ellagic acid
Gupta A, Pandey A
- 965** Obeticholic acid attenuates human immunodeficiency virus/alcohol metabolism-induced pro-fibrotic activation in liver cells
New-Aaron M, Ganesan M, Dagur RS, Kharbanda KK, Poluektova LY, Osna NA
- 976** Screening and identification of bioactive compounds from citrus against non-structural protein 3 protease of hepatitis C virus genotype 3a by fluorescence resonance energy transfer assay and mass spectrometry
Khan M, Rauf W, Habib F, Rahman M, Iqbal M

Retrospective Cohort Study

- 993** Cannabis use history is associated with increased prevalence of ascites among patients with nonalcoholic fatty liver disease: A nationwide analysis
Choi CJ, Weiss SH, Nasir UM, Pyrsopoulos NT
- 1004** Phase angle and non-alcoholic fatty liver disease before and after bariatric surgery
Teixeira J, Marroni CA, Zubiaurre PR, Henz A, Faina L, Pinheiro LK, Mottin CC, Fernandes SA

Retrospective Study

- 1020** Factors associated with 5-year survival of combined hepatocellular and cholangiocarcinoma
Sempokuya T, Wien EA, Pattison RJ, Ma J, Wong LL
- 1031** Circulating miR-21-5p level has limited prognostic value in patients with hepatocellular carcinoma and is influenced by renal function
Franck M, Thon C, Schütte K, Malfertheiner P, Link A
- 1046** Real impact of tumor marker AFP and PIVKA-II in detecting very small hepatocellular carcinoma (≤ 2 cm, Barcelona stage 0) - assessment with large number of cases
Tarao K, Nozaki A, Komatsu H, Komatsu T, Taguri M, Tanaka K, Chuma M, Numata K, Maeda S
- 1055** Non-invasive splenic parameters of portal hypertension: Assessment and utility
Ahmad AK, Atzori S, Maurice J, Taylor-Robinson SD, Lim AKP
- 1067** Outcome of gastric antral vascular ectasia and related anemia after orthotopic liver transplantation
Emhmed Ali S, Benrajab KM, Dela Cruz AC

Clinical Trials Study

- 1076** Hepatitis B surface antigen and hepatitis B core-related antigen kinetics after adding pegylated-interferon to nucleos(t)ide analogues in hepatitis B e antigen-negative patients
Broquetas T, Garcia-Retortillo M, Micó M, Canillas L, Puigvehí M, Cañete N, Coll S, Viu A, Hernandez JJ, Bessa X, Carrión JA

Observational Study

- 1089** Occurrence of seeding metastases in resectable perihilar cholangiocarcinoma and the role of low-dose radiotherapy to prevent this
Franken LC, Roos E, Saris J, van Hooft JE, van Delden OM, Verheij J, Erdmann JI, Besselink MG, Busch OR, van Tienhoven G, van Gulik TM

Randomized Controlled Trial

- 1098** Metalloproteinase expression after desflurane preconditioning in hepatectomies: A randomized clinical trial
Koraki E, Mantzoros I, Chatzakis C, Gkiouliava A, Cheva A, Lavrentieva A, Sifaki F, Argiriadou H, Kesisoglou I, Galanos-Demiris K, Bitsianis S, Tsalis K

SYSTEMATIC REVIEWS

- 1115** Clinical utility of viscoelastic testing in chronic liver disease: A systematic review
Wei H, Child LJ

CASE REPORT

- 1128** Hepatocellular carcinoma with tumor thrombus extends to the right atrium and portal vein: A case report
Gomez-Puerto D, Mirallas O, Vidal-González J, Vargas V

ABOUT COVER

Associate editor of *World Journal of Hepatology*, Dr. Yong-Ping Yang is a Distinguished Professor at Peking University Health Science Center in Beijing, China. Having received his Bachelor's degree from Yanbian University in 1985, Dr. Yang undertook his postgraduate training at PLA Medical College, receiving his Master's degree in 1992. He rose to Chief Physician in the Hepatology Division of the Fifth Medical Center of the Chinese PLA General Hospital in 2003 and has held the position since. His ongoing research interests involve liver fibrosis, cirrhosis and hepatocellular carcinoma, with a particular focus on cryoablation and cryo-immunotherapy for hepatocellular carcinoma. Currently, he serves as Chairman of the Department of Liver Disease of the Chinese PLA General Hospital and as President of the Chinese Research Hospital Association for the Study of the Liver Disease. (L-Editor: Filipodia)

AIMS AND SCOPE

The primary aim of *World Journal of Hepatology* (*WJH*, *World J Hepatol*) is to provide scholars and readers from various fields of hepatology with a platform to publish high-quality basic and clinical research articles and communicate their research findings online.

WJH mainly publishes articles reporting research results and findings obtained in the field of hepatology and covering a wide range of topics including chronic cholestatic liver diseases, cirrhosis and its complications, clinical alcoholic liver disease, drug induced liver disease autoimmune, fatty liver disease, genetic and pediatric liver diseases, hepatocellular carcinoma, hepatic stellate cells and fibrosis, liver immunology, liver regeneration, hepatic surgery, liver transplantation, biliary tract pathophysiology, non-invasive markers of liver fibrosis, viral hepatitis.

INDEXING/ABSTRACTING

The *WJH* is now abstracted and indexed in PubMed, PubMed Central, Emerging Sources Citation Index (Web of Science), Scopus, China National Knowledge Infrastructure (CNKI), China Science and Technology Journal Database (CSTJ), and Superstar Journals Database.

RESPONSIBLE EDITORS FOR THIS ISSUE

Production Editor: Li-Li Wang; Production Department Director: Yun-Xiaojuan Wu; Editorial Office Director: Jia-Ping Yan.

NAME OF JOURNAL

World Journal of Hepatology

ISSN

ISSN 1948-5182 (online)

LAUNCH DATE

October 31, 2009

FREQUENCY

Monthly

EDITORS-IN-CHIEF

Nikolaos Pyrsopoulos, Ke-Qin Hu, Koo Jeong Kang

EDITORIAL BOARD MEMBERS

<https://www.wjnet.com/1948-5182/editorialboard.htm>

PUBLICATION DATE

November 27, 2020

COPYRIGHT

© 2020 Baishideng Publishing Group Inc

INSTRUCTIONS TO AUTHORS

<https://www.wjnet.com/bpg/gerinfo/204>

GUIDELINES FOR ETHICS DOCUMENTS

<https://www.wjnet.com/bpg/GerInfo/287>

GUIDELINES FOR NON-NATIVE SPEAKERS OF ENGLISH

<https://www.wjnet.com/bpg/gerinfo/240>

PUBLICATION ETHICS

<https://www.wjnet.com/bpg/GerInfo/288>

PUBLICATION MISCONDUCT

<https://www.wjnet.com/bpg/gerinfo/208>

ARTICLE PROCESSING CHARGE

<https://www.wjnet.com/bpg/gerinfo/242>

STEPS FOR SUBMITTING MANUSCRIPTS

<https://www.wjnet.com/bpg/GerInfo/239>

ONLINE SUBMISSION

<https://www.f6publishing.com>

Retrospective Study

Outcome of gastric antral vascular ectasia and related anemia after orthotopic liver transplantation

Saad Emhmed Ali, Karim M Benrajab, Anna Christina Dela Cruz

ORCID number: Saad Emhmed Ali 0000-0002-3481-0365; Karim M Benrajab 0000-0002-7988-1159; Anna Christina Dela Cruz 0000-0002-1083-096X.

Author contributions: Emhmed Ali S and Dela Cruz AC provided the conception and designed the study; Emhmed Ali S, Benrajab K and Dela Cruz AC analyzed and interpreted the data and wrote the manuscript; all authors have read and approved the final manuscript.

Institutional review board

statement: The study was reviewed and approved by the University of Kentucky Institutional Review Board (Approval No 54669).

Informed consent statement:

Patients were not required to give informed consent to the study because the analysis used anonymous clinical data that were obtained after each patient agreed to treatment by written consent.

Conflict-of-interest statement:

Authors have no relevant relationships or conflict of interest to disclose.

Data sharing statement: No additional data are available.

Open-Access: This article is an

Saad Emhmed Ali, Division of Hospital Medicine, Department of Internal Medicine, University of Kentucky College of Medicine, Lexington, KY 40536, United States

Karim M Benrajab, Anna Christina Dela Cruz, Division of Digestive Diseases and Nutrition, Department of Internal Medicine, University of Kentucky College of Medicine, Lexington, KY 40536, United States

Corresponding author: Karim M Benrajab, MD, Assistant Professor, Division of Digestive Diseases and Nutrition, Department of Internal Medicine, University of Kentucky College of Medicine, 800 Rose Street, MN649, Lexington, KY 40536, United States.

karimbenrajab@gmail.com

Abstract

BACKGROUND

Gastric antral vascular ectasia (GAVE) is a significant complication of cirrhosis. Numerous medical, surgical, and endoscopic treatment modalities have been proposed with varied satisfactory results. In a few small studies, GAVE and associated anemia have resolved after orthotopic liver transplantation (OLT).

AIM

To assess the impact of OLT on the resolution of GAVE and related anemia.

METHODS

We retrospectively reviewed clinical records of adult patients with GAVE who underwent OLT between September 2012 and September 2019. Demographics and other relevant clinical findings were collected, including hemoglobin levels and upper endoscopy findings before and after OLT. The primary outcome was the resolution of GAVE and its related anemia after OLT.

RESULTS

Sixteen patients were identified. Mean pre-OLT Hgb was 7.7 g/dL and mean 12 mo post-OLT Hgb was 11.9 g/dL, ($P = 0.001$). Anemia improved (defined as Hgb increased by 2g) in 87.5% of patients within 6 to 12 mo after OLT and resolved completely in half of the patients. Post-OLT esophagogastroduodenoscopy was performed in 10 patients, and GAVE was found to have resolved entirely in 6 of those patients (60%).

CONCLUSION

open-access article that was selected by an in-house editor and fully peer-reviewed by external reviewers. It is distributed in accordance with the Creative Commons Attribution NonCommercial (CC BY-NC 4.0) license, which permits others to distribute, remix, adapt, build upon this work non-commercially, and license their derivative works on different terms, provided the original work is properly cited and the use is non-commercial. See: <http://creativecommons.org/licenses/by-nc/4.0/>

Manuscript source: Unsolicited manuscript

Specialty type: Gastroenterology and hepatology

Country/Territory of origin: United States

Peer-review report's scientific quality classification

Grade A (Excellent): 0
Grade B (Very good): 0
Grade C (Good): C
Grade D (Fair): D
Grade E (Poor): 0

Received: July 27, 2020

Peer-review started: July 27, 2020

First decision: September 21, 2020

Revised: October 4, 2020

Accepted: October 26, 2020

Article in press: October 26, 2020

Published online: November 27, 2020

P-Reviewer: Coelho J, Manrai M

S-Editor: Zhang H

L-Editor: A

P-Editor: Xing YX



Although GAVE and associated anemia completely resolved in the majority of our patients after OLT, GAVE persisted in a few patients after transplant. Further studies in a large group of patients are necessary to understand the causality of disease and to better understand the factors associated with the persistence of GAVE post-transplant.

Key Words: Liver cirrhosis; Iron deficiency anemia; End-stage liver disease; Gastroscopy; Gastrointestinal hemorrhage; Liver transplantation

©The Author(s) 2020. Published by Baishideng Publishing Group Inc. All rights reserved.

Core Tip: In this retrospective study, cirrhotic patients who had gastric antral vascular ectasia (GAVE) with anemia and underwent orthotopic liver transplant (OLT) between September 2012 and September 2019 were reviewed to evaluate the impact of OLT on resolution of GAVE and associated anemia. A total of 296 patients underwent OLT during the study period; sixteen patients had GAVE. Anemia improved in the majority of patients in 6 to 12 mo post-OLT, and of the 10 patients who had a post-OLT esophagogastroduodenoscopy, GAVE was found to have completely resolved in 6 of those patients. We concluded that GAVE and associated anemia completely resolved in the majority of our patients post-OLT.

Citation: Emhmed Ali S, Benrajab KM, Dela Cruz AC. Outcome of gastric antral vascular ectasia and related anemia after orthotopic liver transplantation. *World J Hepatol* 2020; 12(11): 1067-1075

URL: <https://www.wjgnet.com/1948-5182/full/v12/i11/1067.htm>

DOI: <https://dx.doi.org/10.4254/wjh.v12.i11.1067>

INTRODUCTION

Gastric antral vascular ectasia (GAVE) is frequently found in patients with cirrhosis. The estimated prevalence in cirrhotic patients with upper gastrointestinal (GI) bleeding is around 6%, and in cirrhotic patients without apparent upper GI bleeding is about 12%^[1]. Another study found that GAVE was present in 1 in 40 of cirrhotic patients who underwent screening esophagogastroduodenoscopy (EGD) during liver transplant evaluation^[2]. The clinical presentation extends from occult hemorrhage to transfusion-dependent chronic iron deficiency anemia.

Diagnosed endoscopically, GAVE lesions are located primarily in the antrum of the stomach^[3] and appear as red spots that are either organized in stripes that project radially from the pylorus ("watermelon stomach")^[4,5], or organized in a diffuse punctate ("honeycomb") pattern^[6]. The exact etiology of GAVE remains unclear, although several hypotheses have been proposed, including mechanical stress, hemodynamic alterations, and humoral and autoimmune factors^[7-9]. Numerous medical, surgical, and endoscopic treatment modalities such as endoscopic band ligation, endoscopic thermal therapy with argon plasma coagulation (APC), and radiofrequency ablation have been proposed with varying satisfactory results^[10-15]. In a few small studies, GAVE and associated anemia have resolved after orthotopic liver transplantation (OLT)^[2,16,17].

The aim of this study was to further investigate the influence of OLT on the resolution of GAVE and associated anemia.

MATERIALS AND METHODS

A retrospective chart review was conducted of all adult patients with diagnosis of cirrhosis and GAVE who underwent OLT at the University of Kentucky Medical Center (UKMC) between September 2012 and September 2019. Patient demographics; body mass index (BMI); co-morbidities; Model of End-stage Liver Disease-sodium (MELD-Na) score at the time of GAVE diagnosis; etiology of cirrhosis; use of proton

pump inhibitors (PPI); GAVE presentation; type of endoscopic treatment utilized; lowest hemoglobin (Hgb) pre-OLT; hemoglobin at 3 mo, 6 mo, 9 mo, and 12 mo post-OLT; and post-OLT EGD findings were collected.

All the data mentioned above were collected from the patient's electronic medical records and stored in a password-protected excel sheet for analysis. The diagnosis of GAVE was obtained from the endoscopy reports. A single endoscopist/hepatologist independently reviewed all endoscopic images to confirm report findings. The primary outcome was the resolution of GAVE and associated anemia post-OLT.

This study was approved by the UKMC Institutional Review Board. No organs from executed prisoners were used.

RESULTS

Of 296 patients who underwent OLT during the study period, 16 (5.4%) had diagnosis of GAVE.

The individual patient cases are summarized in [Table 1](#). All Caucasians, with the majority being female (62.5%) with a mean age of 56.5 years and mean BMI of 31.6. The average MELD-Na score at the time of GAVE diagnosis was 20.4. The most common etiology of cirrhosis was Non-alcoholic steatohepatitis (NASH, 44%).

Twelve patients (75%) had concomitant portal hypertensive gastropathy, and 13 (81%) had chronic kidney disease (defined as a GFR < 60 mL/min/1.73 m² for > 3 mo).

Thirteen patients (81%) were on a PPI. All patients presented with anemia, with 50% have at least one episode of overt bleeding requiring a blood transfusion prior to transplant. Five of those without overt bleed had iron deficiency anemia. Half of the patients were treated endoscopically, with APC being the most common treatment (31%), and 25 % of patients underwent banding.

The pattern of GAVE varied in our patient cohort: Six patients had diffuse punctate GAVE ([Figure 1](#)), five patients had linear/striped pattern ([Figure 2](#)), two had patchy mild punctate GAVE, two patients had nodular polypoid GAVE characterized by polypoid lesions with exudate ([Figure 3](#)), and one had nodular striped GAVE ([Figure 4](#)). The patterns evolved in two patients, with the initial EGD showing a linear pattern and subsequent EGD showing a nodular/polypoid GAVE.

Mean pre-OLT Hgb was 7.7 g/dL compared to 11.9 g/dL at 12 mo post-OLT ($P = 0.001$). Anemia improved in 87.5 % (defined as Hgb increase by 2g) of patients ($n = 14$) & resolved entirely in 50 % of patients within 6 to 12 mo after OLT.

Only two patients required blood transfusion after three months post-transplant. One patient was five months, and the other patient was three years post-OLT; however, neither had evidence of bleeding.

Post-OLT EGD was performed in 10 patients. The mean time between OLT and post-OLT EGD was 27.9 mo. Among the 10 patients who underwent post-OLT EGD, GAVE was found to have resolved entirely in six patients (60%).

It is unclear why GAVE persisted in four out of ten patients who underwent post-OLT EGD. The first patient had psoriatic arthropathy. The second patient had GAVE sixteen years after transplant and had underlying polycythemia vera and chronic splenic thrombosis post-transplant with varices. The third patient had recurrent biopsy-proven cirrhosis. The fourth patient had persistent nodular GAVE, which required two endoscopic band ligations at two and ten weeks post-OLT with an endoscopic resolution of GAVE and associated anemia at six months post-OLT. The pattern of post-transplant GAVE varied in these four patients. Two patients had polypoid GAVE, one patient had linear GAVE, which later evolved into polypoid GAVE, and one patient had patchy mild punctate GAVE.

DISCUSSION

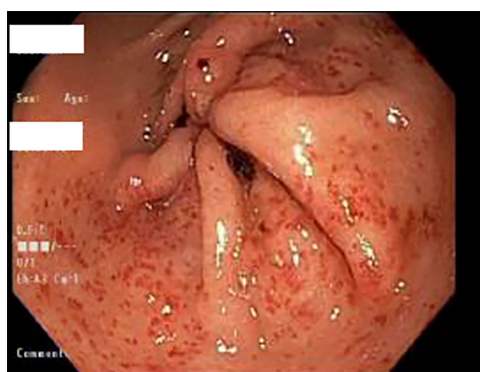
Gastric antral vascular ectasia is a common finding in patients with cirrhosis and often presents as chronic anemia. The endoscopic pathognomonic feature of GAVE is columns of red tortuous ectatic vessels along the folds of the antrum^[18]. Histologically, GAVE is characterized by mucosal vascular ectasia, spindle cell proliferation, fibrohyalinosis, and fibrin thrombi^[19]. It is a disease with focal distribution^[20]. Therefore, a negative biopsy does not rule out GAVE^[20].

Although GAVE has been historically described as a "watermelon stomach," the diffuse pattern of GAVE endoscopically was found to be more frequent in cirrhotic patients in one study^[5]. In contrast, the classic watermelon form was found to be more

Table 1 Clinical characteristics of patients with gastric antral vascular ectasia who underwent orthotopic liver transplantation

Patient No.	Age	Gender	BMI	Etiology of liver disease	MELD-Na score at GAVE diagnosis	Pre-OLT Hgb (g/dL)	GAVE pattern	Endoscopic therapy	Resolution of GAVE post-OLT
1	66	F	33.7	NASH	26	8	Diffuse punctate GAVE	APC	Yes
2	55	F	28	cryptogenic	15	8.7	Pre-OLT: Striped GAVE Post-OLT: Nodular polypoid GAVE with exudate	None	No
3	50	M	42.7	NASH	32	7	Linear/stripped GAVE	APC	Yes
4	57	F	32.9	cryptogenic	13	7.2	Striped and nodular GAVE	Banding	Yes
5	59	F	35.7	NASH	14	6.7	Pre and post-OLT: Nodular polypoid GAVE with exudate	Banding	No
6	51	M	23	Alcohol	30	7.1	Diffuse punctate GAVE	APC	Yes
7	51	M	27	NASH	23	7.2	Diffuse punctate GAVE	APC	Yes
8	57	F	22	Alcohol	23	7.5	Diffuse punctate GAVE	None	Yes
9	59	F	32.6	NASH	31	7.7	Diffuse punctate GAVE	Banding	Yes
10	40	M	36.6	Alcohol, HCV	Post-OLT diagnosis	6.9	Post-OLT: Linear striped; then polypoid GAVE	None	No
11	55	M	30.8	PSC	13	8.8	Nodular polypoid GAVE with exudate	None	Yes
12	58	M	17.8	Alcohol	12	7.3	Diffuse punctate GAVE	None	Yes
13	62	F	47.6	HCV	30	7.6	Linear/stripped GAVE	None	Yes
14	57	F	25.5	Budd Chiari syndrome	Post-OLT diagnosis		Post-OLT: Patchy mild punctate GAVE	None	No
15	67	F	35.5	NASH	15	9.6	Patchy mild punctate GAVE	None	Yes
16	60	F	32.5	NASH	8	7.5	Linear/stripped GAVE	APC	Yes

APC: Argon Plasma Coagulation; BMI: Body mass index; F: Female; GAVE: Gastric antral vascular ectasia; HCV: Hepatitis C virus; Hgb: Hemoglobin; M: Male; MELD-Na: Model for End-Stage Liver Disease- Sodium level; NASH: Non-alcoholic Steatohepatitis; OLT: Orthotopic liver transplantation; PSC: Primary sclerosing cholangitis.

**Figure 1 Endoscopic image showing a diffuse punctate pattern of gastric antral vascular ectasia.**

common in non-cirrhotic patients^[21]. In our cohort, 50% of patients were found to have diffuse punctate GAVE, 31% had a linear/stripped pattern, and 19% with nodular type. The gender distribution in our study seems to be similar to other studies. In our study, the cirrhotic GAVE patients were predominately female (62.5%) with a mean age of 56.2 years. Other studies have shown a female predominance (71%) of GAVE in cirrhotic patients with a mean age of 73 years, and a male predominance (75%) in non-

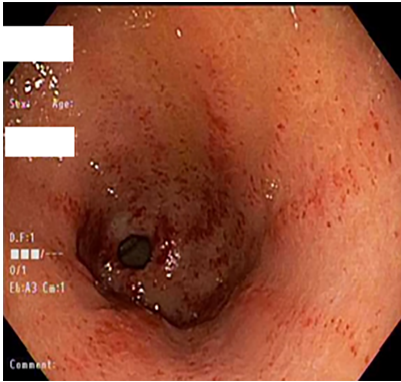


Figure 2 Endoscopic image showing a linear and striped pattern of gastric antral vascular ectasia.

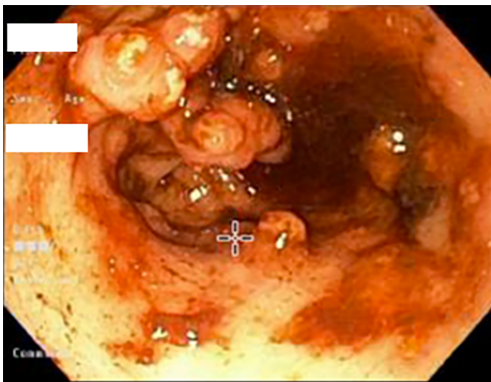


Figure 3 Endoscopic image showing a nodular polypoid pattern of gastric antral vascular ectasia.

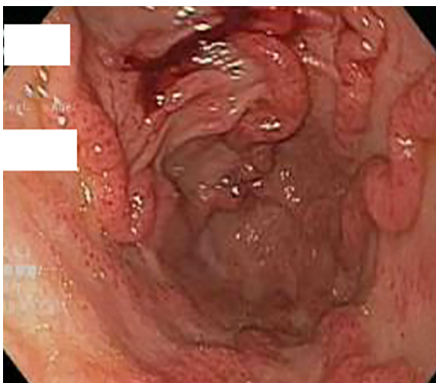


Figure 4 Endoscopic image showing a nodular and striped pattern of gastric antral vascular ectasia.

cirrhotic GAVE patients, with a mean age of 65 years^[22,23].

The exact pathophysiological mechanism that leads to GAVE remains unclear. It is highly essential to differentiate GAVE from portal hypertensive gastropathy (PHG) because they are treated differently. PHG mainly causes mucosal changes in the fundus and corpus^[20], whereas GAVE is limited to antrum^[18]. It is possible that portal hypertension has no significant role in the development of GAVE for several reasons, such as absence of correlation between the severity of portal hypertension and degree of vascular ectasia^[6], and non-resolution of GAVE after reduction in portal pressure^[23,24]. Quintero *et al*^[6] linked low levels of pepsinogen, high levels of gastrin, and achlorhydria, with GAVE, and other studies have reported improvement in GAVE and reduction in gastrin levels after cessation of proton pump inhibitor^[25]. In our study, 13 patients (81%) were taking proton pump inhibitors before and after OLT. Prostaglandin E2 has a gastric vasodilator effect and has been considered to play a role in the development of GAVE^[8]. Another study by Lowes *et al*^[7] found a proliferation of

neuroendocrine cells that secretes 5-hydroxytryptamine and vasoactive peptide close to the ectatic blood vessels. Mechanical stress theory has been suggested by Charneua *et al*^[9] to be playing a role in cirrhotic GAVE patients after they found abnormal motility patterns on antral motility studies. In non-cirrhotic GAVE patients, many other medical conditions have been described, such as autoimmune disease, acute myeloid leukemia, hypertension, chronic renal failure, ischemic heart disease, bone marrow transplantation, scleroderma, and familial Mediterranean fever^[22,26-28]. The most frequent associated autoimmune conditions are connective tissue diseases followed by Raynaud's phenomenon and sclerodactyly^[22].

Bleeding GAVE can be very problematic and challenging to manage. Several endoscopic interventions and medications are available^[10-15]. In three previous small studies, GAVE and associated anemia resolved after liver transplantation^[2,16,17]. Reduction in portal hypertension *via* medical use of beta-blockers or transjugular intrahepatic portosystemic shunt (TIPS) placement has failed to accomplish resolution of GAVE or associated anemia in cirrhotic patients with portal hypertension^[23,24]. None of our patients had TIPS before the diagnosis of GAVE. One patient had TIPS a month just before the transplant, and TIPS was done eighteen months after diagnosis of GAVE for refractory ascites. Before the transplant, eight of our patients underwent endoscopic treatment with APC as the most commonly used method. None of our patients received medical treatment, such as Tranexamic acid.

Our study further supports that GAVE in cirrhotic patients may resolve after OLT. Six out of ten patients who underwent post-OLT EGD have complete resolution of GAVE. The potential explanations for persistent GAVE among the other four patients include an underlying rheumatologic condition which can also cause non-cirrhotic GAVE in the first patient, underlying chronic splenic vein thrombosis in the second patient, recurrent cirrhosis in the third patient, and delayed resolution of GAVE after transplant since GAVE was seen fairly recently post-transplant, noted at two and ten weeks post-transplant with the resolution of anemia in the fourth patient.

The associated anemia entirely resolved in half of our patients and improved in 87.5% of patients six to twelve months after OLT. Anemia is common in cirrhotic patients; however, it is usually complex, and may be influenced by several factors, including etiology of cirrhosis and degree of portal hypertension^[29,30]. Portal hypertension and hypersplenism can be contributing factors to anemia in cirrhosis; however, the magnitude of the effect is unclear^[31,32]. Furthermore, Vincent *et al*^[17] reported resolution of GAVE and anemia in 2 patients post OLT even with persistent evidence of portal hypertension.

One would speculate that the associated resolution of liver dysfunction would lead to the resolution of GAVE after transplant. GAVE was frequently found in patients with more advanced liver disease and has been reported to resolve after liver transplantation^[2,16,17]. In our cohort at the time of GAVE diagnosis, the mean MELD-NA score was 20.4.

The limitations of the current study include retrospective design with a small sample size. EGDs were also performed by several different endoscopists performed EGDs; however, we attempted to control for this by having one endoscopist/hepatologist review all endoscopic images. Also, only 10 patients had undergone EGD post-OLT. The patients were not treated with the same endoscopic modality, and there was no established endoscopic protocol to eradicate GAVE. Indeed, there is usually no standard treatment modality since the type of endoscopic treatment will depend on the pattern of GAVE and previous endoscopic therapies, with the preferable use of banding for most patients with nodular GAVE and APC in all other patterns of GAVE (linear and punctate GAVE). Not all patients in our cohort had histologic confirmation of GAVE, and this could raise the possibility of overlap between GAVE and PHG. Despite these limitations, this study offers the largest number of patients with GAVE who underwent liver transplantation, and our findings corroborate those from previous studies showing that GAVE and associated anemia resolve in the majority of patients who underwent liver transplantation. It also further explored the possible underlying mechanisms for persistent GAVE after OLT in four out of ten patients who had post-OLT EGD.

CONCLUSION

GAVE is a significant cause of morbidity and mortality in patients with cirrhosis. Although GAVE and associated anemia completely resolved in the majority of our patients after liver transplantation, GAVE persisted in a few patients post-OLT. Large,

prospective studies using consistent diagnostic criteria for GAVE and planned follow-up EGDs after OLT are needed to better understand the factors may contribute to persistence of GAVE post-transplant.

ARTICLE HIGHLIGHTS

Research background

Gastric antral vascular ectasia (GAVE) is a well-recognized cause of gastrointestinal bleeding in cirrhotic patients. The etiology of GAVE remains unclear, although several humoral, autoimmune, mechanical stress, and pharmacological (proton pump inhibitor use) hypotheses have been described. Different treatment modalities have been proposed with varying results. Orthotopic liver transplantation (OLT), which is often recommended for patients with significant complications due to end-stage liver disease, has also been shown to be beneficial treatment for resolution of GAVE and associated anemia in a few small studies.

Research motivation

To evaluate the relation between GAVE and associated anemia and OLT.

Research objectives

To assess the impact of OLT on resolution of the natural course of GAVE and associated anemia.

Research methods

A retrospective chart review was conducted of adult patient with GAVE who underwent liver transplant between September 2012 and September 2019. Demographics and other relevant findings, including hemoglobin levels, Model of End-stage Liver Disease-sodium score, GAVE presentation, and upper endoscopy findings before and after OLT were collected.

Research results

Sixteen patients were identified, all Caucasians and predominantly female (62.5%) with a mean age of 56.5 years. The most common etiology for cirrhosis was NASH (44%). All patients presented with anemia, with 50% presenting with overt bleed and required transfusions prior to transplant. Mean pre-OLT Hgb was 7.7, and the mean 12 mo post-OLT Hgb was 11.9 ($P = 0.001$). Anemia improved in 87.5% of patients ($n = 14$) within 6 to 12 mo after OLT and resolved completely in half of the patients. Post-OLT esophagogastroduodenoscopy was performed in 10 patients, and GAVE resolved entirely in 6 of those patients (60%).

Research conclusions

Although GAVE and associated anemia completely resolved in the majority of our patients after liver transplantation, GAVE persisted in a few patients after transplant.

Research perspectives

Large prospective studies are needed to better understand what factors may contribute to persistent GAVE post-liver transplant.

REFERENCES

- Swanson E, Mahgoub A, MacDonald R, Shaukat A. Medical and endoscopic therapies for angiodysplasia and gastric antral vascular ectasia: a systematic review. *Clin Gastroenterol Hepatol* 2014; **12**: 571-582 [PMID: 24013107 DOI: 10.1016/j.cgh.2013.08.038]
- Ward EM, Raimondo M, Rosser BG, Wallace MB, Dickson RD. Prevalence and natural history of gastric antral vascular ectasia in patients undergoing orthotopic liver transplantation. *J Clin Gastroenterol* 2004; **38**: 898-900 [PMID: 15492609 DOI: 10.1097/00004836-200411000-00013]
- Stotzer PO, Willén R, Kilander AF. Watermelon stomach: not only an antral disease. *Gastrointest Endosc* 2002; **55**: 897-900 [PMID: 12024147 DOI: 10.1067/mge.2002.124558]
- Chatterjee S. Watermelon stomach. *CMAJ* 2008; **179**: 162 [PMID: 18625989 DOI: 10.1503/cmaj.080461]
- Ito M, Uchida Y, Kamano S, Kawabata H, Nishioka M. Clinical comparisons between two subsets of gastric antral vascular ectasia. *Gastrointest Endosc* 2001; **53**: 764-770 [PMID: 11375585 DOI: 10.1067/mge.2001.113922]

- 6 **Quintero E**, Pique JM, Bombi JA, Bordas JM, Sentis J, Elena M, Bosch J, Rodes J. Gastric mucosal vascular ectasias causing bleeding in cirrhosis. A distinct entity associated with hypergastrinemia and low serum levels of pepsinogen I. *Gastroenterology* 1987; **93**: 1054-1061 [PMID: [3498659](#) DOI: [10.1016/0016-5085\(87\)90569-5](#)]
- 7 **Lowes JR**, Rode J. Neuroendocrine cell proliferations in gastric antral vascular ectasia. *Gastroenterology* 1989; **97**: 207-212 [PMID: [2785944](#) DOI: [10.1016/0016-5085\(89\)91437-6](#)]
- 8 **Saperas E**, Perez Ayuso RM, Poca E, Bordas JM, Gaya J, Pique JM. Increased gastric PGE2 biosynthesis in cirrhotic patients with gastric vascular ectasia. *Am J Gastroenterol* 1990; **85**: 138-144 [PMID: [2301336](#)]
- 9 **Charneau J**, Petit R, Calès P, Dauver A, Boyer J. Antral motility in patients with cirrhosis with or without gastric antral vascular ectasia. *Gut* 1995; **37**: 488-492 [PMID: [7489933](#) DOI: [10.1136/gut.37.4.488](#)]
- 10 **Hsu WH**, Wang YK, Hsieh MS, Kuo FC, Wu MC, Shih HY, Wu IC, Yu FJ, Hu HM, Su YC, Wu DC. Insights into the management of gastric antral vascular ectasia (watermelon stomach). *Therap Adv Gastroenterol* 2018; **11**: 1756283X17747471 [PMID: [29399041](#) DOI: [10.1177/1756283X17747471](#)]
- 11 **Prachayakul V**, Aswakul P, Leelakusolvong S. Massive gastric antral vascular ectasia successfully treated by endoscopic band ligation as the initial therapy. *World J Gastrointest Endosc* 2013; **5**: 135-137 [PMID: [23515642](#) DOI: [10.4253/wjge.v5.i3.135](#)]
- 12 **Friedel D**. Potential role of new technological innovations in nonvariceal hemorrhage. *World J Gastrointest Endosc* 2019; **11**: 443-453 [PMID: [31523376](#) DOI: [10.4253/wjge.v11.i8.443](#)]
- 13 **Magee C**, Lipman G, Alzoubaidi D, Everson M, Sweis R, Banks M, Graham D, Gordon C, Lovat L, Murray C, Haidry R. Radiofrequency ablation for patients with refractory symptomatic anaemia secondary to gastric antral vascular ectasia. *United European Gastroenterol J* 2019; **7**: 217-224 [PMID: [31080606](#) DOI: [10.1177/2050640618814659](#)]
- 14 **Fuccio L**, Mussetto A, Laterza L, Eusebi LH, Bazzoli F. Diagnosis and management of gastric antral vascular ectasia. *World J Gastrointest Endosc* 2013; **5**: 6-13 [PMID: [23330048](#) DOI: [10.4253/wjge.v5.i1.6](#)]
- 15 **Chiu YC**, Lu LS, Wu KL, Tam W, Hu ML, Tai WC, Chiu KW, Chuah SK. Comparison of argon plasma coagulation in management of upper gastrointestinal angiodysplasia and gastric antral vascular ectasia hemorrhage. *BMC Gastroenterol* 2012; **12**: 67 [PMID: [22681987](#) DOI: [10.1186/1471-230X-12-67](#)]
- 16 **Allamneni C**, Alkurdi B, Naseemuddin R, McGuire BM, Shoreibah MG, Eckhoff DE, Peter S. Orthotopic liver transplantation changes the course of gastric antral vascular ectasia: a case series from a transplant center. *Eur J Gastroenterol Hepatol* 2017; **29**: 973-976 [PMID: [28520574](#) DOI: [10.1097/MEG.0000000000000908](#)]
- 17 **Vincent C**, Pomier-Layrargues G, Dagenais M, Lapointe R, Létourneau R, Roy A, Paré P, Huet PM. Cure of gastric antral vascular ectasia by liver transplantation despite persistent portal hypertension: a clue for pathogenesis. *Liver Transpl* 2002; **8**: 717-720 [PMID: [12149766](#) DOI: [10.1053/jlts.2002.34382](#)]
- 18 **Novitsky YW**, Kercher KW, Czerniach DR, Litwin DE. Watermelon stomach: pathophysiology, diagnosis, and management. *J Gastrointest Surg* 2003; **7**: 652-661 [PMID: [12850679](#) DOI: [10.1016/S1091-255X\(02\)00435-3](#)]
- 19 **Payen JL**, Calès P, Voigt JJ, Barbe S, Pilette C, Dubuisson L, Desmorat H, Vinel JP, Kervran A, Chayvialle JA. Severe portal hypertensive gastropathy and antral vascular ectasia are distinct entities in patients with cirrhosis. *Gastroenterology* 1995; **108**: 138-144 [PMID: [7806035](#) DOI: [10.1016/0016-5085\(95\)90018-7](#)]
- 20 **Burak KW**, Lee SS, Beck PL. Portal hypertensive gastropathy and gastric antral vascular ectasia (GAVE) syndrome. *Gut* 2001; **49**: 866-872 [PMID: [11709525](#) DOI: [10.1136/gut.49.6.866](#)]
- 21 **Chaves DM**, Sakai P, Oliveira CV, Cheng S, Ishioka S. Watermelon stomach: clinical aspects and treatment with argon plasma coagulation. *Arg Gastroenterol* 2006; **43**: 191-195 [PMID: [17160233](#) DOI: [10.1590/S0004-28032006000300007](#)]
- 22 **Gostout CJ**, Viggiano TR, Ahlquist DA, Wang KK, Larson MV, Balm R. The clinical and endoscopic spectrum of the watermelon stomach. *J Clin Gastroenterol* 1992; **15**: 256-263 [PMID: [1479175](#) DOI: [10.1097/00004836-199210000-00019](#)]
- 23 **Spahr L**, Villeneuve JP, Dufresne MP, Tassé D, Bui B, Willems B, Fenyves D, Pomier-Layrargues G. Gastric antral vascular ectasia in cirrhotic patients: absence of relation with portal hypertension. *Gut* 1999; **44**: 739-742 [PMID: [10205216](#) DOI: [10.1136/gut.44.5.739](#)]
- 24 **Kamath PS**, Lacerda M, Ahlquist DA, McKusick MA, Andrews JC, Nagorney DA. Gastric mucosal responses to intrahepatic portosystemic shunting in patients with cirrhosis. *Gastroenterology* 2000; **118**: 905-911 [PMID: [10784589](#) DOI: [10.1016/S0016-5085\(00\)70176-4](#)]
- 25 **Nakade Y**, Ozeki T, Kanamori H, Inoue T, Yamamoto T, Kobayashi Y, Ishii N, Ohashi T, Ito K, Yoneda M. A Case of Gastric Antral Vascular Ectasia Which Was Aggravated by Acid Reducer. *Case Rep Gastroenterol* 2017; **11**: 64-71 [PMID: [28611555](#) DOI: [10.1159/000455967](#)]
- 26 **Tobin RW**, Hackman RC, Kimmey MB, Durtschi MB, Hayashi A, Malik R, McDonald MF, McDonald GB. Bleeding from gastric antral vascular ectasia in marrow transplant patients. *Gastrointest Endosc* 1996; **44**: 223-229 [PMID: [8885337](#) DOI: [10.1016/S0016-5107\(96\)70155-4](#)]
- 27 **Sebastian S**, O'Morain CA, Buckley MJ. Review article: current therapeutic options for gastric antral vascular ectasia. *Aliment Pharmacol Ther* 2003; **18**: 157-165 [PMID: [12869075](#) DOI: [10.1046/j.1365-2036.2003.01617.x](#)]
- 28 **Takahashi T**, Miya T, Oki M, Sugawara N, Yoshimoto M, Tsujisaki M. Severe hemorrhage from gastric vascular ectasia developed in a patient with AML. *Int J Hematol* 2006; **83**: 467-468 [PMID: [16787883](#) DOI: [10.1532/IJH97.06052](#)]
- 29 **Singh S**, Manrai M, V S P, Kumar D, Srivastava S, Pathak B. Association of liver cirrhosis severity with anemia: does it matter? *Ann Gastroenterol* 2020; **33**: 272-276 [PMID: [32382230](#) DOI: [10.20524/aog.2020.0478](#)]
- 30 **Peck-Radosavljevic M**. Hypersplenism. *Eur J Gastroenterol Hepatol* 2001; **13**: 317-323 [PMID: [11338057](#) DOI: [10.1097/00042737-200104000-00004](#)]
- 31 **DuBois B**, Mobley D, Chick JFB, Srinivasa RN, Wilcox C, Weintraub J. Efficacy and safety of partial splenic embolization for hypersplenism in pre- and post-liver transplant patients: A 16-year comparative analysis. *Clin Imaging* 2019; **54**: 71-77 [PMID: [30553121](#) DOI: [10.1016/j.clinimag.2018.11.012](#)]

- 32 **Zhu J**, Chen X, Hu X, Zhu H, He C. A Comparative Study of Surgical Splenectomy, Partial Splenic Embolization, and High-Intensity Focused Ultrasound for Hypersplenism. *J Ultrasound Med* 2016; **35**: 467-474 [PMID: [26839374](#) DOI: [10.7863/ultra.15.03050](#)]



Published by **Baishideng Publishing Group Inc**
7041 Koll Center Parkway, Suite 160, Pleasanton, CA 94566, USA

Telephone: +1-925-3991568

E-mail: bpgoffice@wjgnet.com

Help Desk: <https://www.f6publishing.com/helpdesk>

<https://www.wjgnet.com>

