

World Journal of *Clinical Cases*

World J Clin Cases 2020 December 26; 8(24): 6213-6545



MINIREVIEWS

- 6213 Role of gut microbiome in regulating the effectiveness of metformin in reducing colorectal cancer in type 2 diabetes

Huang QY, Yao F, Zhou CR, Huang XY, Wang Q, Long H, Wu QM

ORIGINAL ARTICLE

Retrospective Cohort Study

- 6229 Impact factors of lymph node retrieval on survival in locally advanced rectal cancer with neoadjuvant therapy

Mei SW, Liu Z, Wang Z, Pei W, Wei FZ, Chen JN, Wang ZJ, Shen HY, Li J, Zhao FQ, Wang XS, Liu Q

Retrospective Study

- 6243 Three-year follow-up of Coats disease treated with conbercept and 532-nm laser photocoagulation

Jiang L, Qin B, Luo XL, Cao H, Deng TM, Yang MM, Meng T, Yang HQ

- 6252 Virus load and virus shedding of SARS-CoV-2 and their impact on patient outcomes

Chen PF, Yu XX, Liu YP, Ren D, Shen M, Huang BS, Gao JL, Huang ZY, Wu M, Wang WY, Chen L, Shi X, Wang ZQ, Liu YX, Liu L, Liu Y

- 6264 Risk factors for *de novo* hepatitis B during solid cancer treatment

Sugimoto R, Furukawa M, Senju T, Aratake Y, Shimokawa M, Tanaka Y, Inada H, Noguchi T, Lee L, Miki M, Maruyama Y, Hashimoto R, Hisano T

- 6274 Cause analysis and reoperation effect of failure and recurrence after epiblepharon correction in children

Wang Y, Zhang Y, Tian N

Clinical Trials Study

- 6282 Effects of different acupuncture methods combined with routine rehabilitation on gait of stroke patients

Lou YT, Yang JJ, Ma YF, Zhen XC

Observational Study

- 6296 Application of endoscopic submucosal dissection in duodenal space-occupying lesions

Li XY, Ji KY, Qu YH, Zheng JJ, Guo YJ, Zhang CP, Zhang KP

- 6306 Early renal injury indicators can help evaluate renal injury in patients with chronic hepatitis B with long-term nucleos(t)ide therapy

Ji TT, Tan N, Lu HY, Xu XY, Yu YY

Prospective Study

- 6315** Neoadjuvant chemoradiotherapy plus surgery in the treatment of potentially resectable thoracic esophageal squamous cell carcinoma
Yan MH, Hou XB, Cai BN, Qu BL, Dai XK, Liu F

CASE REPORT

- 6322** Uterine rupture in patients with a history of multiple curettages: Two case reports
Deng MF, Zhang XD, Zhang QF, Liu J
- 6330** Pleural effusion and ascites in extrarenal lymphangiectasia caused by post-biopsy hematoma: A case report
Lin QZ, Wang HE, Wei D, Bao YF, Li H, Wang T
- 6337** Eighty-year-old man with rare chronic neutrophilic leukemia caused by CSF3R T618I mutation: A case report and review of literature
Li YP, Chen N, Ye XM, Xia YS
- 6346** Sigmoid colon duplication with ectopic immature renal tissue in an adult: A case report
Namgung H
- 6353** Paraplegia from spinal intramedullary tuberculosis: A case report
Qu LM, Wu D, Guo L, Yu JL
- 6358** Confocal laser endomicroscopy distinguishing benign and malignant gallbladder polyps during choledochoscopic gallbladder-preserving polypectomy: A case report
Tang BF, Dang T, Wang QH, Chang ZH, Han WJ
- 6364** Sclerosing stromal tumor of the ovary with masculinization, Meig's syndrome and CA125 elevation in an adolescent girl: A case report
Chen Q, Chen YH, Tang HY, Shen YM, Tan X
- 6373** Primary pulmonary malignant melanoma diagnosed with percutaneous biopsy tissue: A case report
Xi JM, Wen H, Yan XB, Huang J
- 6380** SRY-negative 45,X/46,XY adult male with complete masculinization and infertility: A case report and review of literature
Wu YH, Sun KN, Bao H, Chen YJ
- 6389** Refractory case of ulcerative colitis with idiopathic thrombocytopenic purpura successfully treated by Janus kinase inhibitor tofacitinib: A case report
Komeda Y, Sakurai T, Sakai K, Morita Y, Hashimoto A, Nagai T, Hagiwara S, Matsumura I, Nishio K, Kudo M
- 6396** Immunotherapies application in active stage of systemic lupus erythematosus in pregnancy: A case report and review of literature
Xiong ZH, Cao XS, Guan HL, Zheng HL

- 6408** Minimally invasive maxillary sinus augmentation with simultaneous implantation on an elderly patient: A case report
Yang S, Yu W, Zhang J, Zhou Z, Meng F, Wang J, Shi R, Zhou YM, Zhao J
- 6418** Congenital nephrogenic diabetes insipidus due to the mutation in *AVPR2* (c.541C>T) in a neonate: A case report
Lin FT, Li J, Xu BL, Yang XX, Wang F
- 6425** Primary gastric melanoma in a young woman: A case report
Long GJ, Ou WT, Lin L, Zhou CJ
- 6432** Extreme venous letting and cupping resulting in life-threatening anemia and acute myocardial infarction: A case report
Jang AY, Suh SY
- 6437** Novel conservative treatment for peritoneal dialysis-related hydrothorax: Two case reports
Dai BB, Lin BD, Yang LY, Wan JX, Pan YB
- 6444** Clinical characteristics of pulmonary cryptococcosis coexisting with lung adenocarcinoma: Three case reports
Zheng GX, Tang HJ, Huang ZP, Pan HL, Wei HY, Bai J
- 6450** Fracture of the scapular neck combined with rotator cuff tear: A case report
Chen L, Liu CL, Wu P
- 6456** Synchronous colonic mucosa-associated lymphoid tissue lymphoma found after surgery for adenocarcinoma: A case report and review of literature
Li JJ, Chen BC, Dong J, Chen Y, Chen YW
- 6465** Novel mutation in the *ASXL3* gene in a Chinese boy with microcephaly and speech impairment: A case report
Li JR, Huang Z, Lu Y, Ji QY, Jiang MY, Yang F
- 6473** Recurrent thrombosis in the lower extremities after thrombectomy in a patient with polycythemia vera: A case report
Jiang BP, Cheng GB, Hu Q, Wu JW, Li XY, Liao S, Wu SY, Lu W
- 6480** Status epilepticus as an initial manifestation of hepatic encephalopathy: A case report
Cui B, Wei L, Sun LY, Qu W, Zeng ZG, Liu Y, Zhu ZJ
- 6487** Delayed diagnosis of prosopagnosia following a hemorrhagic stroke in an elderly man: A case report
Yuan Y, Huang F, Gao ZH, Cai WC, Xiao JX, Yang YE, Zhu PL
- 6499** Oral myiasis after cerebral infarction in an elderly male patient from southern China: A case report
Zhang TZ, Jiang Y, Luo XT, Ling R, Wang JW
- 6504** Rare case of drain-site hernia after laparoscopic surgery and a novel strategy of prevention: A case report
Gao X, Chen Q, Wang C, Yu YY, Yang L, Zhou ZG

- 6511** Extracorporeal shock wave therapy treatment of painful hematoma in the calf: A case report
Jung JW, Kim HS, Yang JH, Lee KH, Park SB
- 6517** Takotsubo cardiomyopathy associated with bronchoscopic operation: A case report
Wu BF, Shi JR, Zheng LR
- 6524** Idiopathic adulthood ductopenia with elevated transaminase only: A case report
Zhang XC, Wang D, Li X, Hu YL, Wang C
- 6529** Successful endovascular treatment with long-term antibiotic therapy for infectious pseudoaneurysm due to *Klebsiella pneumoniae*: A case report
Wang TH, Zhao JC, Huang B, Wang JR, Yuan D
- 6537** Primary duodenal tuberculosis misdiagnosed as tumor by imaging examination: A case report
Zhang Y, Shi XJ, Zhang XC, Zhao XJ, Li JX, Wang LH, Xie CE, Liu YY, Wang YL

ABOUT COVER

Peer-Reviewer of *World Journal of Clinical Cases*, Dr. Adonis Protopapas is a gastroenterology Resident at the first Propaedeutic Department of Internal Medicine of the Aristotle University of Thessaloniki (Greece), located at the A.H.E.P.A Hospital. He earned his Bachelor's degree in 2015 from the Democritus University of Thrace, followed by three Master's of Science degrees, with specializations in clinic pharmacology, medical research methodology, and healthcare management. His research interests are mainly focused on the area of hepatology, although he also participates in various projects related to endoscopy and inflammatory bowel disease. He is particularly fascinated by research on cirrhosis and its complications. (L-Editor: Filipodia)

AIMS AND SCOPE

The primary aim of *World Journal of Clinical Cases* (*WJCC*, *World J Clin Cases*) is to provide scholars and readers from various fields of clinical medicine with a platform to publish high-quality clinical research articles and communicate their research findings online.

WJCC mainly publishes articles reporting research results and findings obtained in the field of clinical medicine and covering a wide range of topics, including case control studies, retrospective cohort studies, retrospective studies, clinical trials studies, observational studies, prospective studies, randomized controlled trials, randomized clinical trials, systematic reviews, meta-analysis, and case reports.

INDEXING/ABSTRACTING

The *WJCC* is now indexed in Science Citation Index Expanded (also known as SciSearch®), Journal Citation Reports/Science Edition, PubMed, and PubMed Central. The 2020 Edition of Journal Citation Reports® cites the 2019 impact factor (IF) for *WJCC* as 1.013; IF without journal self cites: 0.991; Ranking: 120 among 165 journals in medicine, general and internal; and Quartile category: Q3.

RESPONSIBLE EDITORS FOR THIS ISSUE

Production Editor: Ji-Hong Liu; Production Department Director: Xiang Li; Editorial Office Director: Jin-Lai Wang.

NAME OF JOURNAL

World Journal of Clinical Cases

ISSN

ISSN 2307-8960 (online)

LAUNCH DATE

April 16, 2013

FREQUENCY

Semimonthly

EDITORS-IN-CHIEF

Dennis A Bloomfield, Sandro Vento, Bao-gan Peng

EDITORIAL BOARD MEMBERS

<https://www.wjgnet.com/2307-8960/editorialboard.htm>

PUBLICATION DATE

December 26, 2020

COPYRIGHT

© 2020 Baishideng Publishing Group Inc

INSTRUCTIONS TO AUTHORS

<https://www.wjgnet.com/bpg/gerinfo/204>

GUIDELINES FOR ETHICS DOCUMENTS

<https://www.wjgnet.com/bpg/GerInfo/287>

GUIDELINES FOR NON-NATIVE SPEAKERS OF ENGLISH

<https://www.wjgnet.com/bpg/gerinfo/240>

PUBLICATION ETHICS

<https://www.wjgnet.com/bpg/GerInfo/288>

PUBLICATION MISCONDUCT

<https://www.wjgnet.com/bpg/gerinfo/208>

ARTICLE PROCESSING CHARGE

<https://www.wjgnet.com/bpg/gerinfo/242>

STEPS FOR SUBMITTING MANUSCRIPTS

<https://www.wjgnet.com/bpg/GerInfo/239>

ONLINE SUBMISSION

<https://www.f6publishing.com>



Extreme venous letting and cupping resulting in life-threatening anemia and acute myocardial infarction: A case report

Albert Youngwoo Jang, Soon Yong Suh

ORCID number: Albert Youngwoo Jang [0000-0002-8802-268X](https://orcid.org/0000-0002-8802-268X); Soon Yong Suh [0000 0001 9007 7535](https://orcid.org/0000-0001-9007-7535).

Author contributions: Jang AY and Suh SY were the patient's interventionists; they reviewed the literature and contributed to drafting, writing, editing, and revising the manuscript; all authors issued final approval of the version to be submitted.

Informed consent statement:

Written informed consent was obtained from the patient for the publication of this report and any accompanying images.

Conflict-of-interest statement: The authors declare that they have no conflicts of interest.

CARE Checklist (2016) statement:

The authors have read the CARE Checklist (2016), and the manuscript was prepared and revised according to the CARE Checklist (2016).

Open-Access: This article is an open-access article that was selected by an in-house editor and fully peer-reviewed by external reviewers. It is distributed in accordance with the Creative Commons Attribution NonCommercial (CC BY-NC 4.0) license, which permits others to distribute, remix, adapt, build

Albert Youngwoo Jang, Department of Cardiology, Gachon University Gil Medical Center, Incheon 21565, South Korea

Soon Yong Suh, Department of Cardiology, Gachon University Gil Hospital, Incheon 21565, South Korea

Corresponding author: Soon Yong Suh, MD, PhD, Associate Professor, Department of Cardiology, Gachon University Gil Hospital, 21, Namdong-daero 774 beon-gil, Namdong-gu, Incheon 21565, South Korea. ssy@gilhospital.com

Abstract

BACKGROUND

Wet cupping (WC) is a traditional therapy of skin suction-assisted bloodletting that is widely used in modern alternative medicine in Asia and the Middle East. Herein, we report the case of a male who presented with ST-elevation myocardial infarction (STEMI) and life-threatening anemia and underwent excessive WC.

CASE SUMMARY

A 55-year-old male presented with chest pain (30 min) and dyspnea (3 wk). His initial electrocardiogram suggested STEMI in the anterior wall. Furthermore, his laboratory results showed severe anemia with a hemoglobin level of 4.1 g/dL. Of note, the patient underwent regular WC therapy for chronic back pain, which he had recently intensified. His WC practice resulted in life-threatening anemia and eventually STEMI. Percutaneous coronary intervention in the left anterior descending artery was performed to treat the STEMI. His dyspnea dramatically improved after the transfusion, and his hemoglobin level returned to 14.8 g/dL within 2 mo after discharge. He has been uneventful for the last seven years of follow-up.

CONCLUSION

The current case demonstrates that excessive WC without adequate medical monitoring can result in severe anemia, which can further develop into STEMI.

Key Words: Bloodletting; ST-elevation myocardial infarction; Anemia; Cupping; Wet cupping; Case report

©The Author(s) 2020. Published by Baishideng Publishing Group Inc. All rights reserved.

upon this work non-commercially, and license their derivative works on different terms, provided the original work is properly cited and the use is non-commercial. See: <http://creativecommons.org/licenses/by-nc/4.0/>

Manuscript source: Unsolicited manuscript

Specialty type: Medicine, research and experimental

Country/Territory of origin: South Korea

Peer-review report's scientific quality classification

Grade A (Excellent): 0
Grade B (Very good): 0
Grade C (Good): C, C
Grade D (Fair): 0
Grade E (Poor): 0

Received: July 28, 2020

Peer-review started: July 28, 2020

First decision: September 24, 2020

Revised: October 7, 2020

Accepted: November 14, 2020

Article in press: November 14, 2020

Published online: December 26, 2020

P-Reviewer: Saad K

S-Editor: Fan JR

L-Editor: A

P-Editor: Ma YJ



Core Tip: Wet cupping (WC) is a traditional therapy for promoting bloodletting by applying subatmospheric pressure to a glass cup attached to a skin-pricked, bleeding lesion. Herein, we report a man who self-performed excessive WC and presented with ST-elevation myocardial infarction and life-threatening anemia.

Citation: Jang AY, Suh SY. Extreme venous letting and cupping resulting in life-threatening anemia and acute myocardial infarction: A case report. *World J Clin Cases* 2020; 8(24): 6432-6436

URL: <https://www.wjgnet.com/2307-8960/full/v8/i24/6432.htm>

DOI: <https://dx.doi.org/10.12998/wjcc.v8.i24.6432>

INTRODUCTION

Wet cupping (WC) is one of the most widely used traditional therapies for musculoskeletal pain or headache that is performed in the Middle East, Asia, and Europe^[1]. WC promotes bloodletting by applying subatmospheric pressure to a glass cup attached to a skin-pricked, bleeding lesion^[1]. Herein, we report a man who self-performed excessive WC and presented with ST-elevation myocardial infarction (STEMI) and life-threatening anemia.

CASE PRESENTATION

Chief complaints

A 55-year-old male presented to the emergency department with chest pain and dyspnea.

History of present illness

The patient had a history of smoking (30 pack years). He had been experiencing dyspnea for 3 wk prior and his chest pain started 30 min before arrival, with a numeric rating scale score of seven.

History of past illness

The patient had a history of hypertension.

Physical examination

The patient was pale and had anemic conjunctiva. His initial blood pressure was 90/60 mmHg with a heart rate of 114 beats per minute.

Electrocardiogram

An electrocardiogram showed ST segment elevation in leads V1 to V3 and reciprocal changes in leads II, III, and aVF, suggestive of STEMI.

Laboratory examinations

The patient was moved to the catheter lab for emergent percutaneous coronary intervention (PCI) before the laboratory results were available because of the strict door-to-balloon time regulations in Korea.

Imaging examinations

Coronary angiography revealed 99% stenosis of the proximal left anterior descending (LAD) artery caused by a ruptured plaque, with distal thrombolysis in myocardial infarction flow 3 (Figure 1A-C). A drug-eluting stent (Ciloxan™ 3.5 mm × 15 mm) was inserted into the LAD lesion without complications. Consistently low blood pressure was noted during and after PCI.

Further diagnostic work-up

After PCI, the patient's chest pain was improved, although his dyspnea remained. The lab results were reported after PCI, and cardiac markers were increased as expected.

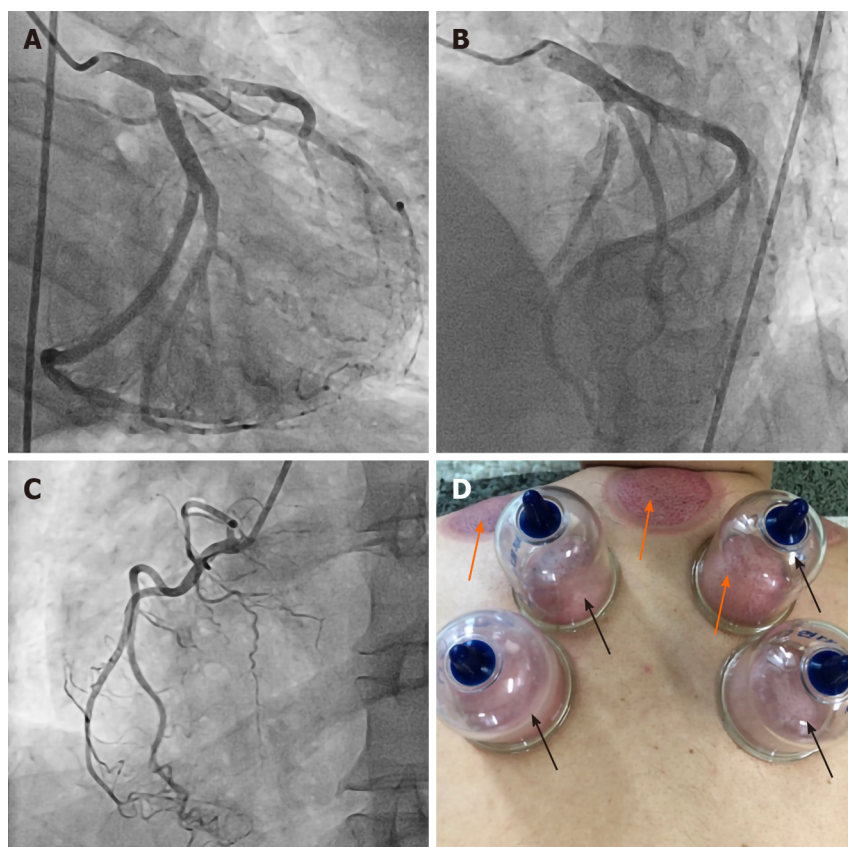


Figure 1 Images of coronary angiography and an illustration of wet cupping. A-C: Coronary angiographic images of the left and right coronary arteries; A and B: A ruptured plaque is observed in the proximal left anterior descending artery; D: A picture of cupping; plastic cups (black arrows) are attached to skin using air suction to create subatmospheric pressure. Skin pricking precedes this process in wet cupping (WC), which facilitates bloodletting. Bruises (orange arrows) develop after WC.

Strikingly, however, the hemoglobin (Hb) level was 4.1 g/dL. Rectal digital tests and nasogastric tube aspiration examinations were negative, ruling out gastrointestinal tract bleeding. Furthermore, his low-density lipoprotein cholesterol level was only 66 mg/dL. Upon careful history taking, we learned that the patient regularly self-performed WC therapy. He had recently intensified his WC routine by implementing it more frequently, which may have led to an excessive loss of blood. We further checked his iron and ferritin levels and total iron binding capacity (TIBC), which showed a typical pattern of iron deficiency anemia (iron, 16 $\mu\text{mol/L}$; ferritin, 2.3 $\mu\text{g/L}$; TIBC, 374 $\mu\text{mol/L}$). The initial echocardiography showed akinetic regional wall motion abnormalities in the LAD territory, although the contractile motion of other territories was hyperdynamic.

MULTIDISCIPLINARY EXPERT CONSULTATION

Junshik Hong, MD, Associate Professor, Department of Hematology, Seoul National University Hospital

We consulted with Dr. Hong, who determined that the patient should be immediately transfused and given iron supplements for iron deficiency anemia.

FINAL DIAGNOSIS

The final diagnosis of the presented case was anemia due to excessive WC. The patient also developed STEMI, which was possibly induced by vigorous heart contractions compensating for the poor blood supply caused by life-threatening anemia.

TREATMENT

A transfusion was immediately initiated, while concurrent iron supplementation was performed after consultation with hematology. Four packed red blood cells were transfused. After transfusion, the patient's dyspnea was dramatically ameliorated and his hypotension recovered to normal blood pressure (120/80 mmHg). His Hb was 7.9 g/dL when he was discharged 2 d post-PCI. We also educated the patient regarding the consequences of unmonitored WC. Iron supplementation was maintained for the next 2 mo. Dual-antiplatelet therapy, angiotensin-converting enzyme inhibitors, beta-blockers, and statins were also given.

OUTCOME AND FOLLOW-UP

Two months after PCI, during his outpatient department visit, the patient's Hb level had increased to 14.8 g/dL and his symptoms were completely alleviated. He no longer performs WC to this day and has been uneventful for the last seven years. A timeline of the patient's disease course is shown in [Table 1](#).

DISCUSSION

WC therapy is the application of subatmospheric pressure to a skin-attached glass or plastic cup after pricking precise acupuncture points or painful areas ([Figure 1D](#))^[1]. The intensity of bruises and the amount of suctioned blood are dependent on the strength of the negative pressure applied. Such practices were traditionally performed in Asia, the Middle East, and Europe with great popularity because they were thought to remove harmful blood or toxins that were causative of diseases^[1]. Even today, WC is widely performed in Asia and the Middle East in the field of alternative medicine for chronic musculoskeletal pain. Although several small, modern studies have investigated the therapeutic efficacy of WC, the benefits remain relatively unknown^[2].

The patient in our study practiced regular WC for his chronic upper back pain. He also stated that as his shortness of breath developed, he had more frequently performed WC during the 3 wk prior to admission because he thought that it would improve his symptoms. Considering that his dyspnea may have developed with decreased cardiac output due to blood loss, his intensified bloodletting may have aggravated his heart failure to a further extent. Furthermore, vigorous heart contractility to compensate for the loss of preload may also have facilitated the imbalance between the patient's myocardial supply and consumption.

Anemia is a well-established risk factor for future adverse events in patients with acute coronary syndrome, stroke, and heart failure^[2,3]. Although whether anemia leads to the formation of atherosclerosis is relatively undiscovered, an intravascular ultrasound study revealed that anemia was independently associated with thin-cap fibroatheroma, which is thought to be impending plaque rupture^[4]. The mechanism of this finding has not been elucidated; however, it has been demonstrated that hypovolemia-induced hypernatremia leads to chronic inflammation and the development of atherosclerosis^[5]. Considering that the patient had relatively low levels of low-density lipoprotein and triglycerides, it is conceivable that other mechanisms, anemia in this case, may have played a major role in the development of atherosclerosis and the rupture of plaque. The dehydrated state of the patient may have promoted systemic inflammation, further leading to the formation of a vulnerable plaque and the subsequent rupture that caused the STEMI^[5].

CONCLUSION

The current case demonstrates that excessive WC without adequate medical monitoring can result in severe anemia, which can further develop into life-threatening myocardial infarction.

Table 1 A timeline of events: Symptoms, diagnosis, and treatment

Event	Timeline
Chest pain and ER presentation	Day 1
PCI to proximal LAD	Day 1
Initial Hb level checked (4.1 g/dL)	Day 1
Transfusion and iron supplementation	Day 1
Discharge (Hb: 7.9 g/dL)	Day 3
Outpatient department visit (Hb: 14.8 g/dL)	Day 63

ER: Emergency room; PCI: Percutaneous coronary intervention; LAD: Left anterior descending; Hb: Hemoglobin.

ACKNOWLEDGEMENTS

We thank Professor Junshik Hong, who works at Seoul National University Hospital, for offering great advice for managing this patient.

REFERENCES

- 1 **Li JQ**, Guo W, Sun ZG, Huang QS, Lee EY, Wang Y, Yao XD. Cupping therapy for treating knee osteoarthritis: The evidence from systematic review and meta-analysis. *Complement Ther Clin Pract* 2017; **28**: 152-160 [PMID: [28779923](#) DOI: [10.1016/j.ctcp.2017.06.003](#)]
- 2 **AlBedah A**, Khalil M, Elolemy A, Hussein AA, AlQaed M, Al Mudaiheem A, Abutalib RA, Bazaid FM, Bafail AS, Essa A, Bakrain MY. The Use of Wet Cupping for Persistent Nonspecific Low Back Pain: Randomized Controlled Clinical Trial. *J Altern Complement Med* 2015; **21**: 504-508 [PMID: [26069973](#) DOI: [10.1089/acm.2015.0065](#)]
- 3 **Mamas MA**, Kwok CS, Kontopantelis E, Fryer AA, Buchan I, Bachmann MO, Zaman MJ, Myint PK. Relationship Between Anemia and Mortality Outcomes in a National Acute Coronary Syndrome Cohort: Insights From the UK Myocardial Ischemia National Audit Project Registry. *J Am Heart Assoc* 2016; **5**: e003348 [PMID: [27866164](#) DOI: [10.1161/JAHA.116.003348](#)]
- 4 **Hong YJ**, Jeong MH, Choi YH, Song JA, Kim DH, Lee KH, Yamanaka F, Lee MG, Park KH, Sim DS, Yoon NS, Yoon HJ, Kim KH, Park HW, Kim JH, Ahn Y, Cho JG, Park JC, Kang JC. Relation between anemia and vulnerable coronary plaque components in patients with acute coronary syndrome: virtual histology-intravascular ultrasound analysis. *J Korean Med Sci* 2012; **27**: 370-376 [PMID: [22468099](#) DOI: [10.3346/jkms.2012.27.4.370](#)]
- 5 **Dmitrieva NI**, Burg MB. Elevated sodium and dehydration stimulate inflammatory signaling in endothelial cells and promote atherosclerosis. *PLoS One* 2015; **10**: e0128870 [PMID: [26042828](#) DOI: [10.1371/journal.pone.0128870](#)]



Published by **Baishideng Publishing Group Inc**
7041 Koll Center Parkway, Suite 160, Pleasanton, CA 94566, USA

Telephone: +1-925-3991568

E-mail: bpgoffice@wjgnet.com

Help Desk: <https://www.f6publishing.com/helpdesk>

<https://www.wjgnet.com>

