

World Journal of *Clinical Cases*

World J Clin Cases 2020 December 6; 8(23): 5835-6212



Contents

Semimonthly Volume 8 Number 23 December 6, 2020

EDITORIAL

- 5835 Understanding the immunopathogenesis of COVID-19: Its implication for therapeutic strategy
Shimizu Y

OPINION REVIEW

- 5844 What is the gut feeling telling us about physical activity in colorectal carcinogenesis?
Cigrovski Berkovic M, Cigrovski V, Bilic-Curcic I, Mrzljak A

REVIEW

- 5852 Latest developments in chronic intestinal pseudo-obstruction
Zhu CZ, Zhao HW, Lin HW, Wang F, Li YX

ORIGINAL ARTICLE

Case Control Study

- 5866 Correlation between ductus venosus spectrum and right ventricular diastolic function in isolated single-umbilical-artery foetus and normal foetus in third trimester
Li TG, Nie F, Xu XY

Retrospective Cohort Study

- 5876 Clinical efficacy of integral theory-guided laparoscopic integral pelvic floor/ligament repair in the treatment of internal rectal prolapse in females
Yang Y, Cao YL, Zhang YY, Shi SS, Yang WW, Zhao N, Lyu BB, Zhang WL, Wei D

Retrospective Study

- 5887 Treatment of Kümmell's disease with sequential infusion of bone cement: A retrospective study
Zhang X, Li YC, Liu HP, Zhou B, Yang HL
- 5894 Application value analysis of magnetic resonance imaging and computed tomography in the diagnosis of intracranial infection after craniocerebral surgery
Gu L, Yang XL, Yin HK, Lu ZH, Geng CJ
- 5902 Focal intrahepatic strictures: A proposal classification based on diagnosis-treatment experience and systemic review
Zhou D, Zhang B, Zhang XY, Guan WB, Wang JD, Ma F
- 5918 Preliminary analysis of the effect of vagus nerve stimulation in the treatment of children with intractable epilepsy
Fang T, Xie ZH, Liu TH, Deng J, Chen S, Chen F, Zheng LL

- 5926** Scoring system for poor limb perfusion after limb fracture in children
Zhu T, Shi Y, Yu Q, Zhao YJ, Dai W, Chen Y, Zhang SS
- 5935** Overexpression of CD155 is associated with PD-1 and PD-L1 expression on immune cells, rather than tumor cells in the breast cancer microenvironment
Wang RB, Li YC, Zhou Q, Lv SZ, Yuan KY, Wu JP, Zhao YJ, Song QK, Zhu B
- 5944** Application of computer tomography-based 3D reconstruction technique in hernia repair surgery
Wang F, Yang XF
- 5952** Effect of methylprednisolone in severe and critical COVID-19: Analysis of 102 cases
Zhu HM, Li Y, Li BY, Yang S, Peng D, Yang X, Sun XL, Zhang M

Observational Study

- 5962** Genetic diagnosis history and osteoarticular phenotype of a non-transfusion secondary hemochromatosis
Ruan DD, Gan YM, Lu T, Yang X, Zhu YB, Yu QH, Liao LS, Lin N, Qian X, Luo JW, Tang FQ
- 5976** Abdominal ventral rectopexy with colectomy for obstructed defecation syndrome: An alternative option for selected patients
Wang L, Li CX, Tian Y, Ye JW, Li F, Tong WD
- 5988** Surgical treatment of multiple magnet ingestion in children: A single-center study
Cai DT, Shu Q, Zhang SH, Liu J, Gao ZG

Randomized Clinical Trial

- 5999** Efficacy and economic benefits of a modified Valsalva maneuver in patients with paroxysmal supraventricular tachycardia
Wang W, Jiang TF, Han WZ, Jin L, Zhao XJ, Guo Y

CASE REPORT

- 6009** Duodenal giant stromal tumor combined with ectopic varicose hemorrhage: A case report
Li DH, Liu XY, Xu LB
- 6016** Healthy neonate born to a SARS-CoV-2 infected woman: A case report and review of literature
Wang RY, Zheng KQ, Xu BZ, Zhang W, Si JG, Xu CY, Chen H, Xu ZY, Wu XM
- 6026** Pleomorphic adenoma of the trachea: A case report and review of the literature
Liao QN, Fang ZK, Chen SB, Fan HZ, Chen LC, Wu XP, He X, Yu HP
- 6036** Neoadjuvant targeted therapy for apocrine carcinoma of the breast: A case report
Yang P, Peng SJ, Dong YM, Yang L, Yang ZY, Hu XE, Bao GQ
- 6043** Huge encrusted ureteral stent forgotten for over 25 years: A case report
Kim DS, Lee SH

- 6048** Roxadustat for treatment of erythropoietin-hyporesponsive anemia in a hemodialysis patient: A case report
Yu WH, Li XJ, Yuan F
- 6056** Suspected SARS-CoV-2 infection with fever and coronary heart disease: A case report
Gong JR, Yang JS, He YW, Yu KH, Liu J, Sun RL
- 6064** Interpersonal psychotherapy-based psychological intervention for patient suffering from COVID-19: A case report
Hu CC, Huang JW, Wei N, Hu SH, Hu JB, Li SG, Lai JB, Huang ML, Wang DD, Chen JK, Zhou XY, Wang Z, Xu Y
- 6071** Optical coherence tomography angiography characteristics in Waldenström macroglobulinemia retinopathy: A case report
Li J, Zhang R, Gu F, Liu ZL, Sun P
- 6080** Forty-nine years old woman co-infected with SARS-CoV-2 and Mycoplasma: A case report
Gao ZA, Gao LB, Chen XJ, Xu Y
- 6086** Endoscopic fenestration in the diagnosis and treatment of delayed anastomotic submucosal abscess: A case report and review of literature
Zhang BZ, Wang YD, Liao Y, Zhang JJ, Wu YF, Sun XL, Sun SY, Guo JT
- 6095** Small-cell neuroendocrine carcinoma of the rectum — a rare tumor type with poor prognosis: A case report and review of literature
Chen ZZ, Huang W, Wei ZQ
- 6103** Laparoscopic left lateral sectionectomy in pediatric living donor liver transplantation by single-port approach: A case report
Li H, Wei L, Zeng Z, Qu W, Zhu ZJ
- 6110** Malignant meningioma with jugular vein invasion and carotid artery extension: A case report and review of the literature
Chen HY, Zhao F, Qin JY, Lin HM, Su JP
- 6122** Neuronal intranuclear inclusion disease mimicking acute cerebellitis: A case report
Guo JJ, Wang ZY, Wang M, Jiang ZZ, Yu XF
- 6130** Hemophagocytic lymphohistiocytosis caused by STAT1 gain-of-function mutation is not driven by interferon- γ : A case report
Liu N, Zhao FY, Xu XJ
- 6136** Single door laminoplasty plus posterior fusion for posterior atlantoaxial dislocation with congenital malformation: A case report and review of literature
Zhu Y, Wu XX, Jiang AQ, Li XF, Yang HL, Jiang WM
- 6144** Occipital nodular fasciitis easily misdiagnosed as neoplastic lesions: A rare case report
Wang T, Tang GC, Yang H, Fan JK

- 6150** Postoperative secondary aggravation of obstructive sleep apnea-hypopnea syndrome and hypoxemia with bilateral carotid body tumor: A case report
Yang X, He XG, Jiang DH, Feng C, Nie R
- 6158** Uncontrolled central hyperthermia by standard dose of bromocriptine: A case report
Ge X, Luan X
- 6164** Acute celiac artery occlusion secondary to blunt trauma: Two case reports
Li H, Zhao Y, Xu YA, Li T, Yang J, Hu P, Ai T
- 6172** Multiple ectopic goiter in the retroperitoneum, abdominal wall, liver, and diaphragm: A case report and review of literature
Qin LH, He FY, Liao JY
- 6181** Symptomatic and optimal supportive care of critical COVID-19: A case report and literature review
Pang QL, He WC, Li JX, Huang L
- 6190** Primary breast cancer patient with poliomyelitis: A case report
Wang XM, Cong YZ, Qiao GD, Zhang S, Wang LJ
- 6197** Discontinuous polyostotic fibrous dysplasia with multiple systemic disorders and unique genetic mutations: A case report
Lin T, Li XY, Zou CY, Liu WW, Lin JF, Zhang XX, Zhao SQ, Xie XB, Huang G, Yin JQ, Shen JN
- 6206** Novel triple therapy for hemorrhagic ascites caused by endometriosis: A case report
Han X, Zhang ST

ABOUT COVER

Peer-reviewer of *World Journal of Clinical Cases*, Dr. Mohamad Adam Bujang is a Research Officer at the Institute for Clinical Research, Ministry of Health, Malaysia. After receiving his Bachelor's degree in Statistics from MARA University of Technology in 2004, Dr. Adam undertook his postgraduate study at the same university, receiving his Master's degree (MBA) in 2008 and his PhD in Information Technology and Quantitative Sciences in 2017. Currently, he works as a biostatistician and researcher in the Clinical Research Centre, Sarawak General Hospital. His ongoing research interests involve such research methodologies as sampling techniques, sample size planning, and statistical analyses. Since 2016, he has served as an active member of the Malaysia Institute of Statistics and the Association of Clinical Registries Malaysia. (L-Editor: Filipodia)

AIMS AND SCOPE

The primary aim of *World Journal of Clinical Cases* (*WJCC*, *World J Clin Cases*) is to provide scholars and readers from various fields of clinical medicine with a platform to publish high-quality clinical research articles and communicate their research findings online.

WJCC mainly publishes articles reporting research results and findings obtained in the field of clinical medicine and covering a wide range of topics, including case control studies, retrospective cohort studies, retrospective studies, clinical trials studies, observational studies, prospective studies, randomized controlled trials, randomized clinical trials, systematic reviews, meta-analysis, and case reports.

INDEXING/ABSTRACTING

The *WJCC* is now indexed in Science Citation Index Expanded (also known as SciSearch®), Journal Citation Reports/Science Edition, PubMed, and PubMed Central. The 2020 Edition of Journal Citation Reports® cites the 2019 impact factor (IF) for *WJCC* as 1.013; IF without journal self cites: 0.991; Ranking: 120 among 165 journals in medicine, general and internal; and Quartile category: Q3.

RESPONSIBLE EDITORS FOR THIS ISSUE

Production Editor: Yan-Xia Xing; Production Department Director: Yun-Xiaojian Wu; Editorial Office Director: Jin-Lai Wang.

NAME OF JOURNAL

World Journal of Clinical Cases

ISSN

ISSN 2307-8960 (online)

LAUNCH DATE

April 16, 2013

FREQUENCY

Semimonthly

EDITORS-IN-CHIEF

Dennis A Bloomfield, Sandro Vento, Bao-gan Peng

EDITORIAL BOARD MEMBERS

<https://www.wjgnet.com/2307-8960/editorialboard.htm>

PUBLICATION DATE

December 6, 2020

COPYRIGHT

© 2020 Baishideng Publishing Group Inc

INSTRUCTIONS TO AUTHORS

<https://www.wjgnet.com/bpg/gerinfo/204>

GUIDELINES FOR ETHICS DOCUMENTS

<https://www.wjgnet.com/bpg/GerInfo/287>

GUIDELINES FOR NON-NATIVE SPEAKERS OF ENGLISH

<https://www.wjgnet.com/bpg/gerinfo/240>

PUBLICATION ETHICS

<https://www.wjgnet.com/bpg/GerInfo/288>

PUBLICATION MISCONDUCT

<https://www.wjgnet.com/bpg/gerinfo/208>

ARTICLE PROCESSING CHARGE

<https://www.wjgnet.com/bpg/gerinfo/242>

STEPS FOR SUBMITTING MANUSCRIPTS

<https://www.wjgnet.com/bpg/GerInfo/239>

ONLINE SUBMISSION

<https://www.f6publishing.com>



Novel triple therapy for hemorrhagic ascites caused by endometriosis: A case report

Xue Han, Shi-Tai Zhang

ORCID number: Xue Han [0000-0002-1754-4173](https://orcid.org/0000-0002-1754-4173); Shi-Tai Zhang [0000-0003-2170-4958](https://orcid.org/0000-0003-2170-4958).

Author contributions: Han X and Zhang ST contributed equally to this work, analyzed the case, wrote the manuscript, and read and approved the final manuscript.

Informed consent statement: All study participants provided informed written consent prior to study enrollment.

Conflict-of-interest statement: The authors declare that they have no conflict of interest.

CARE Checklist (2016) statement: The authors have read the CARE Checklist (2016), and the manuscript was prepared and revised according to the CARE Checklist (2016).

Open-Access: This article is an open-access article that was selected by an in-house editor and fully peer-reviewed by external reviewers. It is distributed in accordance with the Creative Commons Attribution NonCommercial (CC BY-NC 4.0) license, which permits others to distribute, remix, adapt, build upon this work non-commercially, and license their derivative works on different terms, provided the original work is properly cited and

Xue Han, Shi-Tai Zhang, Gynecology Department, Shengjing Hospital of China Medical University, Shenyang 110004, Liaoning Province, China

Corresponding author: Shi-Tai Zhang, MD, PhD, Attending Doctor, Lecturer, Gynecology Department, Shengjing Hospital of China Medical University, No. 36 Sanhao Street, Shenyang 110004, Liaoning Province, China. zhangshitai@126.com

Abstract

BACKGROUND

Massive hemorrhagic ascites caused by endometriosis is exceedingly rare, and the treatment strategy remains controversial. Here, we report a case of endometriosis with massive hemorrhagic ascites treated with a novel triple therapy including conservative surgery, gonadotropin-releasing hormone agonist, and then dienogest.

CASE SUMMARY

A 28-year-old nulliparous patient was admitted to Shengjing Hospital of China Medical University, and exploratory laparoscopy was performed. A total of 9500 mL of brown ascites was aspirated from the pelvic cavity, the bilateral ovaries strongly adhered to the posterior of the uterus and were fixed to the pelvic floor, and endometriotic cysts were not observed in either ovary. The pelvic and abdominal peritonea were covered with patchy red, white, and brown endometriotic lesions and defects. Partial surgical resection of endometriotic lesions on the peritoneum was performed while we simultaneously collected multiple peritoneal biopsies. The final pathological diagnosis was endometriosis coupled with hemorrhagic necrotic tissue.

CONCLUSION

Postoperative injection of gonadotropin-releasing hormone agonist was provided three times, followed by dienogest administration, and we will continue to follow up with this ongoing treatment.

Key Words: Endometriosis; Hemorrhagic ascites; Novel triple therapy; Dienogest; Recurrence; Case report

©The Author(s) 2020. Published by Baishideng Publishing Group Inc. All rights reserved.

the use is non-commercial. See: <http://creativecommons.org/licenses/by-nc/4.0/>

Manuscript source: Unsolicited manuscript

Specialty type: Medicine, research and experimental

Country/Territory of origin: China

Peer-review report's scientific quality classification

Grade A (Excellent): 0
Grade B (Very good): B
Grade C (Good): 0
Grade D (Fair): 0
Grade E (Poor): 0

Received: August 10, 2020

Peer-review started: August 10, 2020

First decision: August 21, 2020

Revised: September 13, 2020

Accepted: September 25, 2020

Article in press: September 25, 2020

Published online: December 6, 2020

P-Reviewer: Laganà A

S-Editor: Zhang L

L-Editor: Wang TQ

P-Editor: Xing YX



Core Tip: We for the first time report a case of endometriosis-related massive ascites treated with a novel triple therapy including conservative surgery, gonadotropin-releasing hormone agonist, and dienogest, which offers a new possibility to treat the disease.

Citation: Han X, Zhang ST. Novel triple therapy for hemorrhagic ascites caused by endometriosis: A case report. *World J Clin Cases* 2020; 8(23): 6206-6212

URL: <https://www.wjgnet.com/2307-8960/full/v8/i23/6206.htm>

DOI: <https://dx.doi.org/10.12998/wjcc.v8.i23.6206>

INTRODUCTION

Endometriosis is a chronic gynecological disorder caused by the presence of endometrial tissue outside the uterine cavity, and typically involves the peritoneum, ovaries, and rectovaginal septum. This is a relatively common disorder estimated to affect 6.1%-10.0% of women of reproductive age and is associated with chronic pelvic pain, dysmenorrhea, and infertility^[1]. Ascites is the pathological accumulation of fluid in the peritoneal cavity usually caused by liver or kidney disease, heart failure, and other conditions. Gynecological disorders such as ovarian cancer, ovarian hyperstimulation syndrome, and Meigs syndrome can also lead to ascites^[2]. Furthermore, ectopic pregnancy and ovarian rupture can cause hemorrhagic ascites, where ascites fluid contains more than 50000 red blood cells/mm³.

Endometriosis presenting with hemorrhagic ascites is extremely rare in clinical settings. In 1954, Brews reported the first case of endometriosis with ascites and in 2011, Gungor *et al*^[3] published a systematic review analyzing 63 cases of endometriosis with ascites^[3]. As of 2014, a total of 76 cases have been reported in the literature, and the majority of those cases were in nulliparous patients from Asia and Africa^[4].

We report on a case of endometriosis with massive hemorrhagic ascites in a nulliparous African patient. The patient also experienced secondary anemia and repeated recurrence of ascites following conservative drug treatment, and opted to undergo surgical intervention. This study was approved by the Institutional Review Board of Shengjing Hospital of China Medical University and implemented in accordance with approved guidelines.

CASE PRESENTATION

Chief complaints

A 28-year-old nulliparous Nigerian patient developed symptoms of bloating, osteoporosis, and hypercoagulopathy. Given these persistent symptoms, the patient opted for further treatment at Shengjing Hospital of China Medical University.

History of present illness

One year ago, the patient was admitted to the First Affiliated Hospital of China Medical University with increasing abdominal circumference and distension^[5]. Ultrasonography-guided omental biopsy was performed, and the pathological diagnosis was endometriosis. The patient had chosen a conservative drug treatment due to her age and desire to retain reproductive options for the future. During treatment with gonadotropin-releasing hormone agonist (GnRH-a) and oral contraceptives, puncture aspiration was required every 3-4 mo to reduce ascites.

History of past illness

The patient had a free previous medical history.

Personal and family history

The patient had a free personal and family history.

Physical examination

The patient's temperature was 36.5 °C, heart rate was 86 bpm, respiratory rate was 16 breaths per minute, blood pressure was 135/75 mmHg, and oxygen saturation in room air was 99%. The abdomen is obviously bulging, and the abdominal circumference was 85 cm.

Laboratory examinations

After admission, CA-125 (carbohydrate antigen 125) in serum was 36.42 U/mL, which slightly exceeded the reference range of 0-35 U/mL, while other serum test results were normal. However, CA-125 in ascites was 3058 U/mL, and although ascites was considered to be exudate, no tumor cells were detected in the collected fluid.

Imaging examinations

Ultrasonography and magnetic resonance imaging revealed a large amount of ascites, but no obvious mass was observed in the abdominal cavity (Figure 1A and B). Magnetic resonance imaging showed slight invagination of the fundus uteri, which proceeded to combine with bicornuate uterus. Hysteroscopy was not performed as per the patient's preference. Anal examination revealed that the Douglas cavity was closed, and a few painful nodules could be felt.

FINAL DIAGNOSIS

The final diagnosis of the presented case was hemorrhagic ascites caused by endometriosis.

TREATMENT

We assembled a multi-disciplinary team prior to surgery, in which specialists in medical imaging and gynecological oncology were invited to participate. Laparoscopic surgery was deemed useful, not only to explore the extent and degree of the lesion but also to exclude malignant metastasis by multiple biopsies.

Considering the ascites recurrence and the patient's desire to retain reproductive options, we proceeded with laparoscopic partial resection of endometriosis and multiple biopsies to preserve the uterine and bilateral adnexa. A total of 9500 mL of brown ascites was aspirated from the pelvic cavity, and large amounts of coagulated blood adhering to the pelvic peritoneum was observed through a laparoscope. The bilateral ovaries strongly adhered to the posterior of the uterus and were fixed to the pelvic floor, causing complete closure of the Douglas cavity. Endometriotic cysts were not observed in either ovary (Figure 1C). The pelvic and abdominal peritonea were covered with patchy red, white, and brown endometriotic lesions and defects (Figure 2A). All surfaces of abdominal organs such as the liver, spleen, and gastrointestinal tract were covered with tough connective tissue, and a portion of the jejunum-ileum and colon had adhered to the left abdominal wall (Figure 2B).

Partial surgical resection of endometriotic lesions on the peritoneum was performed while we simultaneously collected multiple peritoneal biopsies. The final pathological diagnosis was endometriosis coupled with hemorrhagic necrotic tissue (Figure 2C and D). Postoperative injection of GnRH-a 0 was provided 3 d after surgery, and has continued at 28-d intervals during the second and third months postoperatively, followed by dienogest (DNG) (2 mg, daily taken orally) administration, and this course of treatment is planned to continue upon follow-up.

OUTCOME AND FOLLOW-UP

The patient is currently recovering well and had no recurrence during 1 year of follow-up.

DISCUSSION

Endometriosis is an estrogen-dependent disease, manifested by the existence and

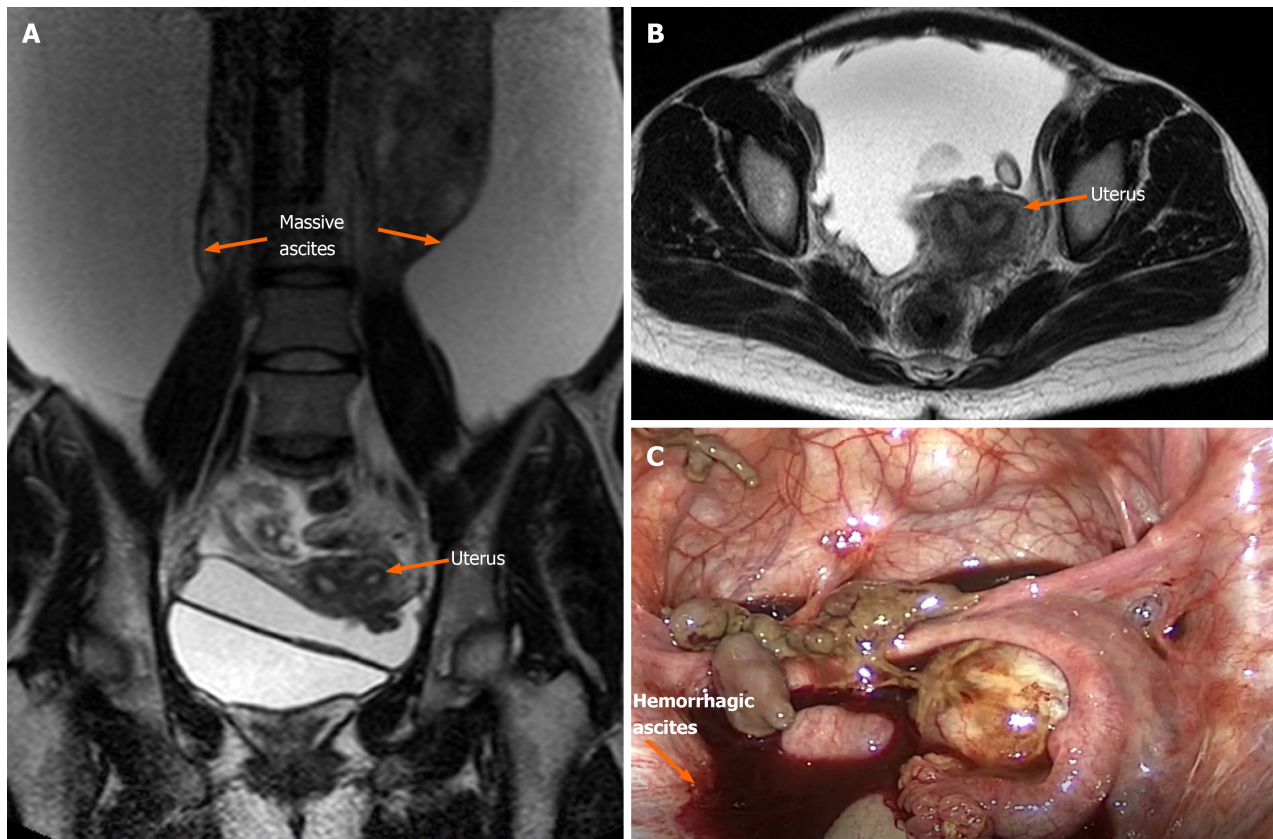


Figure 1 Bilateral ovaries were adhered to the posterior of the uterus, and endometriotic cysts were not observed in either ovary. A and B: Magnetic resonance imaging revealed a large amount of ascites, and slight invagination of the fundus uteri, which proceeded to combine with bicornuate uterus; C: Large amount of brown ascites and coagulated blood were observed in the pelvic cavity.

growth of functional endometrial-like tissue outside the uterus^[5-7]. The pathogenesis of endometriosis is still unclear, and it is currently considered to be a heterogeneous disease caused by multiple factors^[5,8]. Genetic studies have shown that endometriosis has a genetic tendency, however, this predisposition is complex^[6]. Meanwhile, the epigenetic mechanisms underlying endometriosis involve many processes of the acquisition and maintenance of immunologic, immunohistochemical, histological, and biological aberrations that characterize the ectopic endometrium in patients who are affected by endometriosis^[6,7].

Massive hemorrhagic ascites caused by endometriosis is exceedingly uncommon. Among the 63 cases reported by Gungor *et al*^[3] in 2011, 38.1% also presented with pleural effusion^[3].

Currently, the specific pathogenesis for this condition is unclear. Bernstein *et al*^[9] suggest that the rupture of ovarian endometriotic-cysts occurs, splashing contents such as endometrial cell and hemorrhagic fluid onto the surface of the pelvic organs and peritoneum. Capillaries distributed on the visceral and parietal peritoneum are damaged, followed by increased permeability, which could then cause a large amount of fluid and proteins to penetrate into the abdominal cavity. This would then lead to exudative ascites and adhesions. In addition, if severe pelvic adhesions block the absorption of fluid, ascites are further aggravated. As far as we are aware, endometrial rupture is a common pathology, usually accompanied by acute abdominal pain, slight fever, and a small amount of ascites. However, this fails to explain the appearance of massive ascites in this case and others. Average ascites volume in these cases is approximately 3.3 L, with even some recorded as high as 10 L^[10]. Previous reports have also included two cases of hypovolemic shock due to this disease^[11].

In this case, no obvious endometriotic cyst was found on the bilateral ovaries, but the pelvic peritoneal surface showed a scattered pattern of brown viscous tissue. At the same time, the ovaries and surrounding tissues were inflamed, which could have been caused by an earlier endometriotic cyst rupture (Figure 1B). We collected a total of 9500 mL of hemorrhagic ascites fluid during surgery, which then lead to the postoperative anemia. As for cases with pleural effusion, Bernstein *et al* suggested that the presence of pleural endometriosis or a mechanism similar to the development of

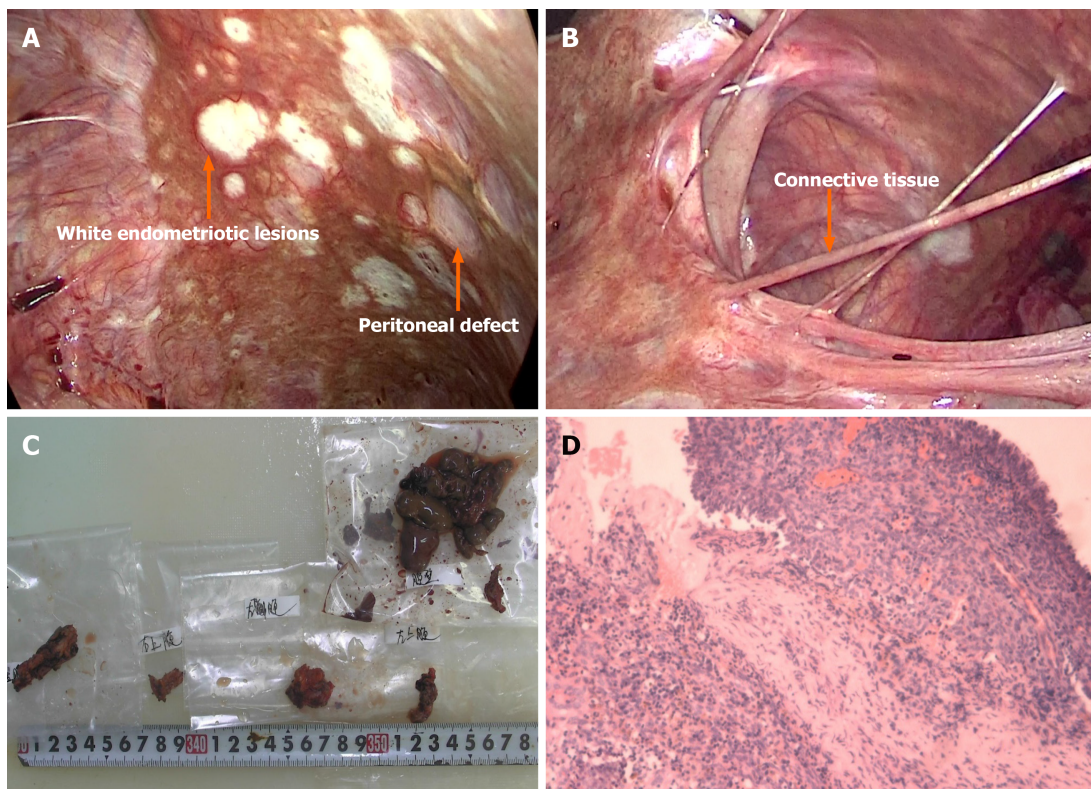


Figure 2 The final diagnosis. A: The pelvic and abdominal peritonea were covered with patchy red, white, and brown endometriotic lesions and defects; B: All surfaces of abdominal organs were covered with tough connective tissue; C: Gross pathology of resected tissues; D: The final pathological diagnosis was endometriosis coupled with hemorrhagic necrotic tissue.

Meigs syndrome may be the cause. However, there are many cases that do not share these characteristics; thus, the pathogenesis of ascites is still not fully explained.

Abdominal distention and pain, anorexia, and menometrorrhagia are the most frequent clinical symptoms of endometriosis-related massive ascites^[12]. Physical findings revealed that pelvic mass and nodularity were most common but appeared in only 35% and 20% of cases, respectively^[3]. Serum CA-125 can have a minimum value of 7 U/mL and a maximum of 3504 U/mL in this condition^[13]. Due to these non-specific features, differential diagnoses for endometriosis-related should include ovarian cancer and pelvic or abdominal tuberculosis in order to avoid unnecessary treatment. Final diagnosis still requires histopathological examination. However, compared with previous laparoscopic surgery techniques or transabdominal surgery, core needle biopsy is a minimally traumatic method of fluid collection with a short recovery period^[5,14].

Although superficial peritoneal lesions and ovarian endometriosis are the most common, deep invasive endometriosis and extrapelvic endometriosis are the challenges that we have to face, and the ascites caused by endometriosis mentioned in this case is also very difficult to treat^[12].

As for the treatment of deep invasive endometriosis, medication is sometimes sufficient to relieve symptoms and signs in many patients, thorough surgery and even segmental intestinal resection are required in some patients, and neuroprotection and blood vessel preservation methods are used to restore normal pelvic anatomy and function^[12,14]. To date, the treatment strategy for ascites related to endometriosis has been inconsistent^[15]. However, such cases can be treated similarly to endometriosis, primarily using drugs or surgery to disrupt ovarian function. Interestingly enough, there were two cases where radiation therapy was effective from 1954 and 1957^[3]. According to previous case reports, 88.9% of the patients opted for surgeries, including transabdominal or laparoscopic salpingo-oophorectomy with or without total abdominal hysterectomy, and biopsy to confirm the histological diagnosis. A total of 14 patients underwent radical surgery (bilateral salpingo-oophorectomy) and none of them relapsed. In addition to the radical surgery, ascites recurrence was reported with all other surgical methods. However, prior reports indicated that the proportion of nulliparity is high (82%), and patients typically do not opt for radical surgery^[3].

Drugs most commonly prescribed for conservative treatment include danazol,

progesterone, and oral contraceptives. After 1970, the development of GnRH-a provided an alternative to conservative treatment^[10]. Pharmaceutical treatments entail not only the risk of ascites recurrence, but also the side effects caused by long-term continuous medication, such as hot flashes, night sweats, and decreased bone mineral density. In 2014, Asano *et al*^[16] reported a case in which DNG was used to replace GnRH-a in the medical treatment of endometriosis-related ascites where diagnosis was confirmed by laparoscopic biopsy^[16], no evidence of recurrence was observed at the 1-year follow-up, and this drug has recently been approved for use in China. In the present case, the patient was a young nulliparous woman who underwent surgical resection of all endometriotic lesions with retention of the uterine and bilateral adnexa. Adhesive prevention material and GnRH-a were adopted during and post-surgery, respectively. DNG is a novel drug in China, and will be implemented as an alternative treatment for this patient following the third application of GnRH-a^[17].

To our knowledge, this is the first report of endometriosis-related massive ascites treated with a novel triple therapy, which includes conservative surgery, DNG, and GnRH-a, and the recurrence reduction and fertility promotion will be evaluated at future follow-ups.

CONCLUSION

In conclusion, due to its rare incidence and unknown etiology, consensus has not been reached regarding the treatment principles and prognosis for endometriosis-related ascites. This issue warrants further research.

REFERENCES

- Howard FM. Endometriosis and mechanisms of pelvic pain. *J Minim Invasive Gynecol* 2009; **16**: 540-550 [PMID: 19835795 DOI: 10.1016/j.jmig.2009.06.017]
- Bignall J, Arambage K, Vimplis S. Endometriosis: a rare and interesting cause of recurrent haemorrhagic ascites. *BMJ Case Rep* 2014; **2014** [PMID: 25355738 DOI: 10.1136/bcr-2013-010052]
- Gungor T, Kanat-Pektas M, Ozat M, Zayifoglu Karaca M. A systematic review: endometriosis presenting with ascites. *Arch Gynecol Obstet* 2011; **283**: 513-518 [PMID: 20821226 DOI: 10.1007/s00404-010-1664-1]
- Ussia A, Betsas G, Corona R, De Cicco C, Koninckx PR. Pathophysiology of cyclic hemorrhagic ascites and endometriosis. *J Minim Invasive Gynecol* 2008; **15**: 677-681 [PMID: 18971129 DOI: 10.1016/j.jmig.2008.08.012]
- Wang X, Li Y, Tong J, Chang B, Zhang Y, Liu Y, Bing H, Guo L, Li D. Endometriosis presenting with recurrent massive hemorrhagic ascites and diagnosed by core needle biopsy: A case report. *Medicine (Baltimore)* 2019; **98**: e15477 [PMID: 31083181 DOI: 10.1097/MD.00000000000015477]
- Laganà AS, Salmeri FM, Ban Frangež H, Ghezzi F, Vrtačnik-Bokal E, Granese R. Evaluation of M1 and M2 macrophages in ovarian endometriomas from women affected by endometriosis at different stages of the disease. *Gynecol Endocrinol* 2020; **36**: 441-444 [PMID: 31663401 DOI: 10.1080/09513590.2019.1683821]
- Vetvicka V, Laganà AS, Salmeri FM, Triolo O, Palmara VI, Vitale SG, Sofo V, Králíčková M. Regulation of apoptotic pathways during endometriosis: from the molecular basis to the future perspectives. *Arch Gynecol Obstet* 2016; **294**: 897-904 [PMID: 27628753 DOI: 10.1007/s00404-016-4195-6]
- Laganà AS, Garzon S, Götte M, Viganò P, Franchi M, Ghezzi F, Martin DC. The Pathogenesis of Endometriosis: Molecular and Cell Biology Insights. *Int J Mol Sci* 2019; **20** [PMID: 31717614 DOI: 10.3390/ijms20225615]
- Dun EC, Wong S, Lakhi NA, Nehzat CH. Recurrent massive ascites due to mossy endometriosis. *Fertil Steril* 2016; **106**: e14 [PMID: 27542707 DOI: 10.1016/j.fertnstert.2016.07.1119]
- Hinduja I, Kapadia K, Udawadia F, Bhilawadikar R, Adhe A, Zaveri K. Unusual presentation of endometriosis with haemorrhagic ascites - A case report. *J Obstet Gynaecol* 2016; **36**: 133-134 [PMID: 26367768 DOI: 10.3109/01443615.2015.1030605]
- Morgan TL, Tomich EB, Heiner JD. Endometriosis presenting with hemorrhagic ascites, severe anemia, and shock. *Am J Emerg Med* 2013; **31**: 272.e1-272. e3 [PMID: 22809773 DOI: 10.1016/j.ajem.2012.05.008]
- Laganà AS, Vitale SG, Trovato MA, Palmara VI, Rapisarda AM, Granese R, Sturlese E, De Dominicis R, Alecci S, Padula F, Chiofalo B, Grasso R, Cignini P, D'Amico P, Triolo O. Full-Thickness Excision versus Shaving by Laparoscopy for Intestinal Deep Infiltrating Endometriosis: Rationale and Potential Treatment Options. *Biomed Res Int* 2016; **2016**: 3617179 [PMID: 27579309]

DOI: [10.1155/2016/3617179](https://doi.org/10.1155/2016/3617179)]

- 13 **Goumenou A**, Matalliotakis I, Mahutte N, Koumantakis E. Endometriosis mimicking advanced ovarian cancer. *Fertil Steril* 2006; **86**: 219.e23-219. e25 [PMID: [16818037](https://pubmed.ncbi.nlm.nih.gov/16818037/) DOI: [10.1016/j.fertnstert.2005.12.044](https://doi.org/10.1016/j.fertnstert.2005.12.044)]
- 14 **Raffaelli R**, Garzon S, Baggio S, Genna M, Pomini P, Laganà AS, Ghezzi F, Franchi M. Mesenteric vascular and nerve sparing surgery in laparoscopic segmental intestinal resection for deep infiltrating endometriosis. *Eur J Obstet Gynecol Reprod Biol* 2018; **231**: 214-219 [PMID: [30415128](https://pubmed.ncbi.nlm.nih.gov/30415128/) DOI: [10.1016/j.ejogrb.2018.10.057](https://doi.org/10.1016/j.ejogrb.2018.10.057)]
- 15 **Laganà AS**, Vitale SG, Granese R, Palmara V, Ban Frangež H, Vrtačnik-Bokal E, Chiofalo B, Triolo O. Clinical dynamics of Dienogest for the treatment of endometriosis: from bench to bedside. *Expert Opin Drug Metab Toxicol* 2017; **13**: 593-596 [PMID: [28537213](https://pubmed.ncbi.nlm.nih.gov/28537213/) DOI: [10.1080/17425255.2017.1297421](https://doi.org/10.1080/17425255.2017.1297421)]
- 16 **Asano R**, Nakazawa T, Hirahara F, Sakakibara H. Dienogest was effective in treating hemorrhagic ascites caused by endometriosis: a case report. *J Minim Invasive Gynecol* 2014; **21**: 1110-1112 [PMID: [24780384](https://pubmed.ncbi.nlm.nih.gov/24780384/) DOI: [10.1016/j.jmig.2014.04.014](https://doi.org/10.1016/j.jmig.2014.04.014)]
- 17 **Sansone A**, De Rosa N, Giampaolino P, Guida M, Laganà AS, Di Carlo C. Effects of etonogestrel implant on quality of life, sexual function, and pelvic pain in women suffering from endometriosis: results from a multicenter, prospective, observational study. *Arch Gynecol Obstet* 2018; **298**: 731-736 [PMID: [30074068](https://pubmed.ncbi.nlm.nih.gov/30074068/) DOI: [10.1007/s00404-018-4851-0](https://doi.org/10.1007/s00404-018-4851-0)]



Published by **Baishideng Publishing Group Inc**
7041 Koll Center Parkway, Suite 160, Pleasanton, CA 94566, USA

Telephone: +1-925-3991568

E-mail: bpgoffice@wjgnet.com

Help Desk: <https://www.f6publishing.com/helpdesk>

<https://www.wjgnet.com>

