

WJG 20th Anniversary Special Issues (3): Inflammatory bowel disease

Clinical management of inflammatory bowel disease in the organ recipient

Amedeo Indriolo, Paolo Ravelli

Amedeo Indriolo, Paolo Ravelli, Digestive Endoscopy Unit, Department of Gastroenterology, Papa Giovanni XXIII Hospital, 24127 Bergamo, Italy

Author contributions: Indriolo A and Ravelli P solely contributed to this paper.

Correspondence to: Amedeo Indriolo, MD, Digestive Endoscopy Unit, Department of Gastroenterology, Papa Giovanni XXIII Hospital, Piazza OMS, 1, 24127 Bergamo, Italy. amedeo.indriolo@gmail.com

Telephone: +39-35-2673407 Fax: +39-35-2674837

Received: September 28, 2013 Revised: November 6, 2013

Accepted: January 19, 2014

Published online: April 7, 2014

Abstract

There was estimated a higher incidence of *de novo* inflammatory bowel disease (IBD) after solid organ transplantation than in the general population. The onset of IBD in the organ transplant recipient population is an important clinical situation which is associated to higher morbidity and difficulty in the medical therapeutic management because of possible interaction between anti-reject therapy and IBD therapy. IBD course after liver transplantation (LT) is variable, but about one third of patients may worsen, needing an increase in medical therapy or a colectomy. Active IBD at the time of LT, discontinuation of 5-aminosalicylic acid or azathioprine at the time of LT and use of tacrolimus-based immunosuppression may be associated with an unfavorable outcome of IBD after LT. Anti-tumor necrosis factor alpha (TNF α) therapy for refractory IBD may be an effective and safe therapeutic option after LT. The little experience of the use of biological therapy in transplanted patients, with concomitant anti-rejection therapy, suggests there be a higher more careful surveillance regarding the risk of infectious diseases, autoimmune diseases, and neoplasms. An increased risk of colorectal cancer (CRC) is present also after LT in IBD patients with primary sclerosing cholangitis (PSC). An

annual program of endoscopic surveillance with serial biopsies for CRC is recommended. A prophylactic colectomy in selected IBD/PSC patients with CRC risk factors could be a good management strategy in the CRC prevention, but it is used infrequently in the majority of LT centers. About 30% of patients develop multiple IBD recurrence and 20% of patients require a colectomy after renal transplantation. Like in the liver transplantation, anti-TNF α therapy could be an effective treatment in IBD patients with conventional refractory therapy after renal or heart transplantation. A large number of patients are needed to confirm the preliminary observations. Regarding the higher clinical complexity of this subgroup of IBD patients, a close multidisciplinary approach between an IBD dedicated gastroenterologist and surgeon and an organ transplantation specialist is necessary in order to have the best clinical management of IBD after transplantation.

© 2014 Baishideng Publishing Group Co., Limited. All rights reserved.

Key words: Inflammatory bowel disease; Ulcerative colitis; Crohn's disease; Primary sclerosing cholangitis; Liver transplantation; Heart transplantation; Renal transplantation; Anti-tumor necrosis factor alpha therapy

Core tip: Inflammatory bowel disease (IBD) in the organ transplant recipient population is an important clinical situation which is associated to higher morbidity and difficulty in the medical therapeutic management because of possible interaction between anti-reject therapy and IBD therapy. IBD course after liver transplantation is variable, but about one third of patients may worsen, needing an increase in medical therapy or a colectomy. About 30% of patients develop multiple IBD recurrence and 20% of patients require colectomy after renal transplantation. Like in the liver transplantation, anti-tumor necrosis factor alpha therapy could be an effective treatment in IBD patients with conventional

refractory therapy after renal or heart transplantation.

Indriolo A, Ravelli P. Clinical management of inflammatory bowel disease in the organ recipient. *World J Gastroenterol* 2014; 20(13): 3525-3533 Available from: URL: <http://www.wjgnet.com/1007-9327/full/v20/i13/3525.htm> DOI: <http://dx.doi.org/10.3748/wjg.v20.i13.3525>

INTRODUCTION

Inflammatory bowel disease (IBD) is a complex chronic inflammatory intestinal disease with a prevalence steadily increasing during the recent years. The management of IBD is leaning towards more complex clinical situations, with possible interactions between the intestinal disease and others organ diseases. The organ recipient population is constantly increasing in the medical specialized centers in the world and it can happen that a patient with a solid organ transplantation has a recurrence of IBD. This is particularly important in the liver transplantation (LT) because there is a close pathophysiological correlation between primary sclerosing cholangitis (PSC) and ulcerative colitis (UC) before the transplant. *De novo* IBD has been reported after solid organ transplantation, with an incidence estimated ten times higher with respect to the expected incidence of IBD in the general population. Therefore, the organ recipient patient may be a new clinical “scenario” for IBD management.

The first objective of this review was to examine the studies present in the English literature (PubMed) about the natural history in organ recipient patients. In particular, we have evaluated: (1) risk of recurrent IBD; (2) risk of *de novo* IBD; (3) need for colectomy; (4) risk of pouchitis; and (5) risk of colorectal cancer. The second objective was to examine the medical therapy for active IBD after organ transplantation.

We have more knowledge of IBD clinical management after LT, but in this review we have evaluated the IBD studies after heart, renal, lung, and intestinal transplantation.

EPIDEMIOLOGY AND CLINICAL FEATURE OF IBD AFTER LIVER TRANSPLANTATION

Recurrent IBD

Singh *et al*^[1] has recently examined the studies on the natural history of IBD after LT for PSC, reporting 609 patients in 14 studies, followed approximately 4.8 years after LT (range, 1.8-7.2 years), about 31% of patients have improvement of IBD activity, 39% of patients do not have a significant change in IBD activity, and 30% of patients develop worsening IBD, requiring intensification of medical therapy and/or surgery. The estimated risk of severe IBD flare up at 5 and 10 years after LT ranged from 39% to 63% and 39% to 98%, with a median time of a flare up around 1 year (range, 0.3-8.6 years)^[2-4]. The

need of colectomy for acute IBD refractory to medical therapy is nearly 9% (range, 0%-21%)^[2-6]. Dvorchik *et al*^[7] observed a significant 3.1-fold increased risk of colectomy due to severe IBD flare up or medically refractory disease after LT compared to IBD patients who did not require LT.

De novo IBD

Wörns *et al*^[8] evaluated 44 patients with IBD after solid organ transplant (SOT) and reported the *de novo* disease: 38 of 44 (86%) cases occurred following LT (23) or combined liver/kidney transplantation (15), 4 (9%) after heart transplantation, and 2 (5%) after kidney transplantation. Riley *et al*^[9] identified 14 patients who developed *de novo* IBD in 6800 cases after liver and kidney transplantation. Twelve (86%) of the patients developed IBD post liver transplant and two (14%) were detected post kidney transplant. The authors estimated a higher incidence of *de novo* IBD after SOT than in the general population (206 *vs* 20 cases per 100000 persons-year. The higher prevalence of IBD post LT in the SOT patients can be related to the strong association between PSC and UC. In these patients, the 10-year risk of *de novo* IBD after LT is estimated to be 14%-30%, with median time to development of approximately 4 years (range, 1.1-7.1 years)^[2-4]. After a median follow-up of 4 years 18/86 (21%) patients who underwent LT for PSC developed IBD. Verdonk *et al*^[3] observed that the *de novo* IBD patients tended to develop disease later in post-transplant period than the patients with pre-existing IBD. Moreover, the patients with *de novo* IBD after LT respond better to medical therapy and none required colectomy.

RISK FACTORS FOR IBD AFTER LIVER TRANSPLANTATION

Clinical activity of IBD

The clinical activity of IBD at the time of LT may be a risk factor for worsening the intestinal disease after LT. In fact, a three-fold higher risk of IBD flare up after LT in patients with active IBD at the time of LT it was observed^[3].

Smoking

Joshi *et al*^[4] evaluated 110 patients underwent LT for PSC. In the multivariate analysis, active smoking at the time of transplant was the only significant risk factor for flare up of IBD post-transplantation (HR = 17; 95%CI: 2-180).

Cytomegalovirus

Cytomegalovirus (CMV) mismatch (seropositive donor, seronegative recipient and CMV infection) have not been associated with the recurrence of IBD after LT^[4,10,11]. CMV mismatch was associated with a 4.5-fold higher risk of *de novo* IBD after LT, but CMV infection is not related to *de novo* IBD post LT^[11].

Therapy of IBD after LT

The therapy with proven efficacy for active IBD may re-

Table 1 Interaction between inflammatory bowel disease therapy and anti-reject therapy in inflammatory bowel disease patients after liver transplantation

Drug	Efficacy		Ref.
	IBD therapy	Anti-reject therapy	
5-ASA	+		[3] [12]
Prednisone	+	+	[12] [21]
Azathioprine	+	+	[2]
Anti-TNF α	+		[15] [16] [13] [14] [18]
Tacrolimus	-	+	[2] [3]
Cyclosporine	+	+	[3]
Mycophenolate	-	+	[22]
Mofetil			[23]

TNF α : Tumor necrosis factor alpha; IBD: Inflammatory bowel disease; 5-ASA: 5-aminosalicylates.

duce the risk of disease exacerbation post-LT (Table 1).

5-aminosalicylates (5-ASA) therapy after LT appears to be protective against the worsening disease activity of IBD, decreasing the flare up and/or colectomy risk about 80%^[3,12].

Azathioprine may reduce the risk of active IBD after transplant. In the study's Haagsma *et al*^[2], a comparison between 55 patients who received azathioprine with the 23 patients did not receive azathioprine, was performed and this showed a significantly higher IBD-free survival for azathioprine group. In particular, at 1, 3 and 5 years after LT, the IBD-free survival rates in patients receiving azathioprine were 96%, 96% and 88%, respectively; while in patients not receiving azathioprine, these value were 87%, 63% and 54%, respectively.

We have little knowledge about the use of anti-tumor necrosis factor alpha (TNF α) therapy for refractory IBD after transplant. To date, there have been only 22 patients treated with anti-TNF for relapsing IBD following LT; this number includes patients with UC, Crohn's disease, indeterminate colitis and pouchitis, treated with infliximab or adalimumab (Table 2)^[13-18]. In our study, we evaluated the efficacy and safety of infliximab therapy in a homogeneous series of four patients with refractory UC following LT, followed for a median time of 18 mo. At week 54, three patients (75%) experienced sustained improvement of IBD. Complete mucosal healing (defined as absence of lesions) was observed in one of three patients (33%). Steroid treatment was successfully withdrawn during infliximab therapy in all patients. Adverse events included only one infection by *Molluscum contagiosum*, which resolved without sequelae. No malignancies were observed in any patient following infliximab therapy. No cases of hepatic rejection were documented. Our results are in line with others studies about the efficacy and

safety of anti-TNF α therapy in patients with refractory IBD following LT, but larger studies are needed to evaluate the safety profile of biological therapy combined with anti rejection treatment.

Anti-reject therapy

Tacrolimus is the principal immunosuppressive agent in SOT, but it has been observed, in retrospective studies, that it may be associated with a four-fold higher risk of post-LT IBD relapse^[2,3]. In patients with tacrolimus for transplant-related immunosuppression, Dvorchik *et al*^[7] found that the risk of relapse of IBD at 1- and 5-year was 13% and 64%, respectively; while, in patients with tacrolimus-free regimens, the risk of IBD was 4% and 10%, respectively. The cause of a possible relationship between tacrolimus and IBD flare up after transplant is not known. IBD results from inappropriate and ongoing activation of the mucosal immune system in the presence of normal luminal flora. Immunosuppression agents may promote infections which may lead to the change bacterial gut flora and decrease the intestinal barrier function^[19]. Moreover, tacrolimus is a strong inhibitor of interleukin-2 production. Deficiency of interleukin-2 can result in T-cell dysregulation, leading to the development of intestinal chronic inflammation^[2,4].

Cyclosporine, like anti-TNF α , is the chosen drug in severe steroid refractory UC. Cyclosporine does not seem to worsen the course of IBD after transplant^[3,10]. In contrast with tacrolimus, the frequency of interleukin-2-expressing T cells was significantly higher with cyclosporine in renal transplant patients^[20]. This may explain in part the different effect of cyclosporine and tacrolimus on IBD course after transplant.

Corticosteroids are effective in acute and chronic prevention of SOT rejection as well as in inducing clinical remission in IBD. Moncrief *et al*^[21] and Navaneethan *et al*^[12] observed that prednisone therapy may favorably modify the course of IBD after LT, but this therapeutic regime is associated to important side effects.

Mycophenolate mofetil (MMF) has proven efficacy in SOT, but its role in IBD is not clear^[22,23]. Moreover, MMF is associated with enterocolitis, which can mimic a IBD flare up.

COLECTOMY POST-LIVER TRANSPLANTATION

Ho *et al*^[24] observed a prevalence of colectomy after LT about 35%. In this Scottish study 7 of 20 patients underwent colectomy with a median time of 3.4 years (range 1.5-6.3 years) following LT^[24]. The indication for colectomy was chronically active severe UC in three patients (43%), colonic dysplasia or colorectal cancer in three patients (43%) and benign stricture of colon in one patient (14%). The study in Cleveland compared 86 patients with UC and LT for PSC with 81 patients with UC and PSC who did not require LT^[25]. The necessity of colectomy was significantly more frequently in the non-LT group

Table 2 Anti-tumor necrosis factor alpha therapy for management of refractory inflammatory bowel disease after liver transplantation

Author	Number LT patients	Clinical outcome	Endoscopic outcome	Adverse events
Sandhu <i>et al</i> ^[13]	6	Response: 67%	-	Systemic lupus erythematosus
Mohabbat <i>et al</i> ^[14]	8	Response: 87.5%	Mucosal healing: 42.9%	Colorectal cancer Oral candidiasis <i>Clostridium difficile</i> colitis Bacterial pneumonia Cryptosporidiosis Post-transplant lympho-proliferative disorder
Lal <i>et al</i> ^[15]	1	Response: 100%	Improvement: 100%	No
El-Nachef <i>et al</i> ^[16]	2	Response: 100%	-	No
Indriolo <i>et al</i> ^[18]	4	Response: 75%	Mucosal healing: 33%	<i>Molluscum contagiosum</i>

than the LT group (76.5% *vs* 34.9%). The percentage of patients which underwent colectomy for steroid dependent/refractory disease was lower in the LT group than patients in the non-LT group (39.9% *vs* 48.4%). Regarding the possible difficulties to surgically pack the J pouch in patients who underwent LT and Roux-en-Y biliary-jejunal reconstruction, Mathis *et al*^[20] did not encounter any problems in the 13 patients operated on.

POUCHITIS POST-LIVER TRANSPLANTATION

The risk of acute pouchitis after LT for PSC ranged from 14% to 66%^[26-28]. The risk of chronic pouchitis ranged from 9.1% to 73.7%^[26-30]. Freeman *et al*^[29] observed that the risk of chronic refractory pouchitis was comparable in patients who underwent LT and those who did not. Therefore, it seems that LT does not increase the risk of pouchitis. With regard to the therapy of pouchitis after LT, Mathis *et al*^[26] evaluated 32 patients who underwent ileal pouch-anal anastomosis (IPAA) for UC and LT for PSC (in 13 patients IPAA followed by OLT). Two-thirds of the patients had pouchitis during follow-up, about half developed a chronic pouchitis that required daily antibiotic therapy. Only one patient needed a defunctioning ileostomy. Anti-TNF α therapy was used in only four IBD patients in three studies for refractory pouchitis after LT for PSC^[13,14,18]. Even though a clinical improvement was observed, the little data available does not allow us to extrapolate any conclusions about the efficacy and safety of biological therapy in patients with chronic refractory pouchitis after LT.

COLORECTAL CANCER POST-LIVER TRANSPLANT

Epidemiology

A large range with rates of risk of colorectal cancer after LT for PSC, from 0 to 31.5 per 1000 person/year, is present in literature in recent years^[4,7,21,25,31-48]. Watt *et al*^[31], reported a cumulative incidence of colorectal cancer (CRC) at 10-years post LT for PSC of 8.2% as compared to 2.6% after LT for non-PSC patients. The CRC risk in PSC patients without IBD after LT is 2.8% at 10-years. There-

fore, the combination of IBD and PSC after LT leads the patient to a higher risk in developing CRC.

Moreover, the CRC risk is increased in patients with long-standing IBD, long-standing LT and extensive colonic involvement^[32,35,45]. In fact, it was observed at 1-, 5- and 10-year, a cumulative incidence of CRC of 3.3%, 6.7%, and 11.8%, respectively, after LT. Regarding the colorectal cancer location, similarly to IBD/PSC patients before LT, the right-side colon is more frequently affected^[39]. There is no clear evidence if the age of the patients at the time of LT is associated with CRC risk^[7,33,35,45]. No significant association between clinical severity IBD and CRC risk after LT was observed^[39,45]. Regarding the use of 5-ASA or ursodeoxycholic acid in the chemoprevention of CRC, it seems that they don't change the cancer risk^[33,39].

Risk factors

The risk of CRC may increase after LT because of errors in mucosa sampling during colonoscopy or perhaps due to the immunosuppression treatment of anti-reject therapy. Loftus *et al*^[42] observed that the CRC rate was 4.4-fold higher after LT, as compared to a historical cohort patient with PSC/IBD who did not undergo LT. However, the role of LT in the risk of CRC in IBD/PSC patients still isn't clear. In fact, while Dvorchik found that LT did not significantly influence the risk of CRC, it was observed that LT may be an independent risk factor for CRC in other studies^[7,35,42,45].

Surveillance

A program of endoscopic surveillance with serial biopsies for CRC is recommended by the European Association for the Study of Liver^[49]. A colonoscopy is suggested every year in IBD/PSC patients after LT. If dysplasia colonic mucosa is found, a colectomy is advised. It has been shown to be a relatively safe procedure in specialized surgical centers^[45,46].

Management

Adjuvant pharmacotherapy with drugs like oxaliplatin has also been shown to be well tolerated in patients post-LT and hepatic graft dysfunction was not documented^[50]. Prophylactic colectomy in selected IBD/PSC patients with CRC risk factors could be a good management strategy in the CRC prevention, but it is used infrequently in

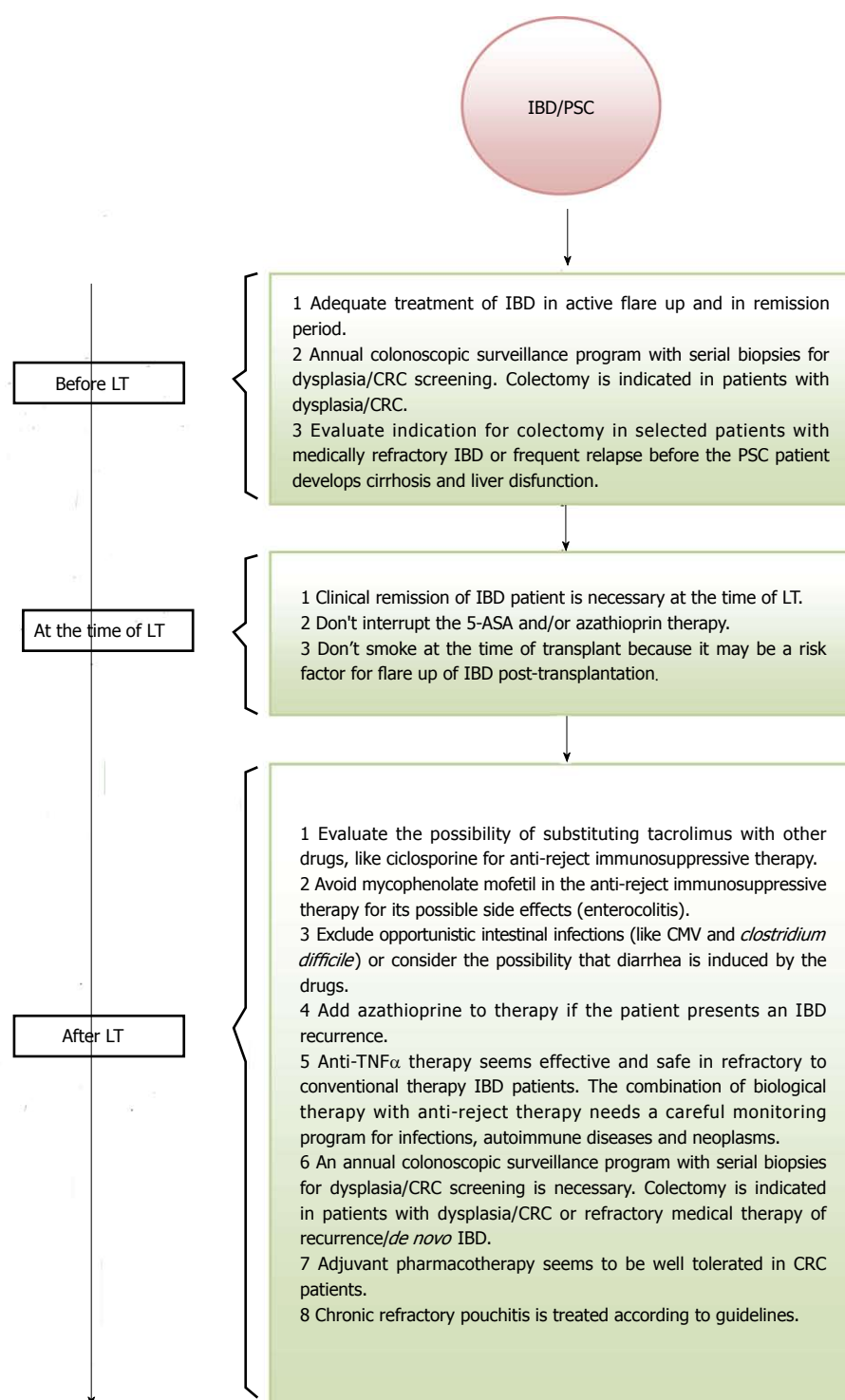


Figure 1 Clinical management of inflammatory bowel disease/primary sclerosing cholangitis patients before and after liver transplantation. TNF α : Tumor necrosis factor alpha; IBD: Inflammatory bowel disease; LT: Liver transplantation; PSC: Primary sclerosing cholangitis; CRC: Colorectal cancer; CMV: Cytomegalovirus; 5-ASA: 5-aminosalicylates.

the majority of LT centers^[45,51].

CLINICAL MANAGEMENT OF ACTIVE IBD AFTER LT

Patients who underwent LT can develop diarrhea and it is very important exclude an intestinal infection (CMV, *Clos-*

tridium difficile), or consider the possibility that diarrhea may be caused by the drugs (Figure 1). If the symptoms of active IBD are confirmed from a colonoscopy and a histological exam, the patient starts the IBD therapy. The plan of IBD therapy in the patient who underwent transplant, is similar to the therapy plan before the transplant. 5-ASA at a dose of 2.4 g per day is indicated in induction and in maintenance in the mild-to-moderate UC patients. Topical

therapy with 5-ASA and/or beclomethasone dipropionate can be useful in distal UC. Budesonide or systemic steroids are indicated in patients with mild Crohn's disease. In moderate-to-severe IBD patients the use of oral or *iv* corticosteroids are necessary. Prednisone at a dose of 50 mg per day or prednisolone at a dose of 40-60 mg per day based on the patient's body weight (60-80 kg) may be used in clinical practice. A gradual tapering of corticosteroids is recommended, for example 5 mg every week in prednisone therapy. Maintenance immunosuppression therapy with azathioprine at a dose of 2.0-2.5 mg/kg body weight per day is effective after the corticosteroid therapy. Anti-TNF α treatment could be effective and safe in refractory to conventional therapy IBD^[13,14,18]. The little experience of the use of biological therapy in transplanted patients, with concomitant anti-rejection therapy, suggests there be a higher and more careful surveillance regarding the risk of infectious diseases, autoimmune diseases, and neoplasms.

It is very important to consider the possibility of surgical treatment in patients with moderate-to-severe IBD after LT for PSC and even more so, because of the higher colorectal cancer risk. Proctocolectomy with IPAA is feasible and safe in dedicated surgical centers^[26,27].

IBD AFTER HEART TRANSPLANTATION

Three cases of *de novo* IBD after heart transplantation have been reported in 3 studies: two cases of Crohn's disease and one case of UC^[52-54]. The onset of IBD has been observed in pediatric age in two of three patients. Rakhit *et al*^[52] reported one case of Crohn's disease in 104 post-orthotopic heart transplant children. The patient developed diarrhea and rectal bleeding immediately after the transplant and IBD was diagnosed after one year. The patient continued to have flares despite immunosuppressive therapy. Harms *et al*^[53] reported a 15-year-old girl developed IBD 10 years after cardiac transplantation and presented a severe growth failure and delayed onset of puberty. The patient was found to have pan-enteric Crohn's disease and has done remarkably well following a nutritional therapy. Jüngling *et al*^[54] reported a 53-year-old patient who developed distal UC 2 years after heart transplantation. In spite of high-dose treatment with prednisolone the patient's clinical situation worsened with a progression of inflammation in the entire colon. Colectomy with ileostomy was necessary to obtain a good state of health. Three IBD cases have been observed after heart transplantation in spite of immunosuppressive therapy. Two of them have been treated with conventional medical therapy with success, whereas one IBD case required surgery with colectomy and ileostomy. No IBD patient was treated with anti-TNF α therapy.

IBD AFTER RENAL TRANSPLANTATION

A total of about of twenty-seven *de novo* IBD patients (15 UC and 11 Crohn's disease) after renal transplantation in

11 studies were reported^[9,16,54-63]. One patient presented erythema nodosum associated to IBD^[60], one patient developed colonic cancer with liver metastasis 2 years later and died^[60], thirteen (50%) patients were treated with conventional medical IBD therapy (mesalazine, corticosteroids, and azathioprine), achieving a clinical remission. Significant clinical improvement of IBD was observed with anti-TNF α therapy in three (11.5%) patients. No severe infections or graft reject were documented after biological therapy^[22,61]. Five (19.2%) patients with Crohn's disease continued to have flare up despite treatment^[9]. Five (19.2%) UC patients were refractory to therapy and required a colectomy^[9,55,56,62].

IBD AFTER LUNG AND INTESTINAL TRANSPLANTATION

The number of patients who underwent lung or intestinal transplantation is significantly lower than the patients who underwent liver, heart, and renal transplantation. This could probably be explained because no IBD cases were reported after lung and intestinal transplantation.

CLINICAL MANAGEMENT OF IBD PATIENTS AFTER HEART AND RENAL TRANSPLANTATION

The concomitant anti-reject immunosuppressive therapy can increase the risk of infectious diseases in transplanted patients. Therefore, in patients who develop diarrhea, it is very important to exclude an intestinal infection (CMV, *Clostridium difficile*). It is also necessary to exclude that diarrhea may be induced by the drugs. The onset of IBD after heart or renal transplantation could lead to a severe clinical situation for the transplanted patient. In fact, in about half of the patients, conventional IBD therapy combined with anti-reject therapy, can be non-effective. Nineteen percent of patients developed multiple recurrence on IBD in the renal transplantation group. Eleven percent of patients required anti-TNF α therapy in order to have clinical remission and in about 20% of patients required a colectomy. The LT model suggests that anti-TNF α therapy combined with anti-reject therapy could be useful in selected IBD patients with refractory to conventional therapy after heart or renal transplantation. Like in the LT, it is very important that there be a higher more careful surveillance regarding the risk of infectious diseases, autoimmune diseases, and neoplasms after biological therapy in heart and renal transplanted patients. The surgical option remains an essential treatment in complicated IBD cases which are refractory to the intensive medical therapy.

CONCLUSION

There is estimated a higher incidence of *de novo* IBD after solid organ transplantation than in the general popula-

tion. The onset of IBD in the organ transplant recipient population is an important clinical situation which is associated with higher morbidity and difficulty in the medical therapeutic management because of the possible interaction between anti-reject therapy and IBD therapy. IBD course after LT is variable, but about one third of patients may worsen, needing increased medical therapy or a colectomy. Active IBD at the time of LT, discontinuation of 5-ASA or azathioprine at the time of LT and use of tacrolimus-based immunosuppression may be associated with an unfavorable outcome of IBD after LT. Anti-TNF therapy for refractory IBD may be an effective and safe therapeutic option after LT. The little experience of the use of biological therapy in transplanted patients, with concomitant anti-rejection therapy, suggests there be a higher more careful surveillance regarding the risk of infectious diseases, autoimmune diseases, and neoplasms. Therefore, it is very important to consider the possibility of a surgical treatment in refractory severe IBD after LT. An increased risk of colorectal cancer is also present after LT in IBD/PSC patient. An annual program of endoscopic surveillance with serial biopsies for CRC is recommended. If dysplasia colonic mucosa is found, a colectomy with IPAA is advised. It has been shown to be a relatively safe procedure in the specialized surgical centers. Adjuvant pharmacotherapy has been shown to be well tolerated in patients post-LT. Hepatic graft dysfunction has not been documented after adjuvant pharmacotherapy. A prophylactic colectomy in selected IBD/PSC patients with CRC risk factors could be a good management strategy in the CRC prevention, but it is used infrequently in the majority of LT centers. About 30% of patients developed multiple recurrences of IBD and 20% of patients required a colectomy after renal transplantation. Like in the LT, anti-TNF α therapy could be an effective treatment in IBD patients with conventional refractory therapy after renal or heart transplantation. A large number of patients are needed to confirm the preliminary observations.

Regarding the higher clinical complexity of this subgroup of IBD patients, a close multidisciplinary approach between an IBD dedicated gastroenterologist and surgeon and an organ transplantation specialist is necessary in order to have the best clinical management of IBD after transplantation.

REFERENCES

- Singh S, Loftus EV, Talwalkar JA. Inflammatory bowel disease after liver transplantation for primary sclerosing cholangitis. *Am J Gastroenterol* 2013; **108**: 1417-1425 [PMID: 23896954 DOI: 10.1038/ajg.2013.163]
- Haagsma EB, Van Den Berg AP, Kleibeuker JH, Slooff MJ, Dijkstra G. Inflammatory bowel disease after liver transplantation: the effect of different immunosuppressive regimens. *Aliment Pharmacol Ther* 2003; **18**: 33-44 [PMID: 12848624 DOI: 10.1046/j.1365-2036.2003.01613.x]
- Verdonk RC, Dijkstra G, Haagsma EB, Shostrom VK, Van den Berg AP, Kleibeuker JH, Langnas AN, Sudan DL. Inflammatory bowel disease after liver transplantation: risk factors for recurrence and de novo disease. *Am J Transplant* 2006; **6**: 1422-1429 [PMID: 16686766 DOI: 10.1111/j.1600-6143.2006.01333.x]
- Joshi D, Bjarnason I, Belgaumkar A, O'Grady J, Suddle A, Heneghan MA, Aluvihare V, Rela M, Heaton N, Agarwal K. The impact of inflammatory bowel disease post-liver transplantation for primary sclerosing cholangitis. *Liver Int* 2013; **33**: 53-61 [PMID: 22103794 DOI: 10.1111/j.1478-3231.2011.02677.x]
- Befeler AS, Lisssoos TW, Schiano TD, Conjeevaram H, Dasgupta KA, Millis JM, Newell KA, Thistlethwaite JR, Baker AL. Clinical course and management of inflammatory bowel disease after liver transplantation. *Transplantation* 1998; **65**: 393-396 [PMID: 9484758]
- MacLean AR, Lilly L, Cohen Z, O'Connor B, McLeod RS. Outcome of patients undergoing liver transplantation for primary sclerosing cholangitis. *Dis Colon Rectum* 2003; **46**: 1124-1128 [PMID: 12907911]
- Dvorchik I, Subotin M, Demetris AJ, Fung JJ, Starzl TE, Wieand S, Abu-Elmagd KM. Effect of liver transplantation on inflammatory bowel disease in patients with primary sclerosing cholangitis. *Hepatology* 2002; **35**: 380-384 [PMID: 11826412 DOI: 10.1053/jhep.2002.30695]
- Wörns MA, Lohse AW, Neurath MF, Croxford A, Otto G, Kreft A, Galle PR, Kanzler S. Five cases of de novo inflammatory bowel disease after orthotopic liver transplantation. *Am J Gastroenterol* 2006; **101**: 1931-1937 [PMID: 16790037 DOI: 10.1111/j.1572-0241.2006.00624.x]
- Riley TR, Schoen RE, Lee RG, Rakela J. A case series of transplant recipients who despite immunosuppression developed inflammatory bowel disease. *Am J Gastroenterol* 1997; **92**: 279-282 [PMID: 9040206]
- Cholongitas E, Papatheodoridis GV, Zappoli P, Giannakopoulos A, Patch D, Marelli L, Shusang V, Kalambokis G, Shirling G, Rolando N, Burroughs AK. Combined HLA-DR and -DQ disparity is associated with a stable course of ulcerative colitis after liver transplantation for primary sclerosing cholangitis. *Liver Transpl* 2007; **13**: 552-557 [PMID: 17394153 DOI: 10.1002/lt.21077]
- Verdonk RC, Haagsma EB, Van Den Berg AP, Karrenbeld A, Slooff MJ, Kleibeuker JH, Dijkstra G. Inflammatory bowel disease after liver transplantation: a role for cytomegalovirus infection. *Scand J Gastroenterol* 2006; **41**: 205-211 [PMID: 16484126 DOI: 10.1080/00365520500206293]
- Navaneethan U, Choudhary M, Venkatesh PG, Lashner BA, Remzi FH, Shen B, Kiran RP. The effects of liver transplantation on the clinical course of colitis in ulcerative colitis patients with primary sclerosing cholangitis. *Aliment Pharmacol Ther* 2012; Epub ahead of print [PMID: 22428731 DOI: 10.1111/j.1365-2036.2012.05067.x]
- Sandhu A, Alameel T, Dale CH, Levstik M, Chande N. The safety and efficacy of antitumour necrosis factor- α therapy for inflammatory bowel disease in patients post liver transplantation: a case series. *Aliment Pharmacol Ther* 2012; **36**: 159-165 [PMID: 22616981 DOI: 10.1111/j.1365-2036.2012.05141.x]
- Mohabbat AB, Sandborn WJ, Loftus EV, Wiesner RH, Bruining DH. Anti-tumour necrosis factor treatment of inflammatory bowel disease in liver transplant recipients. *Aliment Pharmacol Ther* 2012; **36**: 569-574 [PMID: 22779779 DOI: 10.1111/j.1365-2036.2012.05217.x]
- Lal S, Steinhart AH. Infliximab for ulcerative colitis following liver transplantation. *Eur J Gastroenterol Hepatol* 2007; **19**: 277-280 [PMID: 17301656]
- El-Nachef N, Terdiman J, Mahadevan U. Anti-tumor necrosis factor therapy for inflammatory bowel disease in the setting of immunosuppression for solid organ transplantation. *Am J Gastroenterol* 2010; **105**: 1210-1211 [PMID: 20445523 DOI: 10.1038/ajg]
- Indriolo A, Fagioli S, Pasulo L. Infliximab in patients with ulcerative colitis and primary sclerosing cholangitis before

- and after liver transplantation. *J Crohns Colitis* 2012; **6** Suppl 1: S117
- 18 **Indriolo A**, Fagioli S, Pasulo L, Fiorino G, Danese S, Ravelli P. Letter: infliximab therapy in inflammatory bowel disease patients after liver transplantation. *Aliment Pharmacol Ther* 2013; **37**: 840-842 [PMID: 23496317 DOI: 10.1111/apt.12256]
 - 19 **Gabe SM**, Bjarnason I, Tolou-Ghamari Z, Tredger JM, Johnson PG, Barclay GR, Williams R, Silk DB. The effect of tacrolimus (FK506) on intestinal barrier function and cellular energy production in humans. *Gastroenterology* 1998; **115**: 67-74 [PMID: 9649460]
 - 20 **Rostaing L**, Puyoo O, Tkaczuk J, Peres C, Rouzaud A, Cisterne JM, de Preval C, Ohayon E, Durand D, Abbai M. Differences in Type 1 and Type 2 intracytoplasmic cytokines, detected by flow cytometry, according to immunosuppression (cyclosporine A vs. tacrolimus) in stable renal allograft recipients. *Clin Transplant* 1999; **13**: 400-409 [PMID: 10515221 DOI: 10.1034/j.1399-0012.1999.130506.x]
 - 21 **Moncrief KJ**, Savu A, Ma MM, Bain VG, Wong WW, Tandon P. The natural history of inflammatory bowel disease and primary sclerosing cholangitis after liver transplantation—a single-centre experience. *Can J Gastroenterol* 2010; **24**: 40-46 [PMID: 20186355]
 - 22 **Neurath MF**, Wanitschke R, Peters M, Krummenauer F, Meyer zum Büschenfelde KH, Schlaak JF. Randomised trial of mycophenolate mofetil versus azathioprine for treatment of chronic active Crohn's disease. *Gut* 1999; **44**: 625-628 [PMID: 10205197]
 - 23 **Fellermann K**, Steffen M, Stein J, Raedler A, Hämling J, Ludwig D, Loeschke K, Stange EF. Mycophenolate mofetil: lack of efficacy in chronic active inflammatory bowel disease. *Aliment Pharmacol Ther* 2000; **14**: 171-176 [PMID: 10651657 DOI: 10.1046/j.1365-2036.2000.00695.x]
 - 24 **Ho GT**, Seddon AJ, Therapondos G, Satsangi J, Hayes PC. The clinical course of ulcerative colitis after orthotopic liver transplantation for primary sclerosing cholangitis: further appraisal of immunosuppression post transplantation. *Eur J Gastroenterol Hepatol* 2005; **17**: 1379-1385 [PMID: 16292093]
 - 25 **Navaneethan U**, Venkatesh PG, Mukewar S, Lashner BA, Remzi FH, McCullough AJ, Kiran RP, Shen B, Fung JJ. Progressive primary sclerosing cholangitis requiring liver transplantation is associated with reduced need for colectomy in patients with ulcerative colitis. *Clin Gastroenterol Hepatol* 2012; **10**: 540-546 [PMID: 22245961 DOI: 10.1016/j.cgh.2012.01.006]
 - 26 **Mathis KL**, Dozois EJ, Larson DW, Cima RR, Sarmiento JM, Wolff BG, Heimbach JK, Pemberton JH. Ileal pouch-anal anastomosis and liver transplantation for ulcerative colitis complicated by primary sclerosing cholangitis. *Br J Surg* 2008; **95**: 882-886 [PMID: 18496886 DOI: 10.1002/bjs.6210]
 - 27 **Cho CS**, Dayton MT, Thompson JS, Koltun WA, Heise CP, Harms BA. Proctocolectomy-ileal pouch-anal anastomosis for ulcerative colitis after liver transplantation for primary sclerosing cholangitis: a multi-institutional analysis. *J Gastrointest Surg* 2008; **12**: 1221-1226 [PMID: 18449613 DOI: 10.1007/s11605-008-0528-5]
 - 28 **Zins BJ**, Sandborn WJ, Penna CR, Landers CJ, Targan SR, Tremaine WJ, Wiesner RH, Dozois RR. Pouchitis disease course after orthotopic liver transplantation in patients with primary sclerosing cholangitis and an ileal pouch-anal anastomosis. *Am J Gastroenterol* 1995; **90**: 2177-2181 [PMID: 8540511]
 - 29 **Freeman K**, Shao Z, Remzi FH, Lopez R, Fazio VW, Shen B. Impact of orthotopic liver transplant for primary sclerosing cholangitis on chronic antibiotic refractory pouchitis. *Clin Gastroenterol Hepatol* 2008; **6**: 62-68 [PMID: 18065274 DOI: 10.1016/j.cgh.2007.09.018]
 - 30 **Rowley S**, Candinas D, Mayer AD, Buckels JA, McMaster P, Keighley MR. Restorative proctocolectomy and pouch anal anastomosis for ulcerative colitis following orthotopic liver transplantation. *Gut* 1995; **37**: 845-847 [PMID: 8537060 DOI: 10.1136/gut.37.6.845]
 - 31 **Watt KD**, Pedersen RA, Kremers WK, Heimbach JK, Sanchez W, Gores GJ. Long-term probability of and mortality from de novo malignancy after liver transplantation. *Gastroenterology* 2009; **137**: 2010-2017 [PMID: 19766646 DOI: 10.1053/j.gastro.2009.08.070]
 - 32 **Fabia R**, Levy MF, Testa G, Obiekwe S, Goldstein RM, Huserg BS, Gonwa TA, Klintmalm GB. Colon carcinoma in patients undergoing liver transplantation. *Am J Surg* 1998; **176**: 265-269 [PMID: 9776156]
 - 33 **Hanounieh IA**, Macaron C, Lopez R, Zein NN, Lashner BA. Risk of colonic neoplasia after liver transplantation for primary sclerosing cholangitis. *Inflamm Bowel Dis* 2012; **18**: 269-274 [PMID: 21425212]
 - 34 **Albright JB**, Bonatti H, Stauffer J, Dickson RC, Nguyen J, Harnois D, Jeanpierre C, Hinder R, Steers J, Chua H, Aranda-Michel J. Colorectal and anal neoplasms following liver transplantation. *Colorectal Dis* 2010; **12**: 657-666 [PMID: 19508543 DOI: 10.1111/j.1463-1318.2009.01840.x]
 - 35 **Bleday R**, Lee E, Jessurun J, Heine J, Wong WD. Increased risk of early colorectal neoplasms after hepatic transplant in patients with inflammatory bowel disease. *Dis Colon Rectum* 1993; **36**: 908-912 [PMID: 8404380]
 - 36 **Higashi H**, Yanaga K, Marsh JW, Tzakis A, Kakizoe S, Starzl TE. Development of colon cancer after liver transplantation for primary sclerosing cholangitis associated with ulcerative colitis. *Hepatology* 1990; **11**: 477-480 [PMID: 2312061]
 - 37 **Jonas S**, Rayes N, Neumann U, Neuhaus R, Bechstein WO, Guckelberger O, Tullius SG, Serke S, Neuhaus P. De novo malignancies after liver transplantation using tacrolimus-based protocols or cyclosporine-based quadruple immunosuppression with an interleukin-2 receptor antibody or antithymocyte globulin. *Cancer* 1997; **80**: 1141-1150 [PMID: 9305716]
 - 38 **Johnson EE**, Levenson GE, Pirsch JD, Heise CP. A 30-year analysis of colorectal adenocarcinoma in transplant recipients and proposal for altered screening. *J Gastrointest Surg* 2007; **11**: 272-279 [PMID: 17458597]
 - 39 **Jørgensen KK**, Lindström L, Cvancarova M, Castedal M, Friman S, Schrupf E, Foss A, Isoniemi H, Nordin A, Holte K, Rasmussen A, Bergquist A, Vatn MH, Boberg KM. Colorectal neoplasia in patients with primary sclerosing cholangitis undergoing liver transplantation: a Nordic multicenter study. *Scand J Gastroenterol* 2012; **47**: 1021-1029 [PMID: 22577871 DOI: 10.3109/00365521.2012.685754]
 - 40 **Kelly DM**, Emre S, Guy SR, Miller CM, Schwartz ME, Sheiner PA. Liver transplant recipients are not at increased risk for nonlymphoid solid organ tumors. *Cancer* 1998; **83**: 1237-1243 [PMID: 9740091]
 - 41 **Knechtle SJ**, D'Alessandro AM, Harms BA, Pirsch JD, Belzer FO, Kalayoglu M. Relationships between sclerosing cholangitis, inflammatory bowel disease, and cancer in patients undergoing liver transplantation. *Surgery* 1995; **118**: 615-619; discussion 619-620 [PMID: 7570313]
 - 42 **Loftus EV**, Aguilar HI, Sandborn WJ, Tremaine WJ, Krom RA, Zinsmeister AR, Graziadei IW, Wiesner RH. Risk of colorectal neoplasia in patients with primary sclerosing cholangitis and ulcerative colitis following orthotopic liver transplantation. *Hepatology* 1998; **27**: 685-690 [PMID: 9500695]
 - 43 **Narumi S**, Roberts JP, Emond JC, Lake J, Ascher NL. Liver transplantation for sclerosing cholangitis. *Hepatology* 1995; **22**: 451-457 [PMID: 7635412]
 - 44 **Sint Nicolaas J**, Tjon AS, Metselaar HJ, Kuipers EJ, de Man RA, van Leerdam ME. Colorectal cancer in post-liver transplant recipients. *Dis Colon Rectum* 2010; **53**: 817-821 [PMID: 20389217 DOI: 10.1007/DCR.0b013e3181cc90c7]
 - 45 **Vera A**, Gunson BK, Ussatoff V, Nightingale P, Candinas D, Radley S, Mayer A, Buckels JA, McMaster P, Neuberger J, Mirza DF. Colorectal cancer in patients with inflammatory bowel disease after liver transplantation for primary sclerosing

- ing cholangitis. *Transplantation* 2003; **75**: 1983-1988 [PMID: 12829898]
- 46 **Goss JA**, Shackleton CR, Farmer DG, Arnaout WS, Seu P, Markowitz JS, Martin P, Stribling RJ, Goldstein LL, Busuttil RW. Orthotopic liver transplantation for primary sclerosing cholangitis. A 12-year single center experience. *Ann Surg* 1997; **225**: 472-481; discussion 481-483 [PMID: 9193175]
 - 47 **Jain AB**, Yee LD, Nalesnik MA, Youk A, Marsh G, Reyes J, Zak M, Rakela J, Irish W, Fung JJ. Comparative incidence of de novo nonlymphoid malignancies after liver transplantation under tacrolimus using surveillance epidemiologic end result data. *Transplantation* 1998; **66**: 1193-1200 [PMID: 9825817]
 - 48 **Koornstra JJ**, Wesseling J, de Jong AE, Vasen HF, Kleibeuker JH, Haagsma EB. Increased risk of colorectal neoplasia in asymptomatic liver-transplant recipients. *Gut* 2007; **56**: 892-893 [PMID: 17519499 DOI: 10.1136/gut.2007.120121]
 - 49 **European Association For The Study Of The Liver**. EASL Clinical Practice Guidelines: management of cholestatic liver diseases. *J Hepatol* 2009; **51**: 237-267 [PMID: 19501929 DOI: 10.1016/j.jhep.2009.04.009]
 - 50 **Doroshov JH**, Synold TW, Gandara D, Mani S, Remick SC, Mulkerin D, Hamilton A, Sharma S, Ramanathan RK, Lenz HJ, Graham M, Longmate J, Takimoto CH, Ivy P. Pharmacology of oxaliplatin in solid tumor patients with hepatic dysfunction: a preliminary report of the National Cancer Institute Organ Dysfunction Working Group. *Semin Oncol* 2003; **30**: 14-19 [PMID: 14523790]
 - 51 **Levin B**. Risk of cancer in ulcerative colitis. *Gastrointest Endosc* 1999; **49**: S60-S62 [PMID: 10049450]
 - 52 **Rakhit A**, Nurko S, Gauvreau K, Mayer JE, Blume ED. Gastrointestinal complications after pediatric cardiac transplantation. *J Heart Lung Transplant* 2002; **21**: 751-759 [PMID: 12100901]
 - 53 **Harms B**, Bremner AR, Mulligan J, Fairhurst J, Griffiths DM, Salmon T, Beattie RM. Crohn's disease post-cardiac transplantation presenting with severe growth failure and delayed onset of puberty. *Pediatr Allergy Immunol* 2004; **15**: 186-189 [PMID: 15059198 DOI: 10.1046/j.1399-3038.2003.00130.x]
 - 54 **Jüngling B**, Kindermann I, Moser C, Püschel W, Ecker KW, Schäfers HJ, Böhm M, Zeuzem S, Giese T, Stallmach A. Development of ulcerative colitis after heart transplantation during immunosuppressive therapy. *Z Gastroenterol* 2005; **43**: 195-199 [PMID: 15700214 DOI: 10.1055/s-2004-813743]
 - 55 **Hibbs AM**, Bznik-Cizman B, Guttenberg M, Goldberg B, Meyers K. Ulcerative colitis in a renal transplant patient with previous Goodpasture disease. *Pediatr Nephrol* 2001; **16**: 543-546 [PMID: 11465800]
 - 56 **Nagai H**, Matsumaru K, Shiozawa K, Momiyama K, Wakui N, Shinohara M, Watanabe M, Ishii K, Nonaka H, Hasegawa A, Teramoto T, Yamamuro W, Sumino Y, Miki K. Disappearance of HCV after cessation of immunosuppression in a patient with ulcerative colitis and renal transplantation. *J Gastroenterol* 2005; **40**: 848-853 [PMID: 16143892]
 - 57 **Halim MA**, Said T, Nair P, Schmidt I, Hassan A, Johny KV, Al-Muzairai I, Samhan M, Nampoory MR, Al-Mousawi M. De novo Crohn's disease in a renal transplant recipient. *Transplant Proc* 2007; **39**: 1278-1279 [PMID: 17524953 DOI: 10.1016/j.transproceed.2007.03.045]
 - 58 **Stewart IJ**, Gallagher JP, Dahms WJ. A case of new onset Crohn's disease after renal transplantation. *Gastroenterol Hepatol (N Y)* 2008; **4**: 877-878 [PMID: 21904480]
 - 59 **Kourda N**, Bettaieb I, Blél A, Zoghalmi A, Bedoui R, Najah N, Ben Jilani SB, Zermani R. An aggressive course of de novo ulcerative colitis after renal transplantation: colonic adenocarcinoma with choriocarcinomatous differentiation. *Tunis Med* 2009; **87**: 359-361 [PMID: 19927772]
 - 60 **Gheith O**, Al-Otaibi T, Tawab KA, Said T, Balaha MA, Halim MA, Nair MP, Nampoory MR. Erythema nodosum in renal transplant recipients: multiple cases and review of literature. *Transpl Infect Dis* 2010; **12**: 164-168 [PMID: 20002354 DOI: 10.1111/j.1399-3062.2009.00474.x]
 - 61 **Temme J**, Koziolk M, Bramlage C, Schaefer IM, Füzesi L, Ramadori G, Müller GA, Schwörer H. Infliximab as therapeutic option in steroid-refractory ulcerative colitis after kidney transplantation: case report. *Transplant Proc* 2010; **42**: 3880-3882 [PMID: 21094876 DOI: 10.1016/j.transproceed.2010]
 - 62 **Parameswaran S**, Singh K, Nada R, Rath M, Kohli H, Jha V, Gupta K, Sakhuja V. Ulcerative colitis after renal transplantation: A case report and review of literature. *Indian J Nephrol* 2011; **21**: 120-122 [DOI: 10.4103/0971-4065.78063]
 - 63 **Azevedo P**, Freitas C, Aguiar P, Silva H, Santos T, Farrajota P, Almeida M, Pedroso S, Martins LS, Dias L, Vizcaino R, Henriques AC, Cabrita A. A case series of de novo inflammatory bowel disease after kidney transplantation. *Transplant Proc* 2013; **45**: 1084-1087 [PMID: 23622632 DOI: 10.1016/j.transproceed.2013.03.008]

P- Reviewers: Bonaz BL, Liu ZJ **S- Editor:** Gou SX
L- Editor: A **E- Editor:** Wu HL





Published by **Baishideng Publishing Group Co., Limited**

Flat C, 23/F., Lucky Plaza,
315-321 Lockhart Road, Wan Chai, Hong Kong, China

Fax: +852-65557188

Telephone: +852-31779906

E-mail: bpgoffice@wjgnet.com

<http://www.wjgnet.com>



ISSN 1007-9327



9 771007 932045