

# World Journal of *Clinical Cases*

*World J Clin Cases* 2021 March 16; 9(8): 1761-2021



**REVIEW**

- 1761** Cardiac rehabilitation and its essential role in the secondary prevention of cardiovascular diseases  
*Winnige P, Vysoky R, Dosbaba F, Batalik L*

**ORIGINAL ARTICLE****Case Control Study**

- 1785** Association between homeobox protein transcript antisense intergenic ribonucleic acid genetic polymorphisms and cholangiocarcinoma  
*Lampropoulou DI, Laschos K, Aravantinos G, Georgiou K, Papiris K, Theodoropoulos G, Gazouli M, Filippou D*

**Retrospective Study**

- 1793** Risk factors for post-hepatectomy liver failure in 80 patients  
*Xing Y, Liu ZR, Yu W, Zhang HY, Song MM*
- 1803** Outcomes of laparoscopic bile duct exploration for choledocholithiasis with small common bile duct  
*Huang XX, Wu JY, Bai YN, Wu JY, Lv JH, Chen WZ, Huang LM, Huang RF, Yan ML*

**Observational Study**

- 1814** Three-dimensional finite element analysis with different internal fixation methods through the anterior approach  
*Xie XJ, Cao SL, Tong K, Zhong ZY, Wang G*
- 1827** Bedside cardiopulmonary ultrasonography evaluates lung water content in very low-weight preterm neonates with patent ductus arteriosus  
*Yu LF, Xu CK, Zhao M, Niu L, Huang XM, Zhang ZQ*

**CASE REPORT**

- 1835** Conservative endodontic management using a calcium silicate bioceramic sealer for delayed root fracture: A case report and review of the literature  
*Zheng P, Shen ZY, Fu BP*
- 1844** Brain magnetic resonance imaging findings and radiologic review of maple syrup urine disease: Report of three cases  
*Li Y, Liu X, Duan CF, Song XF, Zhuang XH*
- 1853** A three-year clinical investigation of a Chinese child with craniometaphyseal dysplasia caused by a mutated ANKH gene  
*Wu JL, Li XL, Chen SM, Lan XP, Chen JJ, Li XY, Wang W*
- 1863** Intradural osteomas: Report of two cases  
*Li L, Ying GY, Tang YJ, Wu H*

- 1871** Gastroesophageal varices in a patient presenting with essential thrombocythemia: A case report  
*Wang JB, Gao Y, Liu JW, Dai MG, Yang SW, Ye B*
- 1877** Chest pain showing precordial ST-segment elevation in a 96-year-old woman with right coronary artery occlusion: A case report  
*Wu HY, Cheng G, Cao YW*
- 1885** Subcutaneous panniculitis-like T-cell lymphoma invading central nervous system in long-term clinical remission with lenalidomide: A case report  
*Sun J, Ma XS, Qu LM, Song XS*
- 1893** Imaging findings of primary pulmonary synovial sarcoma with secondary distant metastases: A case report  
*Li R, Teng X, Han WH, Li Y, Liu QW*
- 1901** Severe community-acquired pneumonia caused by *Leptospira interrogans*: A case report and review of literature  
*Bao QH, Yu L, Ding JJ, Chen YJ, Wang JW, Pang JM, Jin Q*
- 1909** Bilateral common peroneal neuropathy due to rapid and marked weight loss after biliary surgery: A case report  
*Oh MW, Gu MS, Kong HH*
- 1916** Retroperitoneal laparoscopic partial resection of the renal pelvis for urothelial carcinoma: A case report  
*Wang YL, Zhang HL, Du H, Wang W, Gao HF, Yu GH, Ren Y*
- 1923** 17 $\alpha$ -hydroxylase/17,20 carbon chain lyase deficiency caused by p.Tyr329fs homozygous mutation: Three case reports  
*Zhang D, Sun JR, Xu J, Xing Y, Zheng M, Ye SD, Zhu J*
- 1931** Epithelioid angiomyolipoma of the pancreas: A case report and review of the literature  
*Zhu QQ, Niu ZF, Yu FD, Wu Y, Wang GB*
- 1940** Computed tomography imaging features for amyloid dacryolith in the nasolacrimal excretory system: A case report  
*Che ZG, Ni T, Wang ZC, Wang DW*
- 1946** Epidural analgesia followed by epidural hydroxyethyl starch prevented post-dural puncture headache: Twenty case reports and a review of the literature  
*Song LL, Zhou Y, Geng ZY*
- 1953** Extracorporeal membrane oxygenation for coronavirus disease 2019-associated acute respiratory distress syndrome: Report of two cases and review of the literature  
*Wen JL, Sun QZ, Cheng Z, Liao XZ, Wang LQ, Yuan Y, Li JW, Hou LS, Gao WJ, Wang WJ, Soh WY, Li BF, Ma DQ*
- 1968** Human parvovirus B19-associated early postoperative acquired pure red cell aplasia in simultaneous pancreas-kidney transplantation: A case report  
*Wang H, Fu YX, Song WL, Wang Z, Feng G, Zhao J, Nian YQ, Cao Y*

- 1976** Diabetes insipidus with impaired vision caused by germinoma and perioptic meningeal seeding: A case report  
*Yang N, Zhu HJ, Yao Y, He LY, Li YX, You H, Zhang HB*
- 1983** Madelung disease: A case report  
*Chen KK, Ni LS, Yu WH*
- 1989** Laryngopharyngeal reflux disease management for recurrent laryngeal contact granuloma: A case report  
*Li K, Chen WY, Li YY, Wang TL, Tan MJ, Chen Z, Chen H*
- 1996** *Mycobacterium abscessus* infection after facial injection of argireline: A case report  
*Chen CF, Liu J, Wang SS, Yao YF, Yu B, Hu XP*
- 2001** Inadvertent globe penetration during retrobulbar anesthesia: A case report  
*Dai Y, Sun T, Gong JF*
- 2008** Systemic lupus erythematosus combined with primary hyperfibrinolysis and protein C and protein S deficiency: A case report  
*Liao YX, Guo YF, Wang YX, Liu AH, Zhang CL*
- 2015** Interstitial lung disease induced by the roots of *Achyranthes japonica* Nakai: Three case reports  
*Moon DS, Yoon SH, Lee SI, Park SG, Na YS*

**ABOUT COVER**

Gokul Sridharan, MD, PhD, Associate Professor, Oral Pathology and Microbiology, YMT Dental College and Hospital, Navi Mumbai, Mumbai 400018, Maharashtra, India. drgokuls@gmail.com

**AIMS AND SCOPE**

The primary aim of *World Journal of Clinical Cases* (WJCC, *World J Clin Cases*) is to provide scholars and readers from various fields of clinical medicine with a platform to publish high-quality clinical research articles and communicate their research findings online.

WJCC mainly publishes articles reporting research results and findings obtained in the field of clinical medicine and covering a wide range of topics, including case control studies, retrospective cohort studies, retrospective studies, clinical trials studies, observational studies, prospective studies, randomized controlled trials, randomized clinical trials, systematic reviews, meta-analysis, and case reports.

**INDEXING/ABSTRACTING**

The WJCC is now indexed in Science Citation Index Expanded (also known as SciSearch®), Journal Citation Reports/Science Edition, Scopus, PubMed, and PubMed Central. The 2020 Edition of Journal Citation Reports® cites the 2019 impact factor (IF) for WJCC as 1.013; IF without journal self cites: 0.991; Ranking: 120 among 165 journals in medicine, general and internal; and Quartile category: Q3. The WJCC's CiteScore for 2019 is 0.3 and Scopus CiteScore rank 2019: General Medicine is 394/529.

**RESPONSIBLE EDITORS FOR THIS ISSUE**

Production Editor: Jia-Hui Li; Production Department Director: Yu-Jie Ma; Editorial Office Director: Jin-Li Wang.

**NAME OF JOURNAL**

*World Journal of Clinical Cases*

**ISSN**

ISSN 2307-8960 (online)

**LAUNCH DATE**

April 16, 2013

**FREQUENCY**

Thrice Monthly

**EDITORS-IN-CHIEF**

Dennis A Bloomfield, Sandro Vento, Bao-Gan Peng

**EDITORIAL BOARD MEMBERS**

<https://www.wjgnet.com/2307-8960/editorialboard.htm>

**PUBLICATION DATE**

March 16, 2021

**COPYRIGHT**

© 2021 Baishideng Publishing Group Inc

**INSTRUCTIONS TO AUTHORS**

<https://www.wjgnet.com/bpg/gerinfo/204>

**GUIDELINES FOR ETHICS DOCUMENTS**

<https://www.wjgnet.com/bpg/gerinfo/287>

**GUIDELINES FOR NON-NATIVE SPEAKERS OF ENGLISH**

<https://www.wjgnet.com/bpg/gerinfo/240>

**PUBLICATION ETHICS**

<https://www.wjgnet.com/bpg/gerinfo/288>

**PUBLICATION MISCONDUCT**

<https://www.wjgnet.com/bpg/gerinfo/208>

**ARTICLE PROCESSING CHARGE**

<https://www.wjgnet.com/bpg/gerinfo/242>

**STEPS FOR SUBMITTING MANUSCRIPTS**

<https://www.wjgnet.com/bpg/gerinfo/239>

**ONLINE SUBMISSION**

<https://www.f6publishing.com>

## Severe community-acquired pneumonia caused by *Leptospira interrogans*: A case report and review of literature

Qiu-Hong Bao, Li Yu, Jian-Jun Ding, Ying-Jun Chen, Jun-Wei Wang, Jian-Ming Pang, Qi Jin

**ORCID number:** Qiu-Hong Bao 0000-0001-7993-3126; Li Yu 0000-0001-8660-4064; Jian-Jun Ding 0000-0003-4020-3745; Ying-Jun Chen 0000-0001-6638-3364; Jun-Wei Wang 0000-0001-9278-5041; Jian-Ming Pang 0000-0002-3613-6191; Qi Jin 0000-0001-8521-8145.

**Author contributions:** Bao QH and Jin Q contributed to conception and design, manuscript writing and final approval of the manuscript; Wang JW and Pang JM performed the research; Chen YJ provided financial support and manuscript writing; Ding JJ and Yu L analyzed the data and wrote the manuscript; all authors have read and approved the final manuscript.

**Supported by** Basic Public Welfare Research Scheme of Zhejiang Province, No. GF19H030001.

**Informed consent statement:** Informed written consent was obtained from the patient for publication of this report and any accompanying images.

**Conflict-of-interest statement:** The authors declare that they have no conflict of interest.

**CARE Checklist (2016) statement:** The authors have read the CARE Checklist (2016), and the manuscript was prepared and revised according to the CARE

**Qiu-Hong Bao, Jian-Ming Pang,** Department of Respiratory and Critical Medicine, Tiantai Hospital of Hangzhou Medical College, Tiantai 317200, Zhejiang Province, China

**Li Yu, Ying-Jun Chen, Jun-Wei Wang,** Department of Infectious Disease, Tiantai Hospital of Hangzhou Medical College, Tiantai 317200, Zhejiang Province, China

**Jian-Jun Ding,** Department of Critical Care Medicine, Tiantai Hospital of Hangzhou Medical College, Tiantai 317200, Zhejiang Province, China

**Qi Jin,** ICU Administration, Tiantai Hospital of Hangzhou Medical College, Taizhou 317200, Zhejiang Province, China

**Corresponding author:** Qi Jin, MD, Chief Physician, ICU Administration, Tiantai Hospital of Hangzhou Medical College, No. 1 Middle Corning Road, Shifeng Street, Taizhou 317200, Zhejiang Province, China. [991044@sina.com](mailto:991044@sina.com)

### Abstract

#### BACKGROUND

*Leptospira* is an uncommon pathogen for adult severe community-acquired pneumonia and its nonspecific manifestations and limited diagnostic tests make it difficult to identify. Although conventional penicillin remains efficacious to treat leptospirosis, failure in early diagnosis and treatment can lead to progression into a deadly syndrome with multiple organ dysfunction. Next generation sequencing is of great value to understand cases with infection of unknown cause, which could help in the diagnosis of uncertain *Leptospira* infection.

#### CASE SUMMARY

We recently managed a patient with fever, cough and dyspnea on admission that progressed into persistent adult respiratory distress syndrome, hemoptysis and hematuria after admission. In this case, the rare *Leptospira* infection was clouded by the positive influenza tests at admission, delaying early *Leptospira*-targeted antibiotics administration. Next generation sequencing, a novel molecular diagnostic tool, provided a key hint to uncover the crucial pathogen, *Leptospira interrogans*, further supported by the possible occupational exposure history. Subsequent conventional penicillin and mechanical respiratory support were administrated to cure the patient successfully without any sequela.

#### CONCLUSION

Clinicians must pay attention to possible exposure history and keep uncommon



Checklist (2016).

**Open-Access:** This article is an open-access article that was selected by an in-house editor and fully peer-reviewed by external reviewers. It is distributed in accordance with the Creative Commons Attribution NonCommercial (CC BY-NC 4.0) license, which permits others to distribute, remix, adapt, build upon this work non-commercially, and license their derivative works on different terms, provided the original work is properly cited and the use is non-commercial. See: <http://creativecommons.org/licenses/by-nc/4.0/>

**Manuscript source:** Unsolicited manuscript

**Specialty type:** Medicine, research and experimental

**Country/Territory of origin:** China

**Peer-review report's scientific quality classification**

Grade A (Excellent): 0  
Grade B (Very good): 0  
Grade C (Good): 0  
Grade D (Fair): 0  
Grade E (Poor): 0

**Received:** October 15, 2020

**Peer-review started:** October 15, 2020

**First decision:** December 13, 2020

**Revised:** December 24, 2020

**Accepted:** January 28, 2021

**Article in press:** January 28, 2021

**Published online:** March 16, 2021

**P-Reviewer:** Chan SM

**S-Editor:** Gao CC

**L-Editor:** Filipodia

**P-Editor:** Liu JH



*Leptospira* in mind when managing pneumonia with unknown causes.

**Key Words:** *Leptospira interrogans*; Pneumonia; Next generation sequencing; Influenza; Diagnosis; Case report

©The Author(s) 2021. Published by Baishideng Publishing Group Inc. All rights reserved.

**Core Tip:** Pneumonia caused by *Leptospira interrogans* is rare but life-threatening. In the early phase, the nonspecific symptoms of *Leptospira* pneumonia often lead clinicians to misdiagnosis as influenza or other illness. We herein report a 54-year-old man who presented with cough, fever and dyspnea and was misdiagnosed with influenza but was confirmed with *Leptospira* infection with the help of next generation sequencing. Possible exposure history and next generation sequencing during management of infections with unknown causes are important.

**Citation:** Bao QH, Yu L, Ding JJ, Chen YJ, Wang JW, Pang JM, Jin Q. Severe community-acquired pneumonia caused by *Leptospira interrogans*: A case report and review of literature. *World J Clin Cases* 2021; 9(8): 1901-1908

**URL:** <https://www.wjgnet.com/2307-8960/full/v9/i8/1901.htm>

**DOI:** <https://dx.doi.org/10.12998/wjcc.v9.i8.1901>

## INTRODUCTION

Community-acquired pneumonia (CAP) is a common but multifactorial disease, and nearly a quarter are attributed to *Streptococcus pneumoniae*<sup>[1]</sup>. *Leptospira interrogans* is a rare pathogen also responsible for adult CAP with a high fatality rate. With the increase of international travel, global warming and urban slum settlements, leptospirosis is re-emerging as an infectious disease worldwide, not only limited to tropic developing areas<sup>[2-4]</sup>. Relatively few cases have been reported in China in recent years. However, morbidity and mortality of *Leptospira* infection are thought to be underestimated because of lack of clinical vigilance, nonspecific clinical symptoms and limited availability of rapid and accurate diagnostic tests, which poses challenges to timely and effective clinical judgment and treatment<sup>[5-7]</sup>.

This phenomenon may also result in little systematic research and understanding of the relationship between pneumonia and *Leptospira*. The application of next generation sequencing (NGS) has greatly promoted our knowledge of pneumonia-related pathogens ranging from their subtypes to their pathogenic characteristics<sup>[8]</sup>. Herein, we report a case of a 54-year-old man with severe pneumonia caused by *Leptospira*, which was misdiagnosed as viral pneumonia at admission. In this paper, we will discuss how we made the final diagnosis of *Leptospira* infection. This case will enhance the understanding of *Leptospira* infection and remind clinicians to remember it when managing pneumonia of unknown cause.

## CASE PRESENTATION

### Chief complaints

A 54-year-old man presented with a 4 d history of cough with white phlegm, chills and fever as well as dyspnea for 1 d. No hemoptysis, chest pain, edema or rash were found.

### History of present illness

Before this visit, he had been given 1.5 g of intravenous cefuroxime but received little improvement. According to the above examinations, the initial diagnosis was considered severe pneumonia caused by influenza virus. Thus, the patient was treated with methylprednisolone (40 mg, q12 h), oseltamivir (75 mg, bid), tienam (0.5 g, q8 h) and moxifloxacin (0.4 g qd). Unexpectedly the next morning, the patient's condition worsened into cough with bloody sputum and shortness of breath with decreased

SpO<sub>2</sub> to 60%. Hence, the patient was managed with intubation and continuous mechanical ventilation of positive end-expiratory pressure 8 cm H<sub>2</sub>O, FiO<sub>2</sub> 40% and SpO<sub>2</sub> 99%. Caspofungin was added to the initial therapeutic plan.

Further examinations were also performed to find the essential causes. Sputum smear test showed no positive findings. Bronchoscopy showed sporadic mucosal petechiae and bloody sputum in the bilateral bronchi (Figure 1), and bronchoalveolar lavage fluid (BALF) was collected. Echocardiography revealed left ventricular diastolic dysfunction and moderate tricuspid regurgitation with pulmonary arterial hypertension. The patient was negative for acid-fast bacilli stain, fungi test of BALF, tumor makers and a panel of respiratory viruses and autoantibodies. Under the current comprehensive treatment covering anti-infections of virus, bacteria and fungi, the patient did not improve and had persistent hemoptysis and hematuria under assisted ventilation. Inflammation and myocardial impairment-related laboratory values were elevated, and hemoglobin and platelet counts remained below normal levels (Figure 2).

The NGS report of the BALF on day 6 after admission indicated the cause. To our surprise, NGS indicated an infection of *Leptospira interrogans*. Subsequently, it was retrospectively interviewed that the patient worked as a rubbish cleaner of rivers with high exposure risk of *Leptospira* infection.

### History of past illness

The patient reported a 30 yr history of smoking and drinking. He denied any history of hypertension, diabetes or other chronic disease.

### Personal and family history

The patient and his families denied any history of hypertension, diabetes or other chronic disease.

### Physical examination

On examination, his temperature was 37.5 °C, pulse was 118/min, respiratory rate was 19/min, and blood pressure was 81/54 mmHg at admission. He was in a conscious state but in compulsive position with cyanotic face. His superficial lymph nodes were not swollen. Lung examination showed bilateral rales. Other physical examinations were normal.

### Laboratory examinations

Arterial blood gas analysis showed lower PaO<sub>2</sub> of 64 mmHg and SpO<sub>2</sub> of 94.3% with 2 L/min oxygen support. Laboratory investigations revealed decreased white blood cell count of  $1.7 \times 10^9$ /L and platelet count of  $56 \times 10^9$ /L, elevated C-reactive protein of 190.81 mg/L, creatinine phosphokinase of 372 U/L, creatinine of 117 μmol/L and activated partial thromboplastin ratio of 1.30 and a positive urine occult blood test. The throat swab for influenza virus antigen was positive.

### Imaging examinations

Chest computed tomography (CT) indicated infectious lesions of both lungs and emphysema with pulmonary bullae (Figure 3A).

---

## FINAL DIAGNOSIS

---

Severe pneumonia with *Leptospira interrogans* infection.

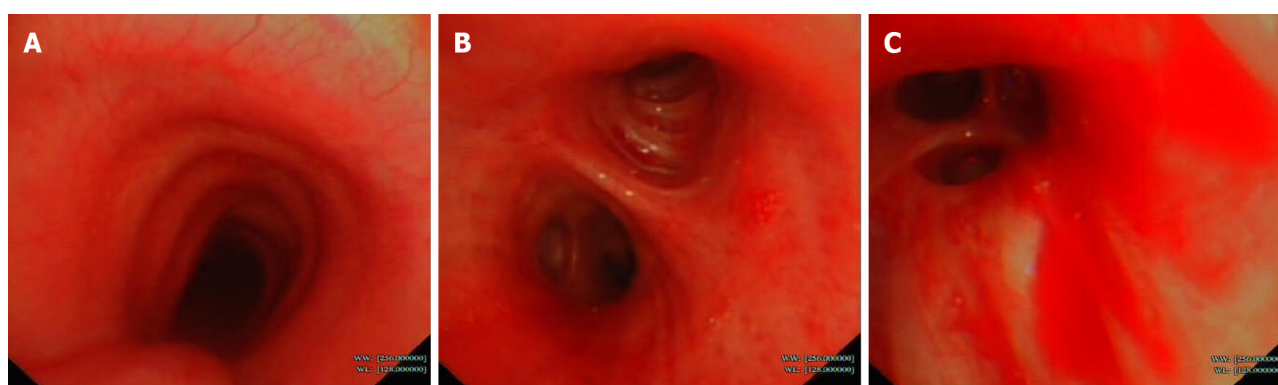
---

## TREATMENT

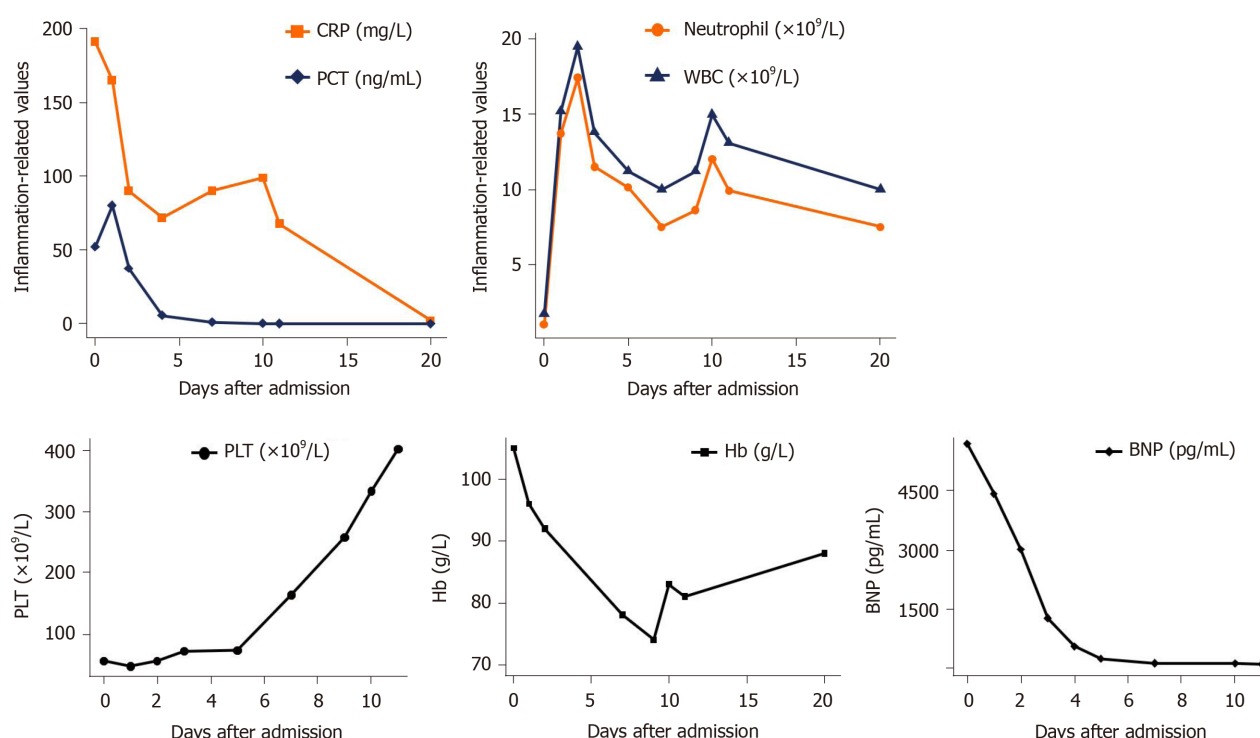
---

After identification of the *Leptospira* pathogen, the patients finally received penicillin (400000 U, q12 h, im) for 1 wk as well as respiratory support, while previous administration of oseltamivir and caspofungin was stopped. After 1 wk, with advice of the infection department, the usage of penicillin was doubled for 2 d and then doubled again for another 1 wk.





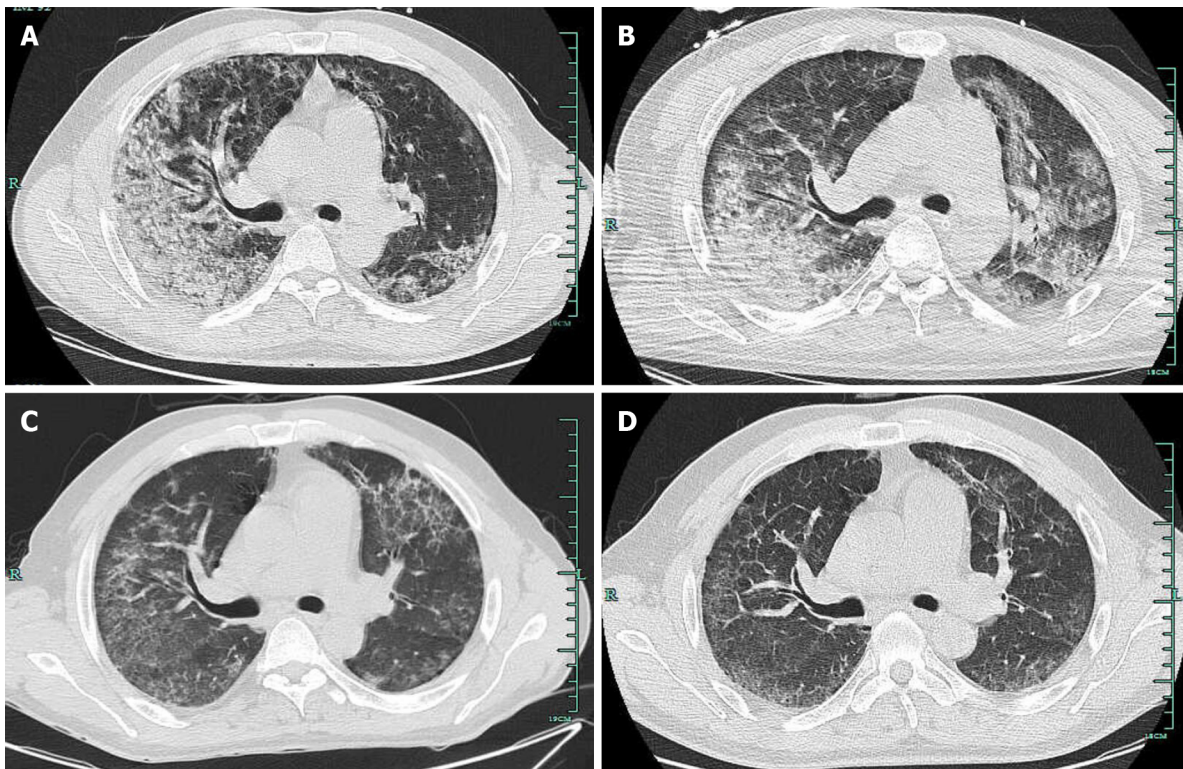
**Figure 1 Bronchoscopy findings.** A-C: Bronchoscopy images of main trachea (A), left main bronchus (B) and opening of the right basal segmental bronchus (C) showed that the bronchi were patent, and sporadic mucosal petechiae and bloody sputum were seen in the bilateral bronchi.



**Figure 2 Changes in laboratory parameters after admission.** In the first 5 d of antiviral treatment after admission: inflammatory values were elevated; platelets and hemoglobin were decreased consistent with hemorrhagic complications; and elevated brain natriuretic peptide indicated the existence of myocardial impairment. After 5 d, penicillin was administered and the above vital parameters improved. WBC: White blood cell; CRP: C-reactive protein; PCT: Procalcitonin; PLT: Platelets; Hb: Hemoglobin; BNP: Brain natriuretic peptide.

## OUTCOME AND FOLLOW-UP

After about 1 wk of penicillin treatment, the patient obviously got better with significantly relieved cough and hemoptysis as well as improved oxygenation status without mechanical ventilation ( $PaO_2$  78 mmHg,  $SpO_2$  95.3 under 5 L/min oxygen flow). Additionally, echocardiography of mild mitral and tricuspid regurgitation and decreased brain natriuretic peptide suggested the improvement of myocardial damage. Chest CT also showed the bilateral lung inflammation was greatly resolved (Figure 3C). After a total of 16 d of penicillin, the patient was discharged home without any complaint. Most laboratory values were returning to normal (Figure 2). Follow-up chest CT after discharge was almost completely cleared with no recurrence (Figure 3D).



**Figure 3 Computed tomography findings.** A-D: Computed tomography images were respectively taken on admission (A), 1 wk after admission (B), 1 wk before discharge (C), and 3 wk after discharge (D). Gradual resolution of inflammation in the bilateral lungs was seen during the treatment course.

## DISCUSSION

The main pathogens of CAP in China are *Streptococcus pneumoniae* and *Mycoplasma pneumoniae*. Other common related-pathogens include *Hemophilus influenzae*, *Chlamydia*, *Klebsiella pneumoniae* and *Staphylococcus aureus*<sup>[1]</sup>. Respiratory virus, especially influenza, rhinovirus and coronavirus, is reported to be responsible for a third of adult pneumonia cases<sup>[9]</sup>. By comparison, pneumonia caused by *Leptospira* is rare and seldom reported. *Leptospira interrogans*, detected in this case, is one type of pathogenic spirochetes and could cause zoonotic leptospirosis. Leptospirosis is estimated to affect over one million people and accounts for about 60000 deaths annually worldwide<sup>[3]</sup>. Clinical manifestations of leptospirosis vary, ranging from subclinical status, mild influenza-like illness to severe multiple organ dysfunction, including kidney, liver, heart and lung. The typical severe syndrome, named “Weil’s disease”, is characterized by jaundice and renal failure with hemorrhagic complications<sup>[10]</sup>.

Pulmonary involvement of leptospirosis occurs in 20%-70% of patients<sup>[11]</sup> and is mostly secondary to renal and hepatic dysfunction as an immunity-mediated status<sup>[12,13]</sup>, including mild to severe pneumonia, deadly alveolar hemorrhage, adult respiratory distress syndrome, *etc.*<sup>[12]</sup> and manifesting as cough, dyspnea, hemoptysis, *etc.* As observed in this case lung involvement of severe pneumonia was primary and main manifestations were relatively few. However, mortality from severe lung involvement like adult respiratory distress syndrome and pulmonary hemorrhage greatly exceeds that from Weil’s disease (> 50% *vs* > 10%), although optimal treatment is given<sup>[14]</sup>. It is the nonspecificity and diversity of clinical symptoms, particularly atypical manifestations, that lead to lack of clinical suspicion, which delays targeted detection and treatment of leptospirosis and increases mortality.

Common laboratory biochemical tests of leptospirosis usually show no specific abnormalities compared with most infectious diseases. For *Leptospira*-related pneumonia, chest CT may show ground-glass opacities, consolidation and small pleural effusion, which could also be observed in radiographs of influenza pneumonia<sup>[12,15]</sup>. Thus, it is possible to misdiagnose this case as influenza pneumonia, especially based on evidence from the initial throat swab test. During hospitalization, bronchoscopy with BALF collection was required because it could help to identify hemorrhage even if it remained occult and to obtain samples for etiological tests. Overall, for differential diagnosis, persistent hemorrhagic complications and related

abnormal values, which are relatively few in influenza-associated pneumonia under corresponding antiviral treatment, it may be the only hint to raise doubt of the initial diagnosis and treatment plan.

For the final etiological diagnosis, serological tests and isolation of *Leptospira* are usually considered as the prior standard diagnostic methods for leptospirosis, including conventional microscopic agglutination test and enzyme-linked immunosorbent assay<sup>[7,16]</sup>, whereas patient autoimmune status, previous medications with immunosuppressor and antibiotics and timing of specimen collection lead to an inevitable bias in etiological tests<sup>[17]</sup>. Polymerase chain reaction, as the representative of current molecular tests, is another widely-used and reliable diagnostic tool<sup>[7]</sup>. However, these methods share several common drawbacks, such as failing to discriminate among widely-diverse *Leptospira* serotypes and only targeting some specific pathogens based on clinical prejudgments<sup>[7,18]</sup>.

NGS, applied in our case, is a rapid and high-throughput assay that determines the entire nucleotide sequences of a sample in a single run without any target primers or probes<sup>[19]</sup>. NGS could identify a variety of microorganisms at one detection and provide data about typing, virulence and antimicrobial resistance simultaneously<sup>[8]</sup>. Many previous reports confirmed that NGS offers great advantages in diagnosis and management of infectious diseases of undetermined, uncommon or emerging origins<sup>[20-22]</sup> and were superior to traditional detecting techniques. It should be noted that not all microorganisms detected by NGS, like internal colonizing bacteria, bear responsibility for the diseases. To identify the crucial pathogens, clinicians need to combine NGS results with contact history, clinical symptoms and other laboratory tests to make a comprehensive interpretation.

Penicillin remains the first choice for treatment of leptospirosis recommended by the World Health Organization because no penicillin-resistant strains have been found so far. Other antibiotics like doxycycline, tetracycline and amoxicillin are also preferred. Early and suitable administration of antibiotics could shorten disease course, decrease mortality and prevent deterioration<sup>[22]</sup>. For patients with severe pulmonary illness of leptospirosis, as observed in, hemodynamic and respiratory support are urgent. Mechanical ventilation should be a priority to deal with severe pulmonary hemorrhage<sup>[23]</sup>. Recently, extracorporeal membrane oxygenation, as a salvage intervention, is also confirmed to benefit the management of severe pulmonary leptospirosis<sup>[18]</sup>. Immunomodulation therapy is expected to promote recovery from leptospirosis. Rodrigo *et al*<sup>[24]</sup> reviewed that steroids may only improve the outcomes of pulmonary leptospirosis but not benefit other clinical subtypes. Several reports and trials supported utilization of glucocorticoids, and Shenoy *et al*<sup>[25]</sup> concluded use of corticosteroids within the first 24 h of onset of pulmonary illness could reduce the need for assisted ventilation<sup>[16,25-27]</sup>. Additionally, activated factor VII, desmopressin cyclophosphamide and hemofiltration have been used in several refractory cases<sup>[28,29]</sup>.

Prevention measures play an important role in management of leptospirosis. It is well-known that pathogenic *Leptospira* invades bodies *via* skin and mucosa abrasion. Indirect infection by contact with contaminated water or soil is more common than direct contact with infected mammals. Avoiding exposure to pathogens, such as wearing boots and goggles, is the most important protective measures for people with potential occupational risk, like the river-trash cleaner in this case. Although vaccines against *Leptospira* have been available since 1886, its general application still faces great challenges. Current qualified vaccines are restricted to partial serotypes and provide short-term immunity and are only available in several specific epidemic areas<sup>[30]</sup>. In addition, oral doxycycline can be used as chemoprophylaxis for high-risk people such as rescuers in floods<sup>[31]</sup>.

## CONCLUSION

In summary, severe CAP caused by *Leptospira* is uncommon, but it poses a considerable threat to public health. Although the lack of specific clinical symptoms and high-efficient diagnostic tools make it hard to discriminate from other infectious diseases, many measures could be taken to correctly diagnose the disease. First, high clinical suspicion of *Leptospira* infection is vital to handle severe pneumonia patients, especially those with hemorrhage complications. Second, recognition of high-risk people in contact with possible infected mammals or contaminated water or soil will give strong evidence to diagnosis. Third, NGS has great advantages in identification of undetermined or uncommon pathogens, which could provide hints for diagnosis and



treatment. However, because of high costs and technical requirements, the application of NGS may be the final choice. Moreover, radiological and bronchoscopy tests are needed to provide further evidence to confirm and evaluate the lung involvement of leptospirosis. Given systematic leptospirosis, other organ functions, like kidney, liver and heart, need to be monitored. Early and overall assessment and timely comprehensive treatment composed of antibiotics, respiratory support and immunomodulation are critical to prevent the rapid progression, improve prognosis and promote rehabilitation of the severe lung leptospirosis.

## ACKNOWLEDGEMENTS

We are grateful to the reviewers and editor for their constructive comments.

## REFERENCES

- 1 **Prina E**, Ranzani OT, Torres A. Community-acquired pneumonia. *Lancet* 2015; **386**: 1097-1108 [PMID: 26277247 DOI: 10.1016/S0140-6736(15)60733-4]
- 2 **Bharti AR**, Nally JE, Ricaldi JN, Matthias MA, Diaz MM, Lovett MA, Levett PN, Gilman RH, Willig MR, Gotuzzo E, Vinetz JM; Peru-United States Leptospirosis Consortium. Leptospirosis: a zoonotic disease of global importance. *Lancet Infect Dis* 2003; **3**: 757-771 [PMID: 14652202 DOI: 10.1016/S1473-3099(03)00830-2]
- 3 **Costa F**, Hagan JE, Calcagno J, Kane M, Torgerson P, Martinez-Silveira MS, Stein C, Abela-Ridder B, Ko AI. Global Morbidity and Mortality of Leptospirosis: A Systematic Review. *PLoS Negl Trop Dis* 2015; **9**: e0003898 [PMID: 26379143 DOI: 10.1371/journal.pntd.0003898]
- 4 **Reis RB**, Ribeiro GS, Felzemburgh RD, Santana FS, Mohr S, Melendez AX, Queiroz A, Santos AC, Ravines RR, Tassinari WS, Carvalho MS, Reis MG, Ko AI. Impact of environment and social gradient on *Leptospira* infection in urban slums. *PLoS Negl Trop Dis* 2008; **2**: e228 [PMID: 18431445 DOI: 10.1371/journal.pntd.0000228]
- 5 **Karpagam KB**, Ganesh B. Leptospirosis: a neglected tropical zoonotic infection of public health importance-an updated review. *Eur J Clin Microbiol Infect Dis* 2020; **39**: 835-846 [PMID: 31898795 DOI: 10.1007/s10096-019-03797-4]
- 6 **Soo ZMP**, Khan NA, Siddiqui R. Leptospirosis: Increasing importance in developing countries. *Acta Trop* 2020; **201**: 105183 [PMID: 31542372 DOI: 10.1016/j.actatropica.2019.105183]
- 7 **Marquez A**, Djelouadji Z, Lattard V, Kodjo A. Overview of laboratory methods to diagnose Leptospirosis and to identify and to type leptospires. *Int Microbiol* 2017; **20**: 184-193 [PMID: 29529330 DOI: 10.2436/20.1501.01.302]
- 8 **Gwinn M**, MacCannell D, Armstrong GL. Next-Generation Sequencing of Infectious Pathogens. *JAMA* 2019; **321**: 893-894 [PMID: 30763433 DOI: 10.1001/jama.2018.21669]
- 9 **Ruuskanen O**, Lahti E, Jennings LC, Murdoch DR. Viral pneumonia. *Lancet* 2011; **377**: 1264-1275 [PMID: 21435708 DOI: 10.1016/S0140-6736(10)61459-6]
- 10 **AREAN VM**. The pathologic anatomy and pathogenesis of fatal human leptospirosis (Weil's disease). *Am J Pathol* 1962; **40**: 393-423 [PMID: 13862141]
- 11 **Carvalho CR**, Bethlem EP. Pulmonary complications of leptospirosis. *Clin Chest Med* 2002; **23**: 469-478 [PMID: 12092040 DOI: 10.1016/S0272-5231(01)00010-7]
- 12 **Marchiori E**, Lourenço S, Setúbal S, Zanetti G, Gasparetto TD, Hochhegger B. Clinical and imaging manifestations of hemorrhagic pulmonary leptospirosis: a state-of-the-art review. *Lung* 2011; **189**: 1-9 [PMID: 21152929 DOI: 10.1007/s00408-010-9273-0]
- 13 **De Brito T**, Silva AMGD, Abreu PAE. Pathology and pathogenesis of human leptospirosis: a commented review. *Rev Inst Med Trop Sao Paulo* 2018; **60**: e23 [PMID: 29846473 DOI: 10.1590/S1678-9946201860023]
- 14 **McBride AJ**, Athanazio DA, Reis MG, Ko AI. Leptospirosis. *Curr Opin Infect Dis* 2005; **18**: 376-386 [PMID: 16148523 DOI: 10.1097/01.qco.0000178824.05715.2c]
- 15 **Koo HJ**, Lim S, Choe J, Choi SH, Sung H, Do KH. Radiographic and CT Features of Viral Pneumonia. *Radiographics* 2018; **38**: 719-739 [PMID: 29757717 DOI: 10.1148/rg.2018170048]
- 16 **Agrawal VK**, Bansal A, Pujani M. A rare case of leptospirosis with isolated lung involvement. *Indian J Crit Care Med* 2015; **19**: 174-176 [PMID: 25810615 DOI: 10.4103/0972-5229.152765]
- 17 **Haake DA**, Levett PN. Leptospirosis in humans. *Curr Top Microbiol Immunol* 2015; **387**: 65-97 [PMID: 25388133 DOI: 10.1007/978-3-662-45059-8\_5]
- 18 **Héry G**, Lethuille J, Flécher E, Quentin C, Piau C, Le Tulzo Y, Tattevin P. Massive intra-alveolar hemorrhage caused by *Leptospira* serovar Djasiman in a traveler returning from Laos. *J Travel Med* 2015; **22**: 212-214 [PMID: 25728613 DOI: 10.1111/jtm.12189]
- 19 **Deurenberg RH**, Bathoorn E, Chlebowicz MA, Couto N, Ferdous M, García-Cobos S, Kooistra-Smid AM, Raangs EC, Rosema S, Veloo AC, Zhou K, Friedrich AW, Rossen JW. Application of next generation sequencing in clinical microbiology and infection prevention. *J Biotechnol* 2017; **243**: 16-24 [PMID: 28042011 DOI: 10.1016/j.jbiotec.2016.12.022]

- 20 **Wilson MR**, Naccache SN, Samayoa E, Biagtan M, Bashir H, Yu G, Salamat SM, Somasekar S, Federman S, Miller S, Sokolic R, Garabedian E, Candotti F, Buckley RH, Reed KD, Meyer TL, Seroogy CM, Galloway R, Henderson SL, Gern JE, DeRisi JL, Chiu CY. Actionable diagnosis of neuroleptospirosis by next-generation sequencing. *N Engl J Med* 2014; **370**: 2408-2417 [PMID: [24896819](#) DOI: [10.1056/NEJMoa1401268](#)]
- 21 **Briese T**, Paweska JT, McMullan LK, Hutchison SK, Street C, Palacios G, Khristova ML, Weyer J, Swanepoel R, Egholm M, Nichol ST, Lipkin WI. Genetic detection and characterization of Lujo virus, a new hemorrhagic fever-associated arenavirus from southern Africa. *PLoS Pathog* 2009; **5**: e1000455 [PMID: [19478873](#) DOI: [10.1371/journal.ppat.1000455](#)]
- 22 **Palacios G**, Druce J, Du L, Tran T, Birch C, Briese T, Conlan S, Quan PL, Hui J, Marshall J, Simons JF, Egholm M, Paddock CD, Shieh WJ, Goldsmith CS, Zaki SR, Catton M, Lipkin WI. A new arenavirus in a cluster of fatal transplant-associated diseases. *N Engl J Med* 2008; **358**: 991-998 [PMID: [18256387](#) DOI: [10.1056/NEJMoa073785](#)]
- 23 **Goarant C**. Leptospirosis: risk factors and management challenges in developing countries. *Res Rep Trop Med* 2016; **7**: 49-62 [PMID: [30050339](#) DOI: [10.2147/RRTM.S102543](#)]
- 24 **Rodrigo C**, Lakshitha de Silva N, Goonaratne R, Samarasekara K, Wijesinghe I, Parththipan B, Rajapakse S. High dose corticosteroids in severe leptospirosis: a systematic review. *Trans R Soc Trop Med Hyg* 2014; **108**: 743-750 [PMID: [25266477](#) DOI: [10.1093/trstmh/tru148](#)]
- 25 **Shenoy VV**, Nagar VS, Chowdhury AA, Bhalgat PS, Juvele NI. Pulmonary leptospirosis: an excellent response to bolus methylprednisolone. *Postgrad Med J* 2006; **82**: 602-606 [PMID: [16954459](#) DOI: [10.1136/pgmj.2005.044255](#)]
- 26 **Niwattayakul K**, Kaewtasi S, Chueasuwanchai S, Hoontrakul S, Chareonwat S, Suttinont C, Phimda K, Chierakul W, Silpasakorn S, Suputtamongkol Y. An open randomized controlled trial of desmopressin and pulse dexamethasone as adjunct therapy in patients with pulmonary involvement associated with severe leptospirosis. *Clin Microbiol Infect* 2010; **16**: 1207-1212 [PMID: [19732091](#) DOI: [10.1111/j.1469-0691.2009.03037.x](#)]
- 27 **Trivedi SV**, Chavda RK, Wadia PZ, Sheth V, Bhagade PN, Trivedi SP, Clerk AM, Mevawala DM. The role of glucocorticoid pulse therapy in pulmonary involvement in leptospirosis. *J Assoc Physicians India* 2001; **49**: 901-903 [PMID: [11837758](#)]
- 28 **Trivedi SV**, Vasava AH, Patel TC, Bhatia LC. Cyclophosphamide in pulmonary alveolar hemorrhage due to leptospirosis. *Indian J Crit Care Med* 2009; **13**: 79-84 [PMID: [19881188](#) DOI: [10.4103/0972-5229.56053](#)]
- 29 **Tatopoulos A**, Herbain D, Kazmierczak C, Bollaert PE, Gibot S. Parenteral use of recombinant activated factor VII during diffuse alveolar hemorrhage secondary to leptospirosis. *Intensive Care Med* 2010; **36**: 555-556 [PMID: [19924396](#) DOI: [10.1007/s00134-009-1718-7](#)]
- 30 **Xu Y**, Ye Q. Human leptospirosis vaccines in China. *Hum Vaccin Immunother* 2018; **14**: 984-993 [PMID: [29148958](#) DOI: [10.1080/21645515.2017.1405884](#)]
- 31 **Schneider MC**, Velasco-Hernandez J, Min KD, Leonel DG, Baca-Carrasco D, Gompper ME, Hartskeerl R, Munoz-Zanzi C. The Use of Chemoprophylaxis after Floods to Reduce the Occurrence and Impact of Leptospirosis Outbreaks. *Int J Environ Res Public Health* 2017; **14** [PMID: [28587195](#) DOI: [10.3390/ijerph14060594](#)]





Published by **Baishideng Publishing Group Inc**  
7041 Koll Center Parkway, Suite 160, Pleasanton, CA 94566, USA

**Telephone:** +1-925-3991568

**E-mail:** [bpgoffice@wjgnet.com](mailto:bpgoffice@wjgnet.com)

**Help Desk:** <https://www.f6publishing.com/helpdesk>

<https://www.wjgnet.com>

