

World Journal of *Clinical Cases*

World J Clin Cases 2021 June 16; 9(17): 4116-4459



Contents

Thrice Monthly Volume 9 Number 17 June 16, 2021

EDITORIAL

- 4116 Is it time to put traditional cold therapy in rehabilitation of soft-tissue injuries out to pasture?
Wang ZR, Ni GX

MINIREVIEWS

- 4123 Health-related quality of life after gastric cancer treatment in Brazil: Narrative review and reflections
Pinheiro RN, Mucci S, Zanatto RM, Picanço Junior OM, Oliveira AF, Lopes Filho GJ
- 4133 Nonalcoholic fatty liver disease and COVID-19: An epidemic that begets pandemic
Ahmed M, Ahmed MH

ORIGINAL ARTICLE

Retrospective Study

- 4143 Why MUC16 mutations lead to a better prognosis: A study based on The Cancer Genome Atlas gastric cancer cohort
Huang YJ, Cao ZF, Wang J, Yang J, Wei YJ, Tang YC, Cheng YX, Zhou J, Zhang ZX
- 4159 Design and development of a new type of phimosis dilatation retractor for children
Yue YW, Chen YW, Deng LP, Zhu HL, Feng JH
- 4166 Primary needle-knife fistulotomy for preventing post-endoscopic retrograde cholangiopancreatography pancreatitis: Importance of the endoscopist's expertise level
Han SY, Baek DH, Kim DU, Park CJ, Park YJ, Lee MW, Song GA

Observational Study

- 4178 Patients with functional bowel disorder have disaccharidase deficiency: A single-center study from Russia
Dbar S, Akhmadullina O, Sabelnikova E, Belostotskiy N, Parfenov A, Bykova S, Bakharev S, Baulo E, Babanova A, Indeykina L, Kuzmina T, Kosacheva T, Spasenov A, Makarova A
- 4188 Self-perceived burden and influencing factors in patients with cervical cancer administered with radiotherapy
Luo T, Xie RZ, Huang YX, Gong XH, Qin HY, Wu YX

SYSTEMATIC REVIEWS

- 4199 COVID-19 in gastroenterology and hepatology: Lessons learned and questions to be answered
Liu S, Tang MM, Du J, Gong ZC, Sun SS

META-ANALYSIS

- 4210** Efficacy of topical *vs* intravenous tranexamic acid in reducing blood loss and promoting wound healing in bone surgery: A systematic review and meta-analysis

Xu JW, Qiang H, Li TL, Wang Y, Wei XX, Li F

CASE REPORT

- 4221** *Ex vivo* liver resection followed by autotransplantation in radical resection of gastric cancer liver metastases: A case report

Wang H, Zhang CC, Ou YJ, Zhang LD

- 4230** Bone marrow inhibition induced by azathioprine in a patient without mutation in the thiopurine S-methyltransferase pathogenic site: A case report

Zhou XS, Lu YY, Gao YF, Shao W, Yao J

- 4238** Eosinophilic gastroenteritis with abdominal pain and ascites: A case report

Tian XQ, Chen X, Chen SL

- 4244** Tunica vaginalis testis metastasis as the first clinical manifestation of pancreatic adenocarcinoma: A case report

Zhang YR, Ma DK, Gao BS, An W, Guo KM

- 4253** “AFGP” bundles for an extremely preterm infant who underwent difficult removal of a peripherally inserted central catheter: A case report

Chen Q, Hu YL, Su SY, Huang X, Li YX

- 4262** Dynamic magnetic resonance imaging features of cavernous hemangioma in the manubrium: A case report

Lin TT, Hsu HH, Lee SC, Peng YJ, Ko KH

- 4268** Diagnosis and treatment of pediatric anaplastic lymphoma kinase-positive large B-cell lymphoma: A case report

Zhang M, Jin L, Duan YL, Yang J, Huang S, Jin M, Zhu GH, Gao C, Liu Y, Zhang N, Zhou CJ, Gao ZF, Zheng QL, Chen D, Zhang YH

- 4279** Stevens-Johnson syndrome and concurrent hand foot syndrome during treatment with capecitabine: A case report

Ahn HR, Lee SK, Youn HJ, Yun SK, Lee IJ

- 4285** Rosai-Dorfman disease with lung involvement in a 10-year-old patient: A case report

Wu GJ, Li BB, Zhu RL, Yang CJ, Chen WY

- 4294** Acute myocardial infarction in twin pregnancy after assisted reproduction: A case report

Dai NN, Zhou R, Zhuo YL, Sun L, Xiao MY, Wu SJ, Yu HX, Li QY

- 4303** Complete recovery of herpes zoster radiculopathy based on electrodiagnostic study: A case report

Kim HS, Jung JW, Jung YJ, Ro YS, Park SB, Lee KH

- 4310** Acute liver failure with thrombotic microangiopathy due to sodium valproate toxicity: A case report
Mei X, Wu HC, Ruan M, Cai LR
- 4318** Lateral epicondyle osteotomy approach for coronal shear fractures of the distal humerus: Report of three cases and review of the literature
Li J, Martin VT, Su ZW, Li DT, Zhai QY, Yu B
- 4327** Pancreatic neuroendocrine carcinoma in a pregnant woman: A case report and review of the literature
Gao LP, Kong GX, Wang X, Ma HM, Ding FF, Li TD
- 4336** Primary primitive neuroectodermal tumor in the pericardium—a focus on imaging findings: A case report
Xu SM, Bai J, Cai JH
- 4342** Minimally invasive surgery for glycogen storage disease combined with inflammatory bowel disease: A case report
Wan J, Zhang ZC, Yang MQ, Sun XM, Yin L, Chen CQ
- 4348** Coronary sinus endocarditis in a hemodialysis patient: A case report and review of literature
Hwang HJ, Kang SW
- 4357** *Clostridium perfringens* bloodstream infection secondary to acute pancreatitis: A case report
Li M, Li N
- 4365** Kidney re-transplantation after living donor graft nephrectomy due to *de novo* chromophobe renal cell carcinoma: A case report
Wang H, Song WL, Cai WJ, Feng G, Fu YX
- 4373** Pelvic lipomatosis with cystitis glandularis managed with cyclooxygenase-2 inhibitor: A case report
Mo LC, Piao SZ, Zheng HH, Hong T, Feng Q, Ke M
- 4381** Prone position combined with high-flow nasal oxygen could benefit spontaneously breathing, severe COVID-19 patients: A case report
Xu DW, Li GL, Zhang JH, He F
- 4388** Primary intratracheal schwannoma misdiagnosed as severe asthma in an adolescent: A case report
Huang HR, Li PQ, Wan YX
- 4395** Prenatal diagnosis of cor triatriatum sinister associated with early pericardial effusion: A case report
Cánovas E, Cazorla E, Alonzo MC, Jara R, Álvarez L, Beric D
- 4400** Pulmonary alveolar proteinosis complicated with tuberculosis: A case report
Bai H, Meng ZR, Ying BW, Chen XR
- 4408** Surgical treatment of four segment lumbar spondylolysis: A case report
Li DM, Peng BG

- 4415** Efficacy of artificial liver support system in severe immune-associated hepatitis caused by camrelizumab: A case report and review of the literature
Tan YW, Chen L, Zhou XB
- 4423** Anti-Yo antibody-positive paraneoplastic cerebellar degeneration in a patient with possible cholangiocarcinoma: A case report and review of the literature
Lou Y, Xu SH, Zhang SR, Shu QF, Liu XL
- 4433** Intraneural ganglion cyst of the lumbosacral plexus mimicking L5 radiculopathy: A case report
Lee JG, Peo H, Cho JH, Kim DH
- 4441** Effectiveness of patient education focusing on circadian pain rhythms: A case report and review of literature
Tanaka Y, Sato G, Imai R, Osumi M, Shigetoh H, Fujii R, Morioka S
- 4453** Schwannoma mimicking pancreatic carcinoma: A case report
Kimura K, Adachi E, Toyohara A, Omori S, Ezaki K, Ihara R, Higashi T, Ohgaki K, Ito S, Maehara SI, Nakamura T, Fushimi F, Maehara Y

ABOUT COVER

Editorial Board Member of *World Journal of Clinical Cases*, Pietro Scicchitano, MD, Professor, Research Scientist, Department of Emergency and Organ Transplantation, School of Medicine, University of Bari, Bari 70124, Italy. piero.sc@hotmail.it

AIMS AND SCOPE

The primary aim of *World Journal of Clinical Cases* (WJCC, *World J Clin Cases*) is to provide scholars and readers from various fields of clinical medicine with a platform to publish high-quality clinical research articles and communicate their research findings online.

WJCC mainly publishes articles reporting research results and findings obtained in the field of clinical medicine and covering a wide range of topics, including case control studies, retrospective cohort studies, retrospective studies, clinical trials studies, observational studies, prospective studies, randomized controlled trials, randomized clinical trials, systematic reviews, meta-analysis, and case reports.

INDEXING/ABSTRACTING

The WJCC is now indexed in Science Citation Index Expanded (also known as SciSearch®), Journal Citation Reports/Science Edition, Scopus, PubMed, and PubMed Central. The 2020 Edition of Journal Citation Reports® cites the 2019 impact factor (IF) for WJCC as 1.013; IF without journal self cites: 0.991; Ranking: 120 among 165 journals in medicine, general and internal; and Quartile category: Q3. The WJCC's CiteScore for 2019 is 0.3 and Scopus CiteScore rank 2019: General Medicine is 394/529.

RESPONSIBLE EDITORS FOR THIS ISSUE

Production Editor: *Jia-Hui Li*; Production Department Director: *Yu-Jie Ma*; Editorial Office Director: *Jin-Lai Wang*.

NAME OF JOURNAL

World Journal of Clinical Cases

ISSN

ISSN 2307-8960 (online)

LAUNCH DATE

April 16, 2013

FREQUENCY

Thrice Monthly

EDITORS-IN-CHIEF

Dennis A Bloomfield, Sandro Vento, Bao-Gan Peng

EDITORIAL BOARD MEMBERS

<https://www.wjnet.com/2307-8960/editorialboard.htm>

PUBLICATION DATE

June 16, 2021

COPYRIGHT

© 2021 Baishideng Publishing Group Inc

INSTRUCTIONS TO AUTHORS

<https://www.wjnet.com/bpg/gerinfo/204>

GUIDELINES FOR ETHICS DOCUMENTS

<https://www.wjnet.com/bpg/GerInfo/287>

GUIDELINES FOR NON-NATIVE SPEAKERS OF ENGLISH

<https://www.wjnet.com/bpg/gerinfo/240>

PUBLICATION ETHICS

<https://www.wjnet.com/bpg/GerInfo/288>

PUBLICATION MISCONDUCT

<https://www.wjnet.com/bpg/gerinfo/208>

ARTICLE PROCESSING CHARGE

<https://www.wjnet.com/bpg/gerinfo/242>

STEPS FOR SUBMITTING MANUSCRIPTS

<https://www.wjnet.com/bpg/GerInfo/239>

ONLINE SUBMISSION

<https://www.f6publishing.com>



Ex vivo liver resection followed by autotransplantation in radical resection of gastric cancer liver metastases: A case report

Hong Wang, Cheng-Cheng Zhang, Yan-Jiao Ou, Lei-Da Zhang

ORCID number: Hong Wang 0000-0003-1396-4098; Cheng-Cheng Zhang 0000-0002-0550-107X; Yan-Jiao Ou 0000-0001-7899-2415; Lei-Da Zhang 0000-0002-2357-5566.

Author contributions: Wang H wrote the manuscript; Zhang CC helped in writing the manuscript; all authors administered the daily medical treatments in this case; Zhang LD comprehensively supervised this study; all authors read and approved the final manuscript.

Informed consent statement:

Written informed consent was obtained from the patient for publication of this case report and accompanying images and clinical data.

Conflict-of-interest statement: The authors declare that they have no competing interests.

CARE Checklist (2016) statement:

The authors have read the CARE Checklist (2016), and the manuscript was prepared and revised according to the CARE Checklist (2016).

Open-Access: This article is an open-access article that was selected by an in-house editor and fully peer-reviewed by external reviewers. It is distributed in accordance with the Creative

Hong Wang, Cheng-Cheng Zhang, Yan-Jiao Ou, Lei-Da Zhang, Southwest Hospital, Third Military Medical University (Army Medical University), Institute of Hepatobiliary Surgery, Chongqing 400038, China

Corresponding author: Lei-Da Zhang, PhD, Professor, Southwest Hospital, Third Military Medical University (Army Medical University), Institute of Hepatobiliary Surgery, No. 30 Gaotanyan Street, Shapingba District, Chongqing 400038, China. 2518569931@qq.com

Abstract

BACKGROUND

Radical resection of gastric cancer liver metastases (GCLM) can increase the 5-year survival rate of GCLM patients. However, patients may lose the theoretical feasibility of surgery due to the critical location of liver metastasis in some cases.

CASE SUMMARY

A 29-year-old woman had a chief complaint of chronic abdominal pain for 1 year. Abdominal computed tomography and magnetic resonance imaging examinations suggested a mass of unknown pathological nature located between the first and second hila and the margin of the lower segment of the right lobe of the liver. The anterior wall of the gastric antrum was unevenly thickened. The diagnosis of (gastric antrum) intramucosal well-differentiated adenocarcinoma was histopathologically confirmed by puncture biopsy with gastroscopy guidance. She underwent radical resection (excision of both gastric tumors and *ex vivo* liver resection followed by autotransplantation simultaneously) followed by XELOX adjuvant chemotherapy. Without serious postoperative complications, the patient was successfully discharged on the 20th day after the operation. Pathological examination of the excised specimen indicated that gastrectomy with D2 lymph node dissection for primary gastric tumors and R0 resection for liver metastases were achieved. The resected mass was confirmed to be poorly differentiated gastric carcinoma (hepatoid adenocarcinoma with neuroendocrine differentiation) with liver metastases in segments VIII. No recurrence or metastasis within the liver was found during a 7.5-year follow-up review that began 1 mo after surgery.

CONCLUSION

Application of *ex vivo* liver resection followed by autotransplantation in radical resection for GCLM can help selected patients with intrahepatic metastases located in complex sites obtain a favorable clinical outcome.

Commons Attribution
NonCommercial (CC BY-NC 4.0)
license, which permits others to
distribute, remix, adapt, build
upon this work non-commercially,
and license their derivative works
on different terms, provided the
original work is properly cited and
the use is non-commercial. See: <http://creativecommons.org/licenses/by-nc/4.0/>

Manuscript source: Unsolicited
manuscript

Specialty type: Surgery

Country/Territory of origin: China

**Peer-review report's scientific
quality classification**

Grade A (Excellent): 0
Grade B (Very good): 0
Grade C (Good): 0
Grade D (Fair): 0
Grade E (Poor): 0

Received: October 21, 2020

Peer-review started: October 21,
2020

First decision: January 17, 2021

Revised: January 26, 2021

Accepted: March 24, 2021

Article in press: March 24, 2021

Published online: June 16, 2021

P-Reviewer: Morelli L

S-Editor: Zhang L

L-Editor: Wang TQ

P-Editor: Zhang YL



Key Words: *Ex vivo* liver resection; Autotransplantation; Gastric cancer liver metastases; Critical location; Selected patients; Radical resection; Case report

©The Author(s) 2021. Published by Baishideng Publishing Group Inc. All rights reserved.

Core Tip: Application of *ex vivo* liver resection followed by autotransplantation in radical resection for gastric cancer liver metastases can help selected patients with intrahepatic metastases located in complex sites obtain a favorable clinical outcome.

Citation: Wang H, Zhang CC, Ou YJ, Zhang LD. *Ex vivo* liver resection followed by autotransplantation in radical resection of gastric cancer liver metastases: A case report. *World J Clin Cases* 2021; 9(17): 4221-4229

URL: <https://www.wjgnet.com/2307-8960/full/v9/i17/4221.htm>

DOI: <https://dx.doi.org/10.12998/wjcc.v9.i17.4221>

INTRODUCTION

The incidence of gastric cancer liver metastases (GCLM) ranges from 9.9% to 18.7% among gastric cancer patients[1,2], and GCLM patients have a median survival time of 11 mo and a 5-year survival rate < 20%[3]. Some retrospective studies have declared that radical resection (excision of both gastric tumors and liver metastases simultaneously) can increase the 5-year survival rate of GCLM patients, but the timing and ideal surgical type remain controversial. Based on the likelihood of a surgical treatment being successful, Chinese type for-GCLM has been proposed by the Chinese consensus on the diagnosis and treatment of GCLM[4]. While we acknowledge that a tumor-free margin is the predictor of a better outcome for GCLM patients, an unavoidable question may emerge: What if liver metastases meet all the surgical qualifications judged by size and scope according to the aforementioned classification criteria, but their location is so critical that the technical risk of surgery significantly increases? It would be regretful to give up the chance of radical resection because of the limited number of eligible patients. The application of *ex vivo* liver resection followed by autotransplantation (ELRA) may provide an alternative solution to this problem. Here, we present a case pertaining to the treatment procedures and prognosis of a young female patient with GCLM, which showed that the application of ELRA in radical resection for GCLM can help patients with intrahepatic metastases located in complex sites obtain a favorable clinical outcome.

CASE PRESENTATION

Chief complaints

A 29-year-old woman had a chief complaint of chronic abdominal pain for one year and she experienced continuous weight loss of 5 kg over 2 mo prior to her admission.

History of present illness

The patient had chronic abdominal pain for 1 year and she experienced continuous weight loss of 5 kg over 2 mo prior to her admission.

History of past illness

The patient had undergone ovarian cystectomy, appendectomy, and subtotal hysterectomy for uncontrollable hemorrhage according to her past medical history.

Personal and family history

No special family history was provided except that her mother was diagnosed with squamous cell carcinoma of the vulvar epithelium and the disease was cured according to her description.

Physical examination

Upon physical examination, a round mass approximately 7 cm in diameter could be palpated in the right upper abdomen and the mass was smooth, pushable, hard, and indistinguishable from adjacent tissue. Other detailed basic information is displayed in [Table 1](#).

Laboratory examinations

Laboratory data demonstrated normal liver function and routine blood test results ([Table 2](#)). The tumor marker results showed that the level of alpha-fetoprotein was 9850 ng/mL and that of carcinoma embryonic antigen was 0.55 ng/mL.

Imaging examinations

Abdominal computed tomography (CT) and magnetic resonance imaging examinations suggested a mass of unknown pathological nature located in segment VIII and it was between the first and second hila and the margin of the lower segment of the right liver lobe ([Figure 1](#)). The anterior wall of the gastric antrum was unevenly thickened. Positron emission tomography/CT (whole body) examination showed two main points: (1) The anterior wall of the gastric antrum was unevenly thickened, and fluorodeoxyglucose uptake was increased, which was consistent with the manifestations of gastric cancer; and (2) A mass shadow was located at the first and second hepatic hila and the lower right lobe of the liver. As increased fluorodeoxyglucose uptake is a sign of malignancy, whether the mass was liver metastasis or primary liver cancer remained to be identified. Electrocardiograph, chest digital radiography, and CT of the lower abdomen and pelvis showed no obvious abnormalities.

MULTIDISCIPLINARY EXPERT CONSULTATION

Due to the unknown nature and special location of the mass in the liver, it was considered to be a liver metastatic focus of gastric cancer after consultation by general and hepatobiliary surgeons.

FINAL DIAGNOSIS

The results of puncture biopsy with gastroscopy guidance supported the pathological diagnosis of gastric antrum intramucosal well-differentiated adenocarcinoma.

TREATMENT

A tumor protruding through the liver capsule with unclear borders and an uneven surface was found in the right liver during abdominal exploration. It was hard and pale and was tightly adhered to the surrounding omentum. Consistent with the preoperative imaging findings, the tumor extended to the junction of the left and right liver lobes and was adjacent to the vena cava. Intraoperative frozen biopsy of the liver mass was performed and the results supported a poorly differentiated malignant tumor. The presence of intrahepatic microlesions was ruled out by intraoperative ultrasound. The results of intraoperative exploration led us to perform ELRA combined with radical resection for gastric cancer as the original plan.

Hepatectomy was accomplished by using standard technique[5] with extensive lymph node dissection around the superior mesenteric artery and celiac trunk. The common bile duct was completely removed up to the head of the pancreas. Preservation and perfusion of the removed isolated liver were performed with ice-cold solution at 4 °C and UW solution *via* the intact portal vein (PV). At the same time, a temporary channel was established between the superior hepatic inferior vena cava and inferior hepatic inferior vena cava with an internal diameter of 2 cm and Geo-Text artificial vessel. The PV was also anastomosed to the vessel to construct a portacaval shunt. After the intrahepatic tumor and target liver segment (VIII) were completely resected and the repairment of the middle and right hepatic vein was done, the aforementioned temporary venous channel was removed. The remnant of the liver was implanted similar to orthotopic liver transplantation, which was followed by anastomosis of the superior hepatic inferior vena cava, inferior hepatic inferior vena cava, PV, hepatic artery, and bile duct. The total anhepatic period was 245 min,

Table 1 Detailed basic information of the patient

Item	Value
Height	158 cm
Weight	48 kg
BMI	19.2 kg/m ²
Obstructive jaundice	No
Zubrod-ECOG-WHO	1
Hypertension	No
Diabetes	No
Heart disease	No
Kidney disease	No
Liver disease	No
Breast disease	No
Genitourinary diseases	No
Infectious disease	No
Respiratory function	Good
Mental state	Good
Neoadjuvant chemotherapy	No

BMI: Body mass index; Zubrod-ECOG-WHO: Zubrod-Eastern-Cooperative Oncology Group-World Health Organization (An indicator of the general health status and treatment tolerance of patients from their physical strength).

including 180 min of cold ischemia time (CIT) for extracorporeal tumor resection and vein repair, 40 min of vena cava anastomosis, and 25 min of PV anastomosis. Observation of the normal liver surface color after reperfusion was commonly performed, and the surgeons usually confirmed bile outflow before bile duct anastomosis. Some of intraoperative photos are presented in [Figure 2](#). As we performed *ex vivo* liver resection on the back table, radical surgery for gastric cancer was accomplished simultaneously by general surgeons on the operating table. The stomach and duodenum were respectively transected at 15 cm from the distal end of the cardia and 2 cm from the distal end of the pylorus with a disposable linear cutting closure. After the lymph nodes around the PV were resected, the digestive tract was reconstructed by gastrojejunal anastomosis and a gastric tube was inserted into the jejunum for input loop.

OUTCOME AND FOLLOW-UP

Our medical team provided the patient with symptomatic treatment after surgery such as gastrointestinal decompression, abdominal drainage, anti-infection medication, and nutritional support. She underwent bile leakage drainage on the fifth day after the operation. Fluid accumulated in the liver section and caused symptoms of gastric compression. The effusion was completely drained out after CT-guided puncture and catheter drainage 1 wk later. No other postoperative complications such as small-for-size syndrome, acute liver failure, vascular embolism, intra-abdominal infection, or hemorrhage occurred. She was successfully discharged on the 20th day after the operation. Postoperative pathological examination of the excised specimen indicated that gastrectomy with D2 lymph node dissection for primary gastric tumors and R0 resection for liver metastases were achieved. The resected mass was confirmed to be poorly differentiated gastric carcinoma (hepatoid adenocarcinoma with neuroendocrine differentiation) with liver metastases in segments of 6 and 8 ([Figure 3](#)). The patient began her first follow-up 1 mo after the operation, and received six courses of XELOX chemotherapy every 21 d since then, during which no serious adverse reactions or treatment discontinuation occurred. The patient also insisted on oral Tegafur Gimeracil and Oteracil Potassium Capsules for 1 mo after intravenous

Table 2 Preoperative laboratory data of the patient

Item	Value
WBC	$6.77 \times 10^9/L$
RBC	$3.62 \times 10^{12}/L$
Hgb	111 g/L
PLT	$168 \times 10^9/L$
Neu	$4.88 \times 10^9/L$
Neu%	(Neu%) 72.1%↑
ALT	34 IU/L
AST	32 IU/L
ALP	37 IU/L
GGT	12 IU/L
ALB	38 g/L
PALB	0.15 g/L
TBA	16.2 umol/L
DBIL	6.1 umol/L
IDBIL	10.1 umol/L
PT	12.50 s
INR	0.95
AFP	9850 ng/mL
CEA	1.46 ng/mL

WBC: White blood cells; RBC: Red blood cells; Hgb: Hemoglobin; PLT: Platelets; Neu: Neutrophile granulocyte; ALT: Alanine aminotransferase; AST: Aspartate amino transferase; ALP: Alkaline phosphatase; GGT: Gamma-glutamyl transpeptidase; ALB: Serum albumin; PALB: Pre-albumin; TBA: Total bile acid; DBIL: Direct bilirubin; IDBIL: Indirect bilirubin; PT: Prothrombin time; PT-INR: International standardized ratio of prothrombin time; AFP: Alpha-fetoprotein; CEA: Carcinoma embryonic antigen.

chemotherapy. She went back to the hospital on time for follow-up every 3 mo after the end of chemotherapy. Routine blood, liver and kidney function, and tumor markers tests, as well as abdominal CT are routine examination items. No obvious signs of tumor recurrence or metastasis within the abdomen or liver were recorded during a 7.5-year follow-up period. The patient had a good overall condition and did not undergo a second operation. Selected pre- and post-operative abdominal CT images of the patient are displayed in Figure 1. Postoperative laboratory data of the patient are displayed in Table 3.

DISCUSSION

GCLM is usually transglobally, multifocally, or even diffusely spread. It is always complicated by peritoneal, extensive lymph node and organ metastases due to its highly malignant and rapidly invasive oncologic nature. Poor prognosis and deadly surgical complications make the resection rate so low that there is no multicenter clinical trial with large samples on the significance of liver resection for GCLM. No well-established criteria exist except for a few retrospective studies with a limited number of cases[4]. What is worth noting is that the results of these limited studies almost indicate that patients with GCLM can benefit from radical resection[6-9].

According to the Chinese type for-GCLM, the definitions of both type I and II include the same criterion: "Technological resectability of liver metastases judged by a hepatobiliary surgeon". It emphasizes the principle that surgery should be performed only when R0 resection is anticipated[4]. Then the aforementioned question arises: What if the size and scope of liver metastases comply with this standard, but the anatomical complexity puts the hepatobiliary surgeon into a dilemma? The most

Table 3 Postoperative laboratory data of the patient

Item	Value
WBC	$5.66 \times 10^9/L$
RBC	$4.07 \times 10^{12}/L$
Hgb	121 g/L
PLT	$154 \times 10^9/L$
Neu	$4.00 \times 10^9/L$
Neu%	(Neu%) 70.6%↑
ALT	53.3 IU/L↑
AST	53.5 IU/L↑
ALP	113 IU/L
GGT	17 IU/L
ALB	42 g/L
PALB	0.18 g/L
TBA	17.3 umol/L
DBIL	4.32 umol/L
IDBIL	12.98 umol/L
PT	11.40 s
PT-INR	0.85
AFP	2.8 ng/mL
CEA	3.56 ng/mL

WBC: White blood cells; RBC: Red blood cells; Hgb: Hemoglobin; PLT: Platelets; Neu: Neutrophile granulocyte; ALT: Alanine aminotransferase; AST: Aspartate amino transferase; ALP: Alkaline phosphatase; GGT: Gamma-glutamyl transpeptidase; ALB: Serum albumin; PALB: Pre-albumin; TBA: Total bile acid; DBIL: Direct bilirubin; IDBIL: Indirect bilirubin; PT: Prothrombin time; PT-INR: International standardized ratio of prothrombin time; AFP: Alpha-fetoprotein; CEA: Carcinoma embryonic antigen.

common situation is that the tumor is located deeply within the liver and has extensive involvement of the main hepatic veins or retrohepatic vena cava. These types of tumors are usually deemed unresectable by conventional surgery because it is extremely hazardous due to the potential risk of uncontrollable hemorrhage and long ischemia time[10,11].

We can infer that ELRA may overcome this issue from our case report[4,12]. It effectively alleviated the technical bottleneck in traditional hepatectomy and allowed the hepatobiliary surgeons to perform precise liver tumor resection and effective vascular repairment by enabling them to operate with bloodless vision and access to critical structures easily since the first report of *ex vivo* hepatectomy by Pichlmayr *et al*[13] in 1988. What is more, full exposure of the surgical area can help reduce the risk due to vascular or bile duct variation that may not be detected before the operation.

ELRA is a challenging and time-consuming surgery with cumbersome procedures and complex operations. The theoretical basis and detailed surgical procedures that have been reported systematically in many studies will not be repeated here[14]. The most valuable experience that our team has summarized from this case is that accurate preoperative evaluation for specific patients based on detailed medical examination is of great importance. Strict patient selection and precise assessment of the size and quality of the remnant liver are pivotal to the decision-making process[14]. Although experiences gained from previous studies have indicated that after extended hepatectomy involving 70% to 75% of the liver, the remnant liver can still function well in non-cirrhosis patients[15,16], the strategy may need to be adjusted in the application of ERLA. A major feature of endoscopic retrograde appendicitis treatment (ERAT) is the longer CIT compared with ordinary liver transplantation (LT)[17]. In addition, procedures of ERAT are more complex than common LT and hepatectomy so a longer operative time and more intraoperative blood loss seem inevitable[10]. These

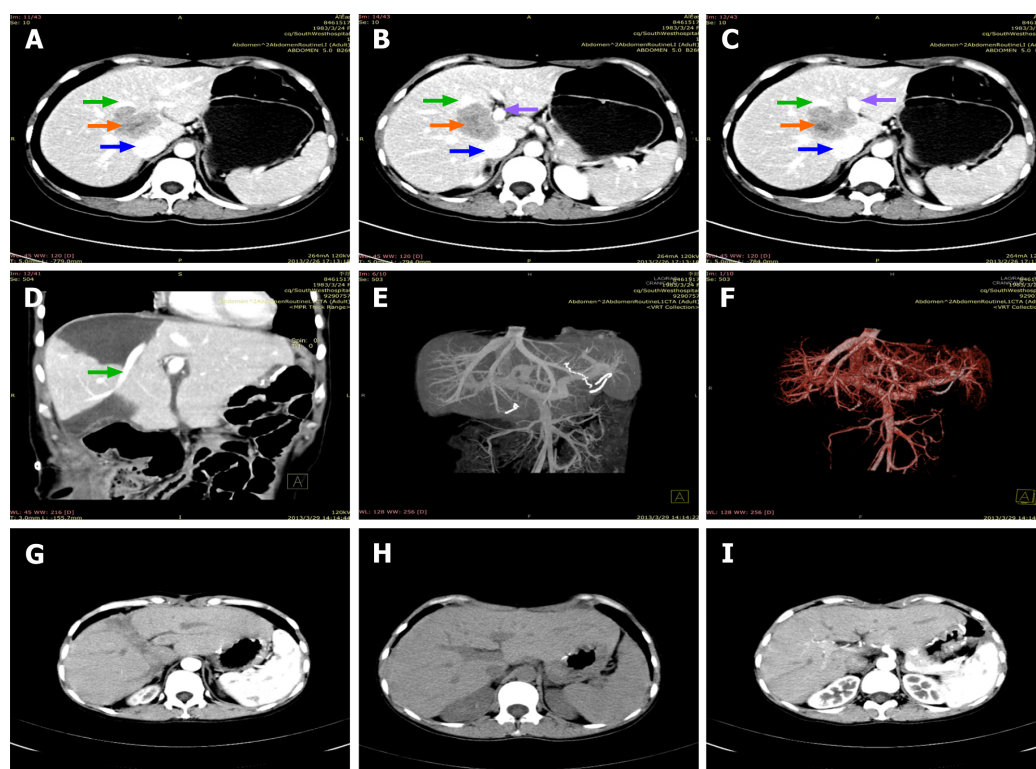


Figure 1 Abdominal computed tomography and magnetic resonance imaging examinations. A-C: The tumor (pointed by the orange arrow) was located between the first and second hila and it was adjacent to the middle hepatic vein (pointed by the green arrow), inferior R vena cava (pointed by the blue arrow), and the right branch of portal vein (pointed by the purple arrow); D-F: Postoperative imaging examination and upper abdominal angiography showed that the left hepatic vein, middle hepatic vein, right hepatic vein, inferior R vena cava, hepatic artery, and portal vein were intact and blood flow was unobstructed; G-I: Computed tomography results in the first, second, and third year after operation showed that there were no obvious signs of tumor recurrence.

are two poor prognostic indicators for LT recipients and hepatectomy patients because they may lead to graft loss due to the high incidence of postoperative biliary and arterial complications or severe hepatic dysfunction[18]. Based on the above theory, the liver function, liver quality, and estimated Rauscher leukemia virus of ELRA patients need to meet higher requirements. Livers with poor quality are less tolerant to cold ischemia-reperfusion injury. In addition, sufficient preoperative preparations, such as biliary drainage in patients with obstructive jaundice and nutritional support in malnourished patients, are indispensable once the doctor and patient reach a consensus to perform the surgery. Without exaggeration, it can be considered that half the success will be achieved if suitable GCLM patients are screened out, but inaccurate preoperative assessments will force surgeons to discontinue the operation or will even cause fatal postoperative complications such as small-for-size syndrome or acute liver failure[19]. Aji *et al*[14] described the largest case series of 69 patients with end stage hepatic alveolar echinococcosis who underwent ELRA. The detailed methods and procedures applied to select patients preoperatively are explicitly described in the literature. We also adopted the same issues to evaluate the patient in this case report.

A longer anhepatic period can lead to circulatory and metabolic disorders. Hepato-biliary surgeons must pursue more accurate and rapid surgical techniques to shorten the CIT and anhepatic phase. This is also a major test for the monitoring and intraoperative management of the anesthesiology department. So launching this type of major surgery can help improve the overall medical level of institutions and optimize the multidisciplinary diagnosis and treatment model. The lack of consensus and guidance on the application of ELRA drives us to accumulate more successful cases and precious experiences. Once successful, it will bring great significance in two aspects. For patients, the painful clinical symptoms caused by the tumor will be controlled, and the quality of their lives will be dramatically improved. It is our responsibility and obligation to create an opportunity for patients who never give up on themselves to extend their lives to fulfill their unfinished wishes. From a medical point of view, an increased survival rate may provide a longer time for more postoperative treatment options and promote the progress of clinical research. For instance, Qiu *et al*[20] proposed their vascular infiltration-based classification as a tool to improve anatomic comprehension and facilitate surgical planning for ELRA.

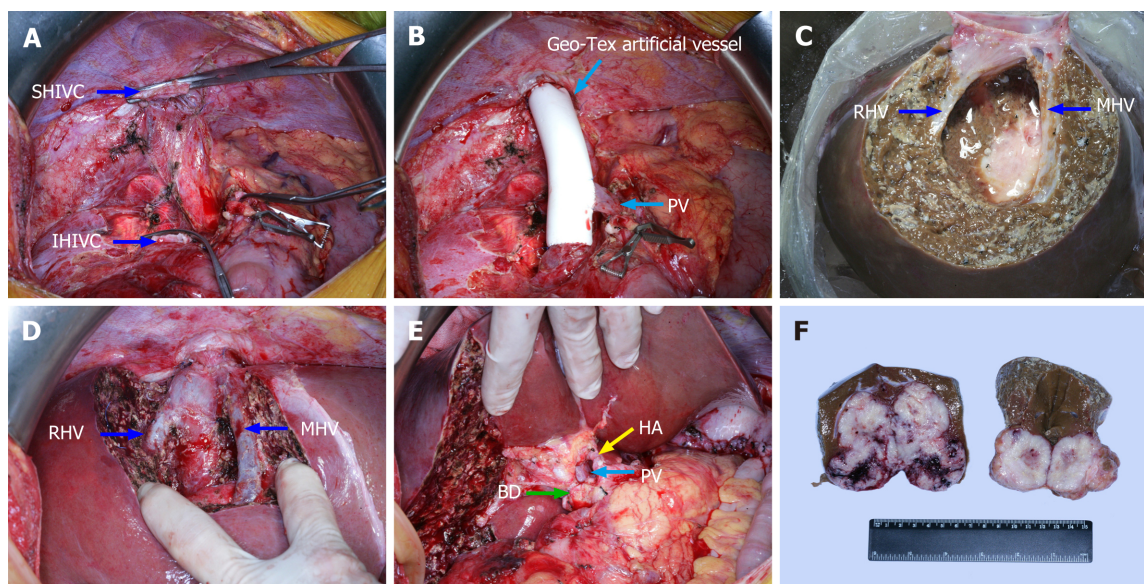


Figure 2 Intraoperative photos. A: The liver was removed from the abdominal cavity; B: The portal vein was anastomosed to the Geo-Tex artificial vessel to construct a portacaval shunt; C: The tumor has been completely resected from the isolated liver. Right hepatic vein and middle hepatic vein were intact; D: The remnant of the liver was implanted similar to orthotopic liver transplantation. After reconstruction, the right hepatic vein, middle hepatic vein, and inferior R vena cava had unobstructed blood flow; E: The first hepatic hilum after reconstruction; F: The first hepatic hilum after reconstruction. PV: Portal vein; RHV: Right hepatic vein; MHV: Middle hepatic vein; IHIVC: Infrahepatic inferior vena cava; SHIVC: Suprahepatic inferior vena cava; HA: Hepatic artery; BD: Biliary dilatation.

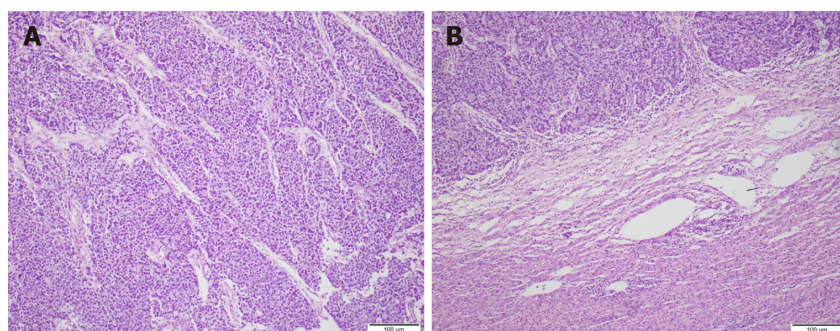


Figure 3 Microscopic images. A: Poorly differentiated gastric carcinoma (hepatoid adenocarcinoma with neuroendocrine differentiation) with liver metastases; B: Tumor tissue and adjacent liver tissue.

CONCLUSION

In conclusion, the application of ELRA in radical resection of GCLM could provide an alternative for selected patients. Strict patient selection and careful perioperative management guaranteed by an experienced multidisciplinary team could contribute to favorable clinical outcomes[21,22].

ACKNOWLEDGEMENTS

All images were taken and post-processed by a professional photographer in our center.

REFERENCES

- 1 **Riihimäki M**, Hemminki A, Sundquist K, Sundquist J, Hemminki K. Metastatic spread in patients with gastric cancer. *Oncotarget* 2016; 7: 52307-52316 [PMID: 27447571 DOI: 10.18632/oncotarget.10740]
- 2 **Cheon SH**, Rha SY, Jeung HC, Im CK, Kim SH, Kim HR, Ahn JB, Roh JK, Noh SH, Chung HC.

- Survival benefit of combined curative resection of the stomach (D2 resection) and liver in gastric cancer patients with liver metastases. *Ann Oncol* 2008; **19**: 1146-1153 [PMID: [18304963](#) DOI: [10.1093/annonc/mdn026](#)]
- 3 **Xiao Y**, Zhang B, Wu Y. Prognostic analysis and liver metastases relevant factors after gastric and hepatic surgical treatment in gastric cancer patients with metachronous liver metastases: a population-based study. *Ir J Med Sci* 2019; **188**: 415-424 [PMID: [30062399](#) DOI: [10.1007/s11845-018-1864-4](#)]
 - 4 **Zhang K**, Chen L. Chinese consensus on the diagnosis and treatment of gastric cancer with liver metastases. *Ther Adv Med Oncol* 2020; **12**: 1758835920904803 [PMID: [32127925](#) DOI: [10.1177/1758835920904803](#)]
 - 5 **Kaishan T**, Dong C, Zhaoxu Y, Xiao L, Ying T. Chinese Code of practice for liver Transplantation. *Zhonghua Qiguan Yizhi Zazhi* 2019; **13**: 171-176 [DOI: [10.3877/cma.j.issn.1674-3903.2019.03.003](#)]
 - 6 **Kunieda K**, Saji S, Sugiyama Y, Osada S, Sano J, Nagao N, Takahashi T, Takagi Y, Arai Y. Evaluation of treatment for synchronous hepatic metastases from gastric cancer with special reference to long-term survivors. *Surg Today* 2002; **32**: 587-593 [PMID: [12111514](#) DOI: [10.1007/s005950200106](#)]
 - 7 **Ueda K**, Iwahashi M, Nakamori M, Nakamura M, Naka T, Ishida K, Ojima T, Yamaue H. Analysis of the prognostic factors and evaluation of surgical treatment for synchronous liver metastases from gastric cancer. *Langenbecks Arch Surg* 2009; **394**: 647-653 [PMID: [18343941](#) DOI: [10.1007/s00423-008-0311-9](#)]
 - 8 **Thelen A**, Jonas S, Benckert C, Lopez-Hänninen E, Neumann U, Rudolph B, Schumacher G, Neuhaus P. Liver resection for metastatic gastric cancer. *Eur J Surg Oncol* 2008; **34**: 1328-1334 [PMID: [18329229](#) DOI: [10.1016/j.ejso.2008.01.022](#)]
 - 9 **Petrelli F**, Coinu A, Cabiddu M, Ghilardi M, Borgonovo K, Lonati V, Barni S. Hepatic resection for gastric cancer liver metastases: A systematic review and meta-analysis. *J Surg Oncol* 2015; **111**: 1021-1027 [PMID: [26082326](#) DOI: [10.1002/jso.23920](#)]
 - 10 **Shen S**, Qiu Y, Yang X, Wang W. Remnant Liver-to-Standard Liver Volume Ratio Below 40% is Safe in Ex Vivo Liver Resection and Autotransplantation. *J Gastrointest Surg* 2019; **23**: 1964-1972 [PMID: [30374819](#) DOI: [10.1007/s11605-018-4022-4](#)]
 - 11 **Moris D**, Tsilimigras DI, Chakedis J, Beal EW, Felekouras E, Vernadakis S, Schizas D, Fung JJ, Pawlik TM. Liver transplantation for unresectable colorectal liver metastases: A systematic review. *J Surg Oncol* 2017; **116**: 288-297 [PMID: [28513862](#) DOI: [10.1002/jso.24671](#)]
 - 12 **Zhanyu Y**, Qian L, Xiangde L, Zhiqing Y, Tengqian T, Ping B. Ex-vivo liver resection combined partial liver autotransplantation for hepatocellular carcinoma located at critical site. *Zhonghua Xiaohua Waikao Zazhi* 2010; **18**-20 [DOI: [10.3760/cma.j.issn.1673-9752.2010.01.009](#)]
 - 13 **Pichlmayr R**, Bretschneider HJ, Kirchner E, Ringe B, Lamesch P, Gubernatis G, Hauss J, Niehaus KJ, Kaukemüller J. [Ex situ operation on the liver. A new possibility in liver surgery]. *Langenbecks Arch Chir* 1988; **373**: 122-126 [PMID: [3287072](#) DOI: [10.1007/BF01262775](#)]
 - 14 **Aji T**, Dong JH, Shao YM, Zhao JM, Li T, Tuxun T, Shalayiadang P, Ran B, Jiang TM, Zhang RQ, He YB, Huang JF, Wen H. Ex vivo liver resection and autotransplantation as alternative to allotransplantation for end-stage hepatic alveolar echinococcosis. *J Hepatol* 2018; **69**: 1037-1046 [PMID: [30031886](#) DOI: [10.1016/j.jhep.2018.07.006](#)]
 - 15 **Pak LM**, Chakraborty J, Gonen M, Chapman WC, Do RKG, Groot Koerkamp B, Verhoef K, Lee SY, Massani M, van der Stok EP, Simpson AL; Memorial Sloan Kettering Cancer Center Hepatopancreatobiliary Service. Quantitative Imaging Features and Postoperative Hepatic Insufficiency: A Multi-Institutional Expanded Cohort. *J Am Coll Surg* 2018; **226**: 835-843 [PMID: [29454098](#) DOI: [10.1016/j.jamcollsurg.2018.02.001](#)]
 - 16 **Markar SR**, Mikhail S, Malietzis G, Athanasiou T, Mariette C, Sasako M, Hanna GB. Influence of Surgical Resection of Hepatic Metastases From Gastric Adenocarcinoma on Long-term Survival: Systematic Review and Pooled Analysis. *Ann Surg* 2016; **263**: 1092-1101 [PMID: [26797324](#) DOI: [10.1097/SLA.0000000000001542](#)]
 - 17 **Rammohan A**, Govil S, Vargese J, Kota V, Reddy MS, Rela M. Changing pattern of biliary complications in an evolving liver transplant unit. *Liver Transpl* 2017; **23**: 478-486 [PMID: [28152569](#) DOI: [10.1002/lt.24736](#)]
 - 18 **Ikegami T**, Yoshizumi T, Sakata K, Uchiyama H, Harimoto N, Harada N, Itoh S, Nagatsu A, Soejima Y, Machara Y. Left lobe living donor liver transplantation in adults: What is the safety limit? *Liver Transpl* 2016; **22**: 1666-1675 [PMID: [27540888](#) DOI: [10.1002/lt.24611](#)]
 - 19 **Haiwen Y**, Ying Z, Qian L, Lingqiang Z, Yong D, Xiaolei X. Small-for-size syndrome in hepatic alveolar echinococcosis treated by *ex vivo* liver resection and autotransplantation: A case report. *Shiyong Gandanbing Zazhi* 2019; **35**: 858-860 [DOI: [10.3969/j.issn.1001-5256.2019.04.030](#)]
 - 20 **Qiu Y**, Yang X, Shen S, Huang B, Wang W. Vascular infiltration-based surgical planning in treating end-stage hepatic alveolar echinococcosis with *ex vivo* liver resection and autotransplantation. *Surgery* 2019; **165**: 889-896 [PMID: [30591376](#) DOI: [10.1016/j.surg.2018.11.007](#)]
 - 21 **Kato T**, Hwang R, Liou P, Weiner J, Griesemer A, Samstein B, Halazun K, Mathur A, Schwartz G, Cherqui D, Emond J. Ex Vivo Resection and Autotransplantation for Conventionally Unresectable Tumors - An 11-year Single Center Experience. *Ann Surg* 2020; **272**: 766-772 [PMID: [32833756](#) DOI: [10.1097/SLA.0000000000004270](#)]
 - 22 **Zawistowski M**, Nowaczyk J, Jakubczyk M, Domagała P. Outcomes of ex vivo liver resection and autotransplantation: A systematic review and meta-analysis. *Surgery* 2020; **168**: 631-642 [PMID: [32727659](#) DOI: [10.1016/j.surg.2020.05.036](#)]



Published by **Baishideng Publishing Group Inc**
7041 Koll Center Parkway, Suite 160, Pleasanton, CA 94566, USA

Telephone: +1-925-3991568

E-mail: bpgoffice@wjgnet.com

Help Desk: <https://www.f6publishing.com/helpdesk>

<https://www.wjgnet.com>

