

World Journal of *Clinical Cases*

World J Clin Cases 2021 February 16; 9(5): 999-1246



Contents

Thrice Monthly Volume 9 Number 5 February 16, 2021

MINIREVIEWS

- 999 Remote nursing training model combined with proceduralization in the intensive care unit dealing with patients with COVID-19

Wang H, Kang K, Gao Y, Yang B, Li J, Wang L, Bi Y, Yu KJ, Dai QQ, Zhao MY

ORIGINAL ARTICLE

Case Control Study

- 1005 Metabolic syndrome, ApoE genotype, and cognitive dysfunction in an elderly population: A single-center, case-control study

Wang JY, Zhang L, Liu J, Yang W, Ma LN

- 1016 Serum neuron-specific enolase: A promising biomarker of silicosis

Huang HB, Huang JL, Xu XT, Huang KB, Lin YJ, Lin JB, Zhuang XB

Retrospective Study

- 1026 Biochemical recurrence of pathological T2+ localized prostate cancer after robotic-assisted radical prostatectomy: A 10-year surveillance

Yang CH, Lin YS, Ou YC, Weng WC, Huang LH, Lu CH, Hsu CY, Tung MC

Observational Study

- 1037 Clinical characteristics of perineal endometriosis: A case series

Liang Y, Zhang D, Jiang L, Liu Y, Zhang J

- 1048 Safety of gastrointestinal endoscopy in patients with acute coronary syndrome and concomitant gastrointestinal bleeding

Elkafrawy AA, Ahmed M, Alomari M, Elkaryoni A, Kennedy KF, Clarkston WK, Campbell DR

SYSTEMATIC REVIEWS

- 1058 Clinical features of SARS-CoV-2-associated encephalitis and meningitis amid COVID-19 pandemic

Huo L, Xu KL, Wang H

CASE REPORT

- 1079 Neuropathy and chloracne induced by 3,5,6-trichloropyridin-2-ol sodium: Report of three cases

Ma Y, Cao X, Zhang L, Zhang JY, Qiao ZS, Feng WL

- 1087 Effect of rifampicin on anticoagulation of warfarin: A case report

Hu YN, Zhou BT, Yang HR, Peng QL, Gu XR, Sun SS

- 1096 Severe lumbar spinal stenosis combined with Guillain-Barré syndrome: A case report

Xu DF, Wu B, Wang JX, Yu J, Xie JX

- 1103** Treatment of pediatric intracranial dissecting aneurysm with clipping and angioplasty, and next-generation sequencing analysis: A case report and literature review
Sun N, Yang XY, Zhao Y, Zhang QJ, Ma X, Wei ZN, Li MQ
- 1111** Imaging characteristics of a rare case of monostotic fibrous dysplasia of the sacrum: A case report
Liu XX, Xin X, Yan YH, Ma XW
- 1119** Primary aldosteronism due to bilateral micronodular hyperplasia and concomitant subclinical Cushing's syndrome: A case report
Teragawa H, Oshita C, Orita Y, Hashimoto K, Nakayama H, Yamazaki Y, Sasano H
- 1127** Management of corneal ulceration with a moisture chamber due to temporary lagophthalmos in a brain injury patient: A case report
Yu XY, Xue LY, Zhou Y, Shen J, Yin L
- 1132** Bronchoscopy for diagnosis of COVID-19 with respiratory failure: A case report
Chen QY, He YS, Liu K, Cao J, Chen YX
- 1139** Pembrolizumab as a novel therapeutic option for patients with refractory thymic epithelial tumor: A case report
Wong-Chong J, Bernadach M, Ginzac A, Veyssi  re H, Durando X
- 1148** Successful bailout stenting strategy against rare spontaneous retrograde dissection of partially absorbed magnesium-based resorbable scaffold: A case report
Liao ZY, Liou JY, Lin SC, Hung HF, Chang CM, Chen LC, Chua SK, Lo HM, Hung CF
- 1156** Chronic myelomonocytic leukemia-associated pulmonary alveolar proteinosis: A case report and review of literature
Chen C, Huang XL, Gao DQ, Li YW, Qian SX
- 1168** Obturator nerve impingement caused by an osteophyte in the sacroiliac joint: A case report
Cai MD, Zhang HF, Fan YG, Su XJ, Xia L
- 1175** Venetoclax in combination with chidamide and dexamethasone in relapsed/refractory primary plasma cell leukemia without t(11;14): A case report
Yang Y, Fu LJ, Chen CM, Hu MW
- 1184** Heterochronic triple primary malignancies with Epstein-Barr virus infection and tumor protein 53 gene mutation: A case report and review of literature
Peng WX, Liu X, Wang QF, Zhou XY, Luo ZG, Hu XC
- 1196** Negative conversion of autoantibody profile in chronic hepatitis B: A case report
Zhang X, Xie QX, Zhao DM
- 1204** Dumbbell-shaped solitary fibrous tumor in the parapharyngeal space: A case report
Li YN, Li CL, Liu ZH
- 1210** Spontaneous small bowel perforation secondary to *Vibrio parahaemolyticus* infection: A case report
Chien SC, Chang CC, Chien SC

- 1215** Management protocol for Fournier's gangrene in sanitary regime caused by SARS-CoV-2 pandemic: A case report
Grabińska A, Michalczyk Ł, Banaczyk B, Syryło T, Ząbkowski T
- 1221** Infective bicuspid aortic valve endocarditis causing acute severe regurgitation and heart failure: A case report
Hou C, Wang WC, Chen H, Zhang YY, Wang WM
- 1228** Endoscopic repair of delayed stomach perforation caused by penetrating trauma: A case report
Yoon JH, Jun CH, Han JP, Yeom JW, Kang SK, Kook HY, Choi SK
- 1237** Bilateral musculocutaneous neuropathy: A case report
Jung JW, Park YC, Lee JY, Park JH, Jang SH

ABOUT COVER

Editorial Board Member of *World Journal of Clinical Cases*, Dr. Antonio Corvino is a PhD in the Motor Science and Wellness Department at University of Naples "Parthenope". In 2008, he obtained his MD degree from the School of Medicine, Second University of Naples. Then, he completed a residency in Radiology in 2014 at University Federico II of Naples. In 2015, he undertook post-graduate training at Catholic University of Rome, obtaining the 2nd level Master's degree in "Internal Ultrasound Diagnostic and Echo-Guided Therapies". In 2016-2018, he served on the directive board of Young Directive of Italian Society of Ultrasound in Medicine and Biology. His ongoing research interests involve ultrasound and ultrasound contrast media in abdominal and non-abdominal applications, etc. (L-Editor: Filipodia)

AIMS AND SCOPE

The primary aim of *World Journal of Clinical Cases* (WJCC, *World J Clin Cases*) is to provide scholars and readers from various fields of clinical medicine with a platform to publish high-quality clinical research articles and communicate their research findings online.

WJCC mainly publishes articles reporting research results and findings obtained in the field of clinical medicine and covering a wide range of topics, including case control studies, retrospective cohort studies, retrospective studies, clinical trials studies, observational studies, prospective studies, randomized controlled trials, randomized clinical trials, systematic reviews, meta-analysis, and case reports.

INDEXING/ABSTRACTING

The WJCC is now indexed in Science Citation Index Expanded (also known as SciSearch®), Journal Citation Reports/Science Edition, Scopus, PubMed, and PubMed Central. The 2020 Edition of Journal Citation Reports® cites the 2019 impact factor (IF) for WJCC as 1.013; IF without journal self cites: 0.991; Ranking: 120 among 165 journals in medicine, general and internal; and Quartile category: Q3. The WJCC's CiteScore for 2019 is 0.3 and Scopus CiteScore rank 2019: General Medicine is 394/529.

RESPONSIBLE EDITORS FOR THIS ISSUE

Production Editor: Jia-Hui Li; Production Department Director: Yu-Jie Ma; Editorial Office Director: Jin-Lai Wang.

NAME OF JOURNAL

World Journal of Clinical Cases

ISSN

ISSN 2307-8960 (online)

LAUNCH DATE

April 16, 2013

FREQUENCY

Thrice Monthly

EDITORS-IN-CHIEF

Dennis A Bloomfield, Sandro Vento, Bao-gan Peng

EDITORIAL BOARD MEMBERS

<https://www.wjgnet.com/2307-8960/editorialboard.htm>

PUBLICATION DATE

February 16, 2021

COPYRIGHT

© 2021 Baishideng Publishing Group Inc

INSTRUCTIONS TO AUTHORS

<https://www.wjgnet.com/bpg/gerinfo/204>

GUIDELINES FOR ETHICS DOCUMENTS

<https://www.wjgnet.com/bpg/GerInfo/287>

GUIDELINES FOR NON-NATIVE SPEAKERS OF ENGLISH

<https://www.wjgnet.com/bpg/gerinfo/240>

PUBLICATION ETHICS

<https://www.wjgnet.com/bpg/GerInfo/288>

PUBLICATION MISCONDUCT

<https://www.wjgnet.com/bpg/gerinfo/208>

ARTICLE PROCESSING CHARGE

<https://www.wjgnet.com/bpg/gerinfo/242>

STEPS FOR SUBMITTING MANUSCRIPTS

<https://www.wjgnet.com/bpg/GerInfo/239>

ONLINE SUBMISSION

<https://www.f6publishing.com>

Heterochronic triple primary malignancies with Epstein-Barr virus infection and tumor protein 53 gene mutation: A case report and review of literature

Wen-Xia Peng, Xin Liu, Qi-Feng Wang, Xiao-Yan Zhou, Zhi-Guo Luo, Xi-Chun Hu

ORCID number: Wen-Xia Peng 0000-0002-6847-1031; Xin Liu 0000-0001-7142-5151; Qi-Feng Wang 0000-0002-0564-6076; Xiao-Yan Zhou 0000-0001-5999-7237; Zhi-Guo Luo 0000-0002-5879-9957; Xi-Chun Hu 0000-0001-6148-9186.

Author contributions: Peng WX and Liu X performed the investigation and provided resources for the case report; Wang QF, Zhou XY, and Luo ZG provided resources for the case report; Peng WX was responsible for data collection and assembly; Hu XC reviewed and edited the article for important intellectual content; All authors participated in manuscript drafting and final approval for the version to be submitted.

Informed consent statement: Informed written consent was obtained from the patient for publication of this report and any accompanying images.

Conflict-of-interest statement: The authors declare that they have no conflict of interest.

CARE Checklist (2016) statement: The authors have read the CARE Checklist (2016), and the manuscript was prepared and revised according to the CARE

Wen-Xia Peng, Xin Liu, Zhi-Guo Luo, Xi-Chun Hu, Department of Medical Oncology, Fudan University Shanghai Cancer Center, Shanghai 200032, China

Qi-Feng Wang, Xiao-Yan Zhou, Department of Pathology, Fudan University Shanghai Cancer Center, Shanghai 200032, China

Corresponding author: Xi-Chun Hu, MD, PhD, Professor, Department of Medical Oncology, Fudan University Shanghai Cancer Center, No. 270 Dongan Road, Xuhui District, Shanghai 200032, China. huxichun2017@163.com

Abstract

BACKGROUND

The diagnosis and etiology of multiple primary malignant neoplasms (MPMNs) are difficult to establish. Here, we report a case of heterochronic triple primary malignancies with gastric cancer, nasopharyngeal squamous cell cancer, and then rectal cancer.

CASE SUMMARY

The patient was first diagnosed with gastric cancer at the age of 33 in 2014 and underwent distal gastrectomy and gastrojejunostomy and six cycles of adjuvant chemotherapy. Three years later, he was diagnosed with nasopharyngeal cancer and treated with radical chemoradiotherapy in 2017. Recently, a mass in the middle of the rectum was resected and reported as ulcerative, moderately to poorly differentiated adenocarcinoma. Research on the etiology of MPMNs showed that Epstein-Barr virus (EBV) infection may be the cause of gastric cancer and nasopharyngeal squamous cell cancer since these two primary lesions were positive for transcripts of EBV-encoded ribonucleic acid using an *in situ* hybridization EBV-encoded ribonucleic acid probe in formalin-fixed, paraffin-embedded tissue. The cause of rectal cancer may be due to a somatic mutation of tumor protein 53 gene in exon 8 (c.844C>T, p.Arg282Trp) through high-throughput sequencing for the rectal cancer. Appropriate standard therapy for each primary cancer was administered, and the patient has no evidence of cancer disease to date.

CONCLUSION

To our knowledge, this is the first report on heterochronic triple primary malignancies whose cause may be associated with EBV infection and tumor

Checklist (2016)

Open-Access: This article is an open-access article that was selected by an in-house editor and fully peer-reviewed by external reviewers. It is distributed in accordance with the Creative Commons Attribution NonCommercial (CC BY-NC 4.0) license, which permits others to distribute, remix, adapt, build upon this work non-commercially, and license their derivative works on different terms, provided the original work is properly cited and the use is non-commercial. See: <http://creativecommons.org/licenses/by-nc/4.0/>

Manuscript source: Unsolicited manuscript

Specialty type: Medicine, research and experimental

Country/Territory of origin: China

Peer-review report's scientific quality classification

Grade A (Excellent): 0
Grade B (Very good): 0
Grade C (Good): 0
Grade D (Fair): 0
Grade E (Poor): 0

Received: October 29, 2020

Peer-review started: October 29, 2020

First decision: November 20, 2020

Revised: December 2, 2020

Accepted: December 16, 2020

Article in press: December 16, 2020

Published online: February 16, 2021

P-Reviewer: Frascio M

S-Editor: Fan JR

L-Editor: Filipodia

P-Editor: Xing YX



protein 53 genetic mutations. The etiological research may not only elucidate the cause of MPMN but also has implications in clinical management.

Key Words: Multiple primary malignant neoplasms; Epstein-Barr virus infection; Epstein-Barr virus-encoded RNA; TP53 mutation; Etiology; Case report

©The Author(s) 2021. Published by Baishideng Publishing Group Inc. All rights reserved.

Core Tip: The occurrence of triple heterochronic primary malignancies associated with Epstein-Barr virus (EBV) infection and genetic mutations is an extremely rare event. To the best of our knowledge, this is the first case of a 39-year-old male patient with triple heterochronic primary tumors including EBV-associated stomach cancer and nasopharyngeal cancer and tumor protein 53 mutant rectal carcinoma in the literature, and appropriate therapy for each primary cancer led to his good clinical outcome. This case further confirms the value of precision medicine; only a precise diagnosis can lead to appropriate treatment and good prognosis. Further research is needed to elucidate the role of EBV infection and the tumor protein 53 gene in the carcinogenesis of multiple primary malignant neoplasms.

Citation: Peng WX, Liu X, Wang QF, Zhou XY, Luo ZG, Hu XC. Heterochronic triple primary malignancies with Epstein-Barr virus infection and tumor protein 53 gene mutation: A case report and review of literature. *World J Clin Cases* 2021; 9(5): 1184-1195

URL: <https://www.wjgnet.com/2307-8960/full/v9/i5/1184.htm>

DOI: <https://dx.doi.org/10.12998/wjcc.v9.i5.1184>

INTRODUCTION

Multiple primary malignant neoplasms (MPMNs) refer to two or more primary malignant tumors simultaneously or successively occurring in different organs and/or tissues in the same patient, which is clinically rare and comprises only 0.52%-11.7% of all malignant cancers^[1,2]. Heterochronic primary malignancy is defined as the second primary cancer, which is diagnosed more than 6 mo after the diagnosis of the first primary cancer. Herein, we reviewed cases of heterochronic triple primary malignant tumors and only found 19 prior cases with heterochronic triple primary malignancies in the English literature. The increasing number of MPMN clinical cases is due to improvements in diagnostic techniques, increasingly novel evidence-based medicine, and increased survival times of cancer patients, justifying that the establishment of a confirmative diagnosis and etiology of MPMNs still plays a pivotal role in extending the life span of cancer patients.

The causes of triple primary malignant tumors are unclear, and multiple factors may synergistically contribute to the occurrence and development of cancer. Epstein-Barr virus (EBV), a ubiquitous human oncovirus, is closely associated with malignant lymphoma, nasopharyngeal carcinoma, and gastric cancer in China and eastern Asia. Studies have shown that EBV genome integration in the human cancer genome is detected in 10% of all gastric cancers and more than 95% of nasopharyngeal squamous cell cancers^[3,4]. EBV-positive tumors have a much poorer prognosis than EBV-negative tumors, and EBV-targeted therapies can significantly improve the prognosis of EBV-associated tumors^[5,6]. In addition to viral factors, many gene mutations in the human genome have been implicated in the pathogenesis of MPMNs, such as p53, breast cancer gene 1/2, phosphatase and tensin homolog, adenomatous polyposis coli (APC), p16, *etc.* As is well known, tumor protein 53 (P53) gene mutations, carried by more than 50% of human tumors, can induce cell cycle disturbances and inhibit cell apoptosis that contribute to the generation of most malignant tumors^[7,8]. In this study, we present a rare case of heterochronic triple primary malignancies with EBV infection-associated stomach cancer and nasopharyngeal cancer and TP53 mutation-associated rectal carcinoma.

CASE PRESENTATION

Chief complaints

A 39-year-old man who was 178 cm in height and 83 kg in weight came to our institute for consultation for rectal cancer resected more than 1 mo ago.

History of present illness

In February 2020, blood was found in his stool, and colonoscopy showed irregular protuberant lesions 7 cm above the anus. On April 3, 2020, he was pathologically diagnosed with moderately to poorly differentiated adenocarcinoma.

History of past illness

In December 2014, the patient was admitted to the First Affiliated Hospital of Nanjing Medical University for abdominal distention. On December 9, 2014, he was found to have mostly circular protuberant lesions in the gastric body and antrum by gastroscopy and then underwent distal gastrectomy and gastrojejunostomy. Histopathological examination of the surgical specimens revealed a 10 cm × 7 cm × 2 cm-sized mass, which invaded the entire layer of the gastric wall and reached the extracorporeal adipose fibrous connective tissue. This confirmed the diagnosis of stomach carcinoma with lymphoid stroma, diffuse type in the Lauren classification (Figure 1A). There was involvement of only one lymph node in the greater curvature with immunohistochemical staining including cytokeratin (CK)-L (++) , Villin (+), P63 (-), P40 (-), CK5/6 (-), and EBV-encoded ribonucleic acid (RNA) (EBER) *in situ* hybridization (+) (Figure 1B). Adjuvant chemotherapy was administered after the operation. After two cycles of paclitaxel, cisplatin, and tegafur, the treatment regimen was changed to paclitaxel, oxaliplatin, and tegafur for four cycles because of Grade 4 myelosuppression.

On March 13, 2017, the patient had epistaxis, and he was diagnosed with poorly differentiated squamous cell carcinoma of the nasopharynx with pathology of nasal endoscopic biopsy (Figure 2A). Immunohistochemical findings were as follows: CK-pan (-), CK5/6 (-), P63 (-), Melan A (-), human melanoma black 45 (-), Ki67 (+), EBER (+) (Figure 2B), CK7 (-), CK8/18 (+), CK-L (+), and P40 (focal+).

On March 27, 2017, his nasopharyngeal biopsy specimen was pathologically consulted by the Cancer Hospital of Sun Yat Sen University and Fudan University Shanghai Cancer Center, and both institutions found that there was great similarity between the gastric and nasopharyngeal lesions in terms of hematoxylin & eosin morphology and immunohistochemistry (IHC). Both of them were likely to be primary tumors, but nasopharyngeal metastasis of gastric cancer could not be completely ruled out. The patient was concurrently treated with radical radiotherapy and cisplatin chemotherapy, followed by nimotuzumab for six cycles.

Personal and family history

The patient had no history of diabetes mellitus, hypertension, or tobacco or alcohol abuse, and his family history was unremarkable.

Physical examination

The Eastern Cooperative Oncology Group score of the patient was 1, and no superficial lymph nodes could be palpated.

Laboratory examinations

His serum tumor markers and other laboratory values were all within normal range.

Imaging examinations

The patient came to our hospital. Magnetic resonance imaging indicated a rectal malignant tumor approximately 58 mm away above the anus (Figure 3A). On April 13, 2020, whole-body positron emission topography/computed tomography with 18-fluorodeoxy-glucose (FDG) scanning revealed thickening of the mid-rectal wall with high FDG uptake, suggesting a malignant tumor (Figure 3B), and increased FDG uptake at the junction of rectum and colon, which was likely to be inflammatory. No abnormal FDG-uptake was observed in the rest.

Biospy

On April 26, 2020, he underwent low anterior resection of the rectum and distal ileostomy. During the operation, the tumor was located 3 cm above the dentate line,

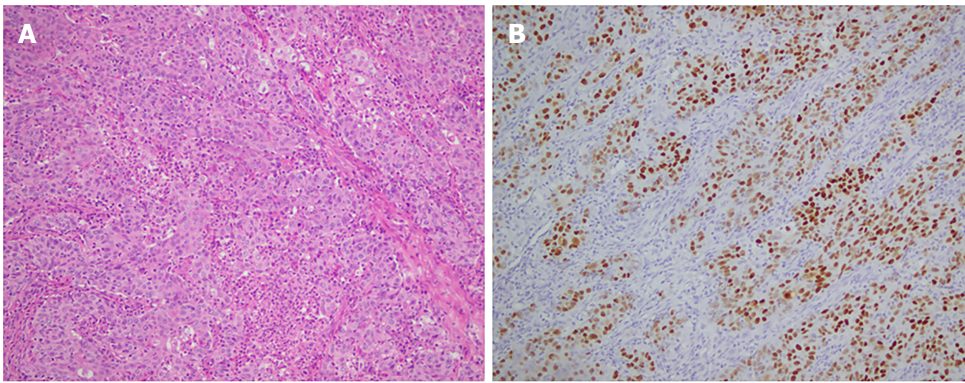


Figure 1 Histopathological and immunohistochemical staining of gastric cancer. A: Poorly differentiated carcinoma in the distal stomach with lymphoid interstitial carcinoma; B: Positive staining for Epstein-Barr virus-encoded ribonucleic acid.

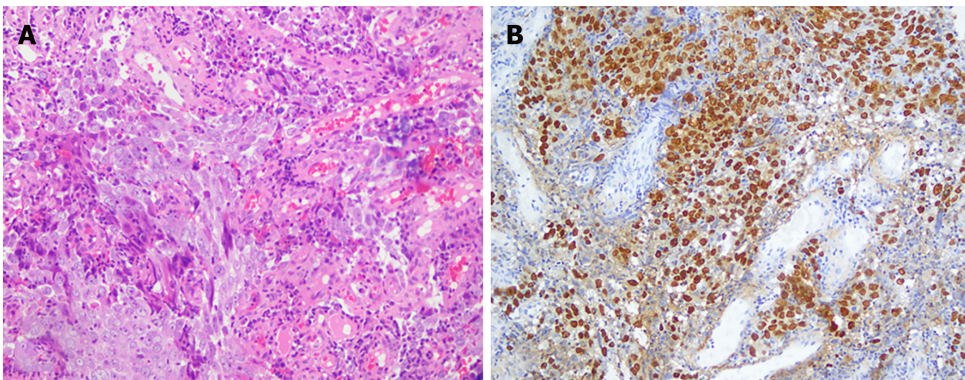


Figure 2 Histopathological and immunohistochemical staining of nasopharyngeal cancer. A: Poorly differentiated squamous cell carcinoma of the nasopharynx by pathology of nasal endoscopic biopsy; B: Positive staining for Epstein-Barr virus-encoded RNA.

with a size of 3 cm × 3 cm and no infiltration into the whole intestinal wall. Postoperative pathology revealed that the tumor was ulcerative, moderately to poorly differentiated adenocarcinoma (Figure 4A), a tumor size of 2.5 cm × 1.5 cm × 1 cm, infiltration into the superficial muscle layer, and T2N0, mesorectal fascia (-), and extramural venous invasion (-). IHC indicated the following tumor cells: Special AT-rich sequence-binding protein 2 (+), caudal-type homeobox 2-88 (+), CK20 (+), Villin (+), human MutL homolog 1 (+), human melanocyte stimulating hormone 2 (+), human melanocyte stimulating hormone 6 (+), PMS1 homolog 1 (+), CD44 (focal+), E-cadherin (+), hair and enhancer of split-1 (+), Ki-67 (80%+), CK7 (-), human epidermal growth factor receptor 2 (-), BRAF (-), 5-hydroxytryptamine receptor 2B (-), zinc finger E-box binding homeobox 1 (-), and EBER (-) (Figure 4B).

MULTIDISCIPLINARY EXPERT CONSULTATION

On Apr 20, 2020, a consultation involving the whole Department of Pathology in our hospital occurred.

The pathology of the gastric lesion was performed, and based on the IHC results in the original hospital, poorly differentiated carcinoma in the distal stomach was observed, consistent with lymphoepithelioma-like carcinoma. The cancer invaded the whole gastric wall and reached the serosa without definite nerve invasion. No cancer was found in the upper or lower margins or anastomotic rings. One lymph node metastasis was found in 14 lymph nodes in the great curvature of the stomach, whereas there were no positive nodes in 37 lymph nodes in the lesser curvature of the stomach. It is difficult to classify further into subtypes based on the Lauren classification. IHC of the original hospital was reevaluated with tumor cells of CK+++, EBER+.

The morphology of the nasopharyngeal biopsy was consistent with EBV-related undifferentiated carcinoma and p63-tumor cells. Based on the medical history,

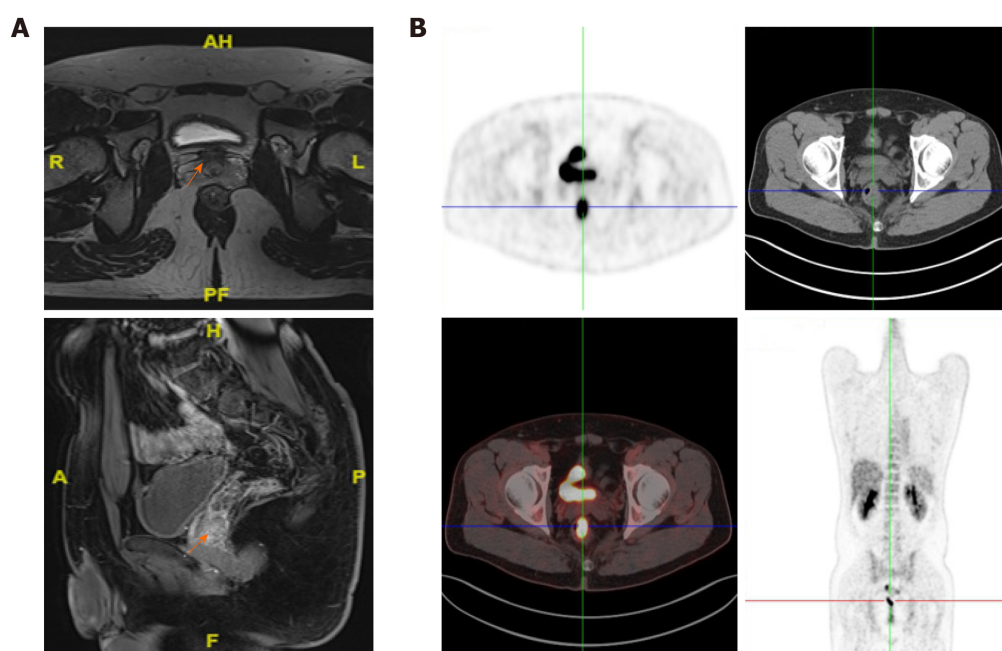


Figure 3 Axial computed tomography images reveal a rectal mass. A: Axial maximum intensive projection at the same imaging level, and coronal images showed a 40 mm solitary nodule approximately 58 mm away above the anus in the rectum; B: Axial images of positron emission topography-computed tomography at the same imaging level, and rectal image of positron emission topography-computed tomography maximum intensive projection showed a thickened medial rectum wall with homogeneous uptake of 18F-fluorodeoxy-glucose, and the maximum standardized uptake value was 14.6.

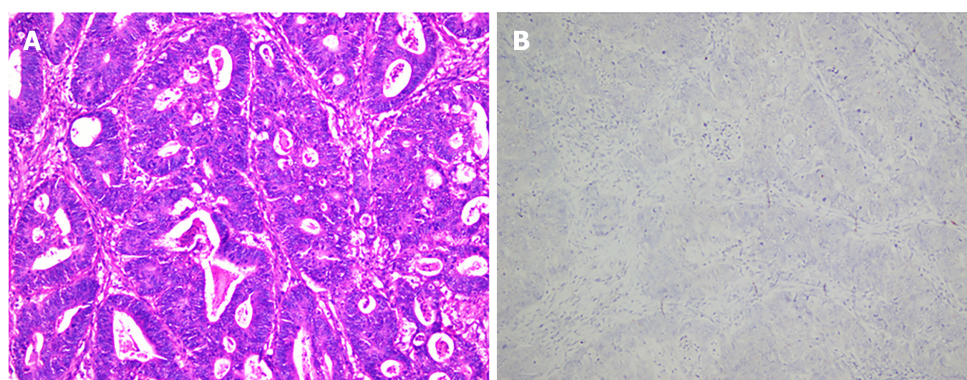


Figure 4 Histopathological and immunohistochemical staining of rectal cancer. A: Postoperative pathology revealed ulcerative, moderately to poorly differentiated adenocarcinoma; B: Negative staining for Epstein-Barr virus-encoded ribonucleic acid.

nasopharyngeal metastasis of stomach carcinoma could not be fully ruled out.

On May 14, 2020, the next-generation sequencing test for his rectal cancer specimens revealed the following: 24 microsatellite (MS) loci were evaluated, and 22 MSs were analyzed. The sample status was microsatellite stable (MSS). The following pathogenic/probably pathogenic variations were detected in the paraffin tissue deoxyribonucleic acid: (1) KRAS (NM_033360.3) missense mutation in exon 4 c.436G > A (p.Ala146Thr), AF 34.43%; (2) APC (NM_000038.5) nonsense mutation in exon 16 c.3340C>T (p.Arg1114*), AF 20.54%; (3) APC (NM_000038.5) code shift mutation in exon 16 c.4127_4128del (p.Tyr1376fs), AF 22.71%; (4) TP53 (NM_000546.5) nonsense mutation in exon 9 c.991C>T (p.Gln331*), AF 3.71% (Figure 5A); (5) TP53 (NM_000546.5) missense mutation in exon 8 c.844C>T (p.Arg282Trp), AF 37.89% (Figure 5B); and (6) single nucleotide polymorphisms of drug metabolism-related enzymes indicated that bilirubin UDP-glucuronosyltransferase 1A1*28, bilirubin UDP-glucuronosyltransferase 1A1*6, cytochrome P450 2D6*10, dihydropyrimidine dehydrogenase*2A, and dihydropyrimidine dehydrogenase*13 were wild type. In September 2020, gene sequencing revealed that the mutation in the TP53 gene was not present in the peripheral blood samples (Figure 6).

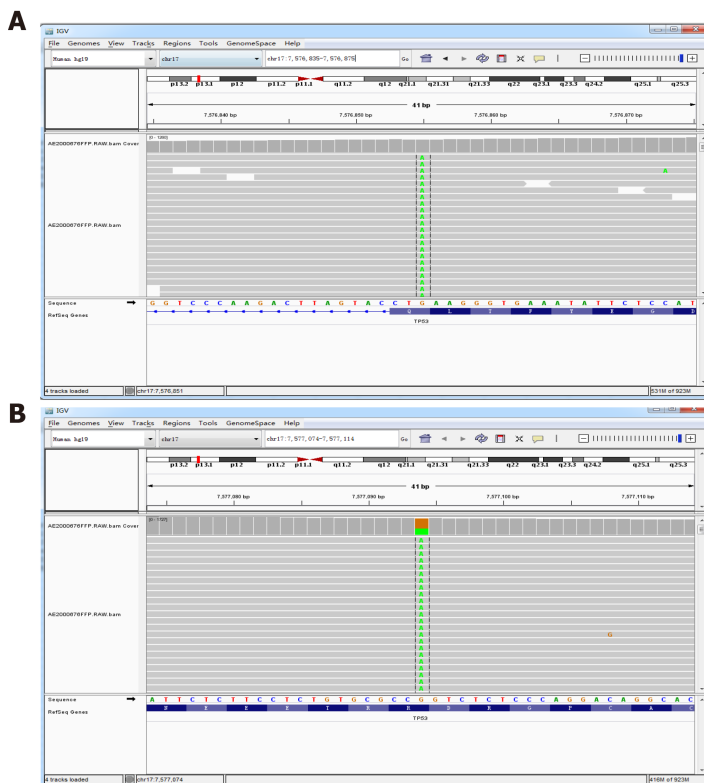


Figure 5 Next-generation sequencing test in rectal cancer specimens. A: Tumor protein 53 (TP53; NM_000546.5) nonsense mutation in exon 9 c.991C>T (p.Gln331*), AF 3.71%; B: TP53 (NM_000546.5) missense mutation in exon 8 c.844C>T (p.Arg282Trp), AF 37.89%.

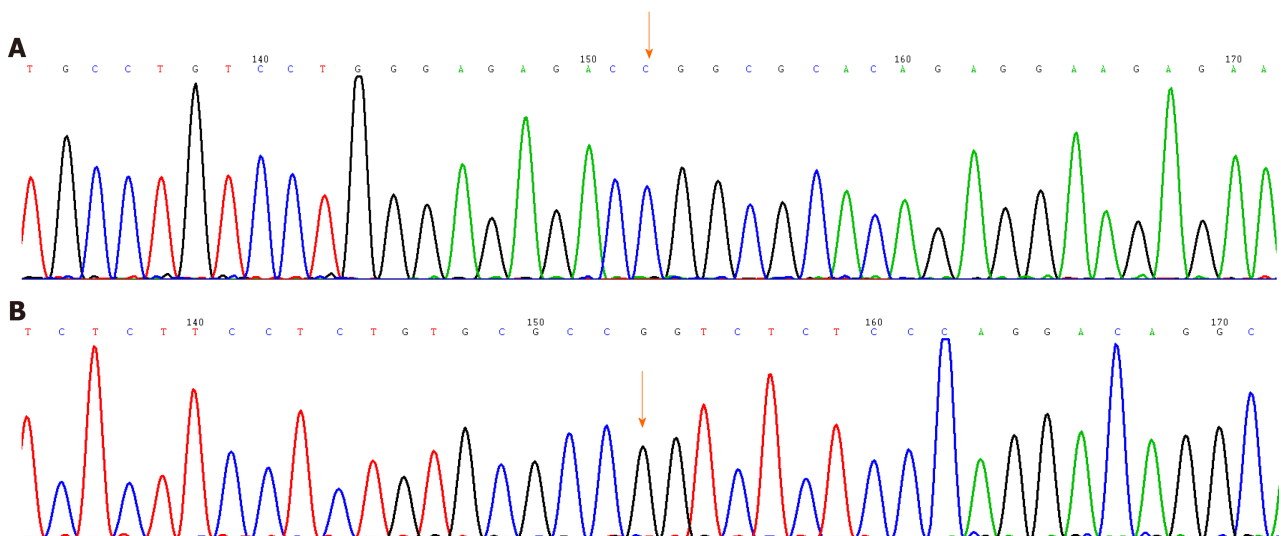


Figure 6 Mutation of waveform of the tumor protein 53 gene fragment. A and B: There were no base mutations.

FINAL DIAGNOSIS

After combining clinical features and pathological findings, the patient was diagnosed with MPMN with rectal cancer (pT2N0M0, stage I) as the third primary, nasopharyngeal undifferentiated cancer as the second primary (EBER+), and gastric cancer as the first primary (pT3N1M0, stage III, EBER+). The timeline of diagnosis and treatment is shown in Figure 7.

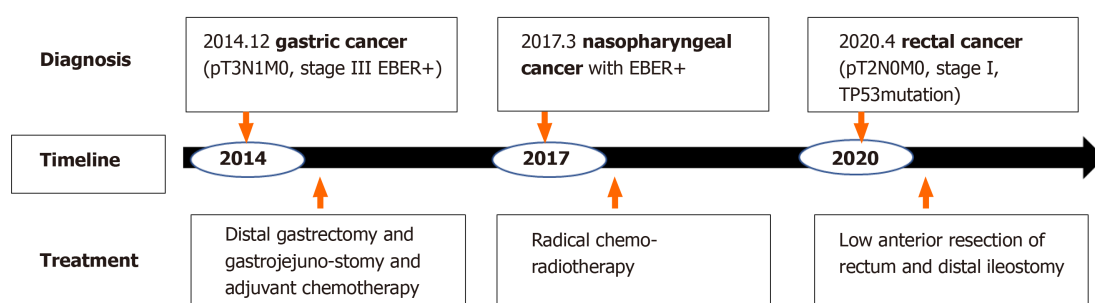


Figure 7 The timeline of diagnosis and treatment for multiple primary malignant neoplasms. EBER: Epstein-Barr virus-encoded ribonucleic acid; TP53: Tumor protein 53.

TREATMENT

There was no adjuvant chemotherapy or radiotherapy administered. The patient was regularly followed up.

OUTCOME AND FOLLOW-UP

The patient was followed up until September 30, 2020. The postoperative recovery of rectal cancer was satisfactory, and normal life was resumed. The blood tests for the tumor markers showed no findings, and the routine imaging examination showed no evidence of tumor occurrence or metastasis. The patient provided written informed consent for publication of this case report.

DISCUSSION

Currently, the diagnosis of MPMNs is mostly based on Warren *et al*^[9]'s revised diagnostic criteria: (1) Each tumor is pathologically confirmed as malignant; (2) Each tumor must exist independently in the anatomy; and (3) Each tumor must be excluded as metastases of other tumors. According to the time interval between the two primaries, Moertel *et al*^[10] divided MPMN into synchronous and metachronous MPMNs^[10], which occur within 6 mo and more than 6 mo, respectively. In this case, the middle-aged male patient developed three distinct primary malignant tumors within three different organs (stomach, nasopharynx, and colorectum), and the time interval between them was longer than 6 mo; thus, the progression of the patient's disease met the criteria of the diagnosis of metachronous MPMN.

Notably, there was a debate about the pathological diagnosis of primary nasopharyngeal carcinoma in the present case. This case and published studies have shown that EBV infection-related lymphoepithelioma-like gastric cancer and nasopharyngeal carcinoma share the same characteristics, except for different sites of occurrence^[11]. However, 90% of nasopharyngeal squamous cell cancers in China are EBER positive, and patients with gastric cancer undergo radical treatments. Furthermore, the lesion in the nasopharynx was the only cancer lesion at that time and occurred 27 mo after the gastric cancer. Therefore, the tumor board of the multidisciplinary team for Cancer of Multiple and Unknown Primaries in Fudan University Shanghai Cancer Center agreed on nasopharyngeal carcinoma as the second primary carcinoma.

Possible causes of MPMN include abnormal activation of oncogenes, silencing of tumor suppressor genes, epigenetic alterations, chromosome instability, immune deficiency, exposure to environmental factors, and an unhealthy lifestyle^[12-14]. Recently, EBV has become the focus of attention of many scholars. EBV, a double-stranded deoxyribonucleic acid virus with a length of approximately 172 kb, mainly attacks human B lymphocytes and epithelial cells through proliferative infection and latent infection, and the virus is mostly in the state of latent infection and does not replicate^[15]. EBV has an infection rate of 1.09% in the general population and is linked to the development of two major epithelial malignancies, including gastric and nasopharyngeal carcinoma^[16]. EBV-encoded small RNA (EBER, EBER1, and EBER2), used as a molecule to signal EBV infection in tissues by *in situ* hybridization, is highly

expressed in latent EBV-infected cells to evade immune surveillance and maintain lifelong latent infection^[17,18]. EBER1/2 could promote the growth of cells, regulate the innate immune system, and promote the formation of tumors *via* the following mechanisms: Adjusting the interleukin-6/signal transducer and activators of transcription-3/P21 and p27 pathways to promote the occurrence of gastric cancer, promoting the expression of focal adhesion kinase phosphorylation to promote cancer cell migration, and serving as an autocrine growth factor to promote the growth of cancer cells^[19,20]. Several reports have shown that early diagnosis and early intervention of EBV infection are helpful to improve the prognosis of EBV virus-associated tumors. The patient denied smoking, drinking, and other bad living habits, which might exclude lifestyle carcinoma, and had no family history of cancer, which can exclude familiar and hereditary cancer; therefore, EBV infection may be the common cause for gastric and nasopharyngeal cancer.

However, the EBER transcript was not found in the colorectal cancer of the patient. The allele frequencies of the K-ras gene missense mutation, APC gene shift mutation, and *TP53* gene missense mutation (exon 8) were 34.43%, 22.7%, and 37.89% by next-generation sequencing, respectively. Moreover, the mutation in the *TP53* genes in the patient was a somatic heterozygous mutation, and no germline gene mutations were found, providing a direction for us to explore the etiologic factors of the third primary cancer.

Lv *et al*^[2] reported that the most common organ of MPMN involved the digestive system with adenocarcinoma, including the stomach and the esophagus^[2]. A literature review of metachronous triple primary neoplasms was performed after searching the PubMed database. Only 19 cases of clinical metachronous triple primary neoplasms have been reported between 1995 and 2020. Table 1 shows a summary of the previous studies describing metachronous triple primaries. Approximately half of the patients had primary colorectal cancer. There have been no reports of heterochronic triple primary malignancies with gastric cancer, nasopharyngeal cancer or rectal cancer. Kato *et al*^[21] reported a high incidence of gastric cancer complicated with colorectal cancer^[21]. Colorectal cancer is the fourth most common malignant tumor in China, posing a serious threat to human health. Obviously, there were different etiologic factors for gastric and rectal cancers in this patient.

In this study, the patient was 6 years past the first onset of primary gastric cancer, 2 more years past the second primary nasopharyngeal cancer, and 7 mo past the third primary rectal cancer. All the treatment of this patient followed the guidelines for each primary cancer. Currently, this patient is in good survival condition without any evidence of recurrence or metastasis. Generally, patients with MPMN have a better prognosis than other cancer patients with no MPMN. As expected, the misdiagnosis of a primary lesion as the metastasis of the prior cancer can lead to incorrect treatment and a poor prognosis.

CONCLUSION

The occurrence of triple heterochronic primary malignancies associated with EBV infection and genetic mutations is an extremely rare event. To the best of our knowledge, this is the first case of a 39-year-old male patient with triple heterochronic primary tumors including EBV-associated stomach cancer and nasopharyngeal cancer and *TP53* mutant rectal carcinoma in the literature, and appropriate therapy for each primary cancer led to his good clinical outcome. This case further confirms the value of precision medicine; only a precise diagnosis can lead to appropriate treatment and good prognosis. Further research is needed to elucidate the role of EBV infection and the *TP53* gene in the carcinogenesis of MPMN.

Table 1 Summary of all existing cases of heterochronic triple primary malignancies in the English literature, *n* = 19

Ref.	Age in yr/gender	Sites	Tumor histology	Treatment	Outcome	Follow-up
Li <i>et al</i> ^[22] , 2020	67/F	Uterine	Moderately differentiated endometrial cancer	Surgery RT CT ET	DFS	19 mo
		Colon	Ascending colon papillary adenocarcinoma and moderately differentiated tubular adenocarcinoma			
		Breast	Invasive ductal carcinoma			
Feng <i>et al</i> ^[23] , 2018	66/M	Prostate	Acinar adenocarcinoma	Surgery CT	DFS	4 mo
		Colon	Moderately differentiated adenocarcinoma			
		Lung	Moderately differentiated adenocarcinoma			
Gheonea <i>et al</i> ^[24] , 2017	75/M	Prostate	Prostate carcinoma	ET	NM	NM
		Lung	Small lung cell carcinoma			
		Skin	Basal cell carcinoma			
Kim <i>et al</i> ^[25] , 2017	73/M	Lung	Small cell carcinoma	Surgery CT	DFS	44 mo
			Poorly differentiated adenocarcinoma			
			Moderately differentiated squamous cell carcinoma			
Yoshikawa <i>et al</i> ^[26] , 2017	60/M	Bile duct	Papillary adenocarcinoma	Surgery CT RT	DFS	NM
			Poorly differentiated cholangio cellular carcinoma			
			A well-differentiated hilar cholangiocarcinoma			
Pastore <i>et al</i> ^[27] , 2015	70/M	Renal	Renal clear cell carcinoma	Surgery RT CT ET	NM	NM
		Oropharynx	Poorly-differentiated (G3) squamous cell carcinoma			
		Prostate	Adenocarcinoma			
Nishikawa <i>et al</i> ^[28] , 2014	37/M	Hypopharynx	Squamous cell carcinoma	Surgery RT CT	DOD	10 yr
		Esophagus				
		Tongue				
Okumura <i>et al</i> ^[29] , 2013	73/M	Prostatic	Moderately differentiated adenocarcinoma	NM	NM	NM
		Bladder	Grade 2 urothelial carcinoma			
		Renal	Grade 2 clear renal cell carcinoma			
Zargar-Shoshtari <i>et al</i> ^[30] , 2013	71/M	Renal	Clear renal cell carcinoma	Surgery ET	DOD	1 yr
		Prostate	Adenocarcinoma			
		Breast	Poorly differentiated invasive ductal cell carcinoma			
Freeman ^[31] , 2013	72/M	Colon	Moderately differentiated adenocarcinoma in the distal sigmoid colon	Surgery	DFS	15 yr
			Infiltrative moderately differentiated colonic			
			Adenocarcinoma in the descending colon moderately differentiated adenocarcinoma in the rectum			
Chang <i>et al</i> ^[32] , 2013	67/M	Maxillary sinus	Adenoid cystic carcinoma	Surgery RT	DFS	15 yr
		Esophagus	Squamous cell carcinoma			22 mo
		Tympanic membrane				18 mo
Egashira <i>et al</i> ^[33] , 2013	63/F	Esophagus	Esophageal cancer	Surgery	DFS	10 mo
		Colon	Ascending colon cancer			
		Jejunum	Jejunal cancer			
Takalkar <i>et al</i> ^[34] , 2013	64/F	Small intestine	Moderately differentiated adenocarcinoma	Surgery CT	NM	NM
		Breast	Well differentiated infiltrated duct carcinoma			

Arikan-Sengul <i>et al</i> ^[35] , 2009	70/M	Ovary	Papillary adenocarcinoma			
		Bladder	Transitional cell carcinoma	NM	NM	NM
		Prostate				
		Renal	Renal cell carcinoma			
Yamanaka <i>et al</i> ^[36] , 2008	24/F	Humerus	Steosarcoma	Surgery CT	NM	NM
		Breast	The light breast cancer the left breast cancer			
Oztop <i>et al</i> ^[37] , 2008	76/M	Rectum	Metastatic rectal cancer	Surgery CT	DOD	1 yr
		Prostate	Prostate cancer	RT ET		
		Lymphocyte	Philadelphia (+) chronic myeloid leukemia			
Baba <i>et al</i> ^[38] , 2002	64/M	Lung	Small cell lung cancer	Surgery	DFS	20 mo
		Prostate	Moderately or poorly differentiated adenocarcinoma			
		Breast	Scirrhus carcinoma			
Iioka <i>et al</i> ^[39] , 2000	60/M	Colon	Sigmoid colon cancer	Surgery RT	DOD	13 mo
		Stomach	Early gastric cancer			
		Esophagus	The middle thoracic esophagus cancer			
Saitoh <i>et al</i> ^[40] , 1995	64/M	Lung	Moderately differentiated squamous cell carcinoma	Surgery RT	NM	NM
		Colon	The rectum carcinoma			
		Trachea	Moderately differentiated squamous cell carcinoma with mediastinal lymph node metastasis			

CT: Computed tomography; DFS: Disease free; DOD: Died of disease; ET: Endocrinotherapy; F: Female; M: Male; NED: No evidence of disease; NM: Not mentioned; RT: Radiotherapy.

REFERENCES

- 1 Demandante CG, Troyer DA, Miles TP. Multiple primary malignant neoplasms: case report and a comprehensive review of the literature. *Am J Clin Oncol* 2003; **26**: 79-83 [PMID: 12576929 DOI: 10.1097/0000421-200302000-00015]
- 2 Lv M, Zhang X, Shen Y, Wang F, Yang J, Wang B, Chen Z, Li P, Zhang X, Li S, Yang J. Clinical analysis and prognosis of synchronous and metachronous multiple primary malignant tumors. *Philos Medicine (Baltimore)* 2017; **96**: e6799 [PMID: 28445321 DOI: 10.1097/MD.0000000000006799]
- 3 Tsao SW, Tsang CM, Lo KW. Epstein-Barr virus infection and nasopharyngeal carcinoma. *Philos Trans R Soc Lond B Biol Sci* 2017; **372**: 20160270 [PMID: 28893937 DOI: 10.1098/rstb.2016.0270]
- 4 Naseem M, Barzi A, Brezden-Masley C, Puccini A, Berger MD, Tokunaga R, Battaglin F, Soni S, McSkane M, Zhang W, Lenz HJ. Outlooks on Epstein-Barr virus associated gastric cancer. *Cancer Treat Rev* 2018; **66**: 15-22 [PMID: 29631196 DOI: 10.1016/j.ctrv.2018.03.006]
- 5 Ghosh SK, Perrine SP, Faller DV. Advances in Virus-Directed Therapeutics against Epstein-Barr Virus-Associated Malignancies. *Adv Virol* 2012; **2012**: 509296 [PMID: 22500168 DOI: 10.1155/2012/509296]
- 6 Tao Q, Young LS, Woodman CB, Murray PG. Epstein-Barr virus (EBV) and its associated human cancers--genetics, epigenetics, pathobiology and novel therapeutics. *Front Biosci* 2006; **11**: 2672-2713 [PMID: 16720343 DOI: 10.2741/2000]
- 7 Otsuka K, Ishioka C. [TP53 mutations and molecular epidemiology]. *Gan To Kagaku Ryoho* 2007; **34**: 683-689 [PMID: 17496437]
- 8 Li XL, Zhou J, Chen ZR, Chng WJ. P53 mutations in colorectal cancer - molecular pathogenesis and pharmacological reactivation. *World J Gastroenterol* 2015; **21**: 84-93 [PMID: 25574081 DOI: 10.3748/wjg.v21.i1.84]
- 9 Warren S. Multiple primary malignant tumors: A survey of the literature and a statistical study. *Am J Cancer* 1932; **93**: 1358-1414 [DOI: 10.1016/0016-5085(87)90440-9]
- 10 MOERTEL CG, DOCKERTY MB, BAGGENSTOSS AH. Multiple primary malignant neoplasms. II. Tumors of different tissues or organs. *Cancer* 1961; **14**: 231-237 [PMID: 13771653 DOI: 10.1002/1097-0142(196103/04)14:2<231::aid-cnrcr2820140203>3.0.co;2-2]
- 11 Hildesheim A. Invited commentary: Epstein-Barr virus-based screening for the early detection of nasopharyngeal carcinoma: a new frontier. *Am J Epidemiol* 2013; **177**: 251-253 [PMID: 23255781 DOI: 10.1093/aje/kws403]
- 12 Oeffinger KC, Baxi SS, Novetsky Friedman D, Moskowitz CS. Solid tumor second primary neoplasms: who is at risk, what can we do? *Semin Oncol* 2013; **40**: 676-689 [PMID: 24331190 DOI: 10.1053/j.seminoncol.2013.09.012]

- 13 **Jiao F**, Yao LJ, Zhou J, Hu H, Wang LW. Clinical features of multiple primary malignancies: a retrospective analysis of 72 Chinese patients. *Asian Pac J Cancer Prev* 2014; **15**: 331-334 [PMID: 24528052 DOI: 10.7314/apjcp.2014.15.1.331]
- 14 **Wang L**, Wang H, Wang T, Liu J, Chen W, Wang Y, Chen C, Zhu H, Dai P. Analysis of polymorphisms in genes associated with the FA/BRCA pathway in three patients with multiple primary malignant neoplasms. *Artif Cells Nanomed Biotechnol* 2019; **47**: 1101-1112 [PMID: 30942098 DOI: 10.1080/21691401.2019.1575846]
- 15 **Yin H**, Qu J, Peng Q, Gan R. Molecular mechanisms of EBV-driven cell cycle progression and oncogenesis. *Med Microbiol Immunol* 2019; **208**: 573-583 [PMID: 30386928 DOI: 10.1007/s00430-018-0570-1]
- 16 **Kanda T**, Yajima M, Ikuta K. Epstein-Barr virus strain variation and cancer. *Cancer Sci* 2019; **110**: 1132-1139 [PMID: 30697862 DOI: 10.1111/cas.13954]
- 17 **Gruhne B**, Sompallae R, Masucci MG. Three Epstein-Barr virus latency proteins independently promote genomic instability by inducing DNA damage, inhibiting DNA repair and inactivating cell cycle checkpoints. *Oncogene* 2009; **28**: 3997-4008 [PMID: 19718051 DOI: 10.1038/onc.2009.258]
- 18 **Iwakiri D**, Takada K. Role of EBERs in the pathogenesis of EBV infection. *Adv Cancer Res* 2010; **107**: 119-136 [PMID: 20399962 DOI: 10.1016/S0065-230X(10)07004-1]
- 19 **Banerjee AS**, Pal AD, Banerjee S. Epstein-Barr virus-encoded small non-coding RNAs induce cancer cell chemoresistance and migration. *Virology* 2013; **443**: 294-305 [PMID: 23791019 DOI: 10.1016/j.virol.2013.05.020]
- 20 **Samanta M**, Takada K. Modulation of innate immunity system by Epstein-Barr virus-encoded non-coding RNA and oncogenesis. *Cancer Sci* 2010; **101**: 29-35 [PMID: 19886912 DOI: 10.1111/j.1349-7006.2009.01377.x]
- 21 **Kato T**, Suzuki K, Muto Y, Sasaki J, Tsujinaka S, Kawamura YJ, Noda H, Horie H, Konishi F, Rikiyama T. Multiple primary malignancies involving primary sporadic colorectal cancer in Japan: incidence of gastric cancer with colorectal cancer patients may be higher than previously recognized. *World J Surg Oncol* 2015; **13**: 23 [PMID: 25889477 DOI: 10.1186/s12957-014-0432-2]
- 22 **Li G**, Yao J, Wu T, Chen Y, Wang Z, Wang Y, Wang F, Zhong R, Yang S. Triple metachronous primary cancer of uterus, colon, and breast cancer: A case report and review of the literature. *Medicine (Baltimore)* 2020; **99**: e21764 [PMID: 32846803 DOI: 10.1097/MD.00000000000021764]
- 23 **Feng Y**, Zhong M, Zeng S, Xiao D, Liu Y. Metachronous triple primary neoplasms with primary prostate cancer, lung cancer, and colon cancer: A case report. *Medicine (Baltimore)* 2018; **97**: e11332 [PMID: 29953024 DOI: 10.1097/MD.00000000000011332]
- 24 **Gheonea IA**, Popp CG, Ivan ET, Gheonea DI. Unusual triple combination of prostate, lung and skin cancer. *Rom J Morphol Embryol* 2017; **58**: 567-574 [PMID: 28730245]
- 25 **Kim JH**, Park SY, Park SJ, Chung MJ, Lee HB. Different histological types of triple metachronous primary lung carcinomas in 1 patient: Case report. *Medicine (Baltimore)* 2017; **96**: e8923 [PMID: 29310384 DOI: 10.1097/MD.00000000000008923]
- 26 **Yoshikawa M**, Ikemoto T, Morine Y, Imura S, Saito Y, Yamada S, Teraoku H, Takata A, Yoshimoto T, Shimada M. Aggressive resection of metachronous triple biliary cancer. *J Med Invest* 2017; **64**: 299-304 [PMID: 28955001 DOI: 10.2152/jmi.64.299]
- 27 **Pastore AL**, Palleschi G, Leto A, Silvestri L, Porta N, Petrozza V, Carbone A. A novel combination of triple metachronous malignancies of the kidney, oropharynx and prostate: A case report. *Oncol Lett* 2015; **10**: 917-920 [PMID: 26622595 DOI: 10.3892/ol.2015.3312]
- 28 **Nishikawa K**, Kawada J, Fujitani K, Hirao M, Yamamoto K, Fukui A, Takagi M, Fushimi H, Iwase K, Endo S, Harada Y, Fukuda Y, Haraguchi N, Miyake M, Asaoka T, Miyamoto A, Miyazaki M, Ikeda M, Nakamori S, Sekimoto M. [A case of metachronous triple cancer treated with a multimodal approach including surgical resection]. *Gan To Kagaku Ryoho* 2014; **41**: 2033-2035 [PMID: 25731413]
- 29 **Okumura A**, Tsuritani S, Takagawa K, Fuse H. [Case of heterochronous triple urogenital cancer (renal cell carcinoma, bladder cancer, prostatic cancer)]. *Nihon Hinyokika Gakkai Zasshi* 2013; **104**: 702-705 [PMID: 24564077 DOI: 10.5980/jpnjurol.104.702]
- 30 **Zargar-Shoshtari MA**, Saffari H, Moslemi MK. Metachronous occurrence of triple malignancies of kidneys, prostate, and breast. A case report and review of the literature. *Case Rep Urol* 2013; **2013**: 194620 [PMID: 23533925 DOI: 10.1155/2013/194620]
- 31 **Freeman HJ**. Triple metachronous colon cancer. *World J Gastroenterol* 2013; **19**: 4443-4444 [PMID: 23885161 DOI: 10.3748/wjg.v19.i27.4443]
- 32 **Chang HY**, Jiang H, Zhou F. A rare case of metachronous triple cancers involving the tympanic membrane. *Pak J Med Sci* 2013; **29**: 218-219 [PMID: 24353544 DOI: 10.12669/pjms.291.2490]
- 33 **Egashira A**, Taguchi K, Toh Y, Yamamoto M, Okamura T, Saeki H, Oki E, Morita M, Ikeda T, Mimori K, Watanabe M, Maehara Y. Successful treatment of primary jejunal cancer after esophageal and colon cancer resection. *Fukuoka Igaku Zasshi* 2013; **104**: 435-441 [PMID: 24620639]
- 34 **Takalkar U**, Asegaonkar BN, Kodlikeri P, Asegaonkar S, Sharma B, Advani SH. An elderly woman with triple primary metachronous malignancy: A case report and review of literature. *Int J Surg Case Rep* 2013; **4**: 593-596 [PMID: 23702365 DOI: 10.1016/j.ijscr.2013.03.032]
- 35 **Arikan-Sengul C**, Pehlivan Y, Sevinc A, Karakok M, Kalender ME, Camci C. A case of metachronous triple primary urogenital cancer: urinary bladder, prostate, and renal cancer. *Onkologie* 2009; **32**: 122-124 [PMID: 19295252 DOI: 10.1159/000197688]
- 36 **Yamanaka S**, Arai H, Rino Y, Masuda M. [Pulmonary metastasis of metachronous triple cancer

- occurring in a young patient]. *Kyobu Geka* 2008; **61**: 541-544 [PMID: [18616097](#)]
- 37 **Oztop I**, Yaren A, Demirpence M, Alacacioglu I, Tuna B, Piskin O, Yilmaz U. The development of metachronous prostate cancer and chronic myeloid leukemia in a patient with metastatic rectal cancer. *J BUON* 2008; **13**: 267-270 [PMID: [18555476](#)]
 - 38 **Baba M**, Higaki N, Ishida M, Kawasaki H, Kasugai T, Wada A. A male patient with metachronous triple cancers of small cell lung, prostate and breast. *Breast Cancer* 2002; **9**: 170-174 [PMID: [12016398](#) DOI: [10.1007/bf02967583](#)]
 - 39 **Iioka Y**, Tsuchida A, Okubo K, Ogiso M, Ichimiya H, Saito K, Osaka Y, Sato S, Aoki T, Koyanagi Y. Metachronous triple cancers of the sigmoid colon, stomach, and esophagus: report of a case. *Surg Today* 2000; **30**: 368-371 [PMID: [10795871](#) DOI: [10.1007/s005950050602](#)]
 - 40 **Saitoh Y**, Umemoto M, Imamura H, Yamanaka E, Hioki K, Okamura A. [A case of metachronous primary cancer of the lung, rectum and trachea]. *Nihon Kyobu Geka Gakkai Zasshi* 1995; **43**: 78-81 [PMID: [7884268](#)]



Published by **Baishideng Publishing Group Inc**
7041 Koll Center Parkway, Suite 160, Pleasanton, CA 94566, USA

Telephone: +1-925-3991568

E-mail: bpgoffice@wjgnet.com

Help Desk: <https://www.f6publishing.com/helpdesk>

<https://www.wjgnet.com>

