

Match Overview

1	Internet 67 words crawled on 01-Jul-2020 www.wjgnet.com	4%
2	Crossref 54 words Guerra, IvÃ¡n. "Ectopic papilla of Vater in the pylorus", World Journal of Gastroenterology, 2009.	3%
3	Internet 30 words crawled on 29-Sep-2016 thieme-connect.com	2%
4	Internet 29 words crawled on 11-Nov-2020 eventscribe.com	2%
5	Internet 14 words crawled on 20-Dec-2019 f6publishing.blob.core.windows.net	1%
6	Crossref 13 words Y Matsuzaki. "Degeneration of skeletal muscle fibers in the rat administrated carbon tetrachloride: similar histologic...	1%

5
Name of Journal: *World Journal of Clinical Cases*

Manuscript NO: 60702

Manuscript Type: CASE REPORT

Acute cholangitis detected ectopic ampulla of vater in the antrum incidentally: A case report

ectopic ampulla of vater in antrum

Hsu-Lin Lee, Chun-Kai Fu

Acute cholangitis detected ectopic ampulla of vater in the antrum ir



Sign in



ALL

IMAGES

VIDEOS

Add the Give with Bing extension >

12,400 Results

Any time ▾

Incidentally detected ectopic ampulla of vater in the ...

www.tropicalgastro.com/articles/36/4/incidentally-detected.html

[3-5] This ectopic ampulla goes undetected unless it causes symptoms, usually related to biliary obstruction or cholangitis or when, for some reason, endoscopic retrograde cholangiopancreatography (ERCP) is attempted. Here we describe a case of colonic tuberculosis with **incidentally detected ectopic Ampulla of Vater in the antrum**. Case report

[PDF] Incidentally detected ectopic ampulla of vater in the ...

www.tropicalgastro.com/filedownload.aspx?id=1376

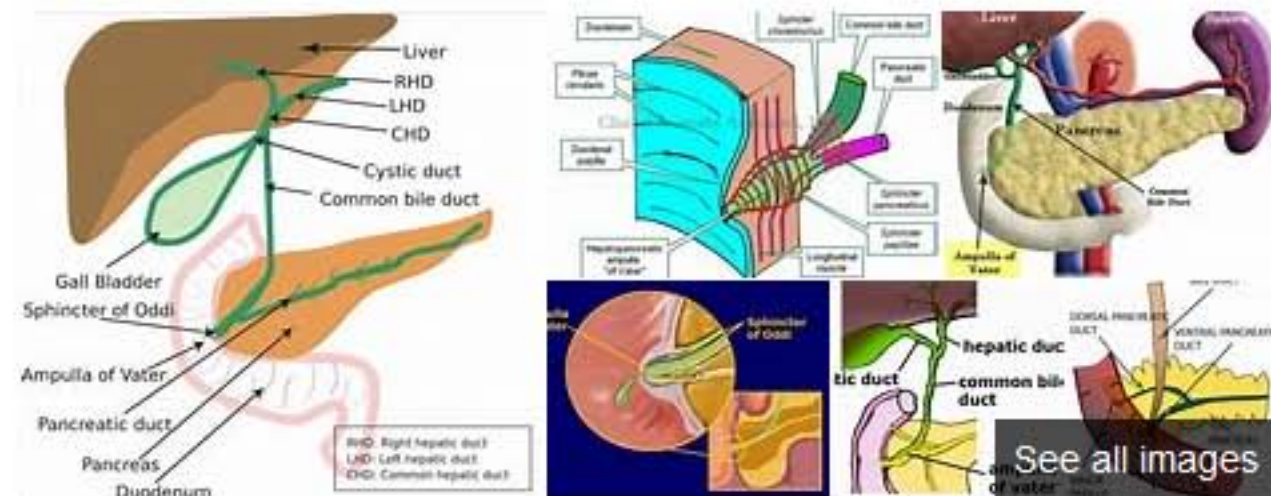
related to biliary obstruction or cholangitis or when, for some reason, endoscopic retrograde cholangiopancreatography (ERCP) is attempted. Here we describe a case of **colonic tuberculosis with incidentally detected ectopic Ampulla of Vater in the antrum**. Case report A 23-year-old female presented with complaints of periumbilical

Author: Mukesh Jain, Gyan Prakash Rai, Rup... Publish Year: 2015

(PDF) Ectopic Location of the Ampulla of Vater Within The ...

<https://www.researchgate.net/publication/265305038...>

Feb 28, 2011 · We found the **ampulla of Vater** in the pyloric channel in a 44 year old patient who had undergone surgery for acute cholecystitis. An intra-operative T ...



Ampulla of Vater

The ampulla of Vater, also known as the hepatopancreatic ampulla or the hepatopancreatic duct, is formed by the union of the pancreatic duct and the common bile duct. The ampulla is specifically located at the major duodenal papilla.



Wikipedia

People also search for: Pancreatic duct · Common bile duct · Gallbladder · Minor duodenal papilla · Cystic duct · Pancreatic islets +

激活 Windows

转到设置以激活 Windows。

[ALL](#)
[IMAGES](#)
[VIDEOS](#)
[MAPS](#)
[NEWS](#)
[SHOPPING](#)

12,600 Results Any time ▾

Incidentally detected ectopic ampulla of vater in the ...

www.tropicalgastro.com/articles/36/4/incidentally-detected.html

[3-5] This ectopic ampulla goes undetected unless it causes symptoms, usually related to biliary obstruction or cholangitis or when, for some reason, endoscopic retrograde cholangiopacreatography (ERCP) is attempted. Here we describe a case of **colonic tuberculosis** with **incidentally detected ectopic Ampulla of Vater in the antrum**. Case report

[PDF] Incidentally detected ectopic ampulla of vater in the ...

www.tropicalgastro.com/filedownload.aspx?id=1376

related to biliary obstruction or cholangitis or when, for some reason, endoscopic retrograde cholangiopacreatography (ERCP) is attempted. Here we describe a case of **colonic tuberculosis** with **incidentally detected ectopic Ampulla of Vater in the antrum**. **Case report** A 23-year-old female presented with complaints of periumbilical

Author: Mukesh Jain, Gyan Prakash Rai, Rupes... **Publish Year:** 2015

(PDF) Ectopic Location of the Ampulla of Vater Within The ...

<https://www.researchgate.net/publication/265305038...>

Feb 28, 2011 · We found the **ampulla** of **Vater** in the pyloric channel in a 44 year old patient who had undergone surgery for **acute** cholecystitis. An intra-operative T ...

[Double common bile duct with ectopic drainage into the ...](#)

[\(PDF\) Ectopic pancreas presenting with intractable ...](#)

[Ectopic pancreas presenting as ampulla of Vater tumor ...](#)

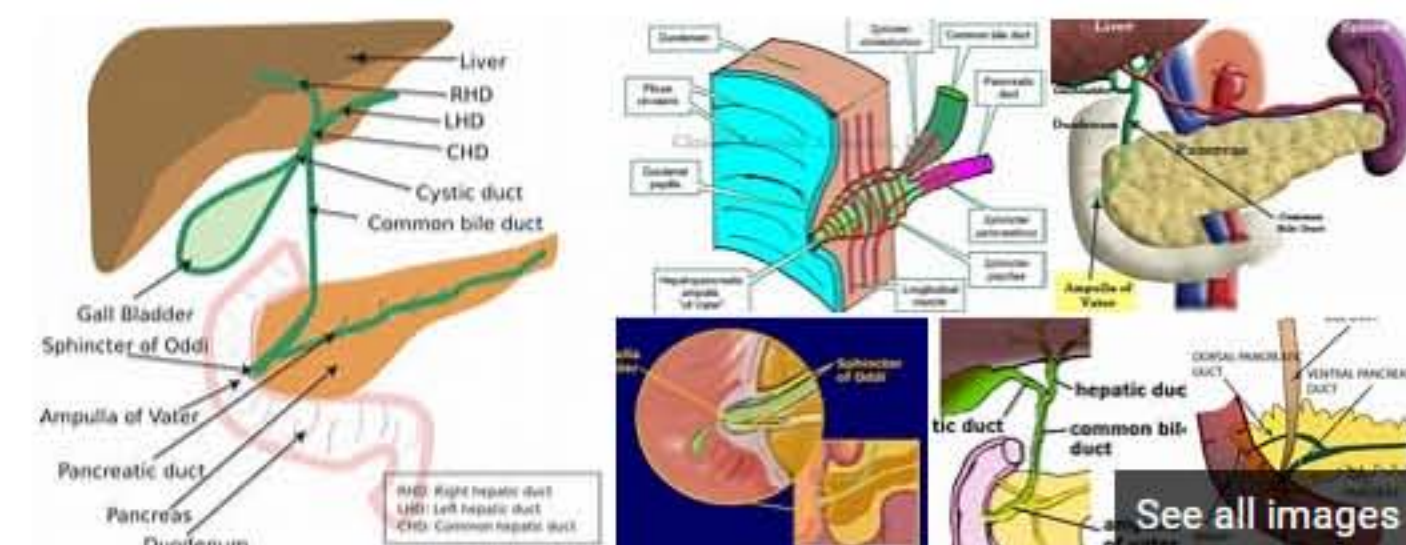
[\(PDF\) Ectopic papilla of Vater in the pylorus](#)

[See more results](#)

(PDF) Inflammation of Ectopic Pancreatic Tissue in a ...

https://www.academia.edu/16252871/Inflammation_of... ▾

longitudinal growth of the intestine continues and exist as The most useful feature for identifying a Meckel's **ectopic** tissue anywhere in the gastrointestinal tract.27 diverticulum on abdominal radiographs is the presence of Klob28 described the histological appearance of a het- enteroliths.14-16 Intussusception (in **a case** with heterotopic ...



Ampulla of Vater

The ampulla of Vater, also known as the hepatopancreatic ampulla or the hepatopancreatic duct, is formed by the union of the pancreatic duct and the common bile duct. The ampulla is specifically located at the major duodenal papilla.

 [Wikipedia](#)

People also search for: [Pancreatic duct](#) · [Common bile duct](#) · [Gallbladder](#) · [Minor duodenal papilla](#) · [Cystic duct](#) · [Pancreatic islets](#) +

Data from: [Wikipedia](#)

[Suggest an edit](#)