

**Name of Journal:** *World Journal of Clinical Cases*

**Manuscript NO:** 61084

**Manuscript Type:** CASE REPORT

**5** *Mycobacterium abscessus* infection after facial injection of argireline: A case report

Chen CF<sup>9</sup> *et al.* *Mycobacterium abscessus* infection after facial injection

Chao-Feng Chen, Jie Liu, Shuang-Shuang Wang, Yu-Fang Yao, Bo Yu, Xiao-Ping Hu

## Abstract

### BACKGROUND

The incidence of infection with *mycobacterium abscessus* (*M. abscessus*) has increased in recent years. This increase is partly associated with invasive cosmetic procedures.

### CASE SUMMARY

The purpose of this case summary is to increase clinicians' awareness of *M. abscessus*

## Match Overview

1	Crossref 36 words Kenjiro Furuta, Akihiro Ito, Tadashi Ishida, Yuhei Ito et al. "18 Cases of pulmonary Mycobacterium abscessus: Clini	2%
2	Crossref 23 words Silva, J.T., F. López-Medrano, M. Fernández-Ruiz, R. San -Juan, M.J. Ruiz-Cano, J.F. Delgado, and J.M. Aguado.	1%
3	Internet 21 words crawled on 23-Jul-2020 mafiadoc.com	1%
4	Internet 17 words crawled on 01-Oct-2020 www.hindawi.com	1%
5	Crossref 17 words Ping Yang, Yongzhou Lu, Tianyi Liu, Yiqun Zhou, Yu Guo, Jingjing Zhu, Chuanlong Jia, Liang Chen, Qingjian Yang...	1%
6	Internet 10 words crawled on 02-Nov-2020 www.vjgnet.com	1%
7	Crossref 9 words D. French. "Advances in Clinical Mass Spectrometry", Els evier BV, 2017	1%
8	Internet 9 words crawled on 15-Oct-2020 www.intechopen.com	1%



A case of Mycobacterium abscessus infection after facial injection



Chat with Bing



Sign in

大家都在搜

NEWS

135微...

ALL

IMAGES

VIDEOS

31,500 Results

Any time ▾

## Mycobacterium chelonae Facial Infections Following ...

<https://www.ncbi.nlm.nih.gov/pmc/articles/PMC4618382>

A cluster of 3 facial **Mycobacterium chelonae infections** occurred **after** cosmetic dermal filler **injections** at a plastic surgery clinic. Pulsed-field gel electrophoresis showed that M chelonae isolated from the clinic tap water were identical to the patient wound isolates. Review of **injection** procedures identified application of nonsterile ice to the skin prior to **injection** as a possible source ...

Cited by: 24

Author: Jan M. Rodriguez, Yingda L. Xie, Kevin L. W...

Publish Year: 2013

## Mycobacterium abscessus Infection After Facial Injection ...

<https://insights.ovid.com/annals-plastic-surgery/...> ▾

**Abstract**We report a case of Mycobacterium abscessus infection in a 29-year-old woman after facial injection with autologous fat. Nineteen months previously, she received a facial surgery of autologous fat injection with the fat harvested from her inner thigh. On examination, she had multiple painful

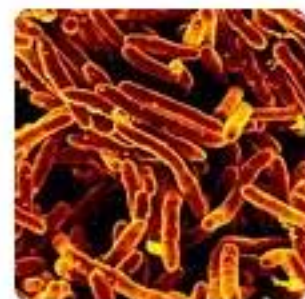Cited by: 1

Author: Ping Yang, Yongzhou Lu, Tianyi Liu, Yiqun Z...

Publish Year: 2017

## Mycobacterium abscessus cutaneous infection secondary to ...

## Mycobacterium Abscessus



Mycobacterium abscessus complex is a group of rapidly growing, multidrug-resistant, nontuberculous mycobacteria species that are common soil and water contamin... +



Wikipedia

Scientific name: Mycobacterium abscessus

Kingdom: Bacteria

Genus: Mycobacterium

Phylum: Actinobacteria

Order: Actinomycetales

Domain: Prokaryote

激活 Windows

转到“设置”以激活 Windows。



Mycobacterium abscessus infection after facial injection of argirelin



Sign in

ALL IMAGES VIDEOS

Add the Give with Bing extension

30,200 Results Any time

## Mycobacterium abscessus Infection After Facial Injection ...

<https://journals.lww.com/annalsplasticsurgery/...>

We report a case of **Mycobacterium abscessus infection** in a 29-year-old woman **after facial injection** with autologous fat. Nineteen months previously, she received a **facial surgery** of autologous fat **injection** with the fat harvested from her inner thigh.

## Mycobacterium abscessus Infection After Facial Injection ...

<https://insights.ovid.com/annals-plastic-surgery/...>

AbstractWe report a case of **Mycobacterium abscessus infection** in a 29-year-old woman **after facial injection** with autologous fat. Nineteen months previously, she received a **facial surgery** of autologous fat **injection** with the fat harvested from her inner thigh. On examination, she had multiple painful

Cited by: 1 Author: Ping Yang, Yongzhou Lu, Tianyi Liu, Yiqun Z...  
Publish Year: 2017

## Mycobacterium chelonae Facial Infections Following ...

<https://www.ncbi.nlm.nih.gov/pmc/articles/PMC4618382>

A cluster of 3 **facial Mycobacterium chelonae infections** occurred **after** cosmetic dermal filler **injections** at a plastic surgery clinic. Pulsed-field gel electrophoresis showed that M chelonae isolated from the clinic tap water were identical to the patient wound isolates. Review of **injection** procedures identified application of nonsterile ice to the skin prior to **injection** as a possible source ...

Cited by: 24 Author: Jan M. Rodriguez, Yingda L. Xie, Kevin L. W...  
Publish Year: 2013

## Mycobacterium abscessus cutaneous infection secondary to ...

<https://europepmc.org/article/PMC/PMC6834988>

Oct 28, 2019 · Introduction. **Mycobacterium abscessus** is a rapidly growing nontuberculous **mycobacterium** existing extensively in water, soil, and dust that causes **infections** of skin, soft tissue, respiratory, and central nervous system by direct contact with contaminated material or water.1 The incidence of cutaneous M **abscessus infection** has increased in the past decade.

Cited by: 1 Author: Xi Chen, Yan Jin, Kara Melissa T. Torres, Bo...  
Publish Year: 2019

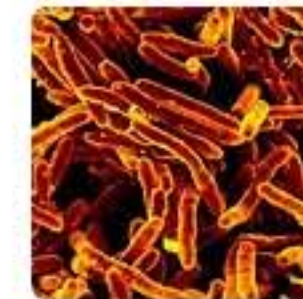## [PDF] CASE REPORT Open Access Facial skin and soft tissue ...

<https://bmcinfectdis.biomedcentral.com/track/pdf/10.1186/1471-2334-13-479>

Table 2 Summary data of **facial skin and soft tissue infection** by rapidly growing **mycobacterium** **after** cosmetic procedures in the literature **Case** Sex/Age Type of procedure Site Microbiologic finding  
Reference 1 F/67 Autologous fat graft Both cheek M. **abscessus** [4] 2 F/50 Autologous fat graft Both cheek M. conceptionense [4]

1 2 3 4 5 >

## Mycobacterium A



Mycobacterium abscessus is a rapidly growing, multidrug-resistant, nontuberculous mycobacteria species that are common soil and water contaminants. Although M. abscessus complex most commonly causes chronic lung infection a... +

Wikipedia

**Scientific name:** Mycobacterium abscessus

**Kingdom:** Bacteria

**Genus:** Mycobacterium

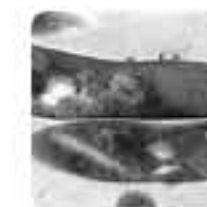**Phylum:** Actinobacteria

**Order:** Actinomycetales

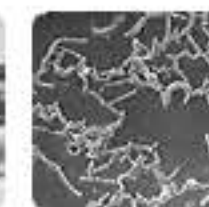
**Domain:** Prokaryote

## People also search for


See all (10+)



Mycobacterium abscessus



Mycobacterium chelonae



Nontuberculous Mycobacteria



Mycobacterium tuberculosis



Mycobacterium leprae

Data from: Wikipedia · Wikidata · Itis

Wikipedia text under CC-BY-SA license

Suggest an edit

## Search Tools

Turn off Hover Translation (关闭取词)



ALL IMAGES VIDEOS MAPS NEWS SHOPPING

30,500 Results Any time ▾ Open links in new tab ☒

## [Mycobacterium abscessus Infection After Facial Injection ...](#)

<https://insights.ovid.com/annals-plastic-surgery/...> ▾

Abstract We report a case of Mycobacterium abscessus infection in a 29-year-old woman after facial injection with **autologous fat**. Nineteen months previously, she received a facial surgery of **autologous fat** injection with the fat harvested from her inner thigh. On examination, she had multiple painful

Cited by: 1 Author: Ping Yang, Yongzhou Lu, Tianyi Liu, Yiqun Z...

Publish Year: 2017

## [Mycobacterium abscessus Infection After Facial Injection ...](#)

<https://journals.lww.com/annalsplasticsurgery/...> ▾

Abstract We report a case of Mycobacterium abscessus infection in a 29-year-old woman after facial injection with **autologous fat**. Nineteen months previously, she received a facial surgery of **autologous fat** injection with the fat harvested from her inner thigh.

## [Mycobacterium abscessus cutaneous infection secondary to ...](#)

[https://www.jaadcasereports.org/article/S2352-5126\(19\)30575-2/fulltext](https://www.jaadcasereports.org/article/S2352-5126(19)30575-2/fulltext)

Oct 28, 2019 · **Mycobacterium abscessus** is a rapidly growing nontuberculous **mycobacterium** existing extensively in water, soil, and dust that causes **infections** of skin, soft tissue, respiratory, and central nervous system by direct contact with contaminated material or water.<sup>1</sup> The incidence of cutaneous M **abscessus infection** has increased in the past decade. Most reported **cases** were associated with ...

Cited by: 1 Author: Xi Chen, Yan Jin, Kara Melissa T. Torres, Bo...

Publish Year: 2019

## [Extensive Infection of Face by Mycobacterium chelonae: An ...](#)

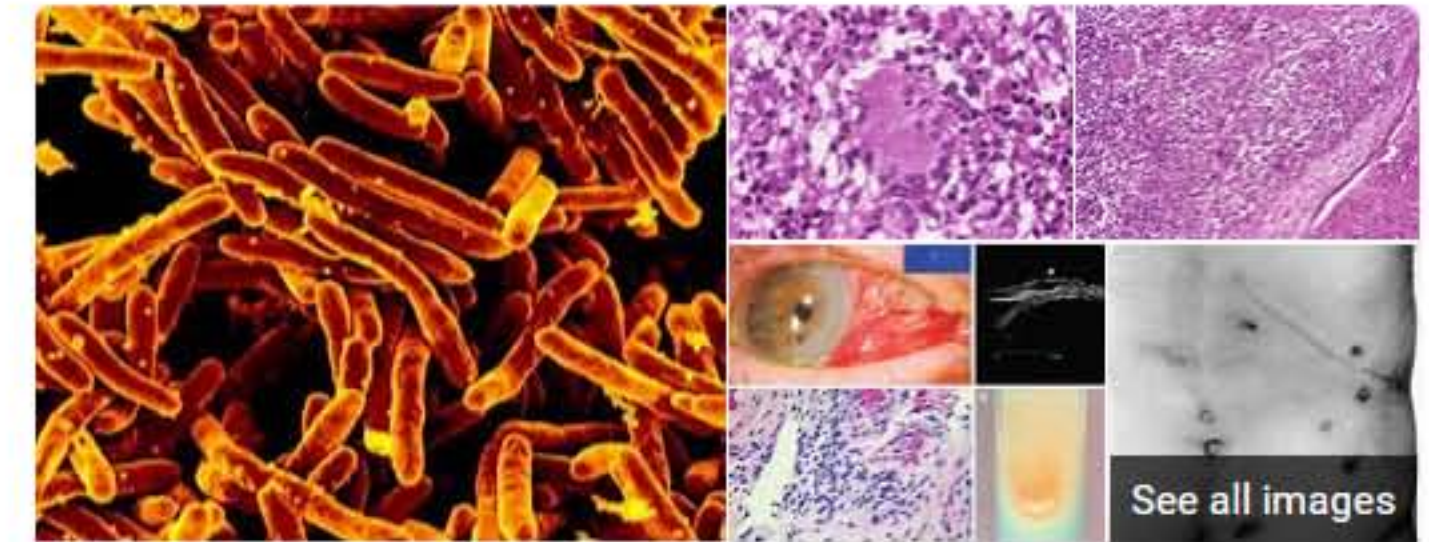
<https://www.ncbi.nlm.nih.gov/pmc/articles/PMC4171922>

Mycobacterium chelonae is rapid growing (Group IV) atypical mycobacteria (growth in 1-7 days) and can cause infections in immunocompromised as well as immunocompetent people. Infections caused are **Cutaneous** infections (cervical skin, hand and leg), post operative infections and injection abscesses. (Face is very unusual site of infection).

Cited by: 1 Author: Swapna A Mali, Tasneem B Doctor, Arun P ...

Publish Year: 2014

## [Nontuberculous Mycobacterial Infection after Fractionated ...](#)



## Mycobacterium Abscessus

Mycobacterium abscessus complex is a group of rapidly growing, multidrug-resistant, nontuberculous mycobacteria species that are common soil and water contaminants. Although M. abscessus complex most commonly causes chronic lung infection and skin and soft tissue infection, the complex can also cause infection in almost all human o... +

 Wikipedia

**Scientific name:** Mycobacterium abscessus

**Kingdom:** Bacteria

**Genus:** Mycobacterium

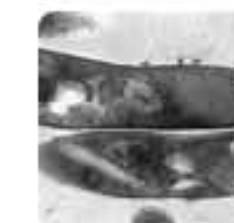**Phylum:** Actinobacteria

**Order:** Actinomycetales

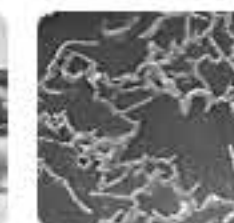**Domain:** Prokaryote

### People also search for


See all (10+)



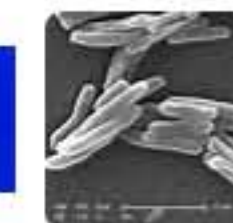Mycobacteri  
um



Mycobacteri  
um



Nontubercul  
ous



Mycobacteri  
um



Mycobacteri  
um Leprae